BMUS ULTRASOUND 2019 December 10th - 12th HARROGATE Convention Centre Diagnosis · Disease · Delivery

NHS Tameside and Glossop Integrated Care NHS Foundation Trust

The Role of New Technologies in Head and Neck Imaging

Authors: Ruth Berry & Gerry Johnson
Radiology Department, Tameside & Glossop Integrated Care NHS Trust, Manchester.

Introduction:

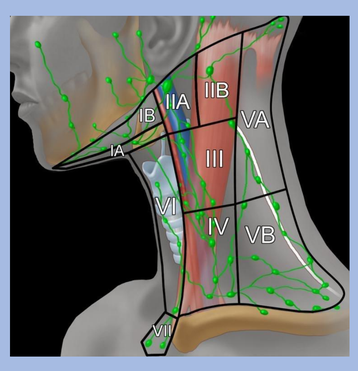

Figure 1 Figure showing Lymph Node levels

Aims and purpose

To assess the use of superb microvascular imaging (SMI) in lateral neck investigations. This poster will give a pictorial review of ultrasound appearances of neck masses and our experience of SMI to date.

The Objectives of the review were:

- To explore whether alongside the characteristic appearances on ultrasound the presence /absence of established vascularity on SMI can improve diagnosis.
- To investigate the efficacy in determining squamous cell carcinoma and also infective lymphadenopathy and to explore whether SMI technology can increase confidence in correct selection of patients for FNAC and possible debate whether there is a need for further interventional procedures.

What is SMI?

The principle underlying SMI is an algorithm that effectively separates vascular flow signals from overlying tissue motion artefacts, preserving even the subtlest low flow components with high definition.[1]

Methodology

All patients presenting with a suspected head and neck lump were seen in a dedicated one stop head and neck clinic, between Jan 2019 to October 2019 (approx. 480 patients were seen in this time period) all scans were performed by a team of Head and Neck Advanced Practitioner sonographers in collaboration with the clinicians. Using a multidisciplinary approach to managing difficult cases.

Case 1: SQUAMOUS CELL CARCINOMA

This patient was referred into the one stop head and neck clinic with history of neck lump for several weeks. Ultrasound revealed an abnormal lymph node with loss of vascular pedicle on application of Power Doppler. SMI revealed chaotic vascularisation with further confirming suspicions of squamous cell carcinoma.

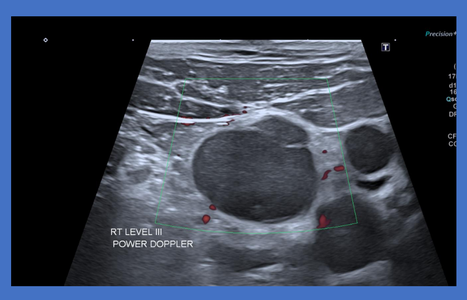

Figure 2: Showing: US Lymph Node with Extracapsular breech note lack of flow on Power Doppler

An initial FNA within the main body of the lesion had previously revealed no malignancy.

SMI revealed neovascularisation within the apparent capsular breach and this area was targeted on a subsequent FNA performed in the head and neck clinic

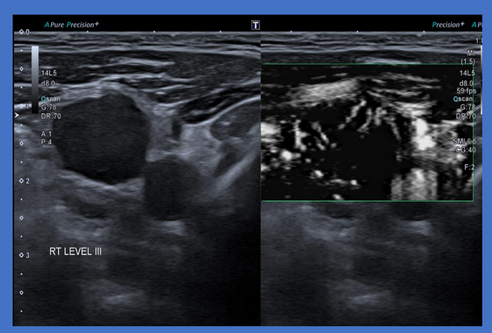

Figure 3: Showing: US Lymph Node with Extracapsular breech: SMI showing neovascularisation

MICROSCOPIC DESCRIPTION OF ABOVE SAMPLE
Sections at levels show squamous mucosa and ulcerated granulation tissue There is severe active chronic inflammatory cell infiltrate, not withstanding which there is a high grade epithelia dysplasia. There are islands of epithelium within the stroma , highly suggestive of neoplasia.

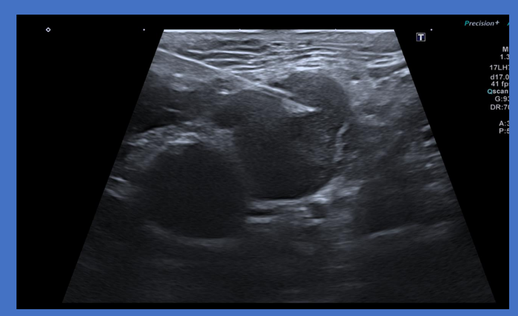

Figure 4: Showing: US Lymph Node with Extracapsular breech, needle t tip in the capsular breech

Following the diagnosis of SCC a staging CT scan was performed revealing a 1cm nodule in the apical segment of the right lower lobe. This was deemed highly concerning for lung metastasis. Patient now undergoing radiotherapy.

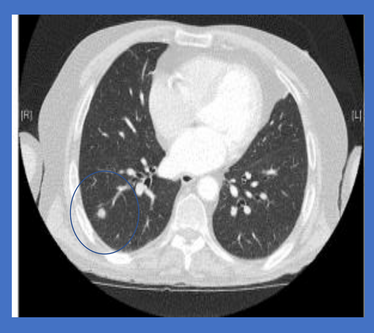

Figure 5: CT Scan showing Lung Metastasis (as circled)

Case 2: SUBMANDIBULAR ADENOCARCINOMA

This 82yr old patient was referred to the one stop head and neck clinic with a 2 week history of the right sided neck lump. This revealed an irregular hypoechoic lesion in the right submandibular gland

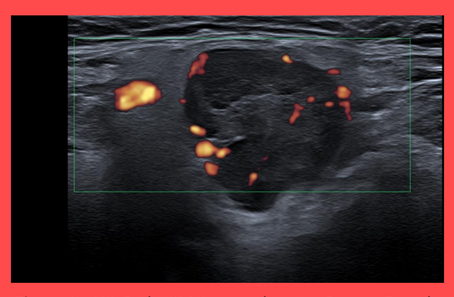

Figure 6: US Right SMG mass showing Power Doppler flow

Scant vascularity was revealed on Power Doppler but as seen below the application of SMI displayed a chaotic vascular pattern along several apparent pathways.

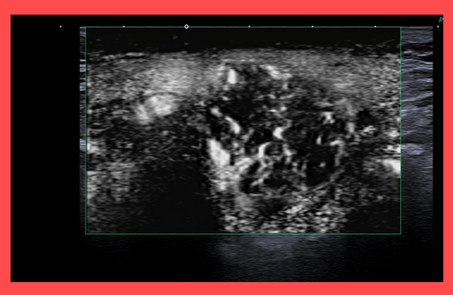

Figure 7: US Right SMG mass showing chaotic SMI flow

Biopsy taken following assessment with SMI to avoid a vascular pathway to decrease the chance of affecting the associated nerve, to reduce risk of palsy. The biopsy revealed adenocarcinoma. This diagnosis prompted a staging scan which revealed spinal metastases.

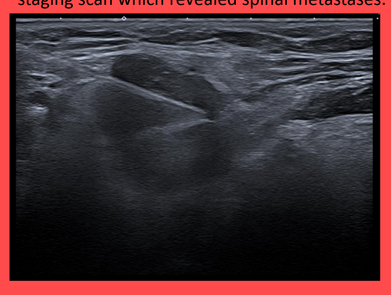

Figure 8: US Right SMG mass showing FNAC

Case 3: REACTIVE LYMPHADENOPATHY

Patient referred for Ultrasound by GP for 4week history of lump in left side of neck. Atypical enlarged lymph node with seemingly chaotic vascular pattern on Colour Doppler (no SMI on machine used at that time). Patient referred on to Head and Neck clinic as suspicious findings.

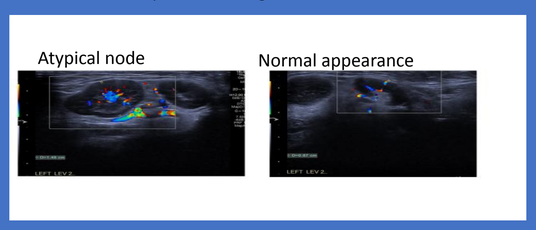

Figure 9: US : Image of Atypical Lymph Node

The patient attends one stop clinic where SMI is available. So whilst the lymph node in question has increased in size the dendritic pattern of vascularity is reassuring, excision biopsy is belayed in favour of follow up scan and patient booked for 6week follow up.

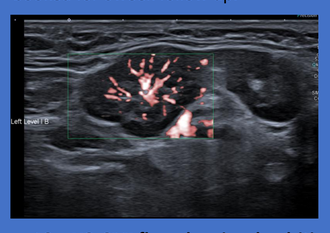

Figure 10 : US SMI flow showing dendritic micro flow

The patient returned 5 weeks later, the B mode image shows some reduction in size and the echogenic hilum is less irregular, whilst the SMI image shows normal dendritic pattern. The patient can now be discharged.

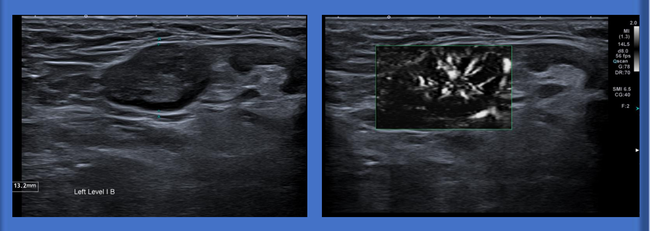

Figure 11: US Lymph Node 5 weeks later, SMI showing dendritic pattern

Conclusion

- SMI revealed normal vascularity with otherwise atypical reactive lymphadenopathy as shown in Case 3
- Increased vascular information improved targeting options for FNA and biopsy shown in both Case 1 and 2

Food for thought…..
Can we use SMI to improve patient care, by reducing the excision biopsy rate for atypical lymph nodes ? Can we biopsy more accurately by using vascularity to avoid likely nerve branches in the salivary glands or target neo-vascular areas of suspicious lesions ? Time and experience may prove this to be an extremely useful tool. Lets see this time next year !

References
1 Toshiba Medical: SMI Superb Microvascular imaging - An essential ultrasound tool