Sheffield Teaching Hospitals NHS Foundation Trust

UNIVERSITY OF LEEDS

What is the diagnostic accuracy of 3D ultrasound in comparison to MRI for uterine anomalies?

Sally-Anne Jones[1] and Jane Arezina[2]

[1]Sonographer, Sheffield Teaching Hospitals [2]Programme Leader, University of Leeds

AIMS

- To determine the accuracy of 3D ultrasound in the characterisation of uterine anomalies (UAs) in comparison with magnetic resonance imaging (MRI) via systematic review – Does 3D ultrasound (3D US) have the potential to replace MRI for the investigation of UAs?
- To make recommendations for local infertility pathways and protocol

BACKGROUND

Congenital uterine anomalies (UAs) range in severity and are caused by fusion failures at varied stages of embryological development[1]. It is widely accepted that UAs are a risk factor for infertility and/or recurrent miscarriage[2] with UAs occurring in approximately 13.3% of infertile patients and between 3% and 38% in patients with repeated spontaneous miscarriage[3].

JUSTIFICATION

- 3D US allows distinctions to be made between septate, bicornuate, arcuate and didelphic uteri.
- Diagnosis of arcuate or bicornuate uteri renders interventional or operative surgery unnecessary[4] whereas septate uteri benefit from surgical repair
- 3D US could inform treatment options, speed up diagnoses and negate the use of further imaging or invasive tests[5].

3D US - bicornuate uterus. Prominent concave indentation.
External contour – fundal indentation > 10 mm dividing the two cornua[6]

3D US - septate uterus.
Presence of septum.
External contour is universally convex or with indentation < 10 mm[6]

METHODOLOGY

3698 initial citations reduced to 4 included in the literature review, reduced via inclusion/exclusion criteria. The 4 articles meeting the inclusion criteria were subject to quality assessment and data extraction.

Articles included in the review:

- Dewan et al (2014) and Ergenoglu et al (2016) compare 3D US and MRI with hysteroscopy/laparoscopy
- Graupera et al (2015) and Bermejo et al (2010) used MRI as reference standard.

RESULTS

Two studies which verified findings with hysteroscopy found 3D US to have higher diagnostic accuracy in the detection of UAs compared with MRI.

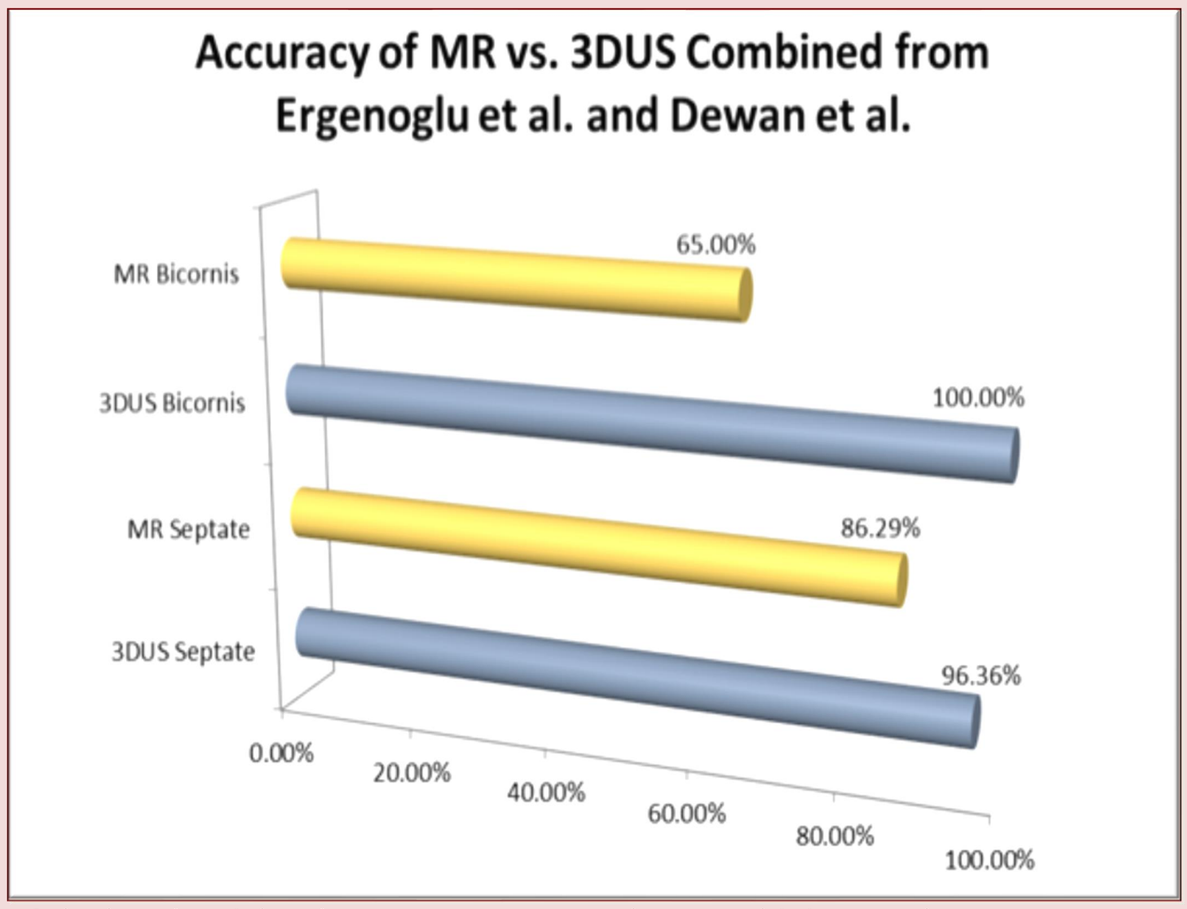

Calculated weighted mean percentage when combining results

DISCUSSION

Quality assessment highlighted that incorporating the test under investigation into the reference standard is likely to inflate the estimate of the test's diagnostic power[5]. A criticism of the studies which use MRI as the reference standard are the assumptions made in the discrepancy cases for example, Graupera et al. (2015) describe one case whereby 3D US diagnosed partial septum, MRI revealed normal morphology which was not investigated further. This is similarly evidenced in the study by Bermejo et al. (2010) as 221 patients received neither the reference standard or further diagnostic tests.

However, findings by Ergenoglu et al. (2016), Dewan et al. (2014), Bermejo et al. (2010) and Graupera et al. (2015) demonstrate the inferior accuracy of MRI in comparison with 3D US, an assertion also noted by Deutch and Abuhamad (2008). Therefore, rather than MRI supplanting invasive procedures a more pertinent suggestion given findings in this study would be to further investigate supplanting MRI with 3D US.

CONCLUSIONS

Despite the limited number of studies conducted, current research demonstrates that the diagnostic accuracy of 3D US in the detection and characterisation of UAs is comparable and indeed superior to MRI.

RECOMMENDATIONS

- Include 3D US as a first line investigation in addition to 2D US for all infertility investigations. This will be implemented locally following multi-disciplinary team discussion for agreement of classification and regular audit of the service will be conducted to ensure quality and consistency[7]
- Further high quality primary research involving large sample sizes which compares 3D US with MRI against surgical diagnosis in order to achieve a definitive answer to the question of accuracy
- Standardised classification criteria incorporating all possible variations and offering clear and distinct descriptions to facilitate diagnosis, evaluation of prognosis and treatment planning[8]
- Adequate training for sonographers and radiologists

REFERENCES

[1]Ekerhovd, E., Fried, G. and Granberg, S. 2004. An ultrasound-based approach to the assessment of infertility, including the evaluation of tubal patency. Best Practice & Research Clinical Obstetrics & Gynaecology. [Online]. 18 (1), pp. 12-28. [Accessed 13 March 2017]. Available from: http://www.sciencedirect.com/science/article [2]Chan, Y. Y., Jayaprakasan, K., Zamora, J., Thornton, J. G., Raine-Fenning, N. and Coomarasamy, A. 2011. The prevalence of congenital uterine anomalies in unselected and high-risk populations: a systematic review. Human reproduction Update. [Online]. 17 (6), pp. 761-771. [Accessed October 29 2017]. Available from: https://www.ncbi.nlm.nih.gov/pmc/articles/PMC3191936/ [3]Huseiny, A. E., Ahmad, R. A., Sadek, S. M., Gouhar, G. K., and Dawood, H. A. 2014. Role of three-dimensional ultrasound in the diagnosis of double uterine cavity anomalies and concordance with laparoscopic and hyseroscopic diagnosis. The Egyptian Journal of Radiology and Nuclear Medicine. [Online]. 45 (2), pp. 555-560. [Accessed 02 December 2016]. Available from: http://www.sciencedirect.com/science/article/ [4]Ghi T., Casadio P., Kuleva M., Perrone A., Savelli L., Giunchi S., Meriggiola M., Gubbini G., Pilu G., Pelusi C and Pelusi G. 2009. Accuracy of three-dimensional ultrasound in diagnosis and classification of congenital uterine anomalies. Fertility and Sterility [Online]. 92 (2), pp. 808-813. [Accessed 04 July 2017]. Available from: https://www.ncbi.nlm.nih.gov/pubmed/18692833 [5]Carrascosa, P., Capuñay, C., Vallejos, J., Carpio, J., Baronio, M. and Papier, S. 2016. Two-dimensional and three-dimensional imaging of uterus and fallopian tubes in female infertility. Fertility and Sterility [Online]. 105 (6), pp. 1403-1420. [Accessed 08 March, 2017]. Available from: http://www.sciencedirect.com/science/article/pii/S0015028216611081 [6]Dewan, K., Hefeda, M. and ElKholy. (2014). Septate or bicornuate uterus: Accuracy of three-dimensional trans-vaginal ultrasonography and pelvic magnetic resonance imaging. The Egyptian Journal of Radiology and Nuclear Medicine. [Online]. 45 (3), pp. 987–995. [Accessed on 04 November, 2016]. Available at: http://www.sciencedirect.com/science/article/pii/S0378603X14000631 [7]Chen, C., Ken, T., Kuo, N. and Tam, K. 2017. Evidence-based health care: A roadmap for knowledge translation. Journal of the Chinese Medical Association. [Online]. Accessed 14 November 2017. Available from: http://www.sciencedirect.com/science/article/pii/S1726490117302307 [8]Sardo, A. D. S., Campo, R., Gordts, S., Spinelli, M., Cosimato, C., Tanos, V., Brucker, T., Li, T. C., Gergolet, M. and Angelis, D. 2015. The comprehensiveness of the ESHRE/ESGE classification of female genital tract congenital anomalies: a systematic review of cases not classified by the AFS system. Human Reproduction. [Online]. 30 (5), pp. 1046-1058. [Accessed on 03 June 2017]. Available from: https://academic.oup.com/humrep/article/30/5/1046/591195

•Bermejo, C., Martínez Ten, P., Cantarero, R., Diaz, D., Pérez Pedregosa, J., Barrón, E., Labrador, E. and Ruiz López, L. (2010). Three-dimensional ultrasound in the diagnosis of Müllerian duct anomalies and concordance with magnetic resonance imaging. Ultrasound in Obstetrics and Gynaecology [Online]. 35 (5), pp. 593–601. [Accessed 05 November, 2016]. Available at: http://onlinelibrary.wiley.com/doi/10.1002/uog.7551/full.

•Deutch T, and Abunhamad, A., (2008). The role of 3-dimensional ultrasonography and magnetic resonance imaging in the diagnosis of mullerian duct anomalies: A review of the literature. Embase Journal of Ultrasound in Medicine. [Online]. 27 (3), pp 413-423. [Accessed on 13 November 2016]. Available at: http://onlinelibrary.wiley.com/doi/10.7863/jum.2008.27.3.413/full

•Ergenoglu, A, M., Sahin, C., Simsek, D., Akdemir, A., Yeniel, A., Yerli, H., and Sendag, F. (2016). Comparison of three-dimensional ultrasound and magnetic resonance imaging diagnosis in surgically proven Müllerian duct anomaly cases. European Journal of Obstetrics and Gynecology and Reproductive Biology. [Online]. 197 pp, 22-26. [Accessed on 06 December, 2016]. Available from: http://www.sciencedirect.com/science/article/pii/S0301211515004