

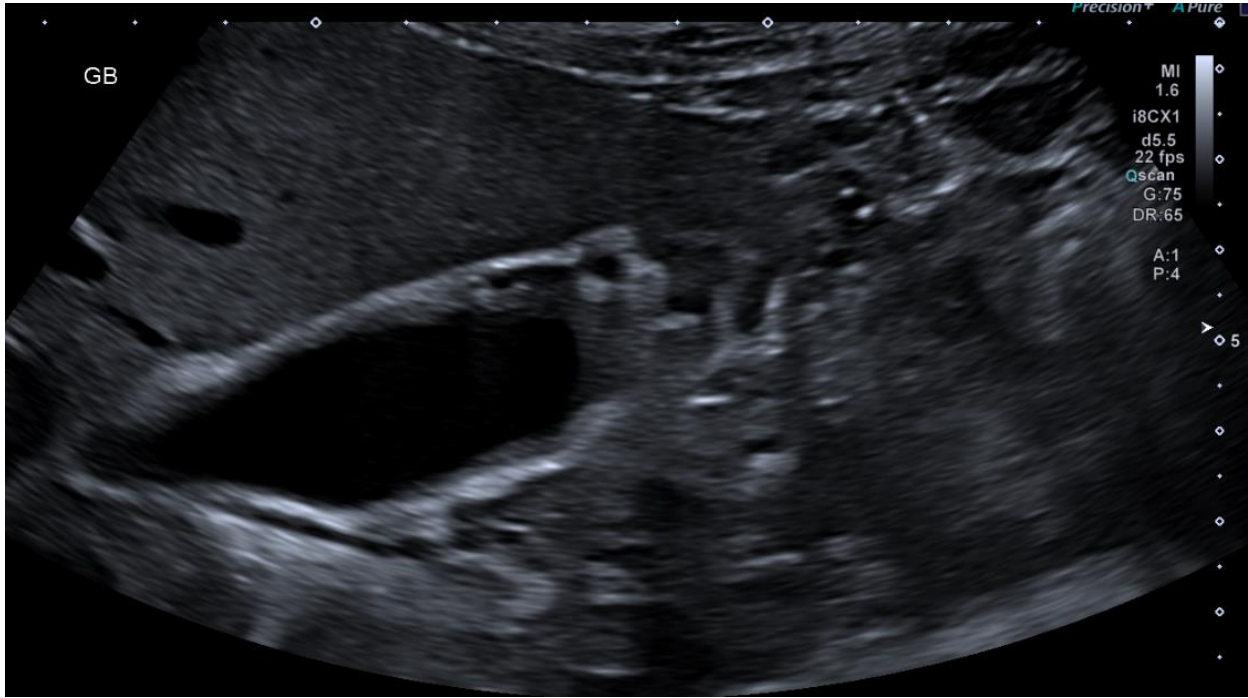
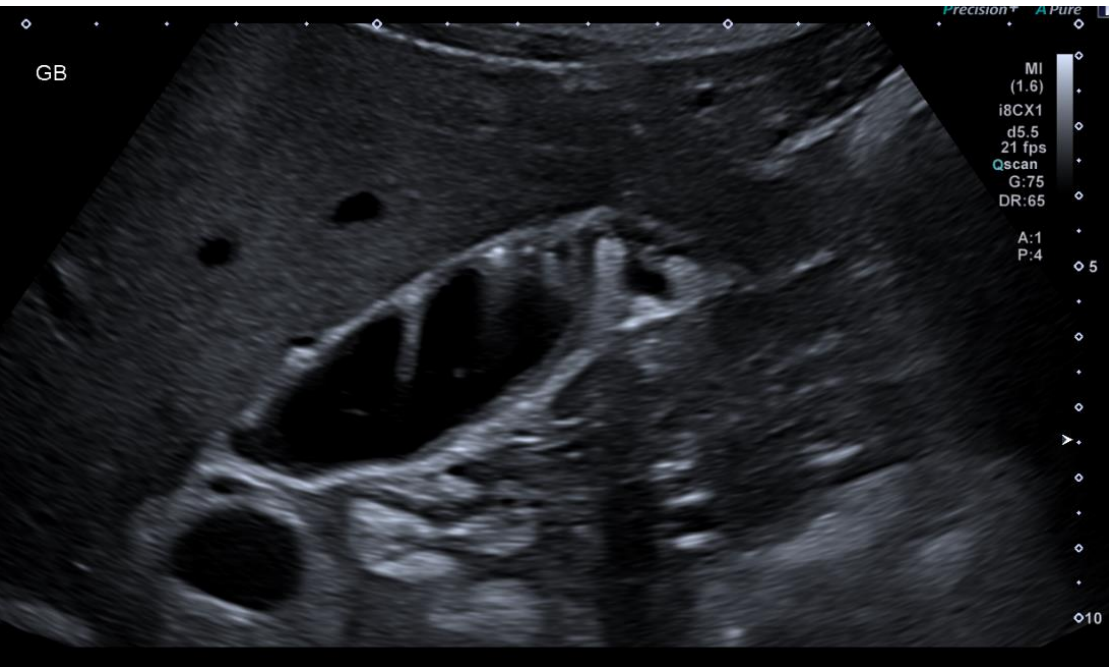
## **General Medical Case 9**

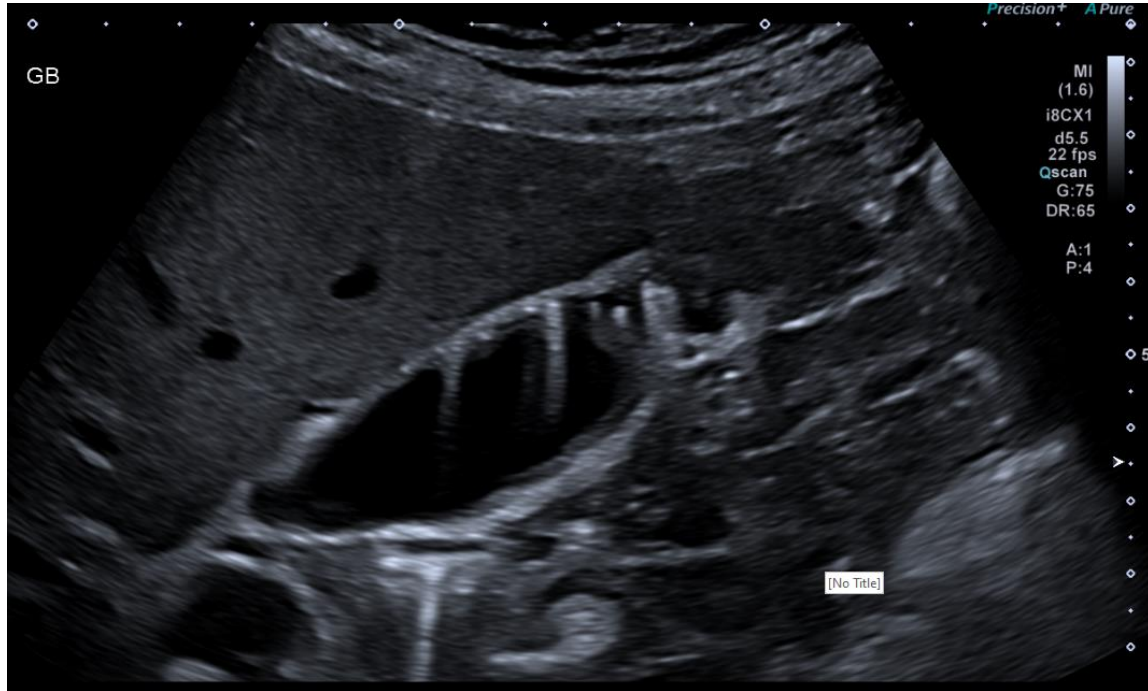**June 2023**

**Clinical details: GP referral**

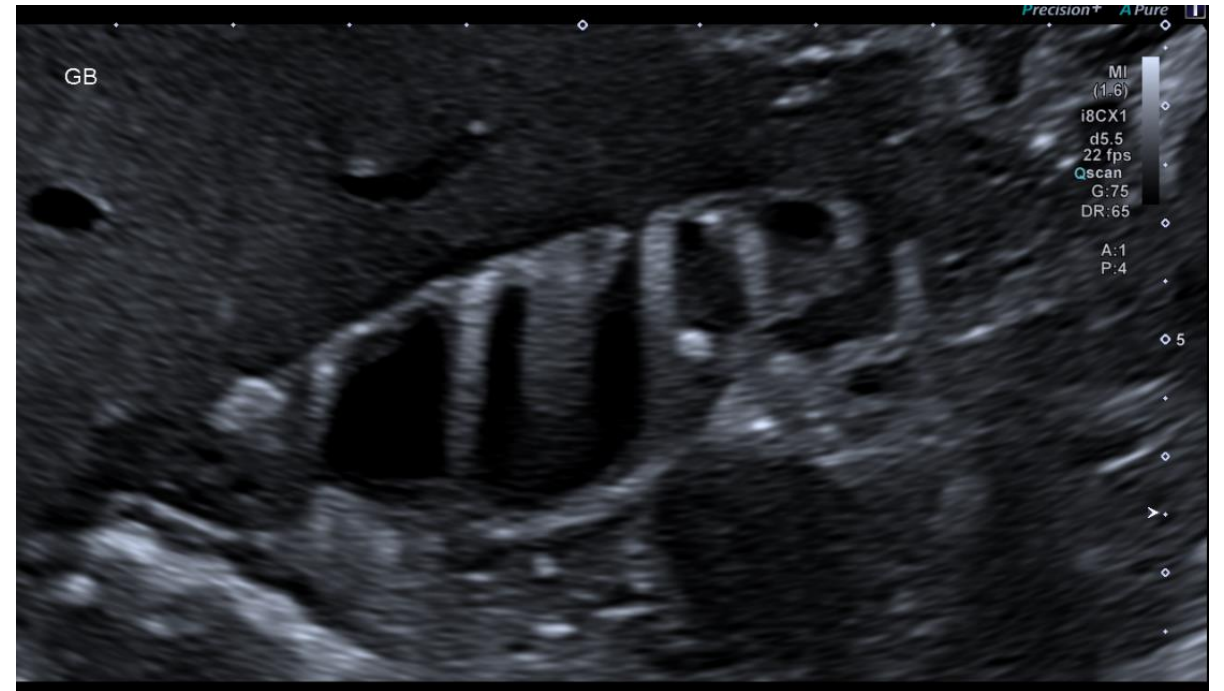57 y/o male. Low grade RUQ pain. Weight loss, ? cause ? gallstones

Gallbladder





Gallbladder



Do not progress to next slide until you have attempted to write your own report

## US Report:

The gallbladder wall is irregular, thickened and contains Rokitansky-Aschoff sinuses. Appearances typical for adenomyomatosis. No gallstones identified.

# Adenomyomatosis Fact File

Benign common condition characterised by hyperplastic changes in the gallbladder wall and pathognomonic epithelial invaginations (Rokitansky-Aschoff sinuses) containing crystal deposits that give rise to small 'comet tail' artefacts.

## **Epidemiology/Incidence:**

Common – found in around 9% of cholecystectomy samples.

## **Risk factors:**

Chronic inflammation, age over 50, 3:1 female dominance ratio.

## **Symptoms:**

Often asymptomatic but may be associated with RUQ pain due to chronic inflammation, especially where there are coexisting gallstones.