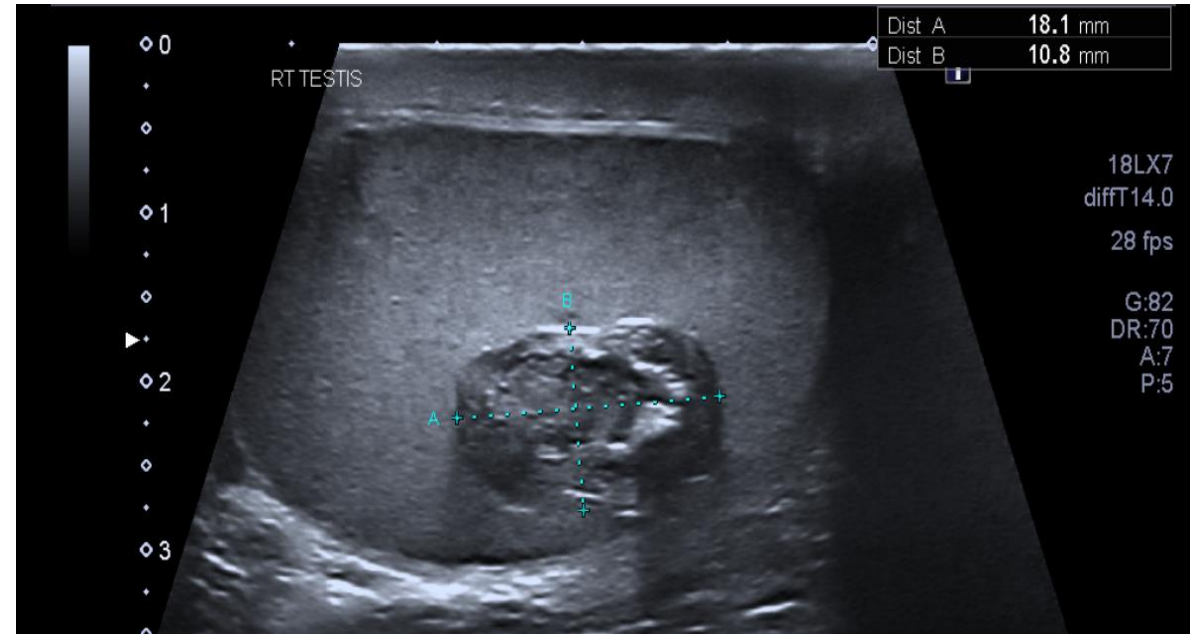
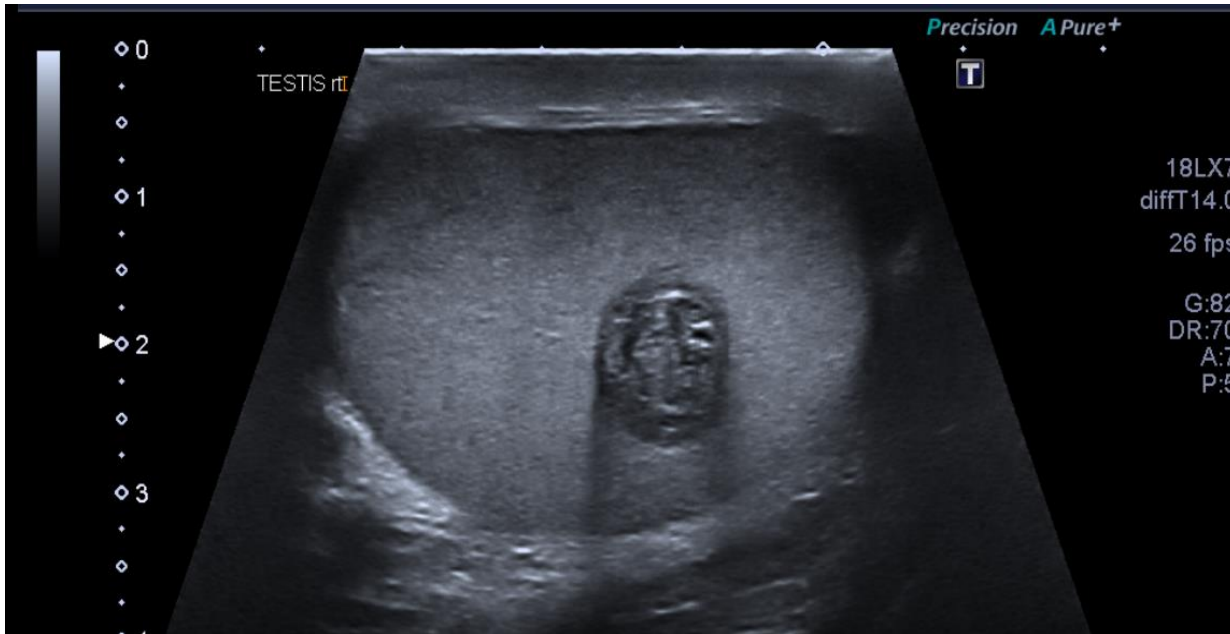
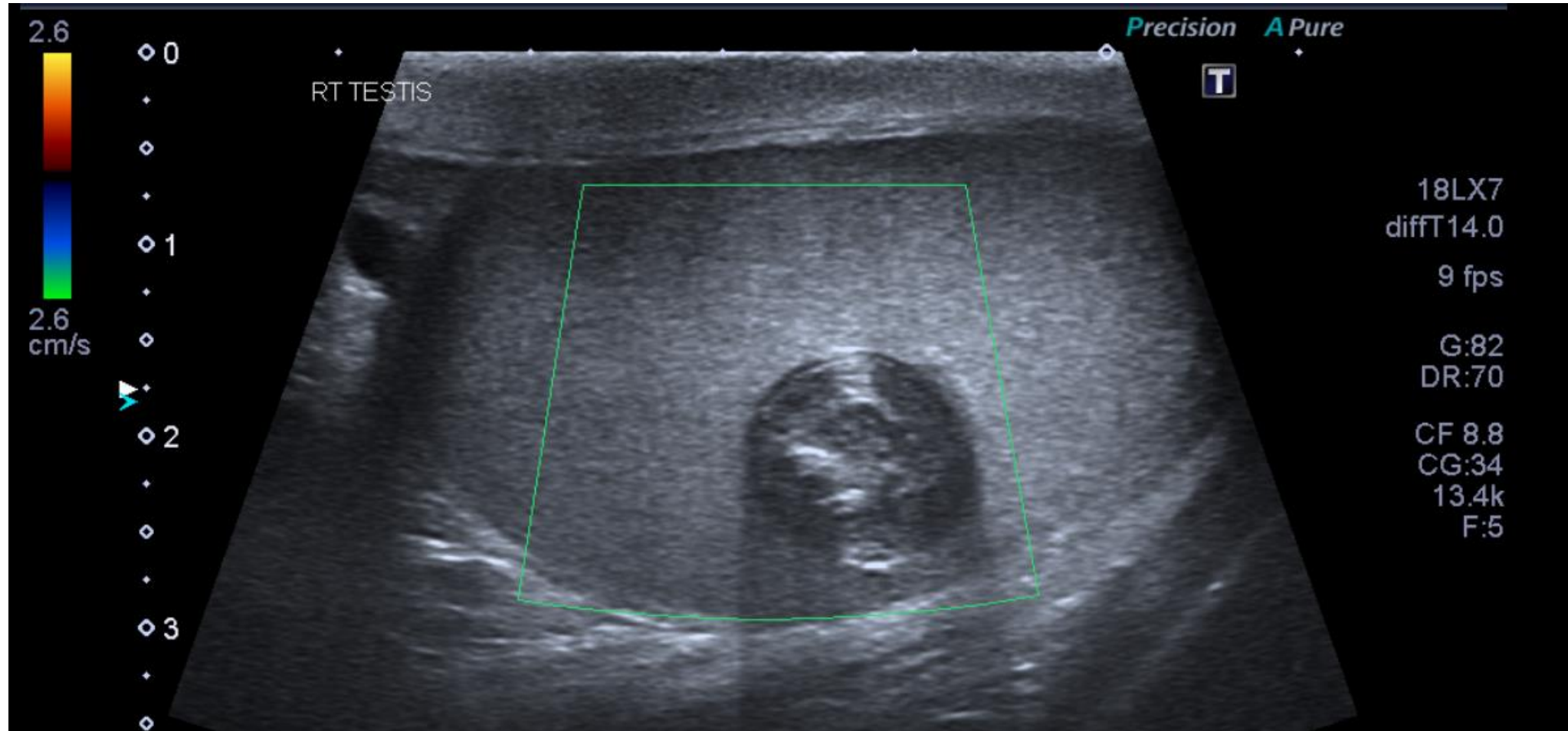
General Medical Case no.8

May 2023

Clinical details: GP request

41 yr old male. New right testicular lump. Painless and thought to be epididymal cyst however increasing in size and patient concerned.





Do not progress to next slide until you have attempted to write your own report

US Report:

Within the right testicle there is an avascular, well-circumscribed lesion, with a lamellated “onion layer” appearance measuring approx 18mm. Appearances are in keeping with an intratesticular epidermoid cyst.

No significant pathology of the right epididymis, left epididymis and left testicle.

Conclusion:

Appearances typical for right epidermoid cyst. Referral to urology is advised.

Epidermoid Cyst Fact File

- Rare benign tumours
- Make up only ~1% of testicular tumours
- May occur at any age but peak in 2nd to 4th decades
- Alpha fetoprotein and beta hCG will be normal where isolated
- Treatment remains controversial: some advocate local excision while others manage conservatively
- Differential diagnosis could be testicular teratoma but this will have abnormal tumour markers