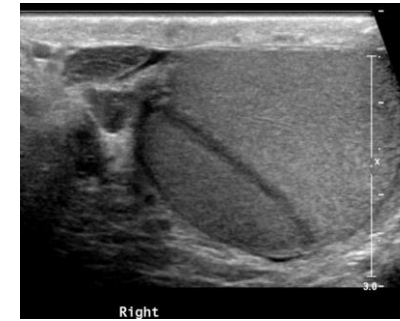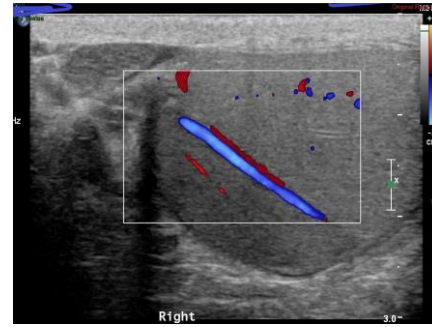
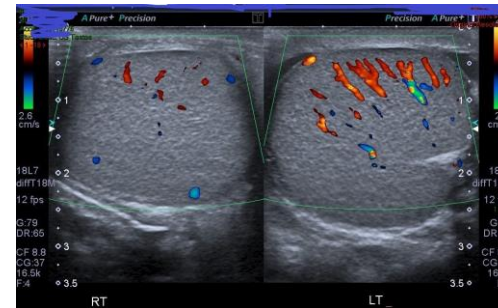


# Answers to March 2021 scenarios:

1. 'Two tone testis' due to a reflection artefact. Avoid mistaking it for infarct.



2. Likely left diffuse orchitis due to the presence of hyperaemia



3. Epidermoid cyst with classic onion layer appearance

