

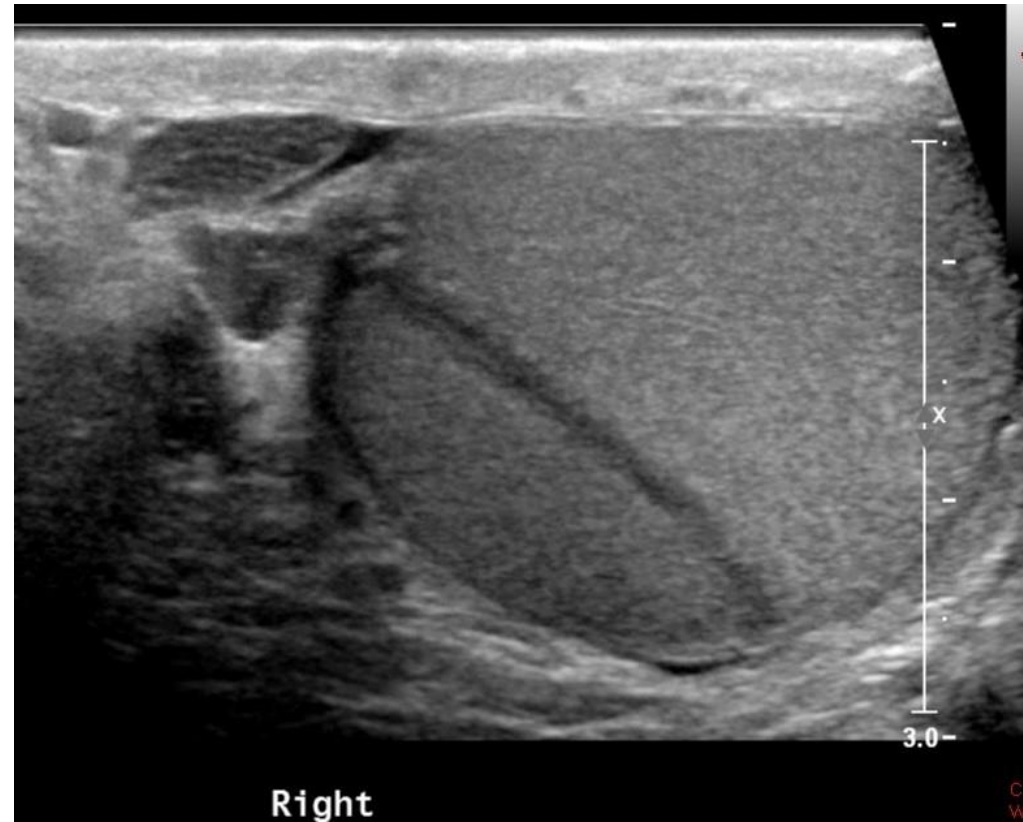General Medical Image Bank

Testicular Ultrasound

March 2021

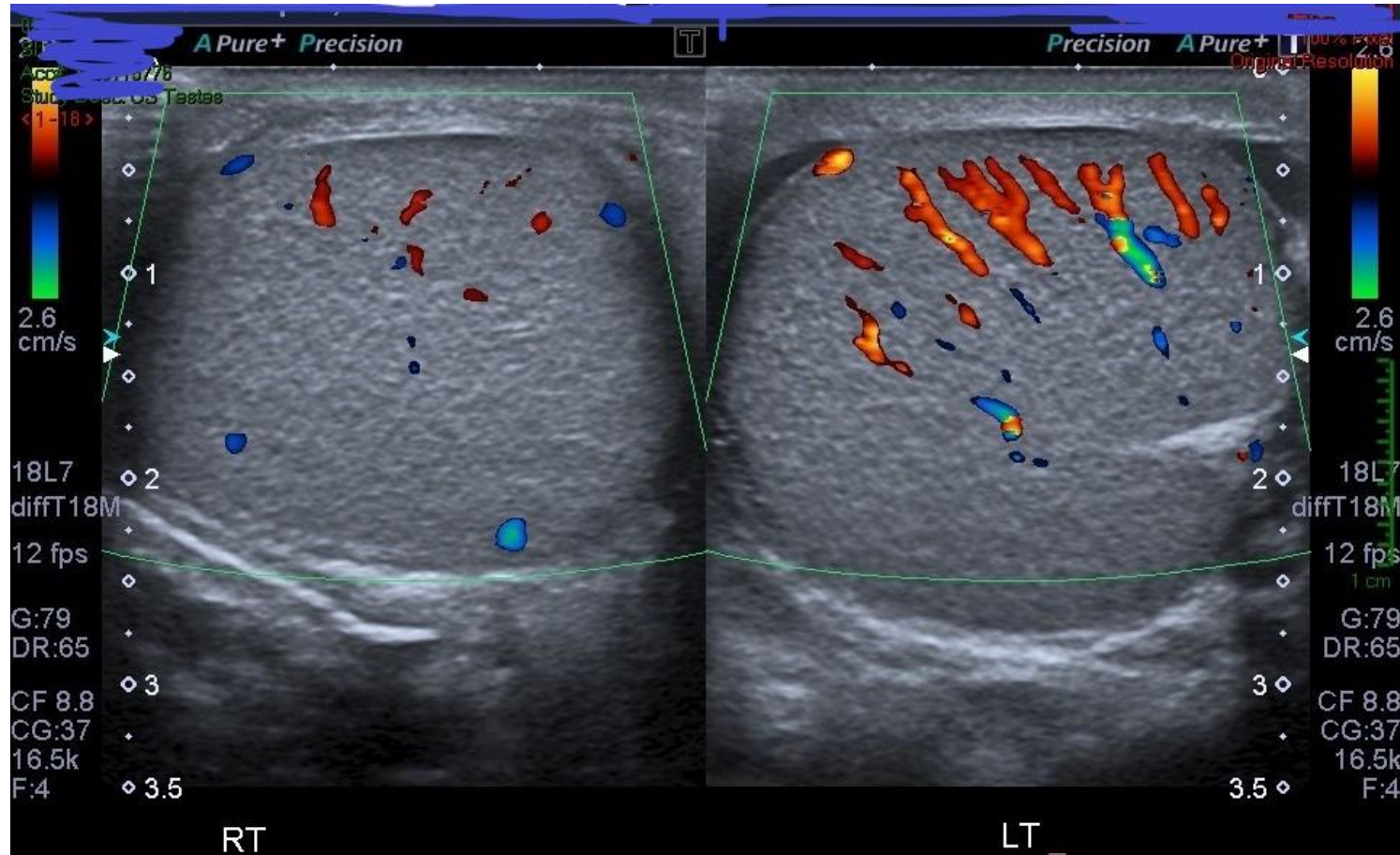
BMUS 1.

What artefact is visible in this normal testis?
What may the artefact be mistaken for?



BMUS))) 2.

What condition is indicated in this 'spectacle image' of a man with left sided pain?



BMUS 3.

The mass in this testis has an 'onion layer' appearance. What type of mass is commonly described as having this pattern?

