BMUS Paediatric Neck Lump Guideline

Introduction and Clinical Background

Neck masses are common in the paediatric population. Congenital lesions such as lymphatic and vascular malformations account for the majority of cases in infants and young children. In older children, enlarged lymph nodes secondary to infection are by far the commonest cause with a prevalence of 45%-57% in otherwise healthy children.[1,2] Malignancy is rare but increases in prevalence throughout adolescence. Rhabdomyosarcoma and neuroblastoma are the commonest tumour types in infants and young children, with haematological malignancy more common in older children. Developmental lesions, such as thyroglossal duct cysts and branchial cleft cysts may present at any age during childhood although are most frequently encountered during the first decade of life.

Evaluation of the likely cause of a neck mass initially requires a careful clinical assessment. The patient's age is critical, particularly in the context of congenital lesions which usually present in infancy or childhood.[3] Correlating age and clinical history with the examination findings will allow the differential diagnosis to be narrowed, and in many cases, the diagnosis can be reached with this alone. Imaging, serology and/or biopsy should therefore be reserved for selected cases only.

Differential Diagnosis

The site and location of the lump help narrow down the likely cause. In infancy, a congenital lesion is the most likely aetiology. Midline lesions are more likely to be thyroglossal duct cysts, dermoid cysts or ranulas. Off-midline lesions may be branchial cleft cysts or lymphangiomas.[4] In children, reactive lymphadenopathy is the commonest cause of neck lumps. Benign reactive lymph nodes are commonly bilateral and found in the anterior cervical, jugulodigastric, submandibular, and to a lesser extent, the posterior cervical regions. Supraclavicular lymph nodes, and to a lesser extent, pre-auricular lymph nodes are less typical sites for 'reactive' lymph nodes.[1] Malignancy is rare at all ages.

Indication for Ultrasound Referral

Cervical Lymphadenopathy:

No specific size criteria has been described for cervical lymphadenopathy in children, and in general, the same size criterion described in adults are applied to children. Level II lymph nodes in the neck with a maximum diameter of 1.5 cm are considered to be within normal limits.[5] The Children's Cancer and Leukaemia Group (CCLG) suggests that nodes < 2cm may be watched but larger nodes when present for > 6 weeks should be referred for further assessment. [6] Ultrasound can be useful to determine the nature of the lump, for example to differentiate a lymph node from a developmental cyst, confirm the presence of a solid mass, and help direct further investigation and management.

Cervical Lymphadenitis:

Lymphadenitis is characterised by larger lymph nodes which are often tender and frequently associated with fever, warmth and erythema of the overlying skin. Ultrasound adds little to clinical examination in the majority of cases, but can be helpful if there are clinical signs to suggest abscess formation and to assess suitability for drainage.

Congenital lesions or developmental lesions:

This includes suspected branchial cleft cysts, thyroglossal duct cysts, haemangiomas and cystic hygromas. Ultrasound is the first-line imaging modality of choice to confirm the nature of the abnormality and aid in directing further management. These patients will also require appropriate secondary care referral.

Other 'focal' neck lesions:

Neck lumps such as sternocleidomastoid pseudotumours, ranulas, dermoid cysts, thyroid nodules and queried cases of malignancy should also be assessed with ultrasound in the first instance. Depending on the nature of the lump, these patients will also require secondary care referral.
Be aware of ectopic thymic tissue which may occasionally present as a neck lump. Ectopic thymus can occur anywhere along the path of descent of the thymopharyngeal duct (a structure connecting the thymus and embryonic pharynx) and displays the same ultrasound characteristics as normal thymus – hypoechoic with echogenic foci or strands giving a 'starry-sky appearance'.

Summary: Indications for Ultrasound

- A focal neck mass persistently enlarged > 2 cm for > 6 weeks.
- A midline neck mass.
- A palpable neck mass in infants under 6 months of age.
- Suspected congenital or developmental neck lesions – to characterise and direct further management following paediatric or ENT referral.
- Acute lymphadenitis which fails to respond to medical therapy – to assess for abscess formation and the need for further intervention.

Scan Timing / Urgency & Follow-Up

The timing of the ultrasound scan ultimately depends on the level of clinical concern. Many palpable neck lumps will have been present for weeks or months, and it would therefore be appropriate to scan these routinely within 6 weeks.

However, there may be indications for performing ultrasound more acutely such as:

- Rapidly enlarging neck masses
- Suspected malignancy
- Cervical lymphadenitis with the suspicion for abscess formation requiring drainage

Small, morphologically normal lymph nodes may persist and remain palpable for many months due to a lack of subcutaneous fat and relative size of the neck.[1] These should be followed up clinically. Enlarged and/or morphologically abnormal lymph nodes, developmental lesions, congenital lesions and the miscellaneous lesions previously described should be referred to secondary care with further follow-up imaging determined following appropriate clinical assessment. If there is a genuine clinical concern for malignancy, patients should be urgently referred to paediatric haematology / oncology for further assessment and work-up.[1,7]

Ultrasound – Not Recommended

Well, healthy children with small palpable cervical lymph nodes do not require routine investigation with ultrasound.[5,8,9] Whilst useful to determine the nature of a lump, ultrasound cannot reliably differentiate between reactive and malignant lymph nodes and should not be used as a screening tool to 'exclude malignancy'.[1] There is no single sonographic criterion that is able to determine the aetiology of an enlarged lymph node given that there are several overlapping sonographic features between benign, malignant and infectious cervical lymph nodes.[2] This emphasises the importance of a thorough clinical history and examination in order to contextualise the neck lump.

Cervical ribs (accessory ribs arising from the seventh cervical vertebrae) may present as a spurious 'mass' in the supraclavicular fossa which is clinically hard and immobile. If a cervical rib is suspected, this can be confirmed with plain radiographs alone.

Scanning Protocol

Neck ultrasound should be performed with a high frequency (10-15MHz) linear array transducer using B-mode and colour Doppler imaging. The patient should be positioned comfortably in a supine position with their neck hyperextended over a pillow. The use of warm sonographic gel is also favourable and may improve patient cooperation.

A targeted scan of the neck lump should first be performed acquiring images in transverse and longitudinal planes, and associated vascularity should be evaluated with colour Doppler imaging. Scanning anteriorly in the midline of the neck enables assessment of the thyroid gland, which includes assessing both lobes and the isthmus. The submandibular glands are imaged by placing the transducer along and posterior to the mandibular body and the parotid glands are assessed by scanning anterior to the ear. Scanning along the anterior and posterior cervical chains with the sternocleidomastoid muscle as the anatomical landmark between the two will allow identification of enlarged and/or morphologically abnormal lymph nodes.

Scan Assessment

The neck should be scanned in a systematic manner. The following should be assessed:

- *Neck lump(s):* Location, morphology, size, vascularity, attachment or relationship to other structures.
- *Thyroid gland*: Location, echogenicity, size, vascularity, presence of nodules or cysts.
- *Submandibular glands*: Echogenicity and echotexture, size, ductal dilatation or calculi.
- *Parotid glands:* Echogenicity and echotexture, size, ductal dilatation or calculi. Small intra-parotid lymph nodes may often be seen.
- *Lymph nodes:* Location (anterior / posterior triangle or neck level), size (measured in short axis), morphology including presence or absence of the normal fatty hilum, shape, calcification and vascularity.

Standard Images

In addition to scanning the focal neck lump (in two planes with measurements) and colour Doppler, the following shows an example of recommended images to be acquired:

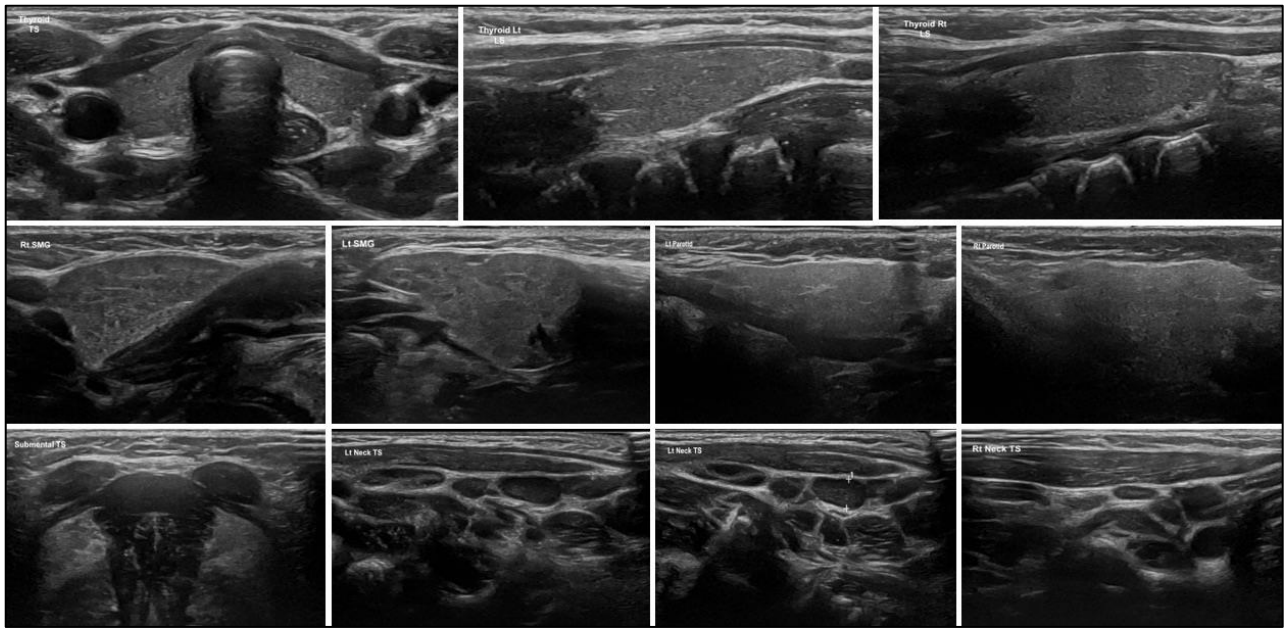

Take Home Points

Ultrasound is the first line imaging modality and has a high sensitivity with 'typical' imaging findings supported by 'typical' clinical findings. It helps to characterise neck lesions and directs further imaging. Cross-sectional imaging is performed when further characterisation of a neck lump is required following an indeterminate ultrasound, in cases of suspected deep neck space infection and for surgical planning. Depending on clinical assessment and/or ultrasound findings, patients may warrant referral to secondary care, such as endocrine, oncology / haematology or ENT specialists.

References

1. Ruffle A, Beattie G, Prasai A, *et al*. Fifteen-minute consultation: A structured approach to the child with palpable cervical lymph nodes. Arch Dis Child Educ Pract Ed. 2022;0:1-4.
2. Paddock M, Ruffle A, Beattie G, *et al*. Do otherwise well, healthy children with palpable cervical lymph nodes require investigation with neck ultrasound? Arch Dis Child. 2020;105:1012-6.
3. Meuwly JY, Lepori D, Theumann N, *et al*. Multimodality imaging evaluation of the paediatric neck: techniques and spectrum of findings. Radiographics. 2005;25:931-48.
4. Littooij A, Ravesloot C, Beek E. The Radiology Assistant: Neck masses in children [Internet]. 2016. Available from: https://radiologyassistant.nl/head-neck/neck-masses/neck-masses-in-children
5. Spijkers S, Littooij AS, Nievelstein RAJ. Measurements of cervical lymph nodes in children on computed tomography. Paediatr Radiol. 2022;50:534-42.
6. Children's Cancer and Leukaemia Group. Findings that may be associated with a cancer diagnosis in childhood. 2021. www.cclg.org.uk/guidelines
7. Murray MJ, Ruffle A, Lowis S*, et al.* Delphi method to identify expert opinion to support children's cancer referral guidelines. Arch Dis Child. 2020;105:241-6.
8. Yaris N, Cakir M, Sozen E, *et al*. Analysis of Children with Peripheral Lymphadenopathy. Clin Paediatr (Phila). 2006;45:44-9.
9. Leung AKC and Robson WLM. Childhood cervical lymphadenopathy. J Paediatr Health Care. 2004;18:3-7.