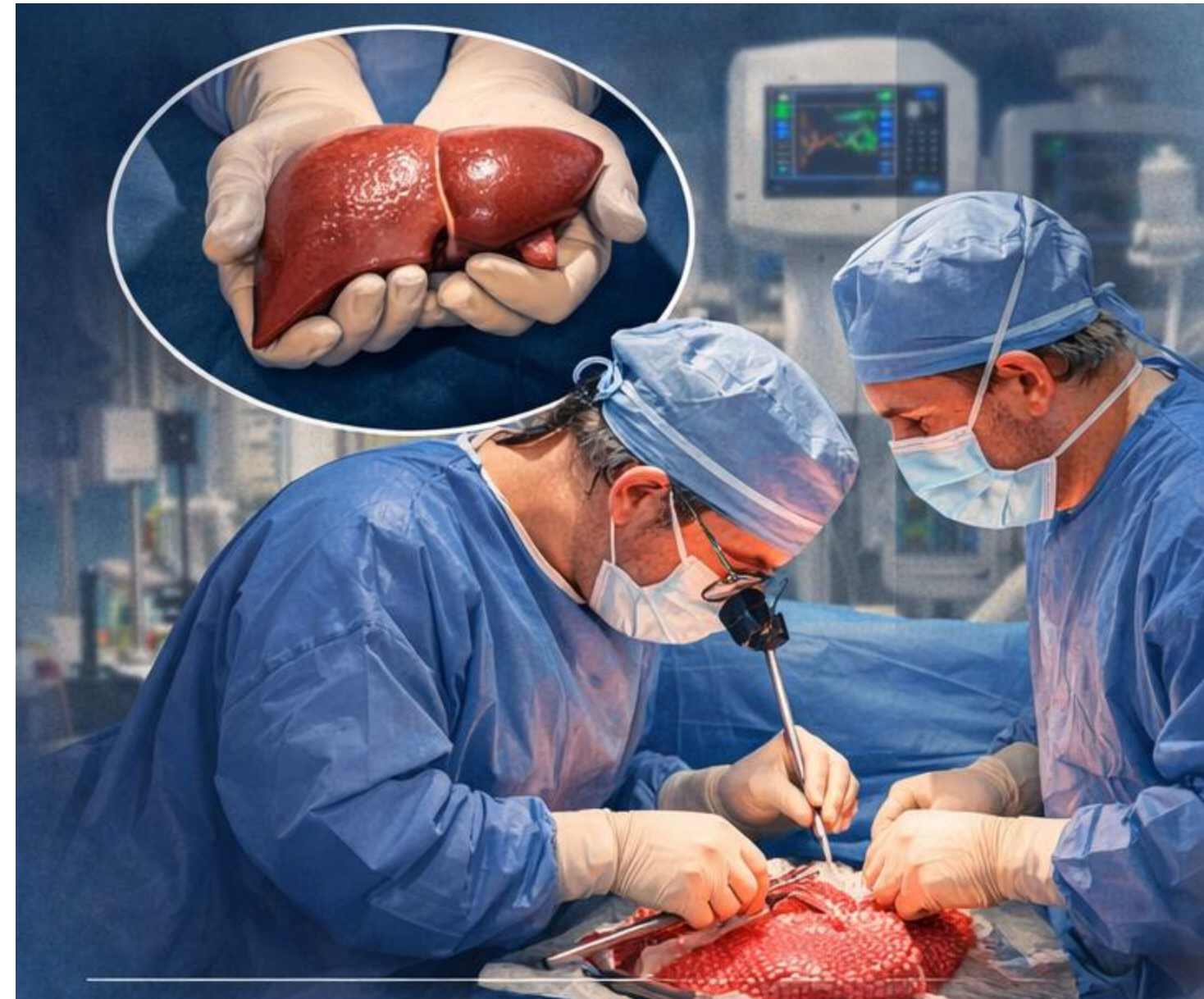

BMUS)))

Vascular liver disease

Presented by: Annalisa Berzigotti
Department for Visceral Surgery and
Medicine, Inselspital, Bern University
Hospital, University of Bern
Switzerland



US in Vascular liver diseases

Budd-Chiari syndrome

Portal vein thrombosis

Congenital vascular malformations


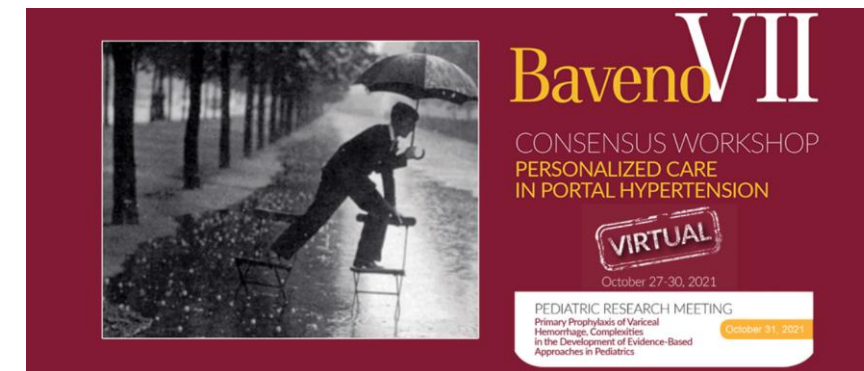
Porto-sinusoidal vascular disorder (PSVD)

Hepatic artery diseases (aneurysm, thrombosis)

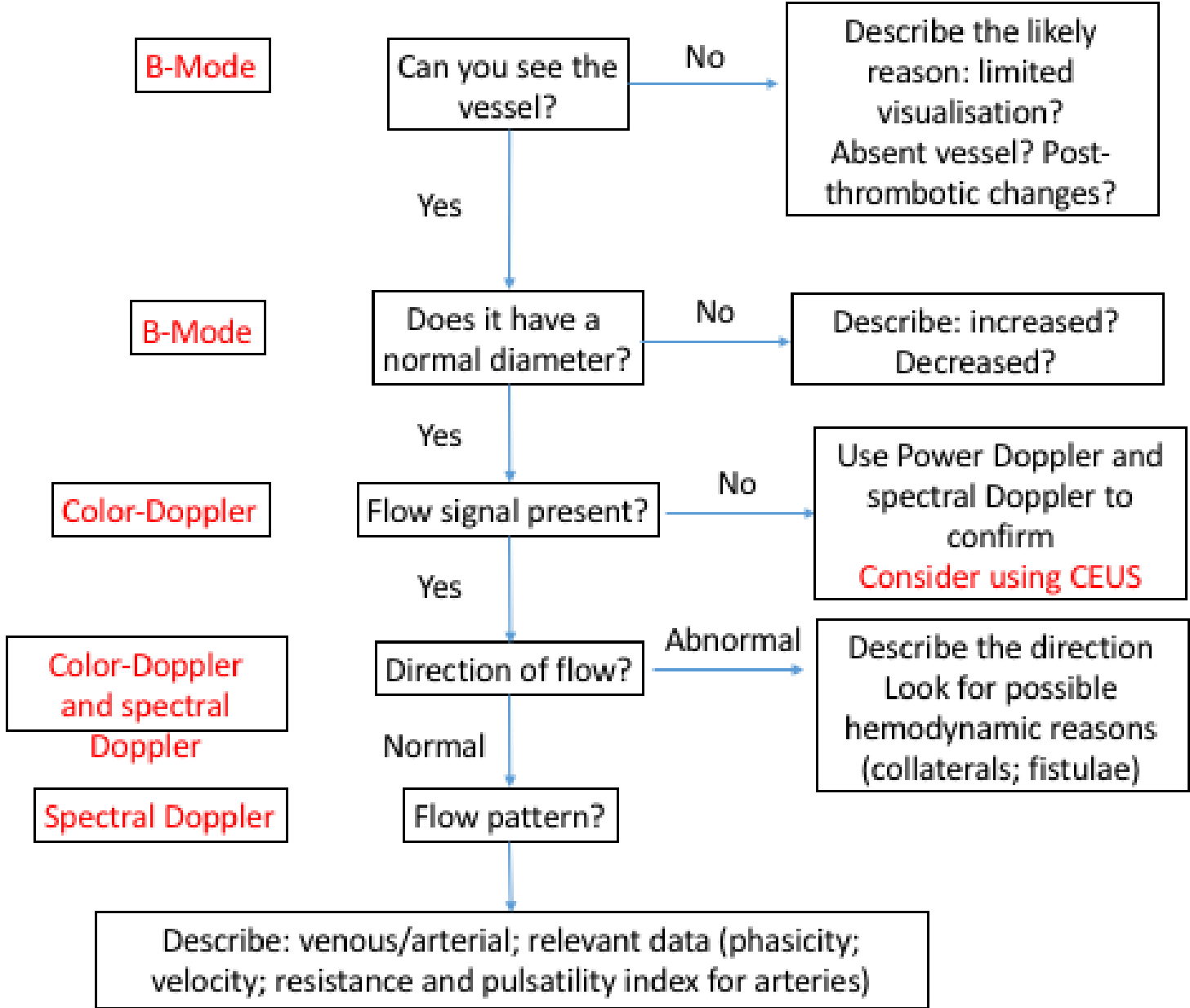
Sinusoidal obstruction syndrome

Radiation-induced liver disease

Peliosis hepatis and sinusoidal dilatation



Systematic US approach to liver vessels



De Gottardi, Berzigotti et al.
Ultraschall Med 2018

US in Vascular liver diseases

Budd-Chiari syndrome

Portal vein thrombosis

Congenital vascular malformations


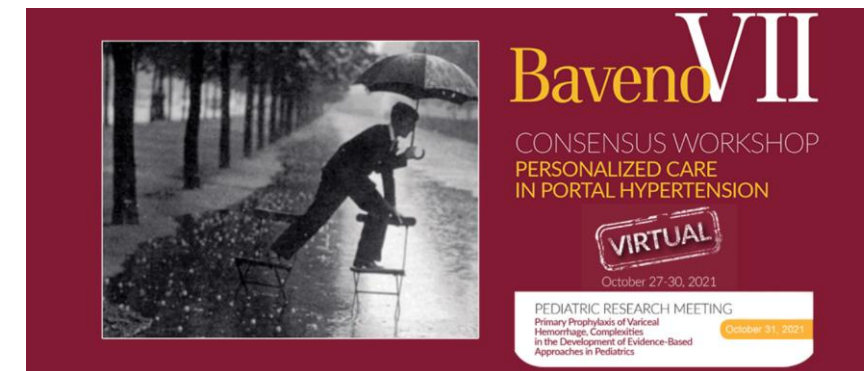
Porto-sinusoidal vascular disorder (PSVD)

Hepatic artery diseases (aneurysm, thrombosis)

Sinusoidal obstruction syndrome

Radiation-induced liver disease

Peliosis hepatis and sinusoidal dilatation



Ultrasound/CDUS is the first line imaging technique
to be used in this setting

High sensitivity (>90%) for thrombosis

Budd-Chiari syndrome

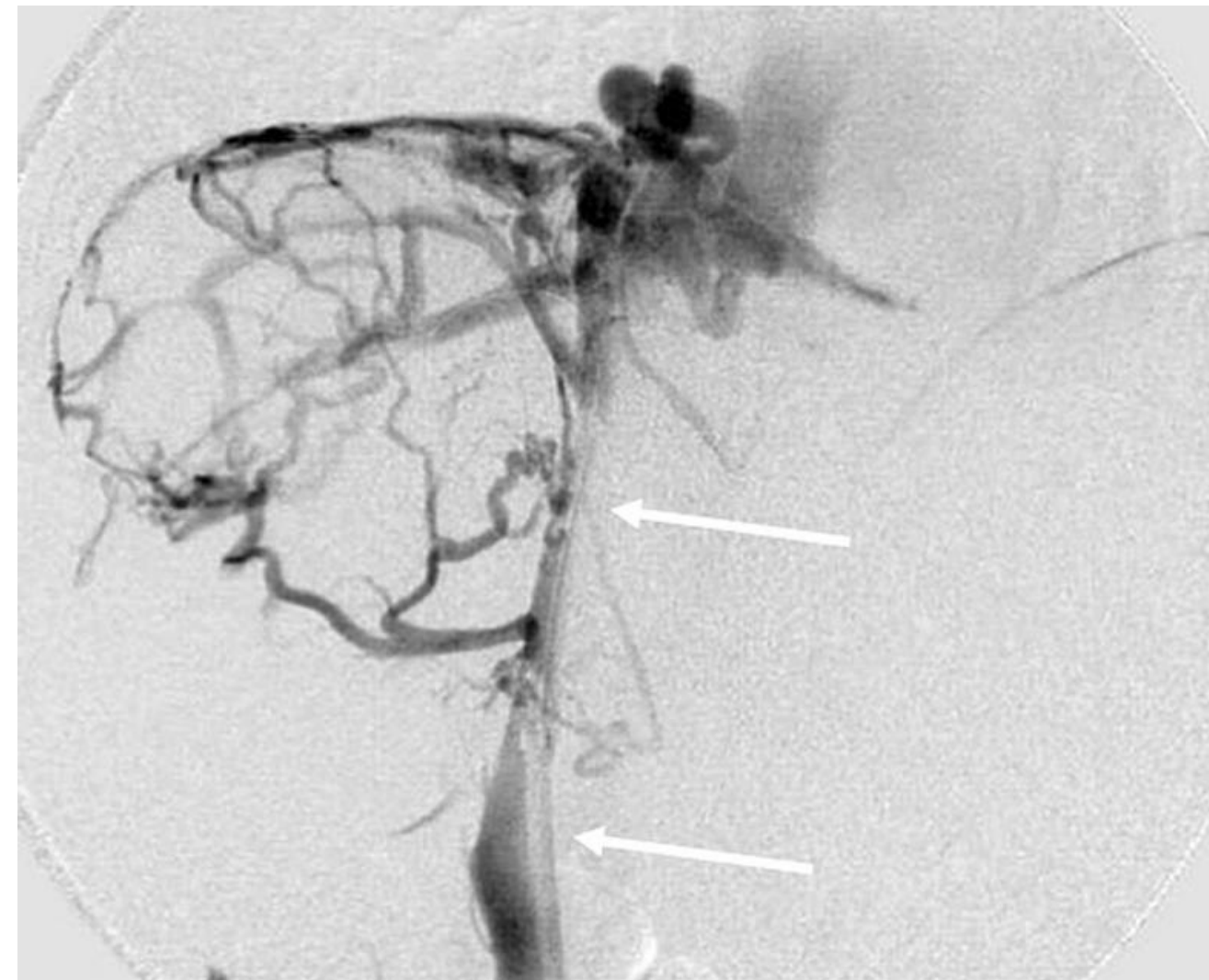
DEFINITION

BCS is defined as the obstruction of hepatic venous outflow regardless of its causative mechanism or level of obstruction

Clinical impact very heterogeneous according to localization and timing.
Hepatic venous web.

EPIDEMIOLOGY

- Incidence 1.5 (0.68-2.17)/million year
- Prevalence 4/million
- F/M=7/3



Potier, Hepato-Gastro, 2018. Van Wettere, Abd Radiol, 2018

Budd-Chiari syndrome

Acute or fulminant forms (7%)

- sudden onset hepatic impairment, ascites, pain, and often kidney failure
- hepatomegaly following obstruction of the three main hepatic veins.

Chronic or subacute forms

- most frequent presentation
- onset of the disease is slower in most patients
- few symptoms
- frequently impaired liver function
- portal hypertension is often present

The clinical diagnosis of BCS is difficult and should be suspected in the presence of:

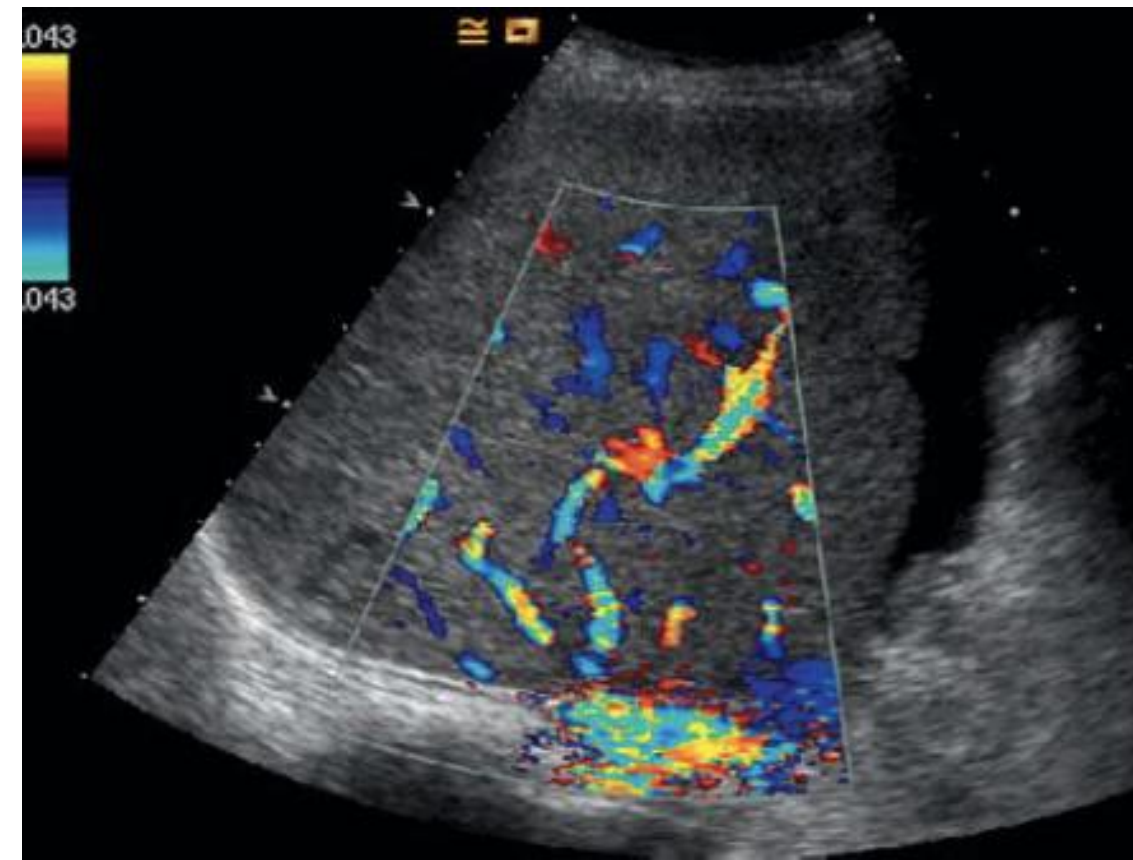
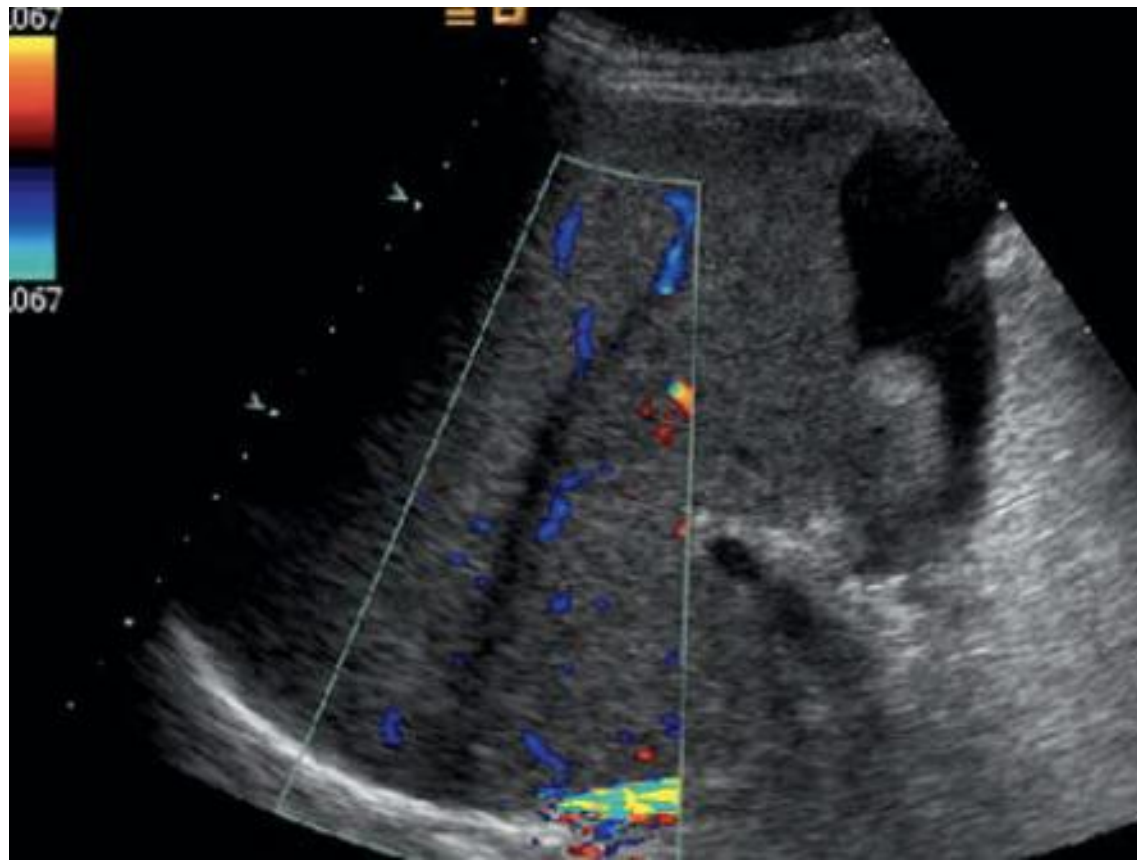
- sudden development of ascites with increased liver volume and upper abdominal pain
- abundant high-protein ascites contrasting with moderately abnormal hepatic tests
- liver disease in a patient with a known thrombogenic condition
- fulminant hepatic failure accompanied by increased liver volume and ascites
- unexplained chronic liver disease

Determinants of thrombotic events

Underlying condition	NCPVT N=432		BCS N=168	
	N tested	% positive	N tested	% positive
Systemic				
Acquired conditions				
Myeloproliferative neoplasms	432	21%	168	41%
JAK2 ^{V617F}	432	16%	168	35%
Antiphospholipid syndrome	429	6%	165	10%
PNH	386	0.3%	152	7%
Inherited conditions				
Factor V Leiden	429	3%	165	8%
Factor II gene mutation	432	6%	168	3%
Protein C deficiency	404	5%	150	5%
Protein S deficiency	407	5%	147	4%
Antithrombin deficiency	416	1%	153	1%
External factors				
Recent pregnancy	353	2%	168	1%
Recent oral contraceptive use	353	14%	168	22%
Systemic disease: connective tissue disease, celiac disease, Behçet's disease, mastocytosis, inflammatory bowel disease, human immunodeficiency virus infection, sarcoidosis	432	3%	168	6%
Local factor				
Inflammatory intra-abdominal lesions	432	11%	168	2%
Intra-abdominal surgery	432	10%	168	1%
Abdominal trauma	292	4%	168	2%
> 1 risk factor	432	14%	168	19%
No cause identified	219	42%	168	24%

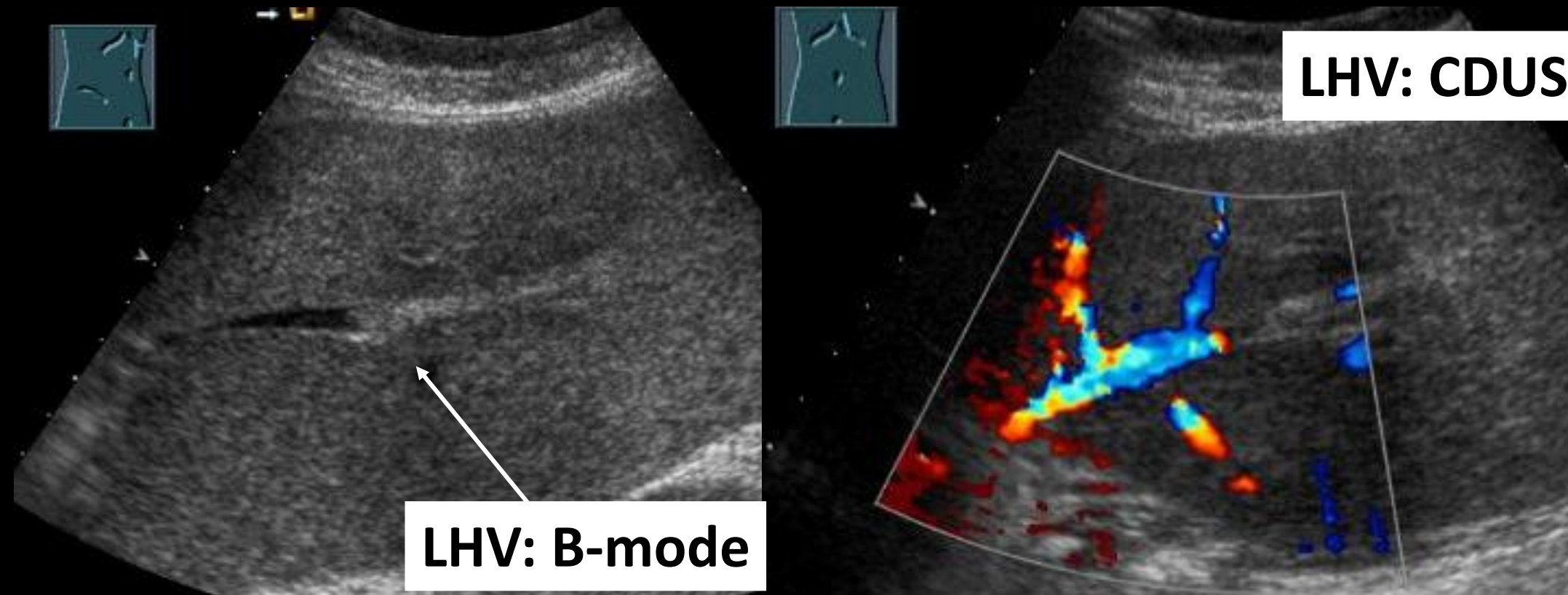
Hernandez-Gea, J Hepatol, submitted

Budd-Chiari syndrome can be diagnosed by ultrasound

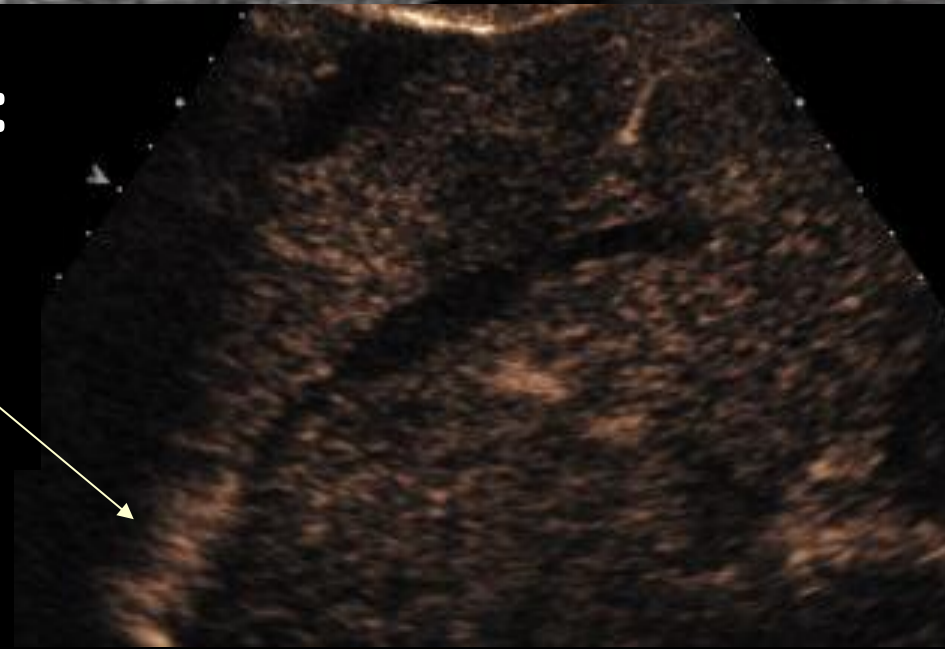


De Gottardi, Berzigotti, Ultraschall in Med, 2018

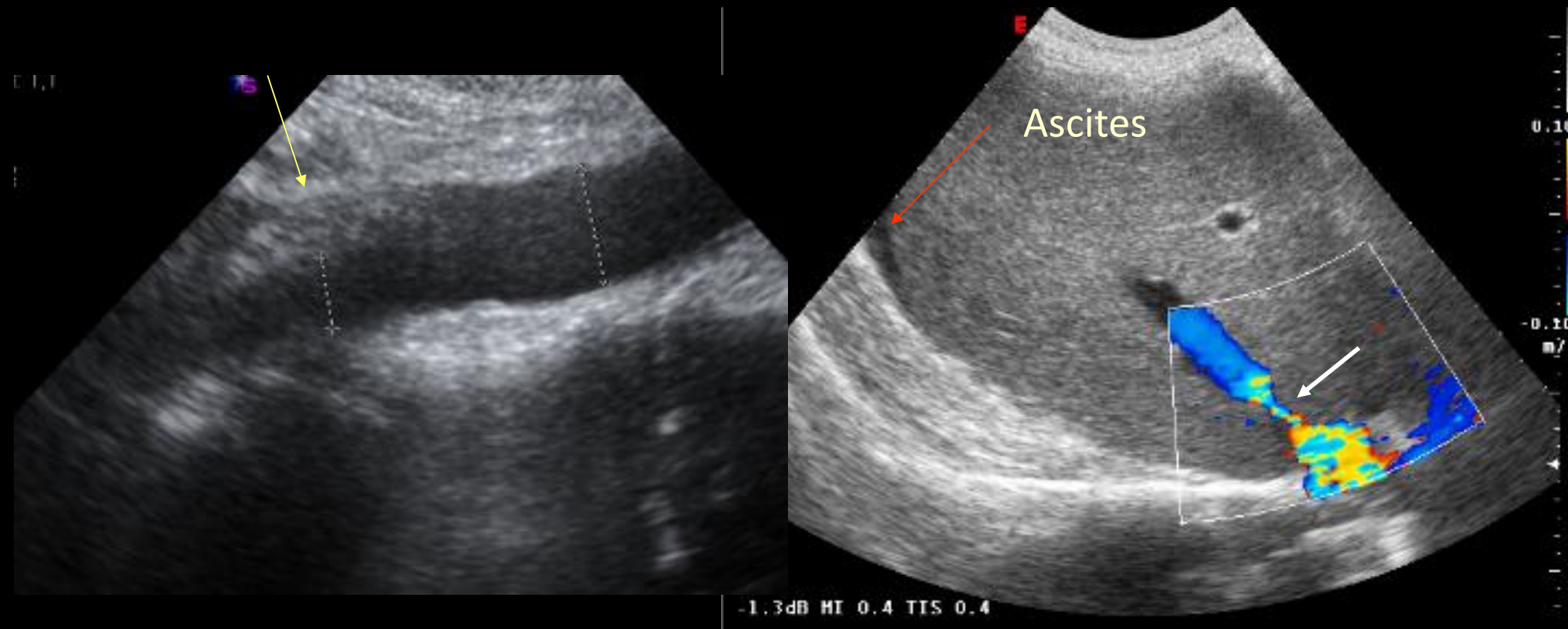
Direct signs of BCS: HV thrombus



CEUS of left HV:
patency of
proximal
tract

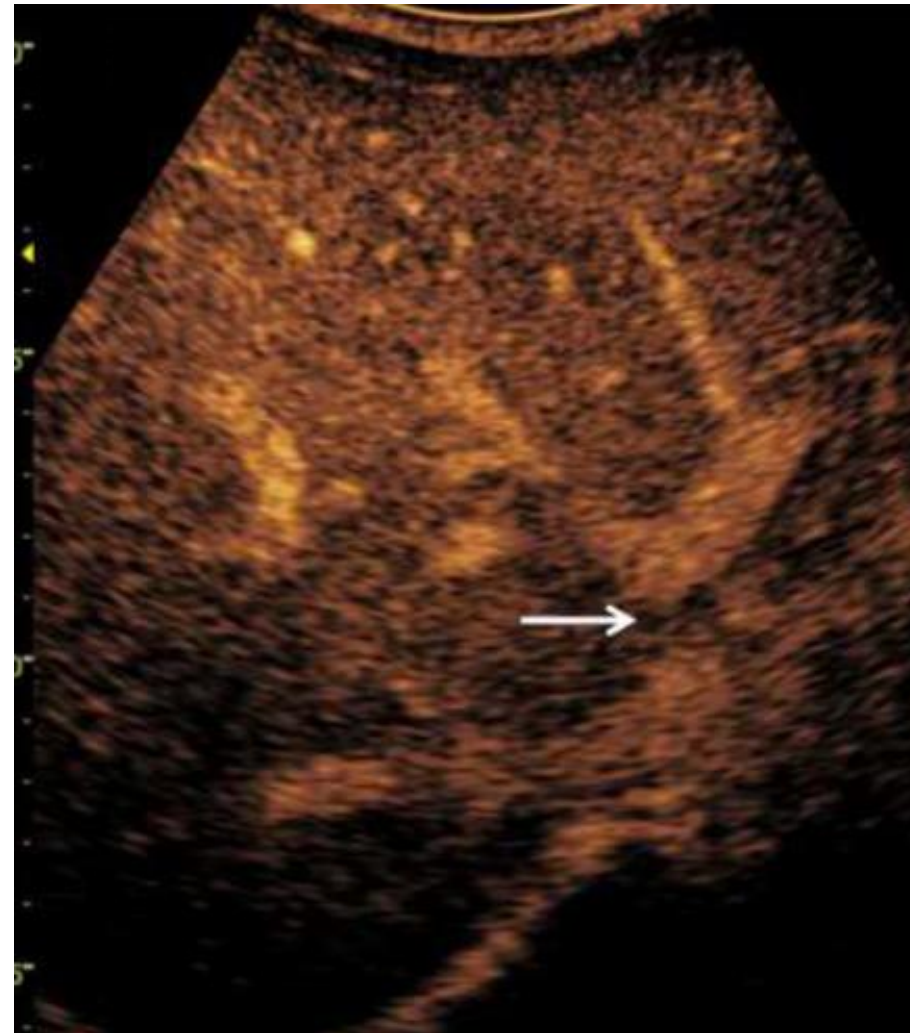

Direct signs of BCS: IVC/hepatic vein system



Thrombosis of IVC

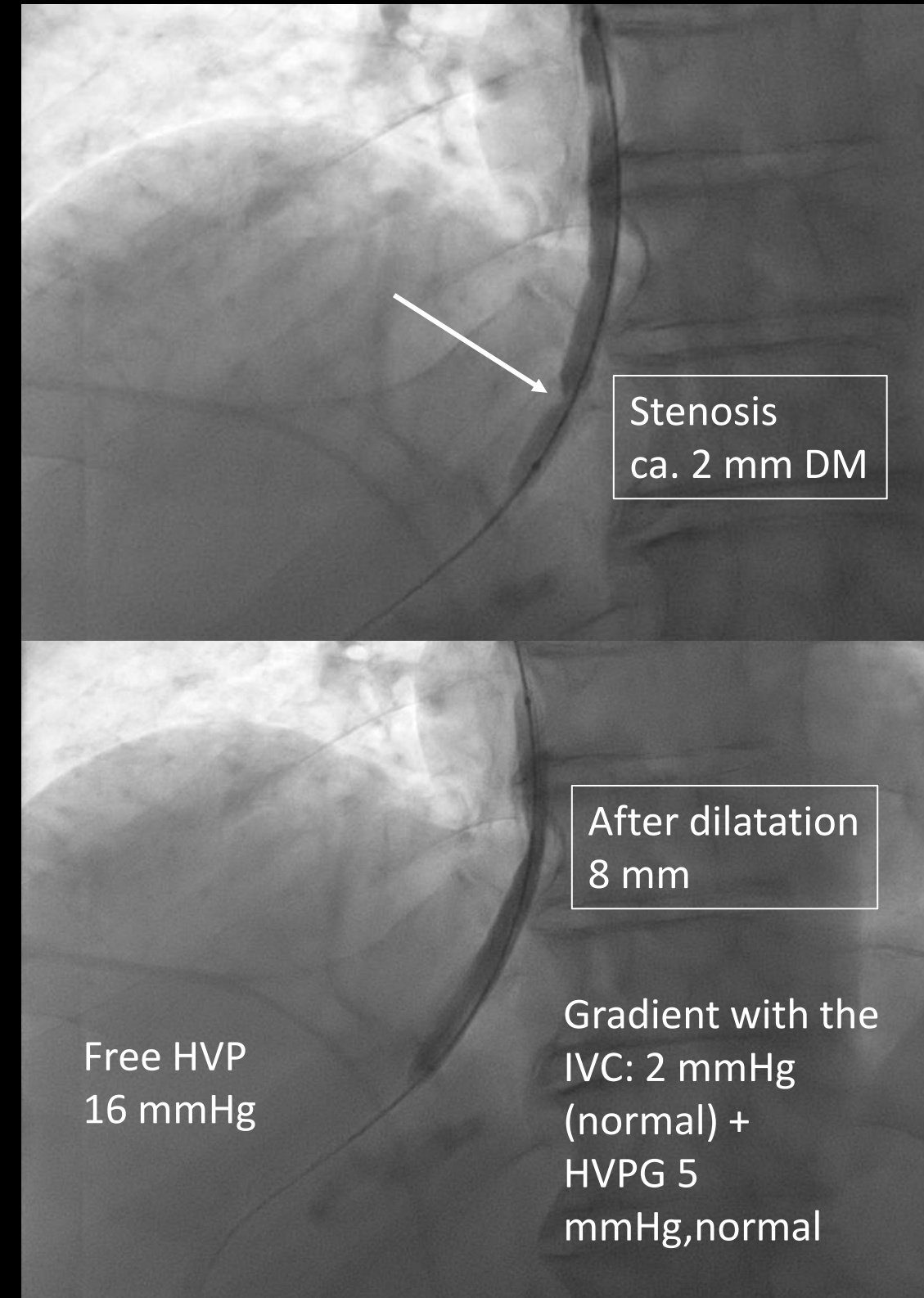
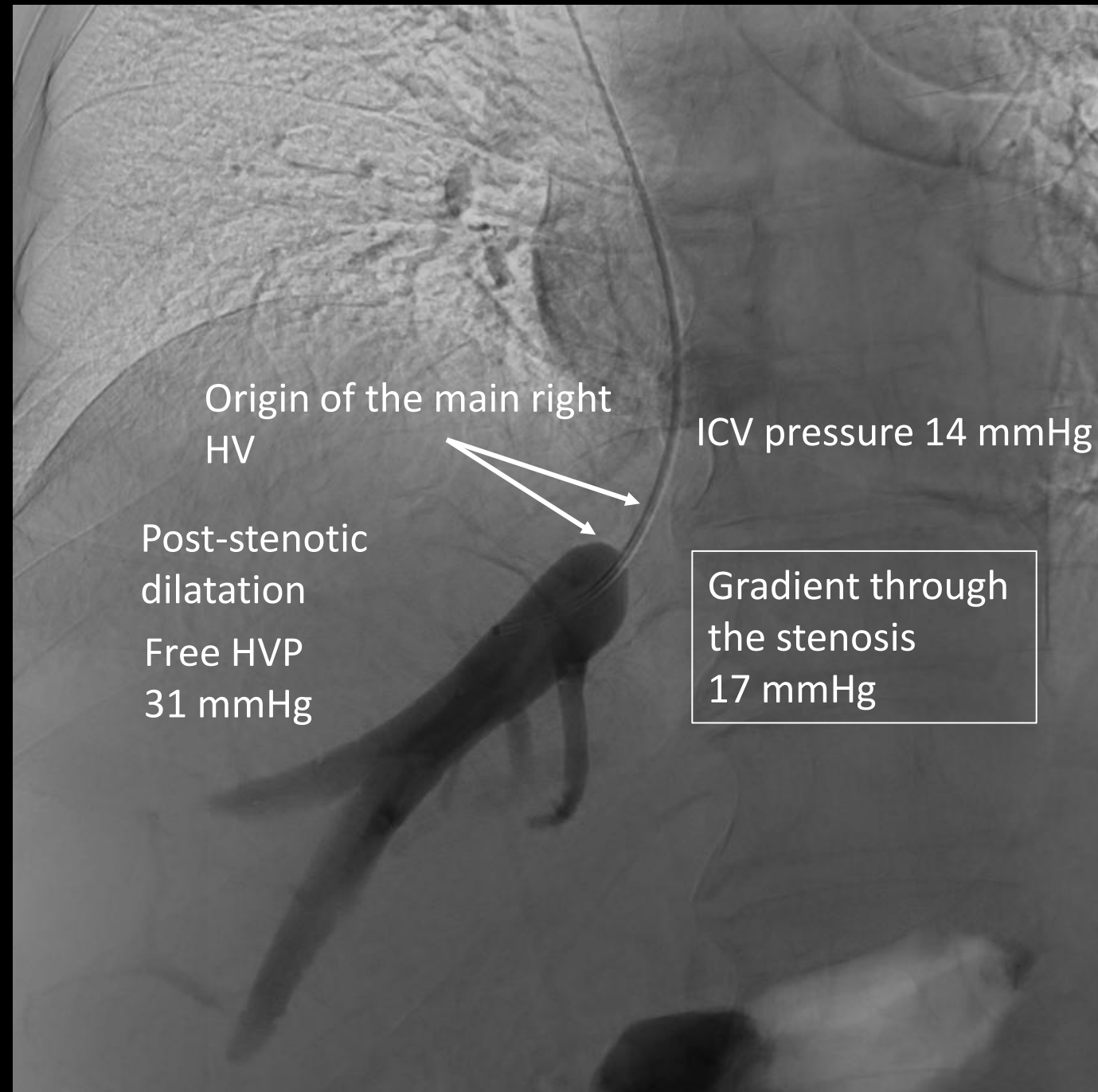
**Short-length stenosis
of the right HV**



«membrane» at the origin
of the liver veins

Almost impossible to detect
without CEUS

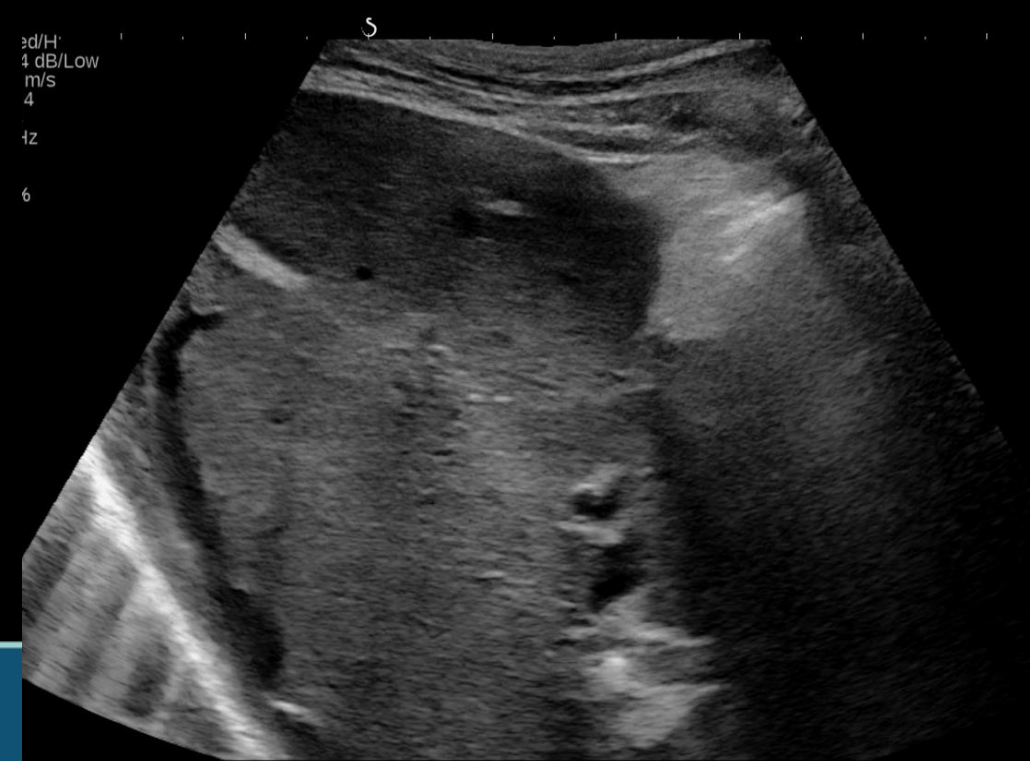
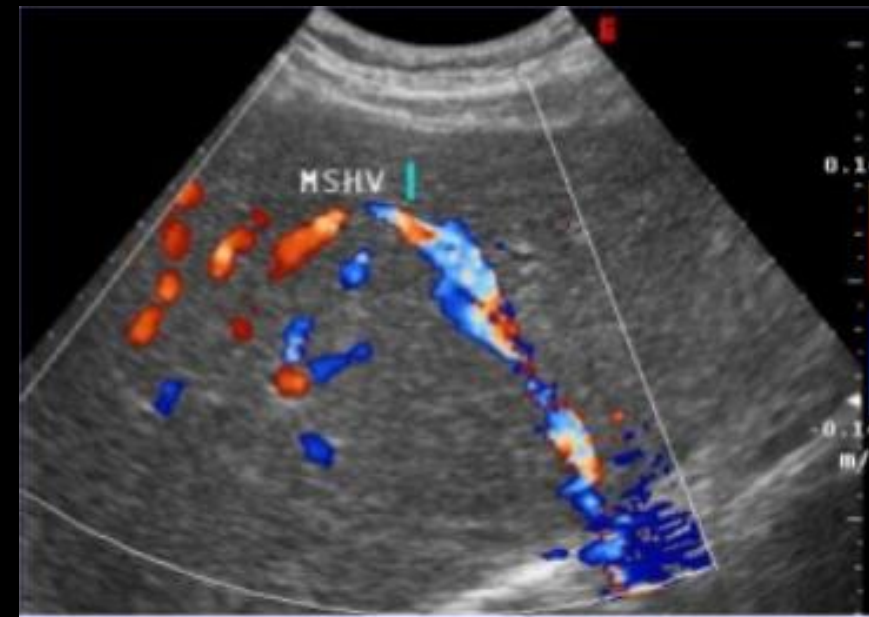
Bansal, Brit J Radiol, 2018



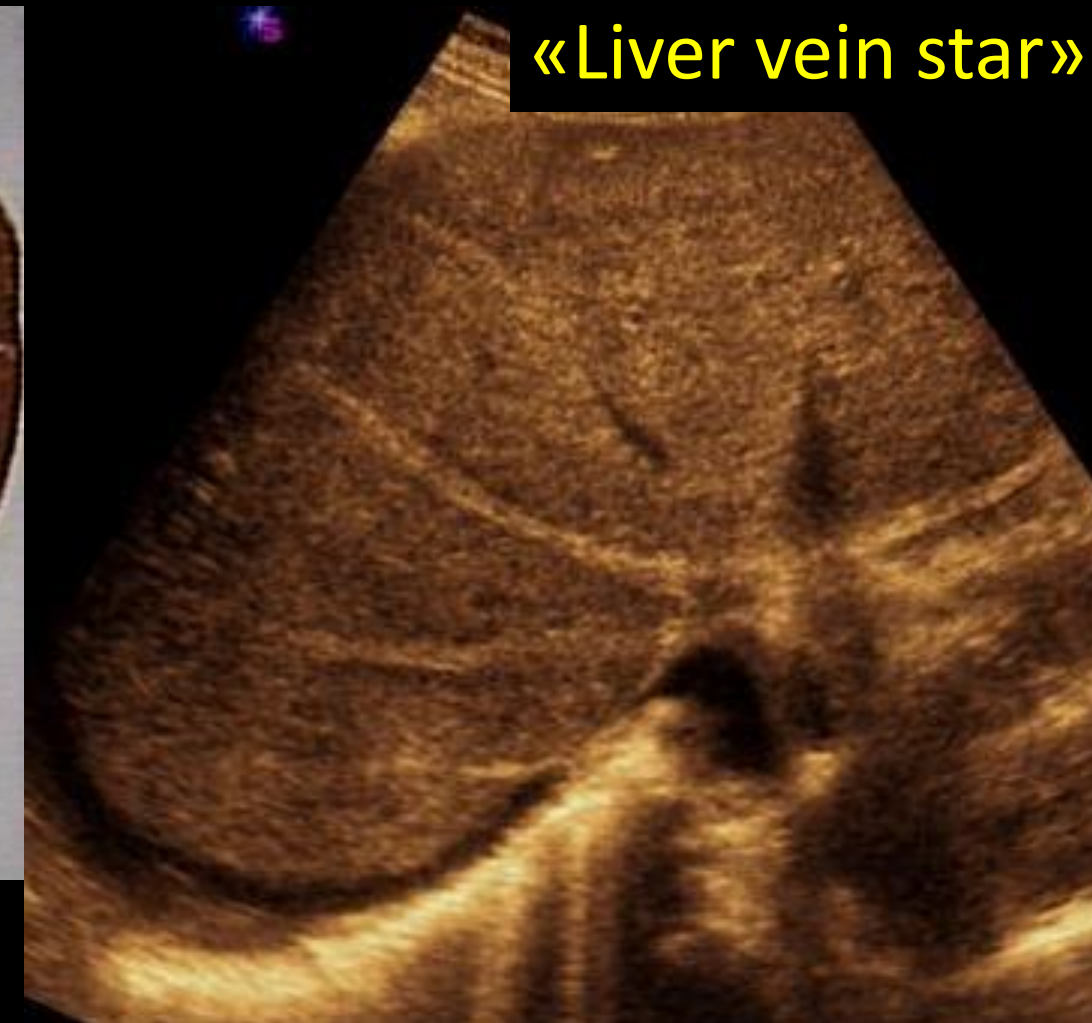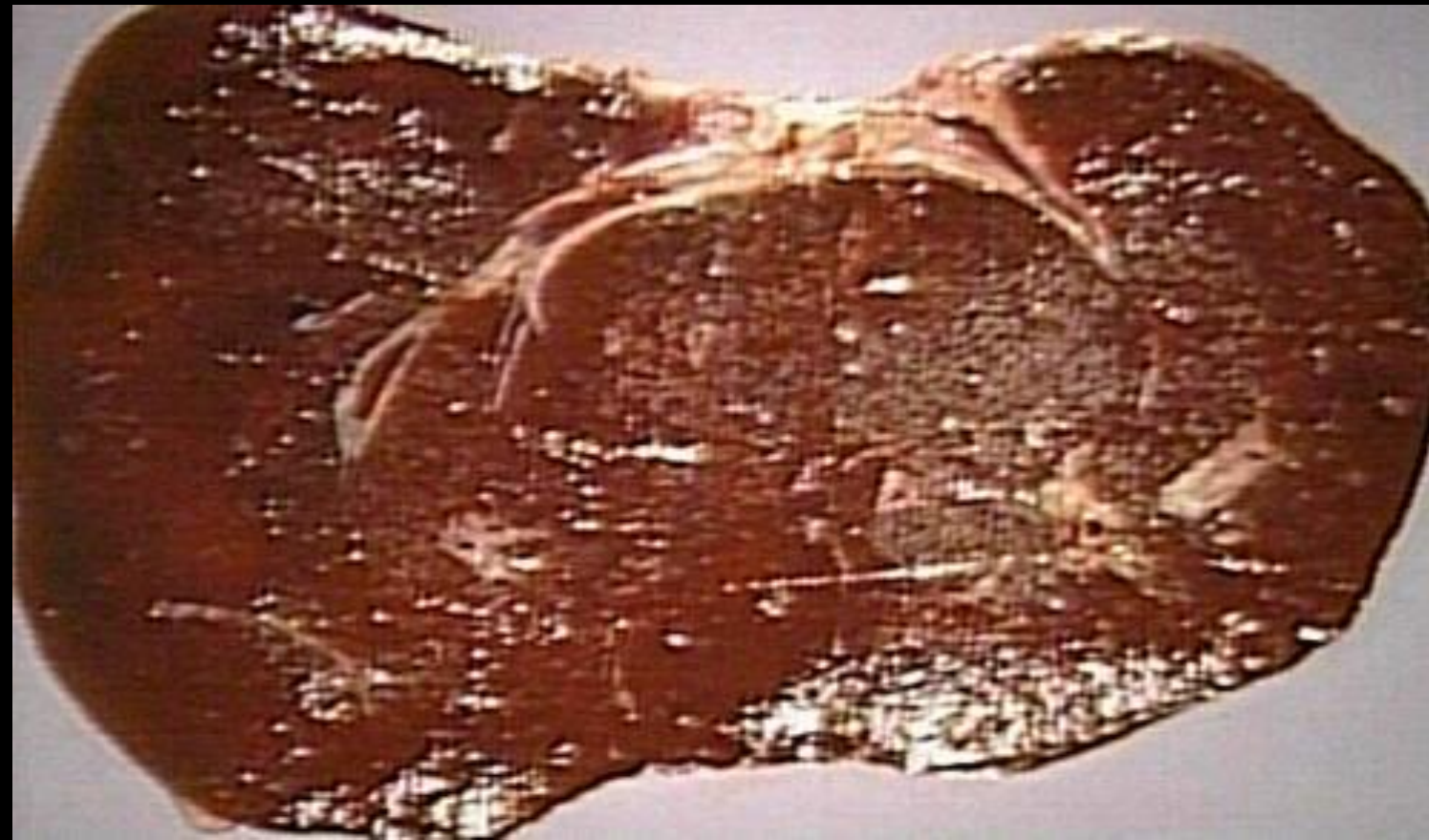
Hepatic veins: indirect signs of BCS

- Reversed flow in one of the HVs or a tract of it
- Large communication between one vein and another one
«Bicolored hepatic vein»
- Large subcapsular veins draining in the IVC (compensatory)

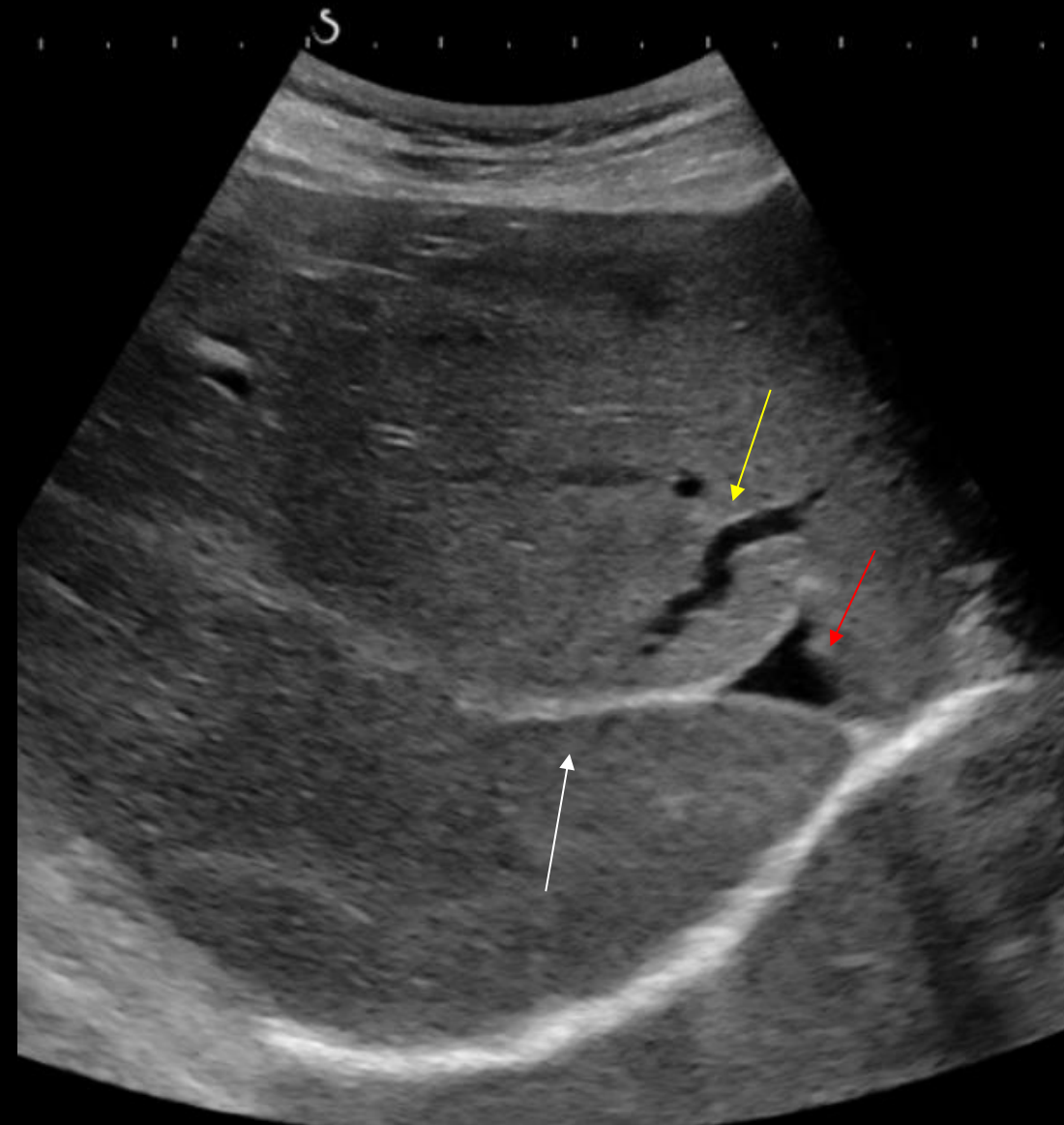
Bargalló X et al. Am J Roent 2006



Chronic BCS: Hyperechoic cords (chronic fibrotic changes)



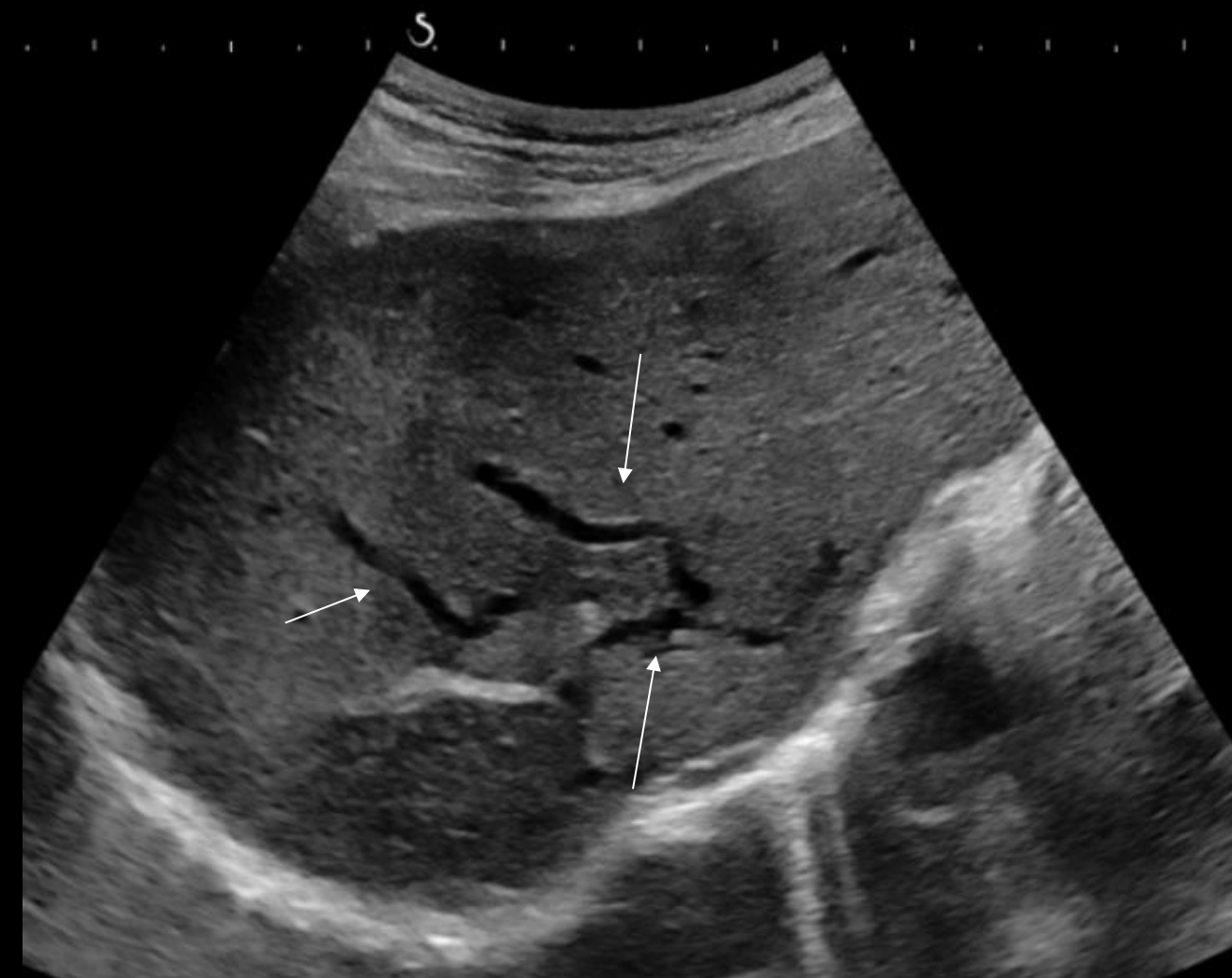Chronic BCS



White arrow: right liver vein substituted by a fibrous cord

Yellow arrow: veno-venous collaterals

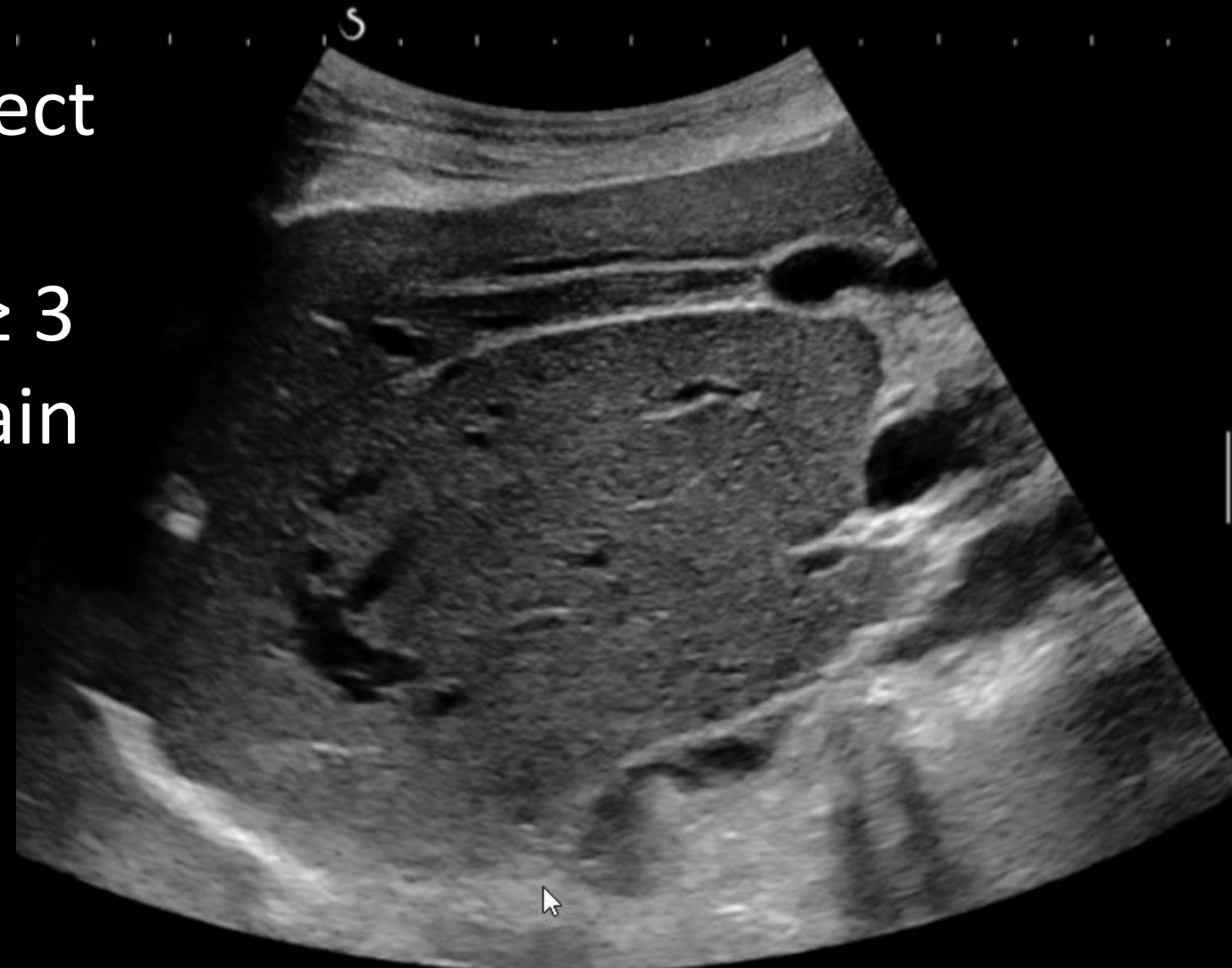
Red arrow: intrahepatic part of the IVC compressed by the liver parenchyma



Veno-venous
collateral
circulation

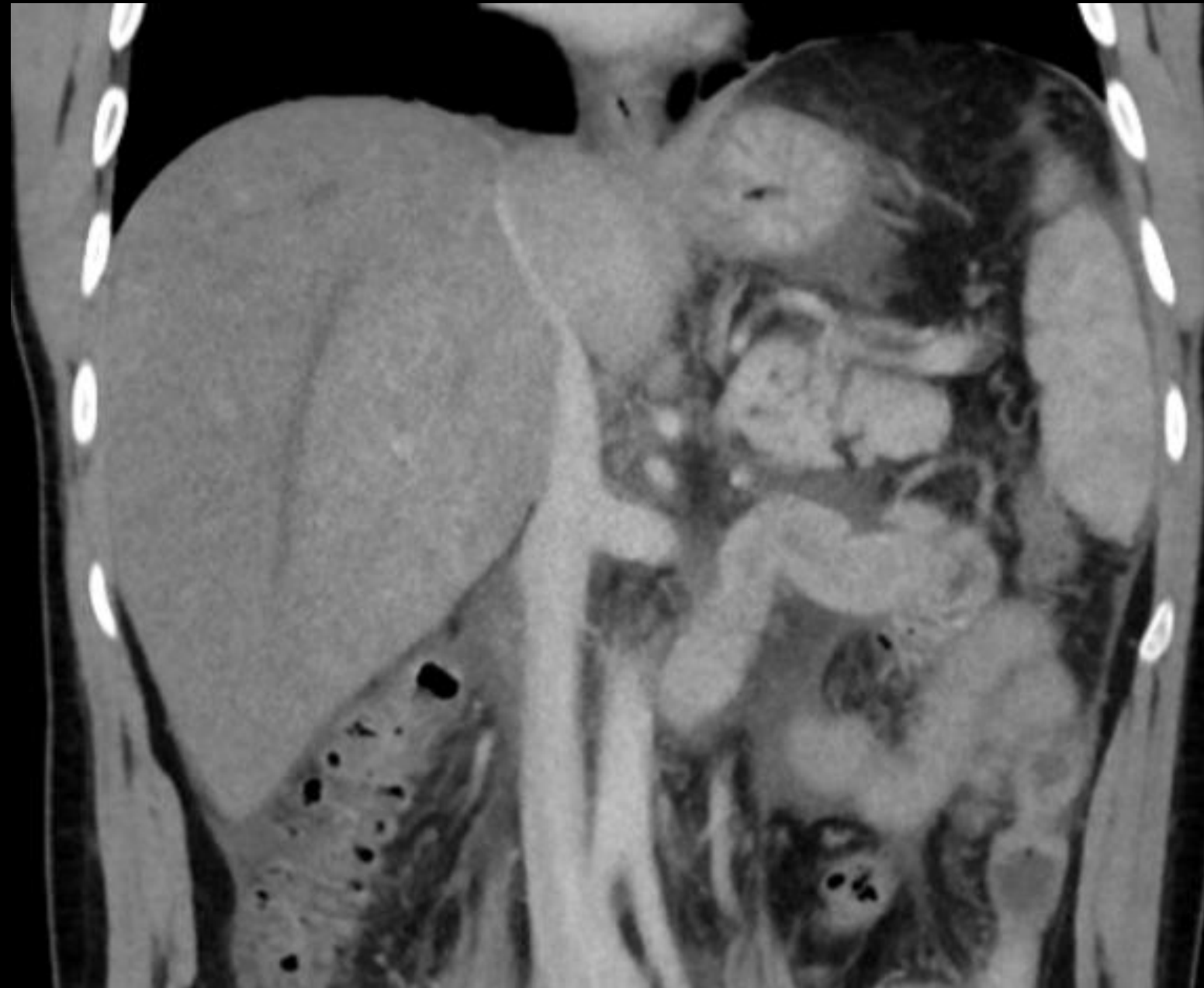
Caudate lobe hypertrophy

- Sometimes grotesque aspect
- Caudate vein ≥ 3 mm (direct drain into IVC)

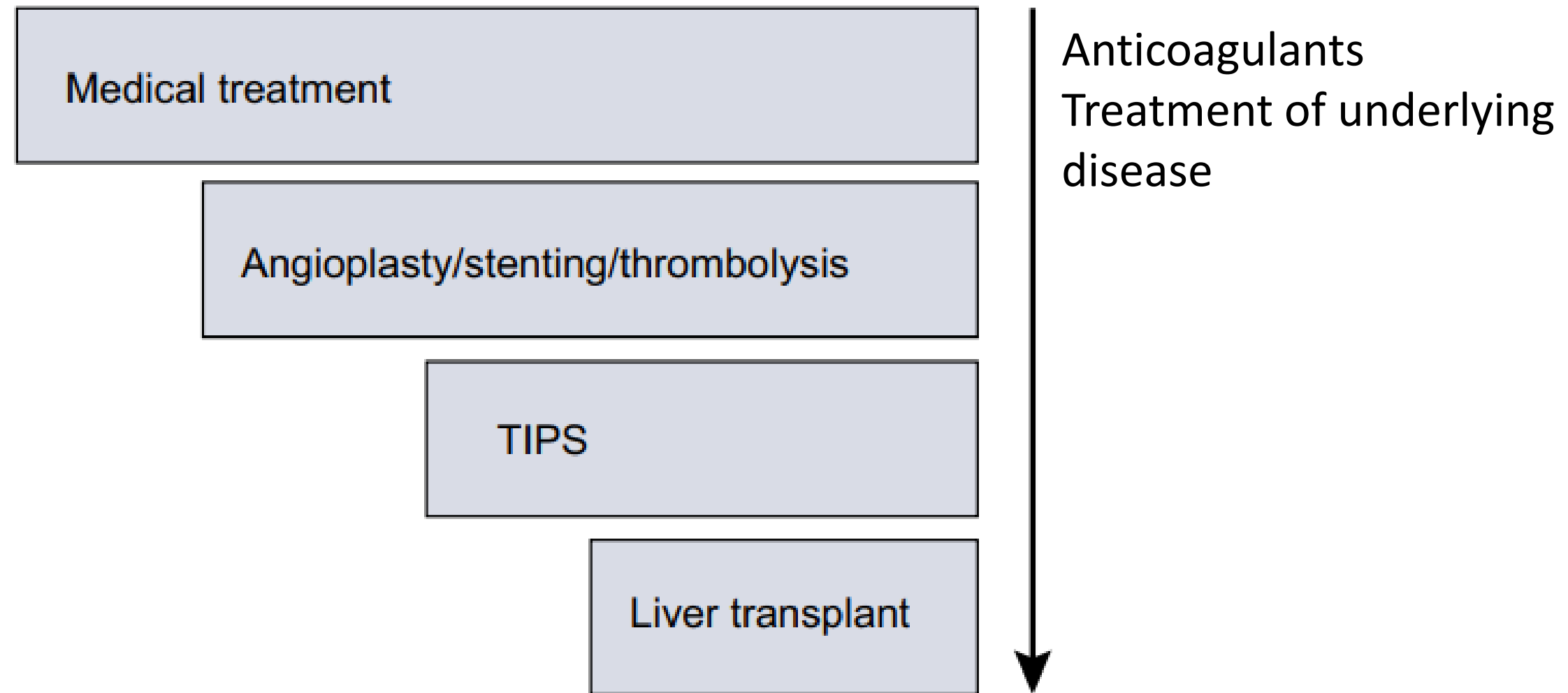


Massive increase in size of the caudate lobe and hypotrophy of the anterior segments of the left liver lobe

CECT: IVC compressed in its intrahepatic part

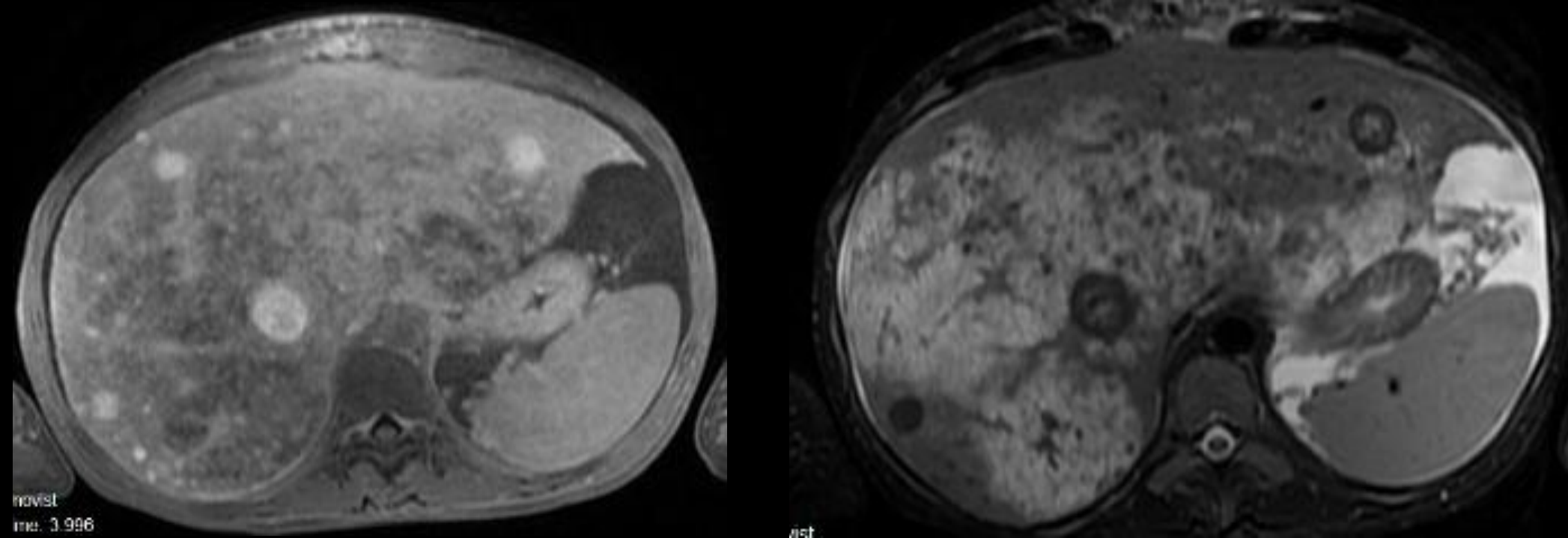


Treatment algorithm in BCS



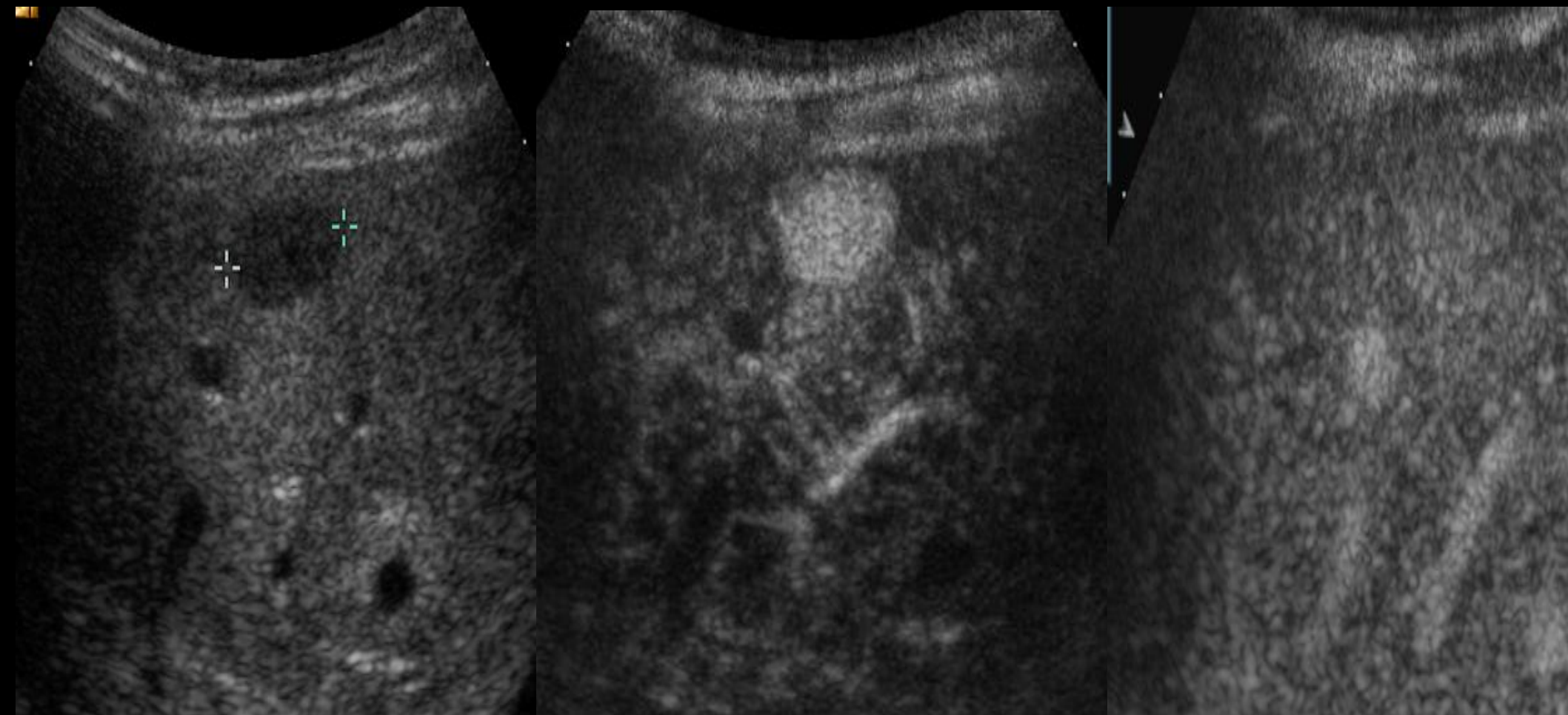
EASL CPGs on VLD 2016

Liver nodules in Budd-Chiari



- **Very frequent** 60–80% of patients on pathology
- **Often large; often increase in size**
- **Mostly benign** (FNH-like and large regenerative nodules)
- **But HCC can appear: f-up and biopsy if increase in size**

CEUS to assess nodules in BCS

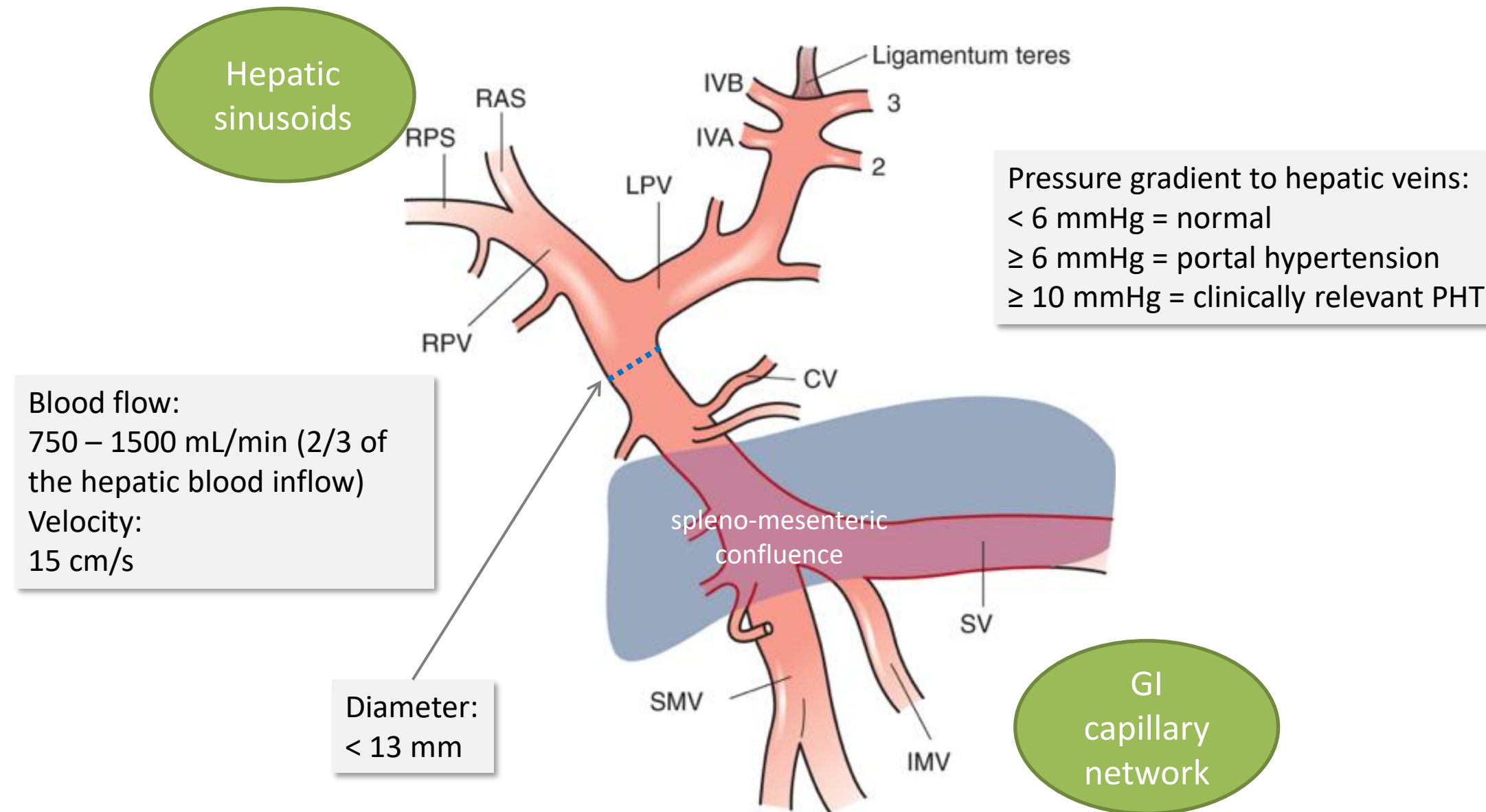


Basal US

Arterial phase

Venous phase

Portal circulation: normal conditions



Portal vein thrombosis: definition and prevalence

Presence of a clot **in any** of the vessels of the PV axis:

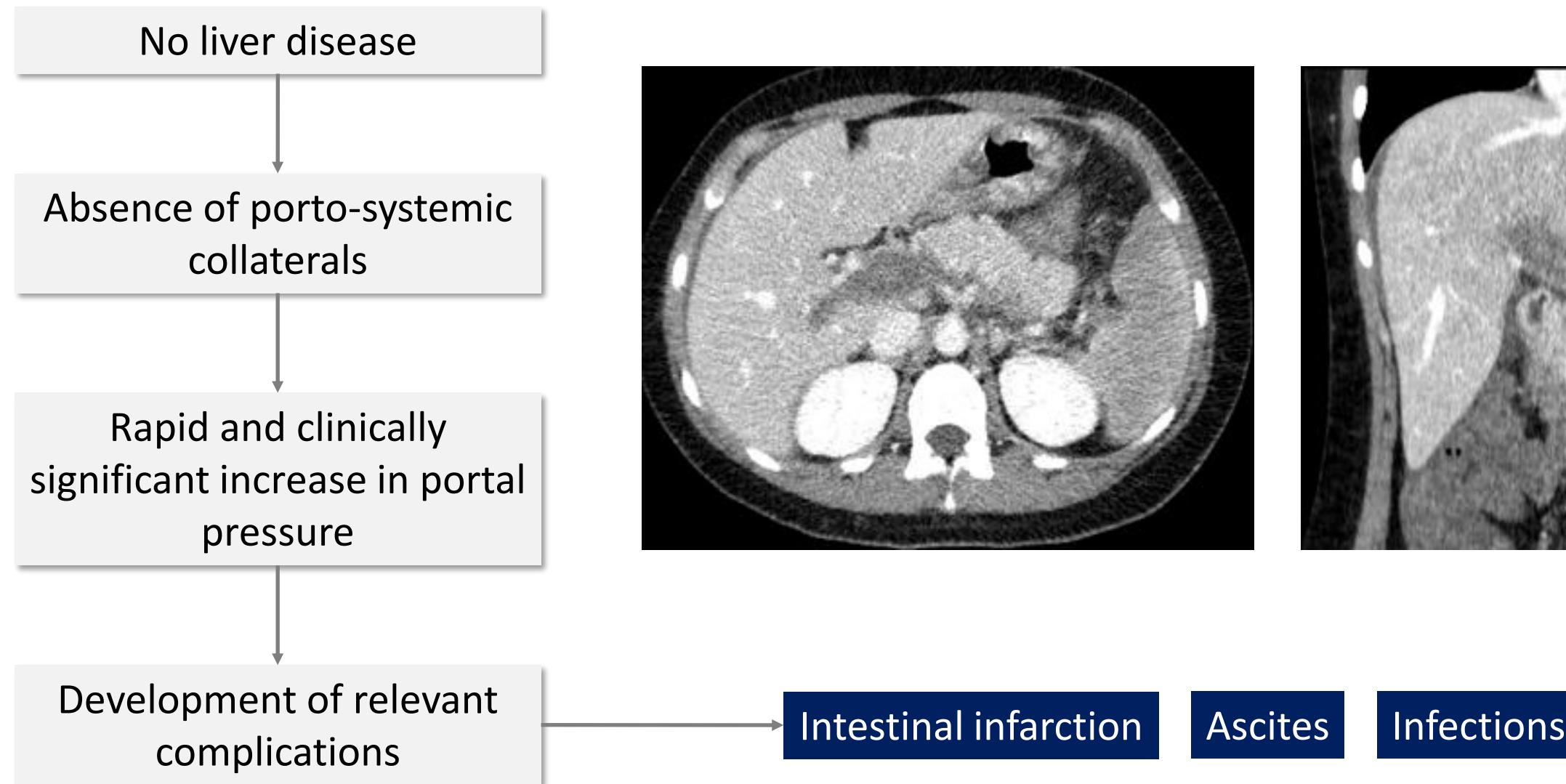
- main portal vein trunk
- left and/or right intrahepatic PV branches
- splenic vein
- superior and/or inferior mesenteric veins

How frequent is it?

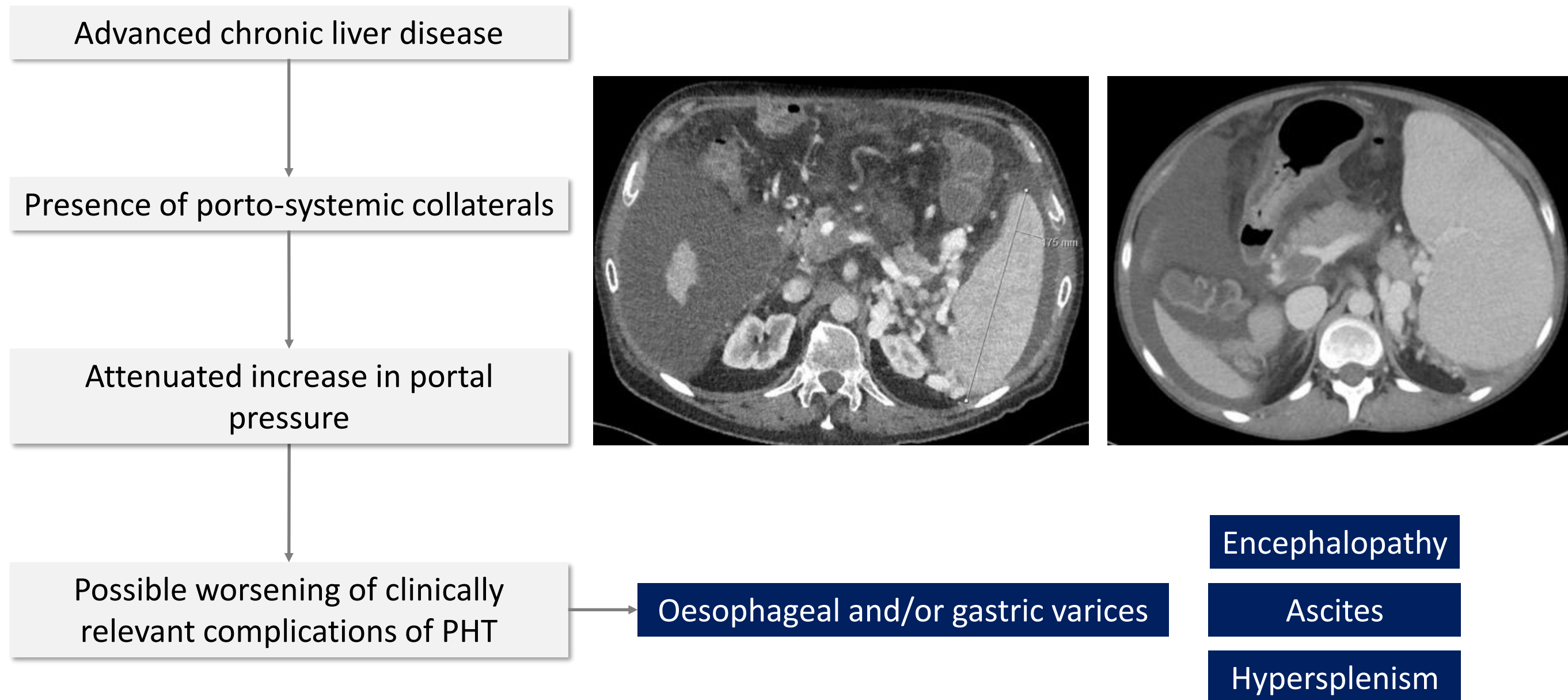
- 2.5 cases per 100'000 per year (without cirrhosis): **EHPVO**
- 5 cases per 100 per year (in patients with cirrhosis)
- 9 cases per 100 per year in PSVD

Northup et al. AASLD Guidance 2020

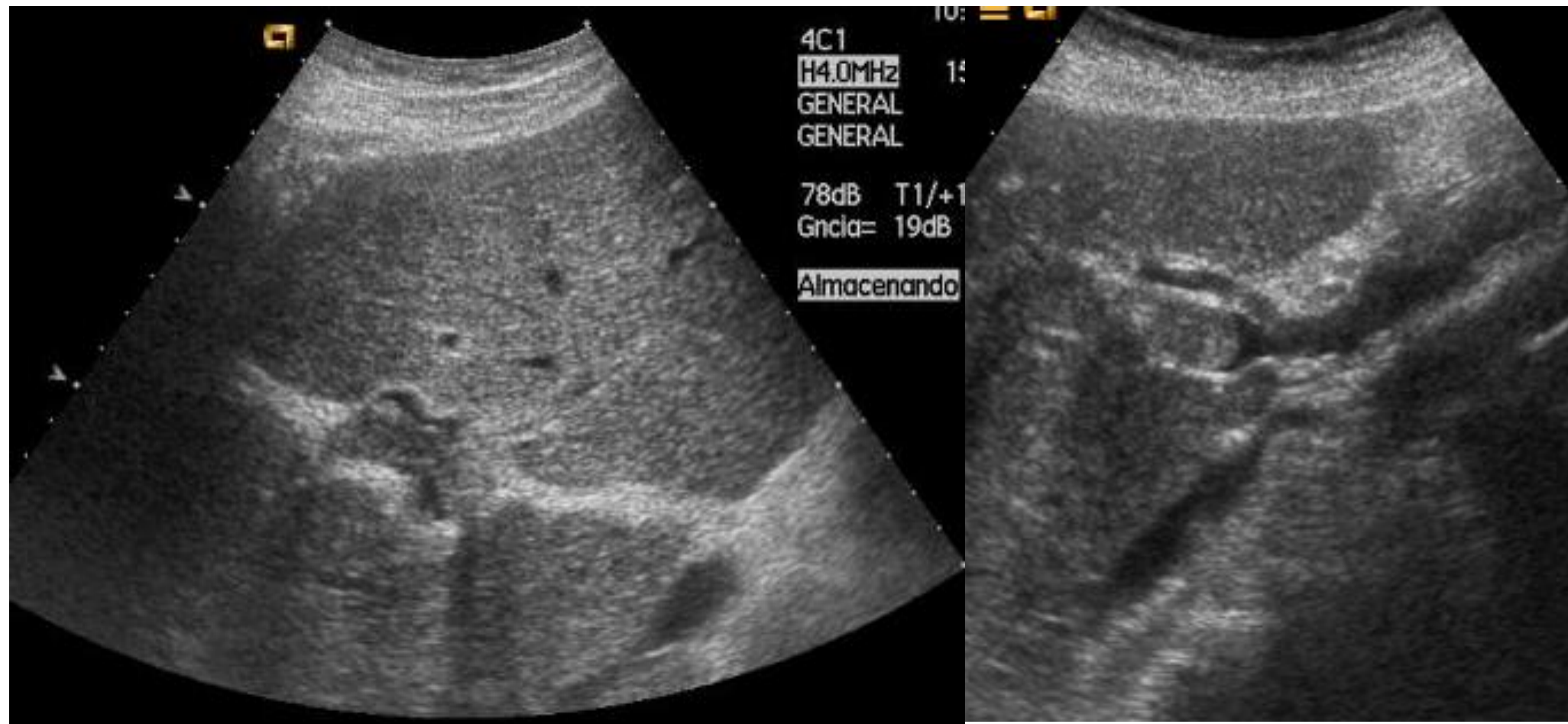
Clinical presentation: recent obstructive portal vein thrombosis



Clinical presentation in cirrhosis: obstructive portal vein thrombosis



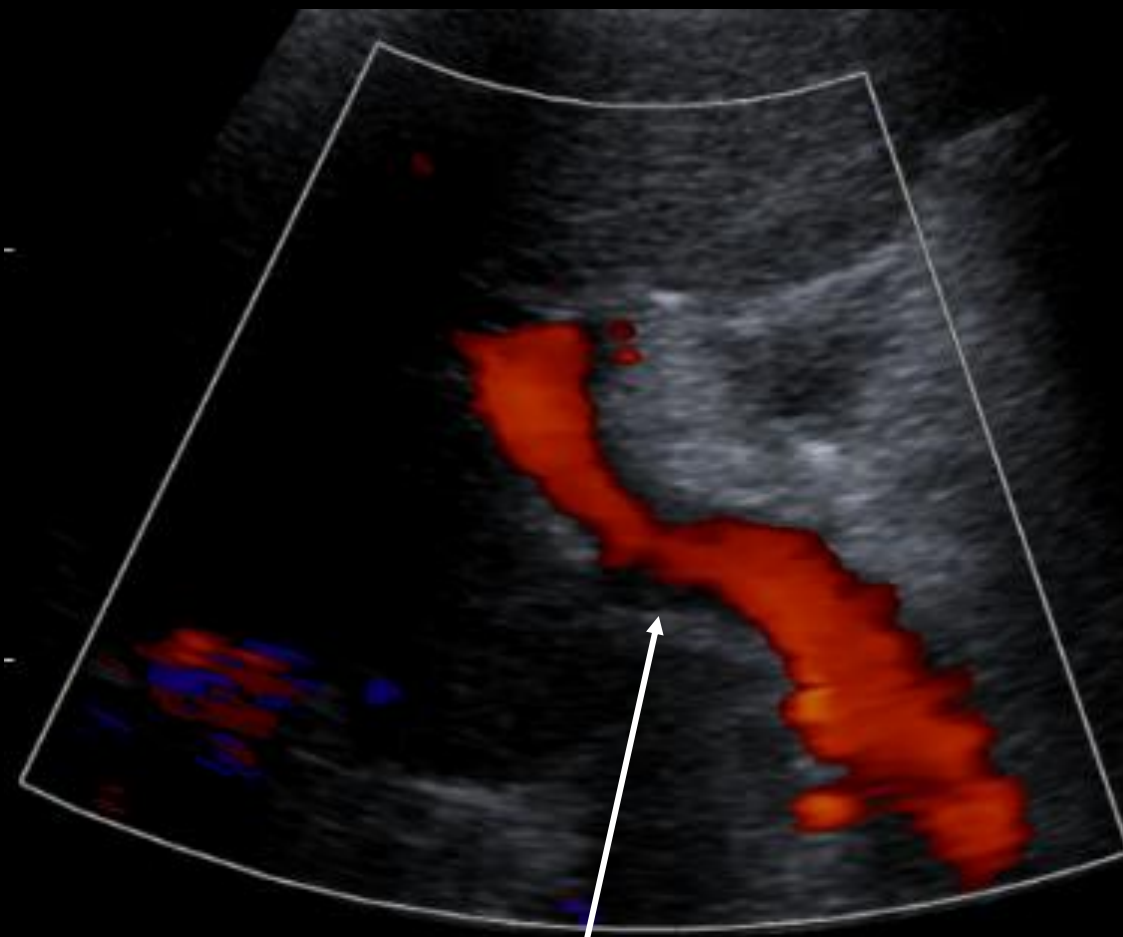
How does it appear on US?



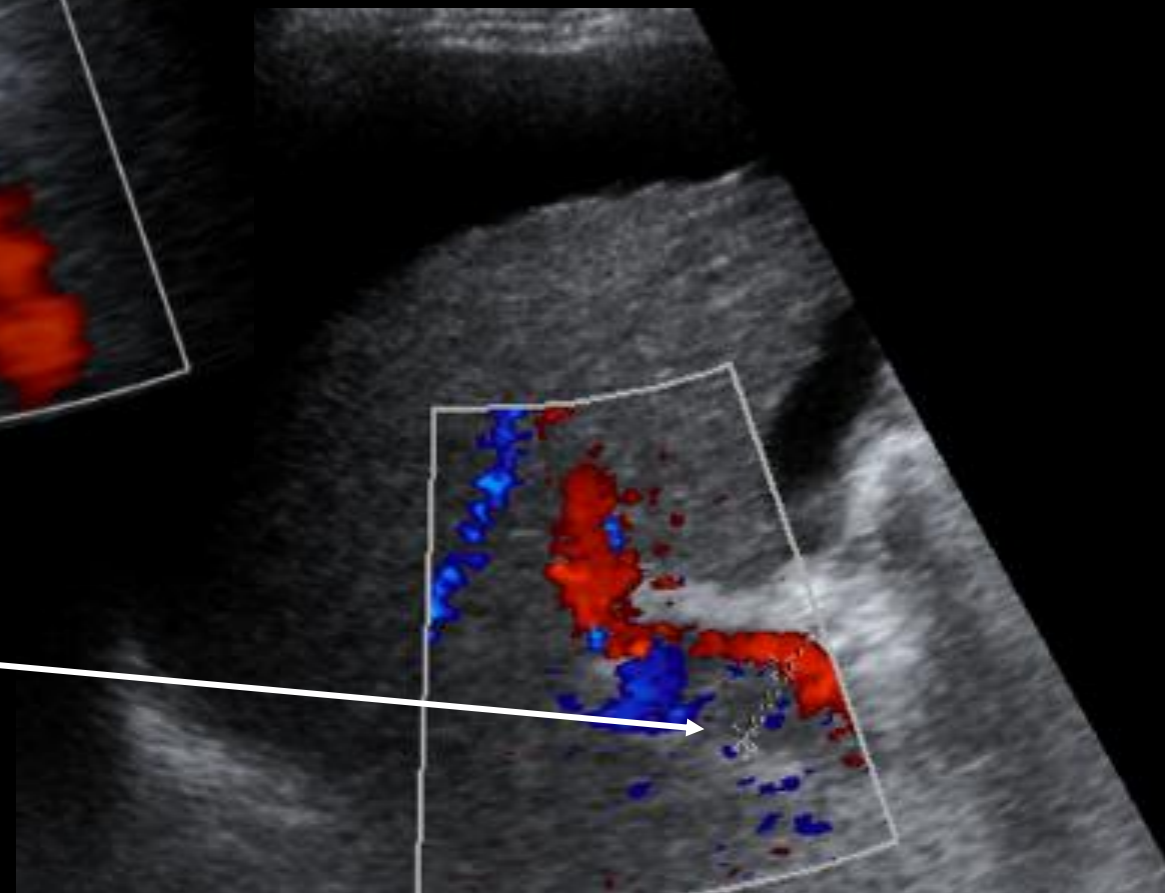
Echogenic material (hypo-, iso- or slightly hyperechogenic) within the vessel (better visualized in B-mode)

which can be partially (better seen on B mode) or completely occluded
(flow better visualized by CDUS and PWUS)

CDUS of partial PVT
at hepatic hilum

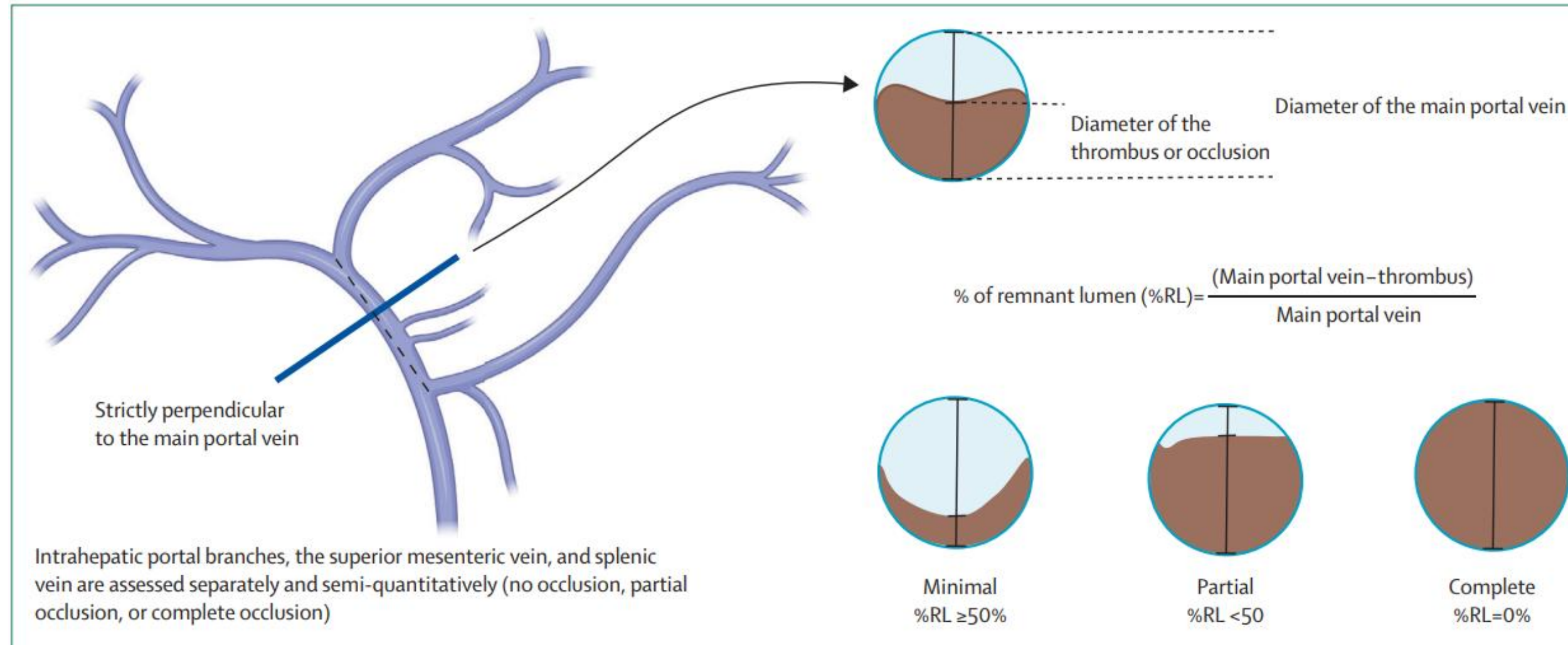


Lack of complete colour filling



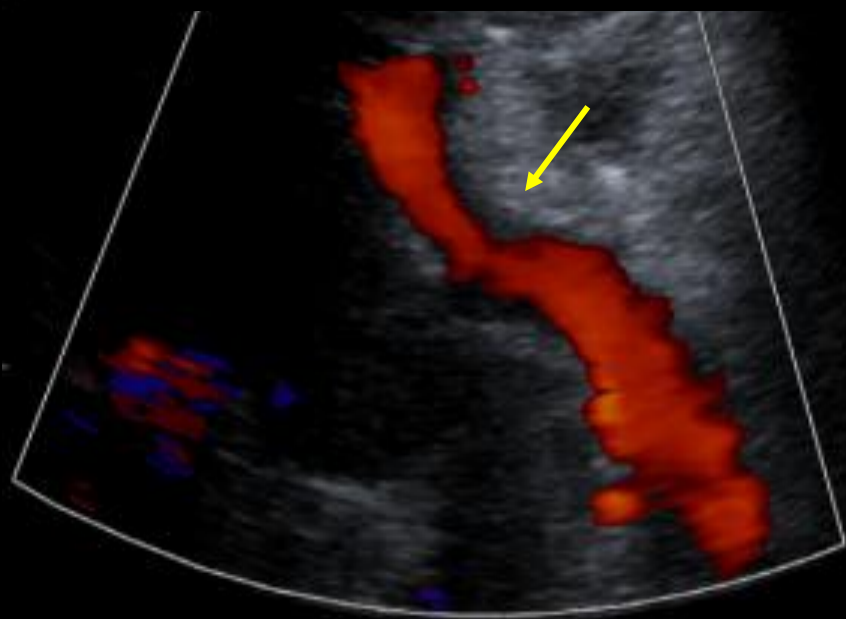
Grey scale first; false negative if CDUS is used on first place!

Extent of PV Thrombosis: terminology according to the Baveno VII consensus

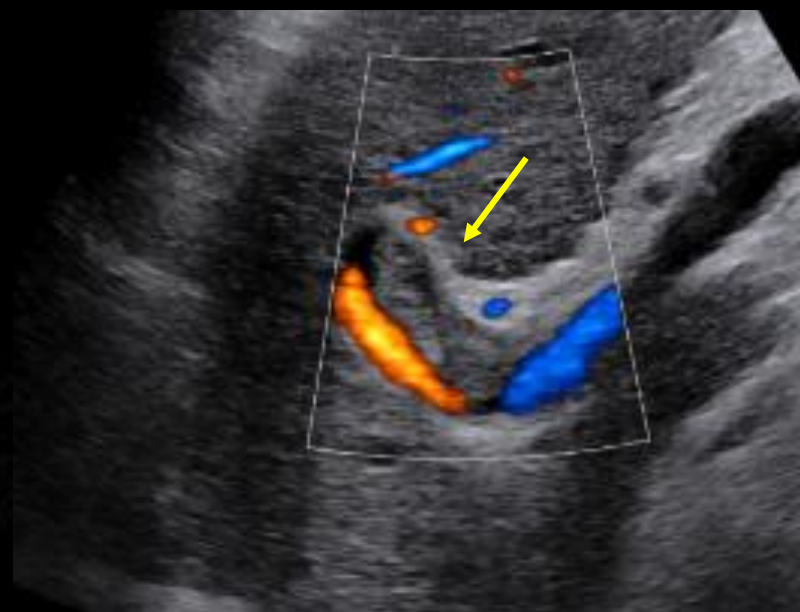

Elkrief et al. Lancet GH 2024

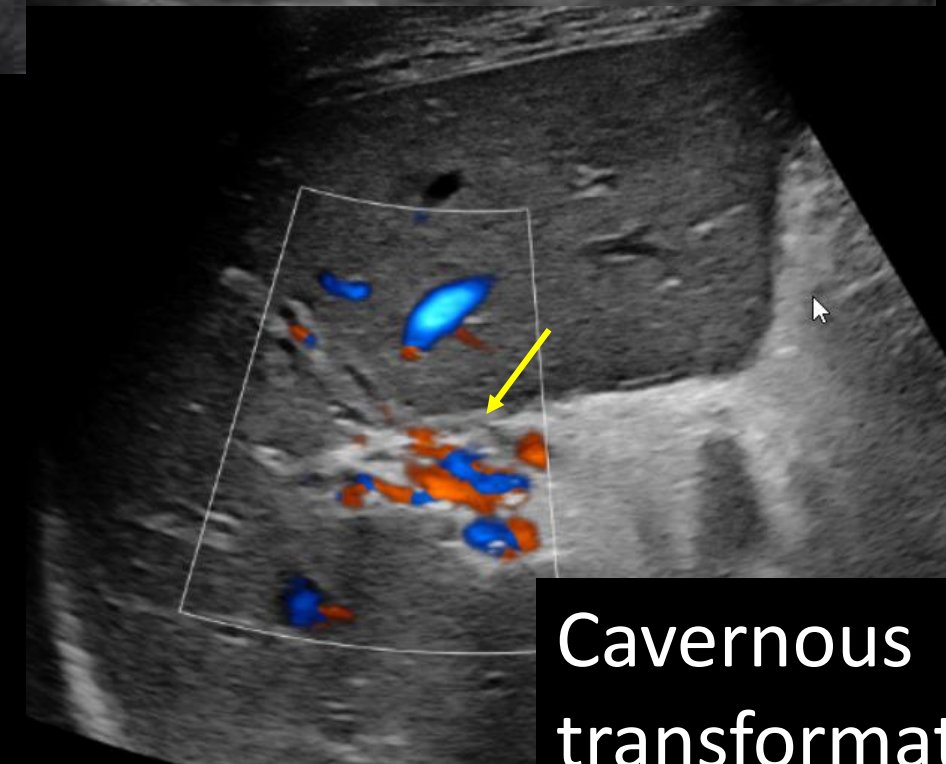
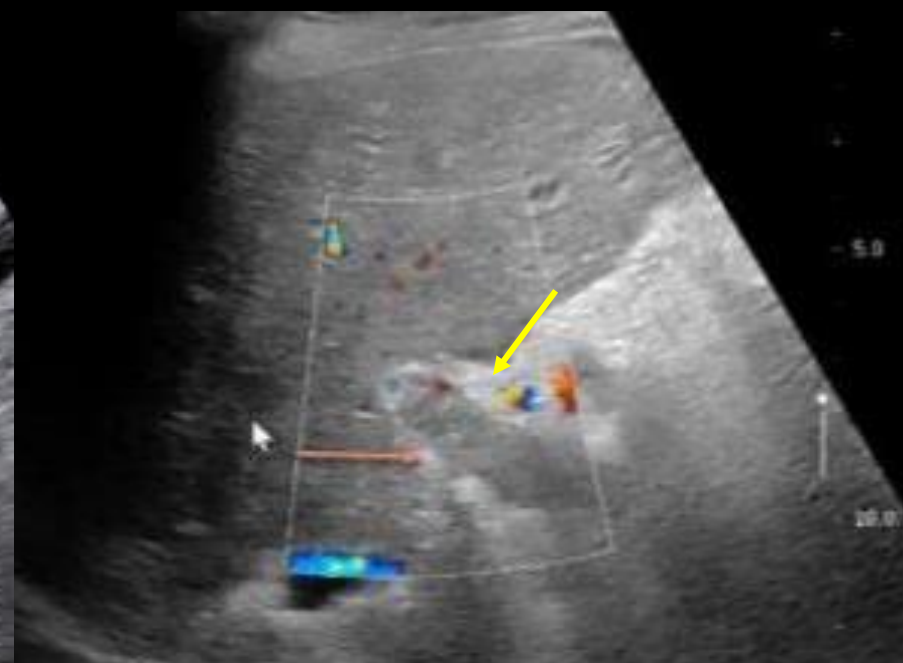
Minimally occlusive
($<50\%$ of the lumen)



Partially occlusive
($>50\%$ of the lumen)

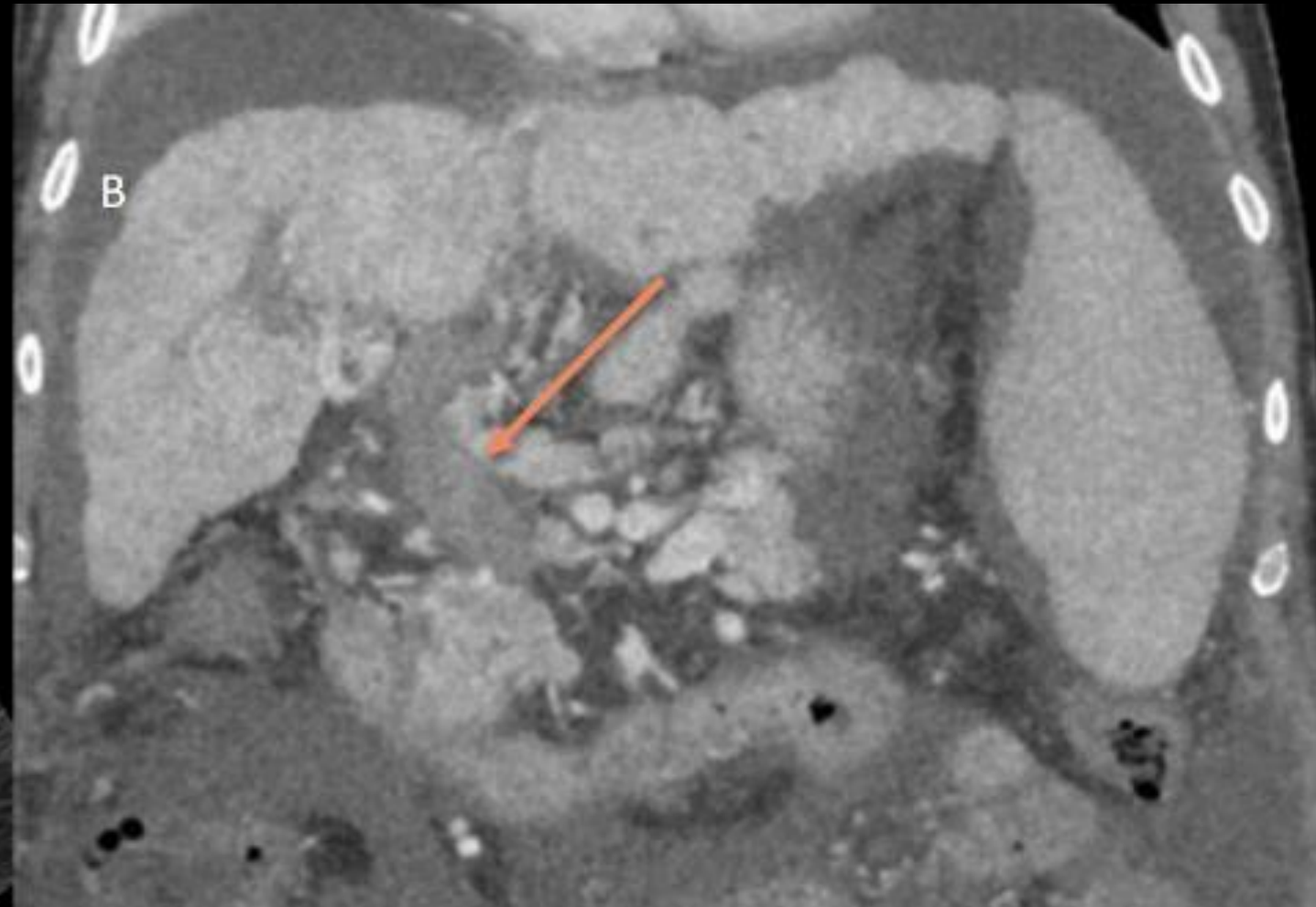
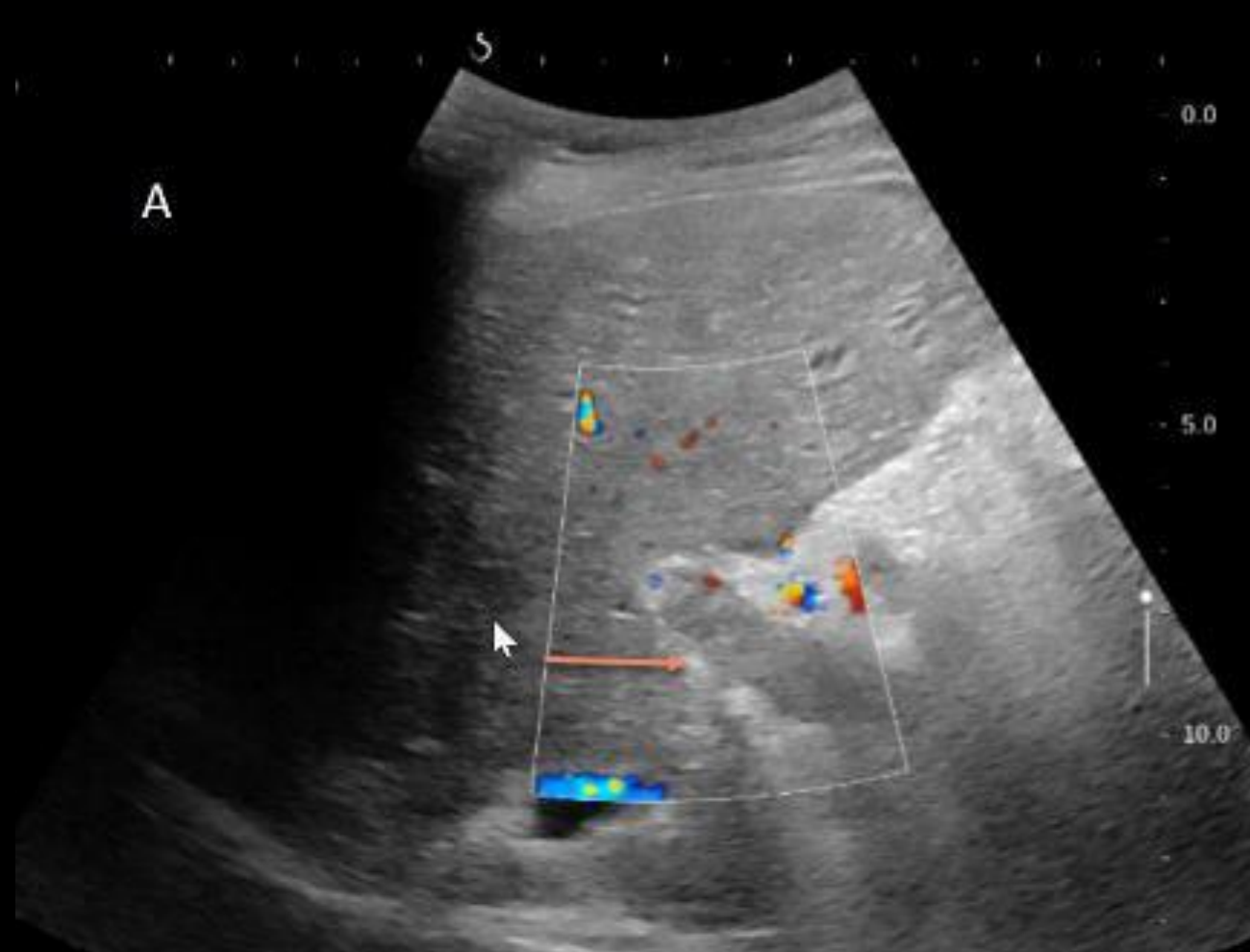

Completely occlusive PVT

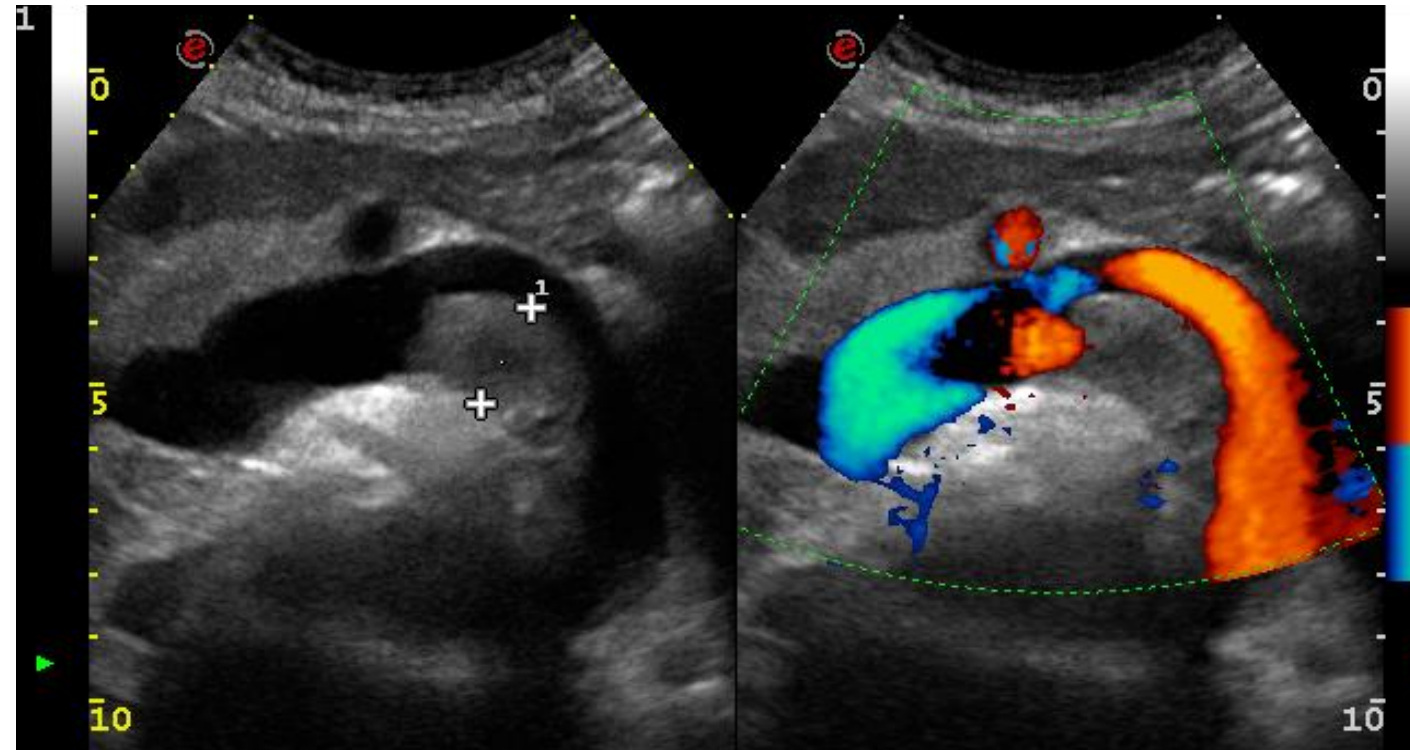


**Extent of PV Thrombosis:
terminology according to the
Baveno VII consensus**

Complete PVT



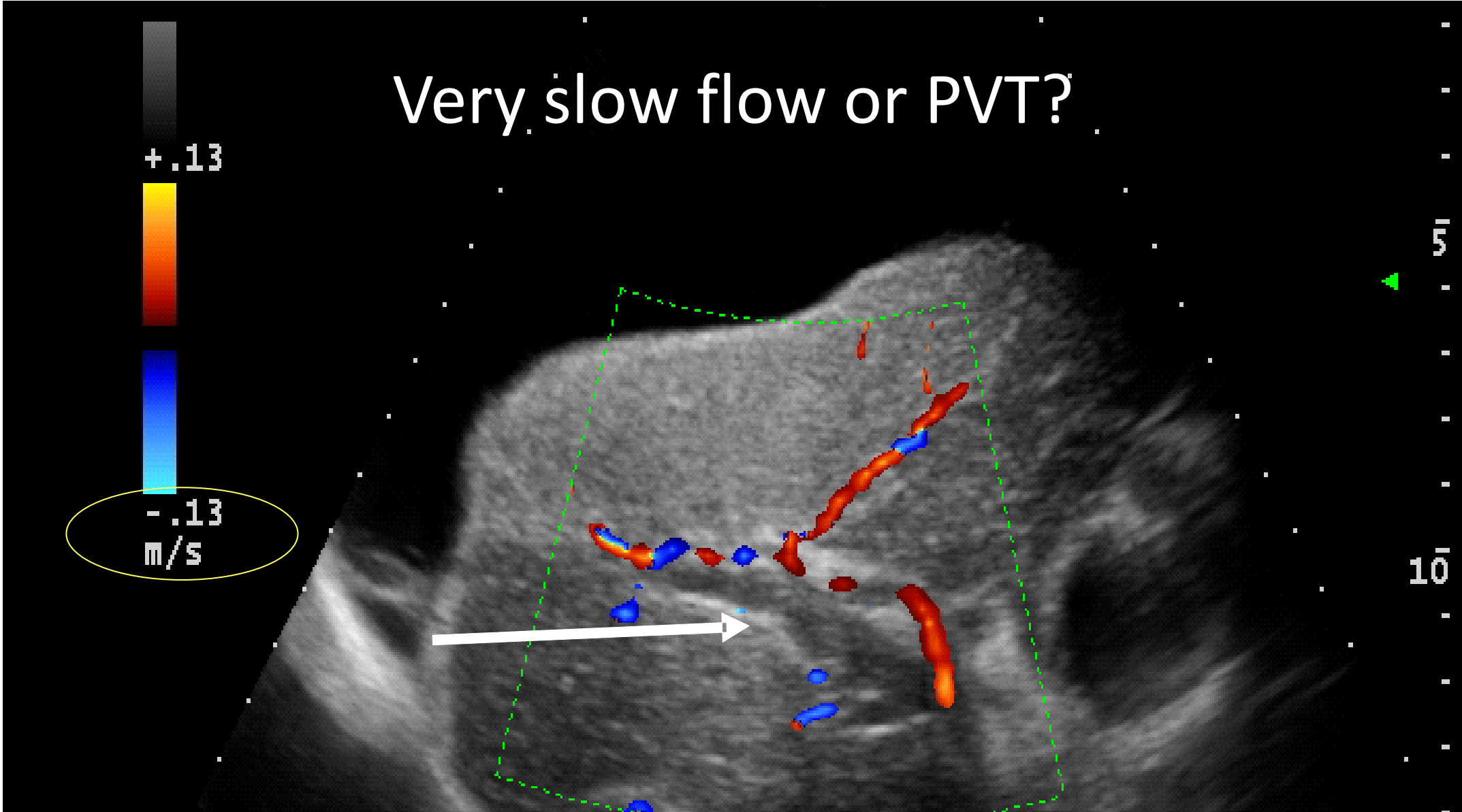
Thrombosis of the splenic vein



US/CDUS is > 90% accurate in diagnosing PVT and SVT, but accuracy is lower for SMVT

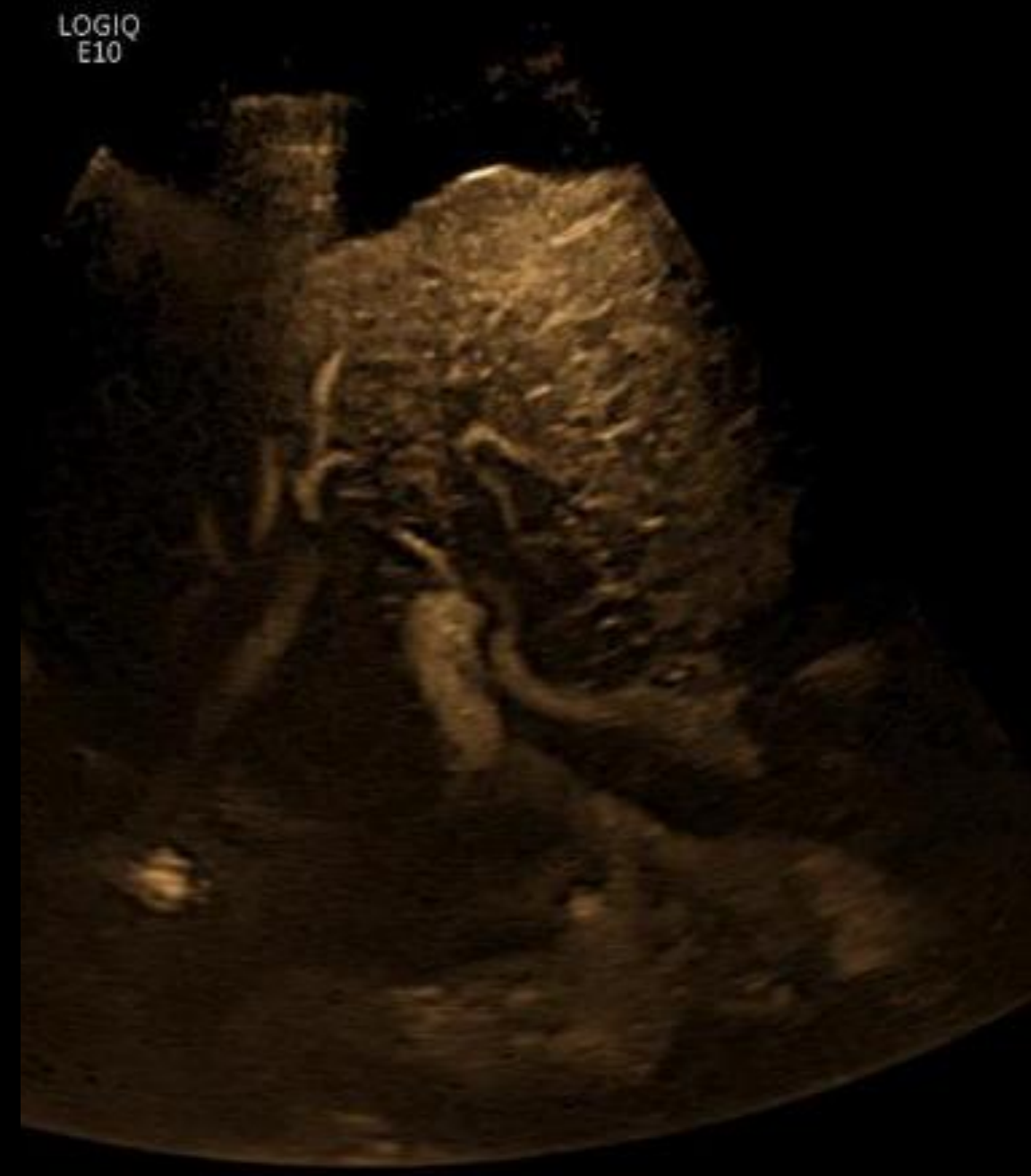
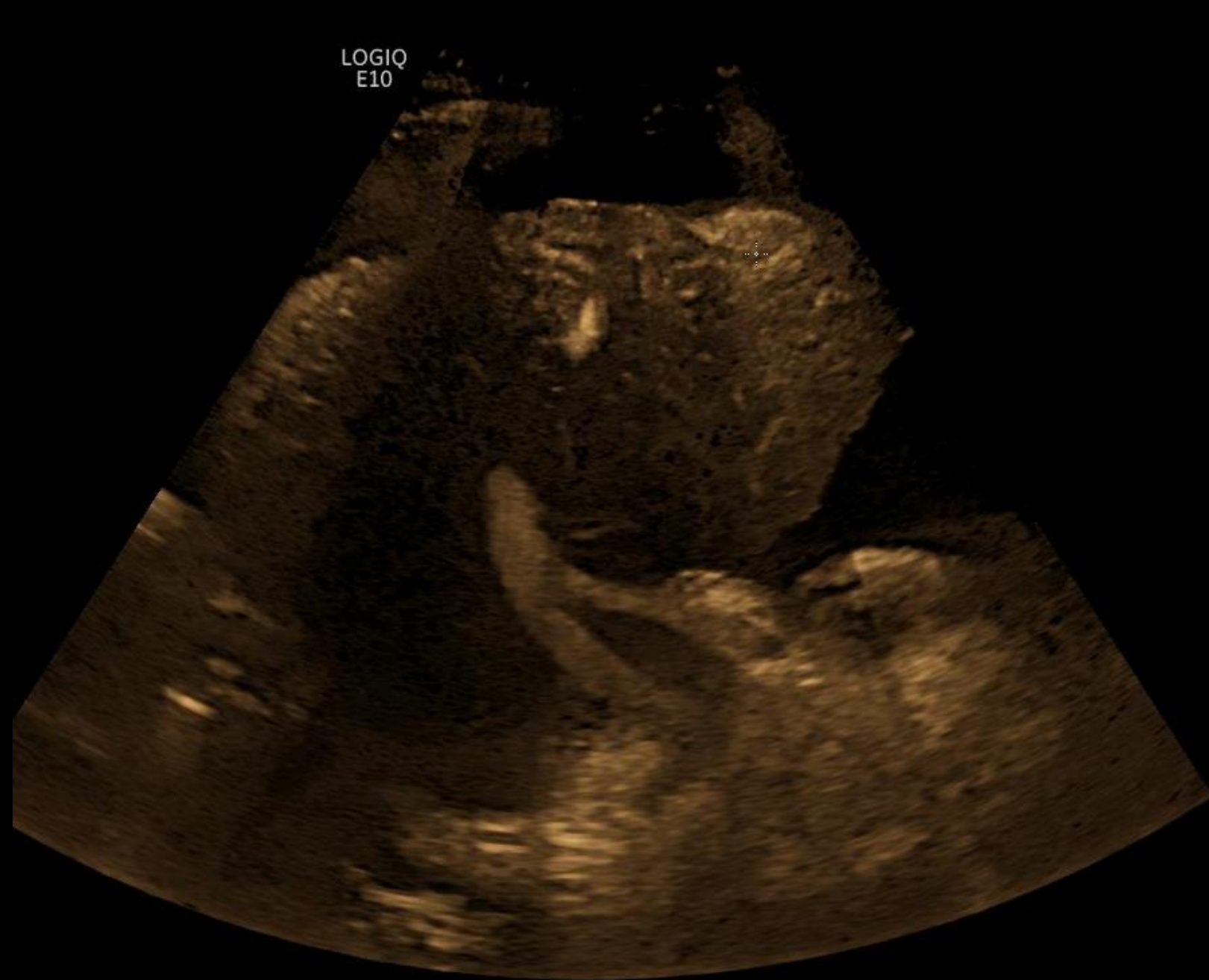Bach et al. Radiology 1996
Kuszyk et al. Radiology 1998

Once thrombosis is diagnosed, study of extension should be done with other imaging techniques



Avoiding US false positives (pseud thrombosis)

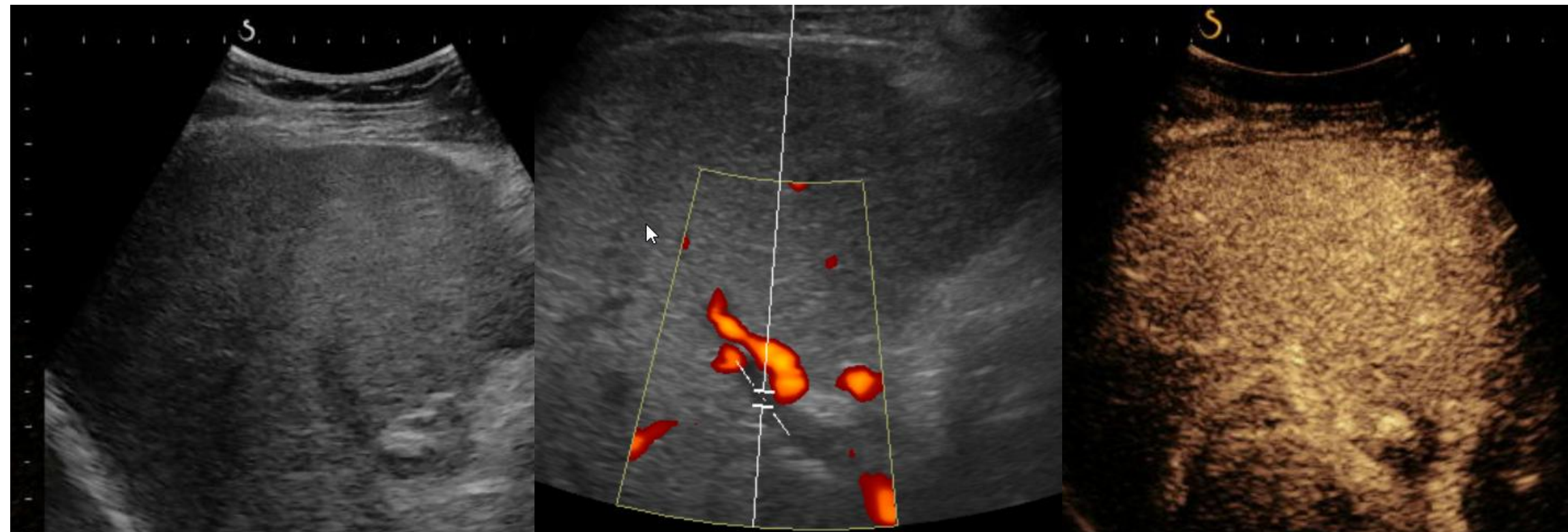
- 1- **CDUS**: reduce pulse repetition frequency (PRF) to minimum → slow flows
- 2- **Power** Doppler US or **angle-independent flow** imaging
- 3- **CEUS** if CDUS and other modes are not conclusive



CLINICAL WEB SERIES

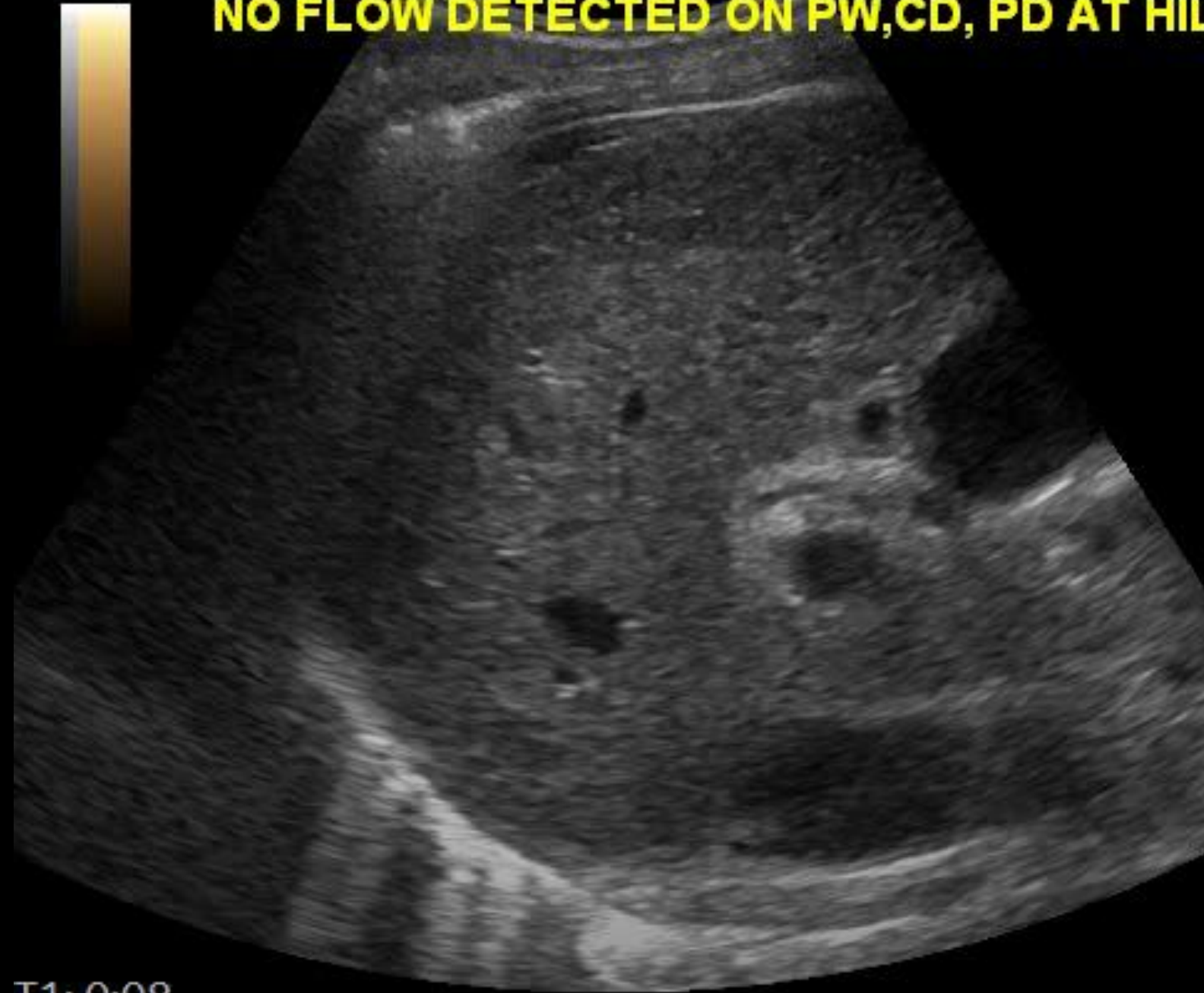
Avoiding US false positives: use CEUS

33 secs

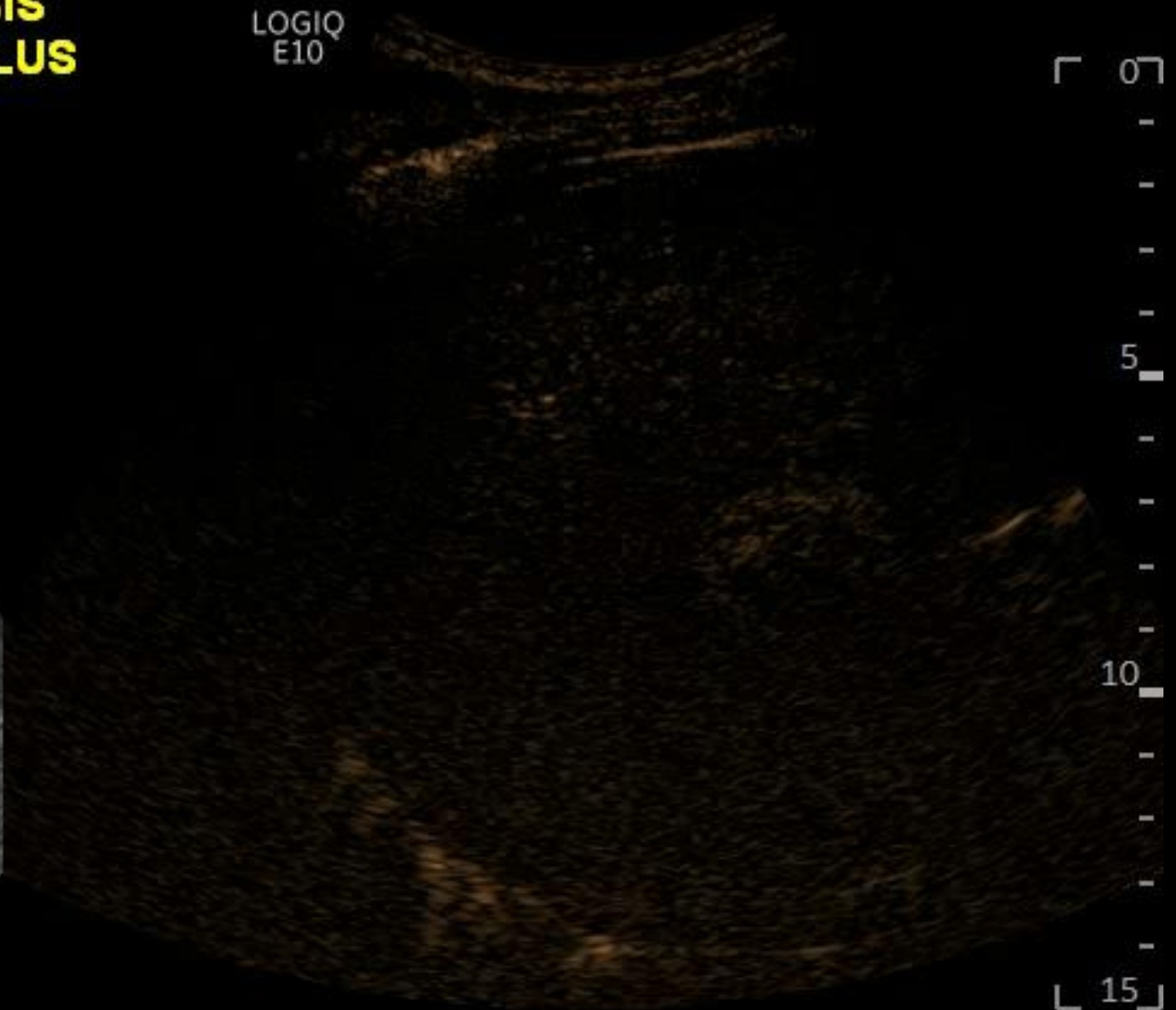


17/04/19 09:00:41AM ADM C1-6 Abdomen MI 0.09 TIs 0.0

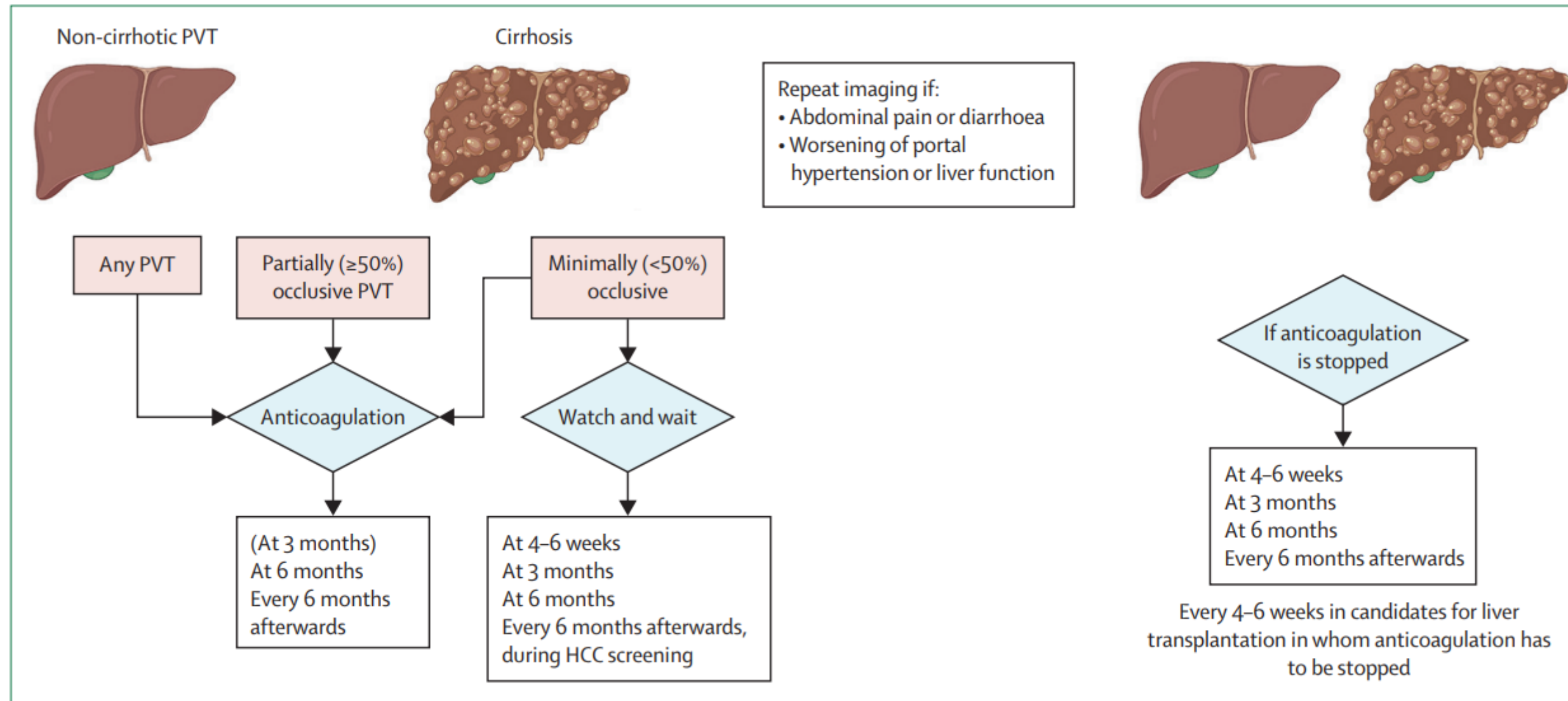
**LIVER CIRRHOSIS AND SEPTIC SHOCK
SUSPICION OF COMPLETE PV THROMBOSIS
NO FLOW DETECTED ON PW,CD, PD AT HILUS**



T1: 0:08



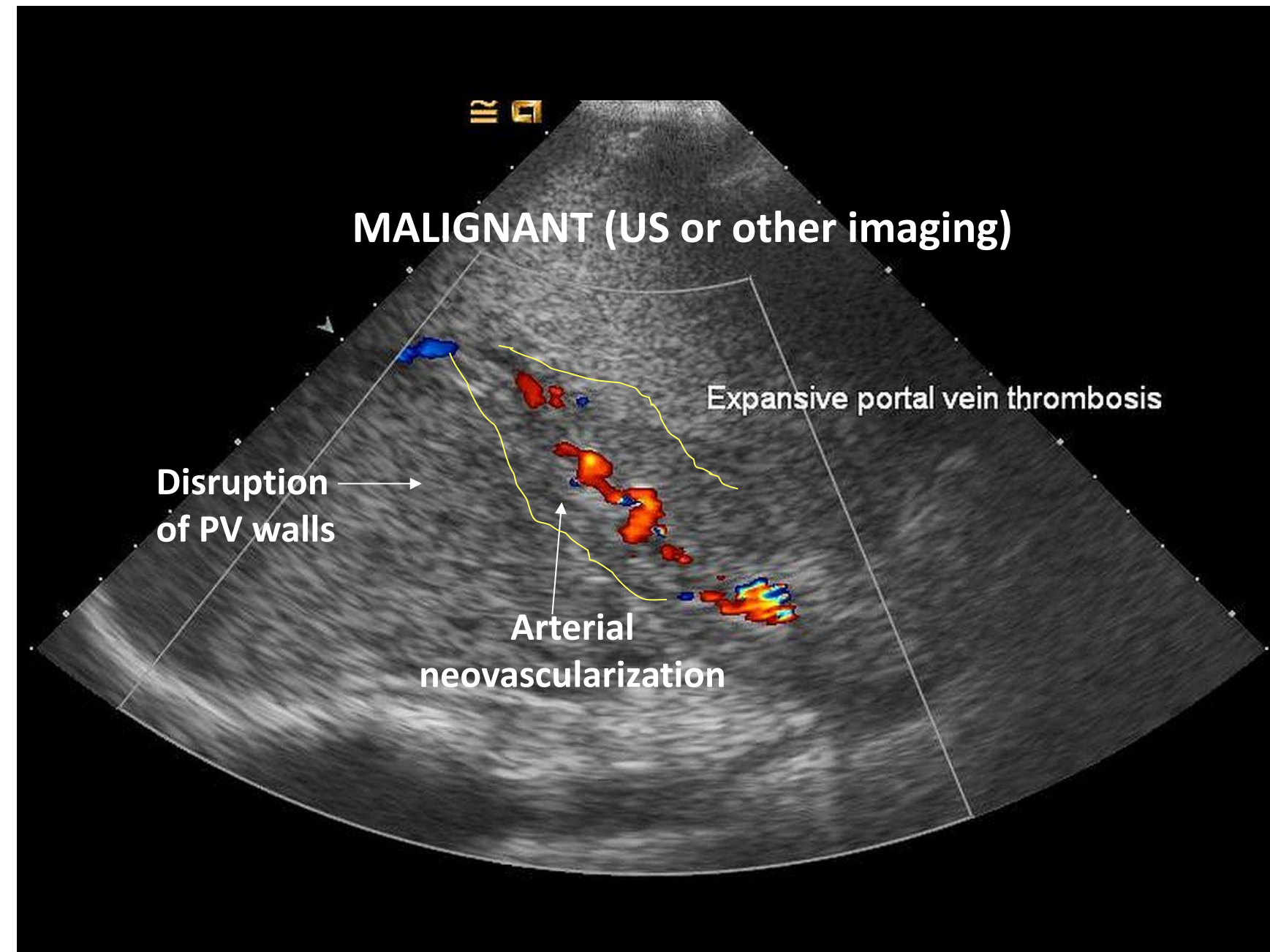
PVT is confirmed by imaging -what to do and what follow-up?



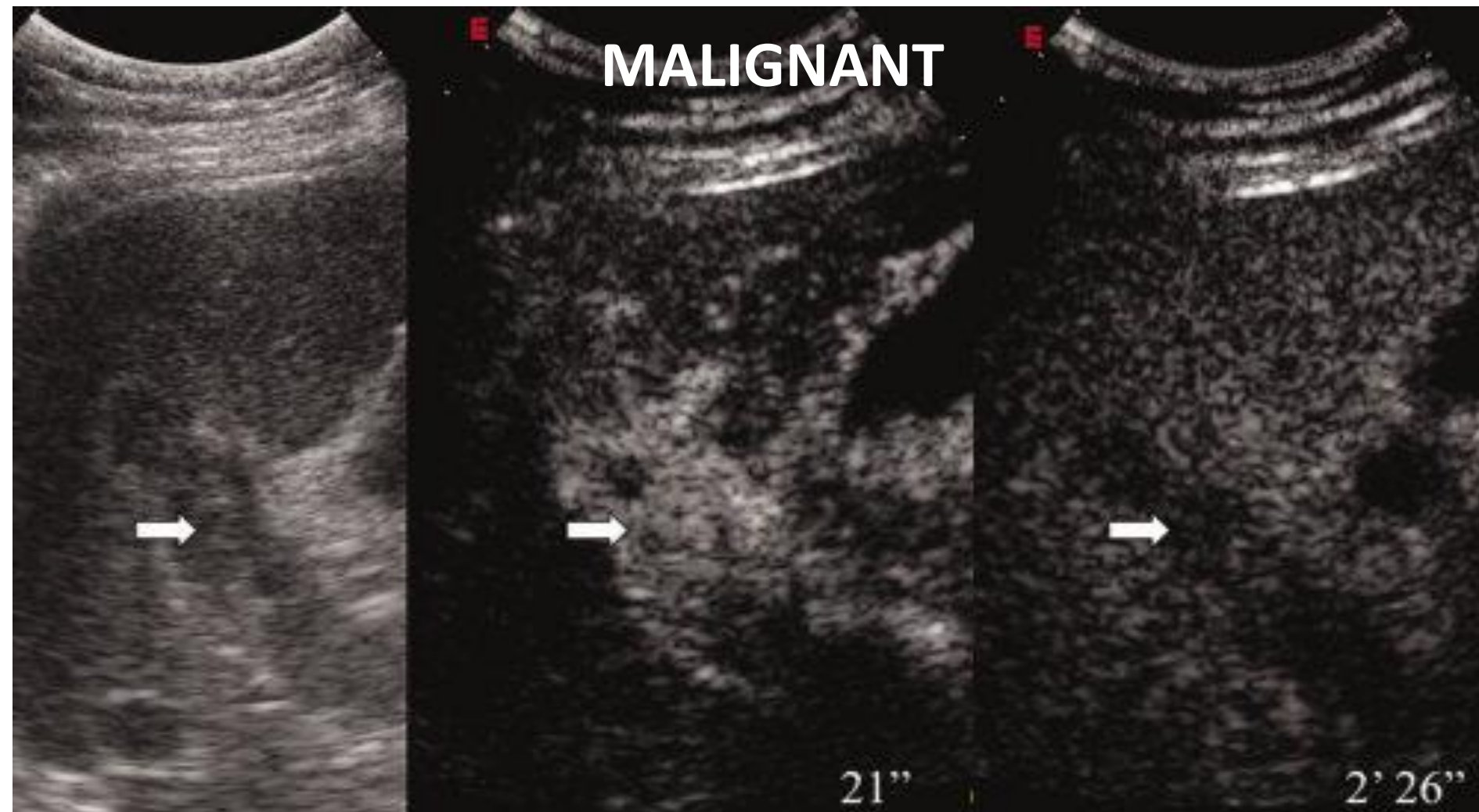
Elkrief et al. Lancet GH 2024

In patients with HCC, is the portal vein thrombosis a bland, benign PVT or is it a neoplastic vascular invasion (“tumor in vein”, “malignant” PVT)?

US differentiation of benign vs. malignant PVT in patients with cirrhosis and HCC



CEUS for differentiating benign vs. malignant portal vein thrombosis in the patients with cirrhosis and HCC



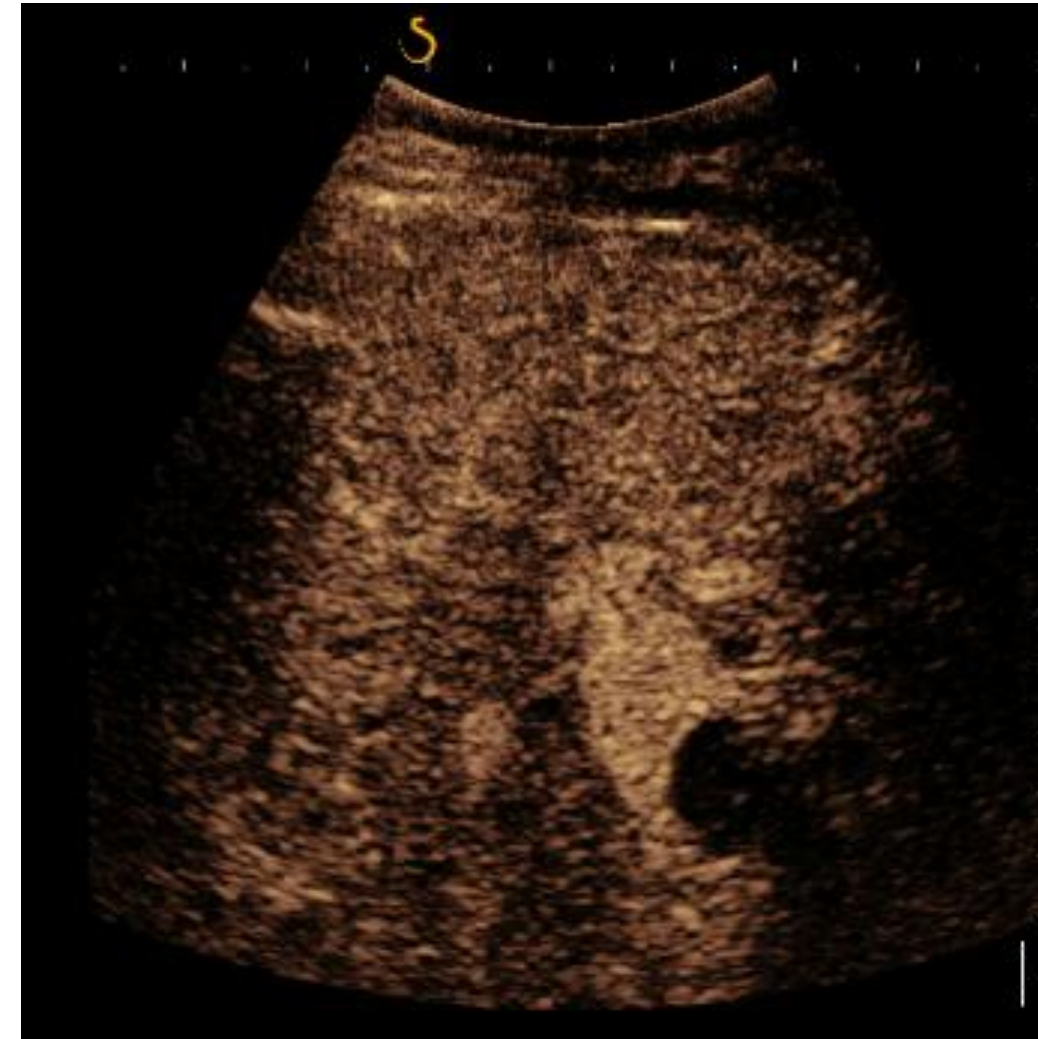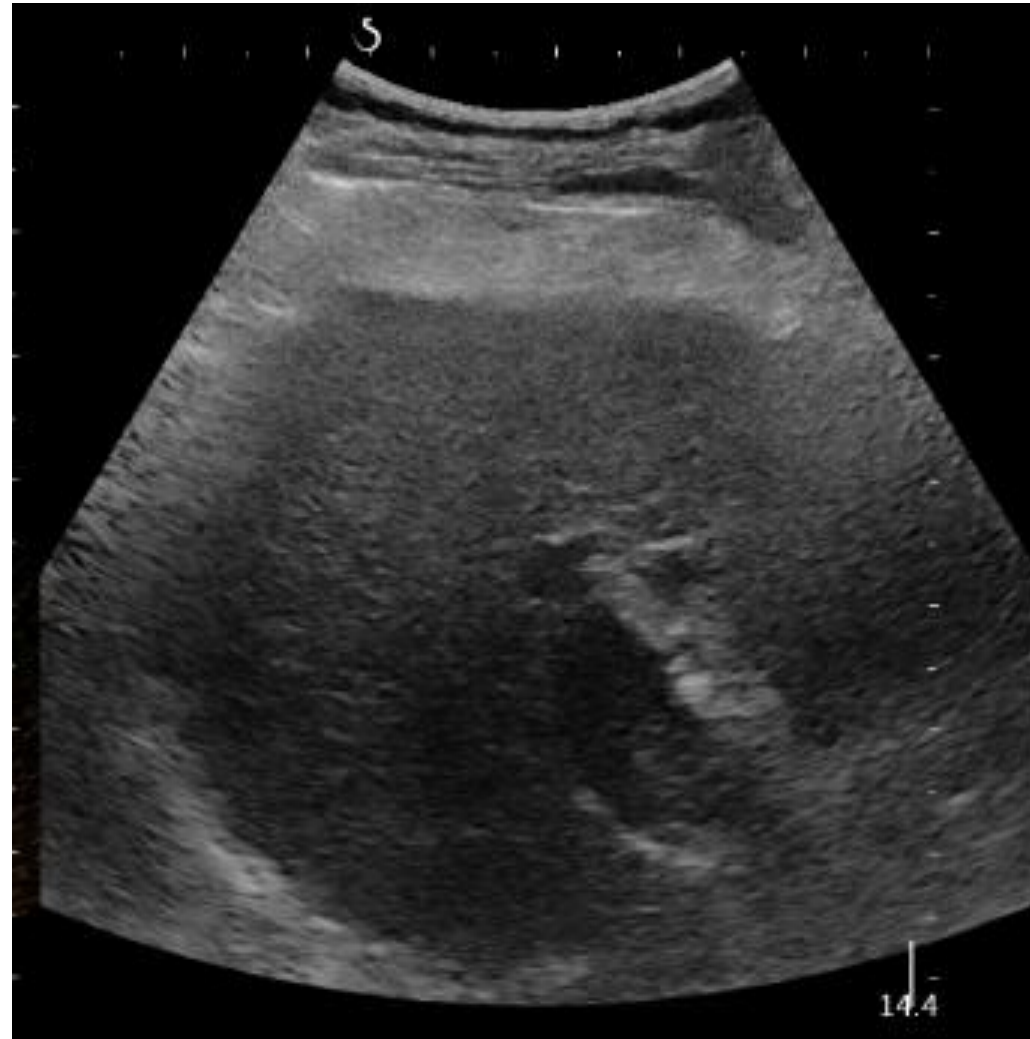
In 50 patients undergoing biopsy of the PV thrombus: better performance of CEUS vs CT scan in PVT detection ($p < 0.0001$) and thrombus characterization ($p = 0.0001$)

For neoplastic vascular invasion: Sens 98% CEUS vs 67.6% CT, specificity 100% CEUS, vs. 60% CT

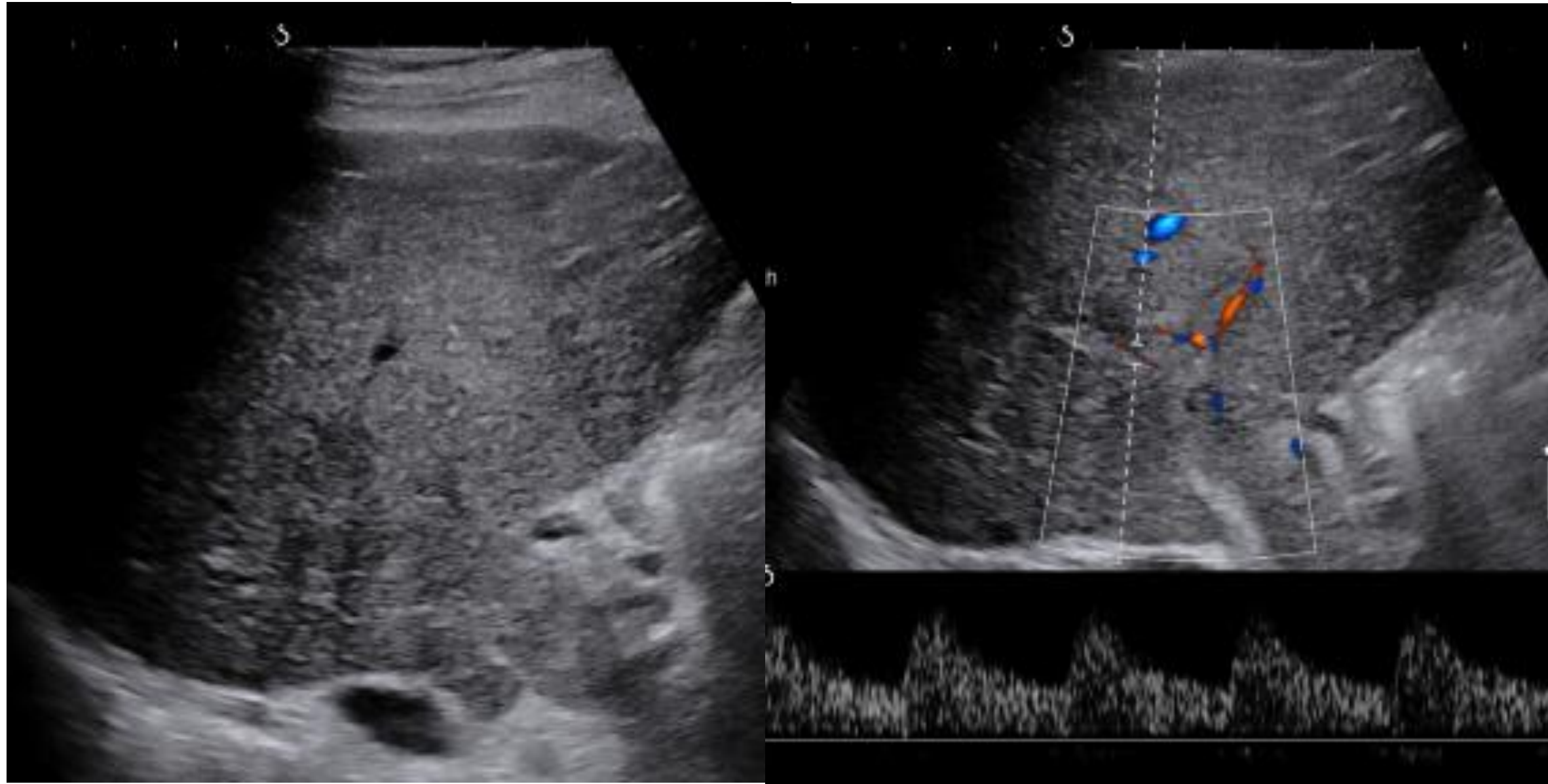
Rossi et al. Eur Radiol 2008

Piscaglia et al. Liver Traspl 2010

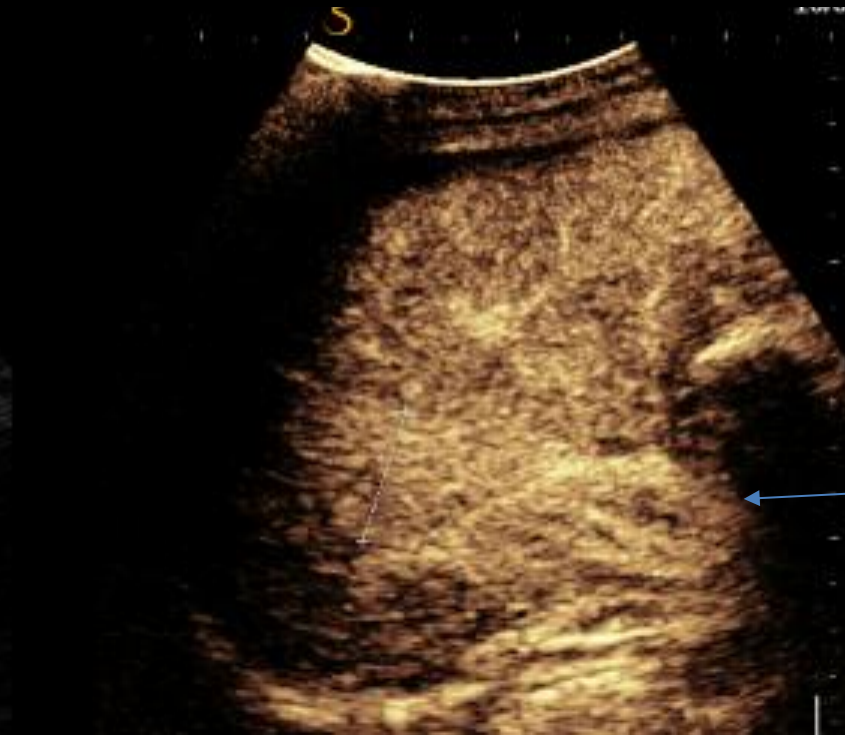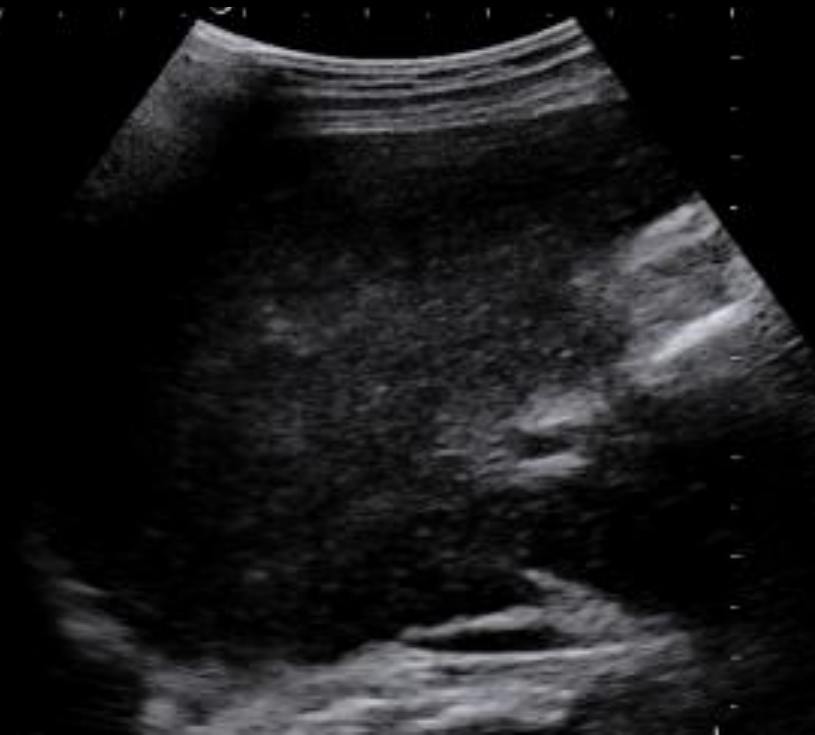Partial PVT in a patient with HCC: benign



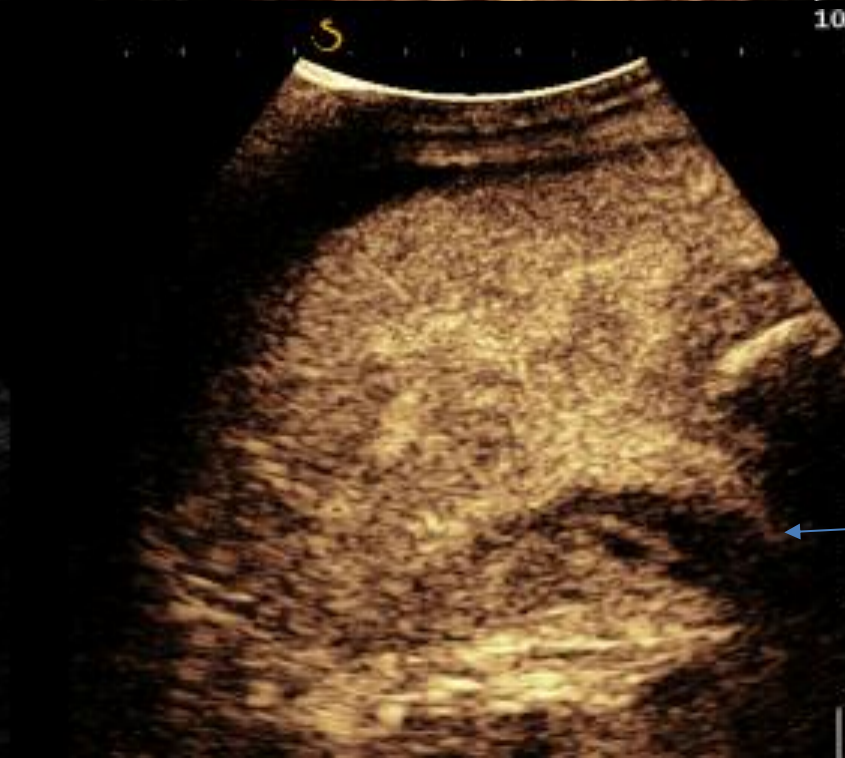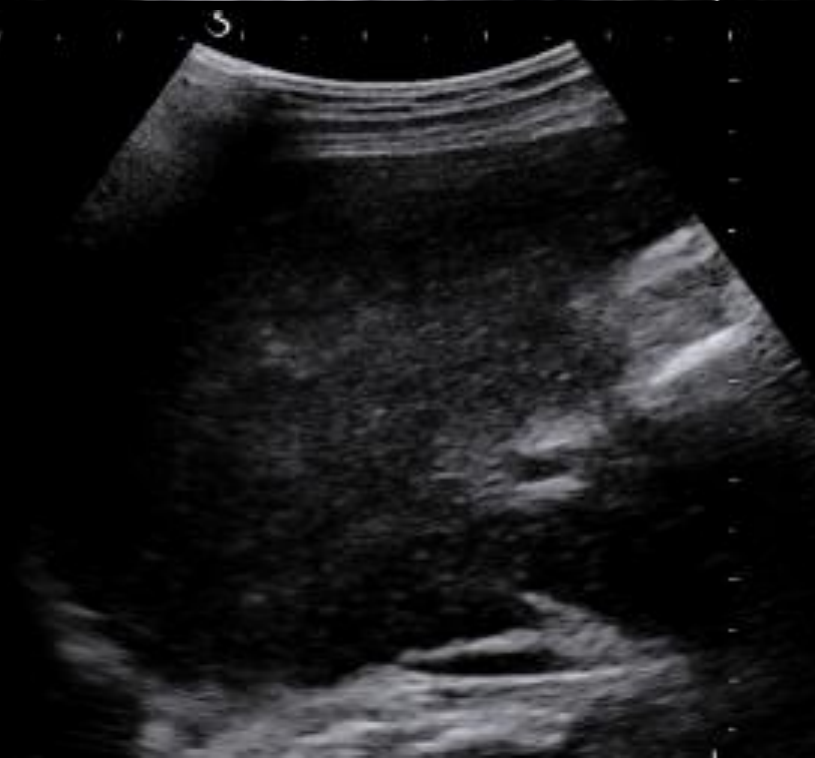Obvious vascular invasion in a patient with HCC: MALIGNANT aspect on B mode and Doppler



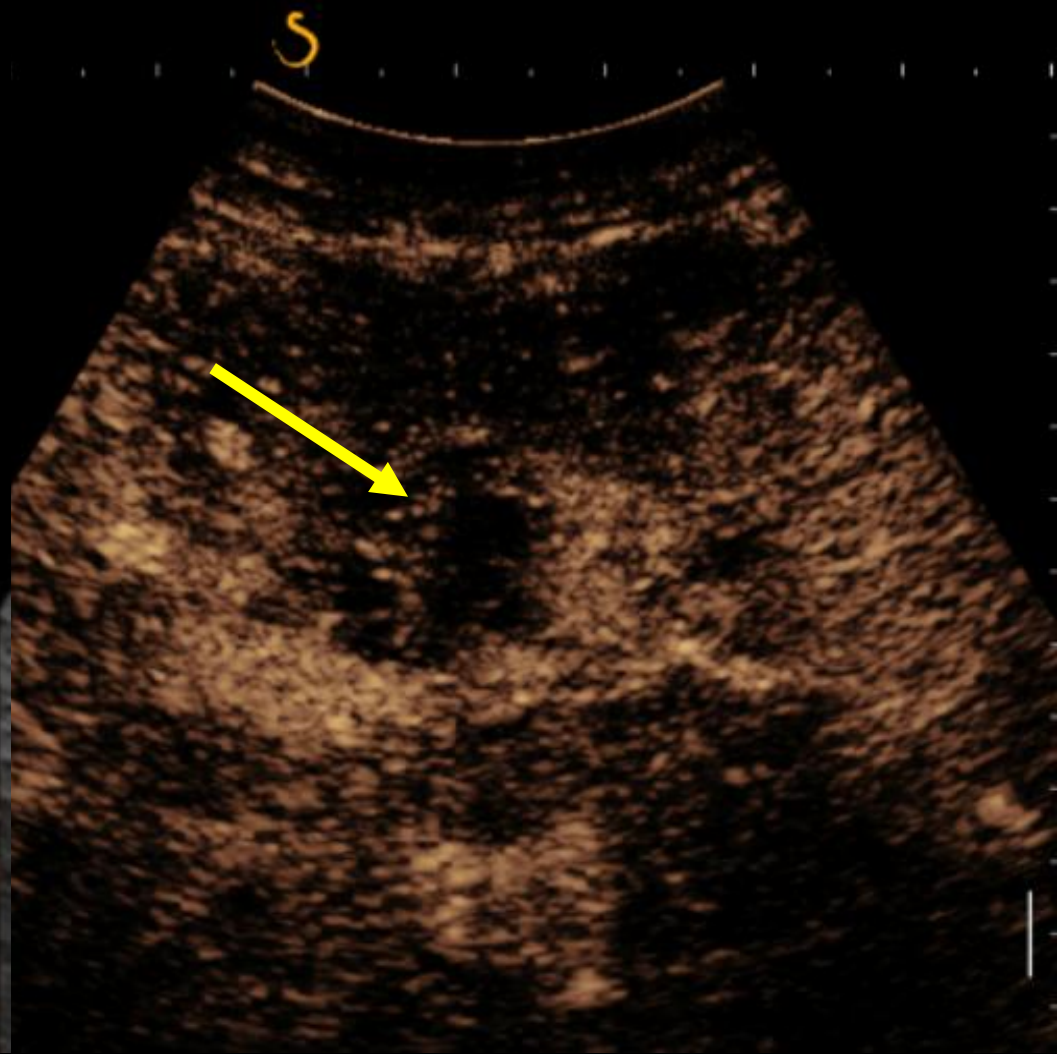
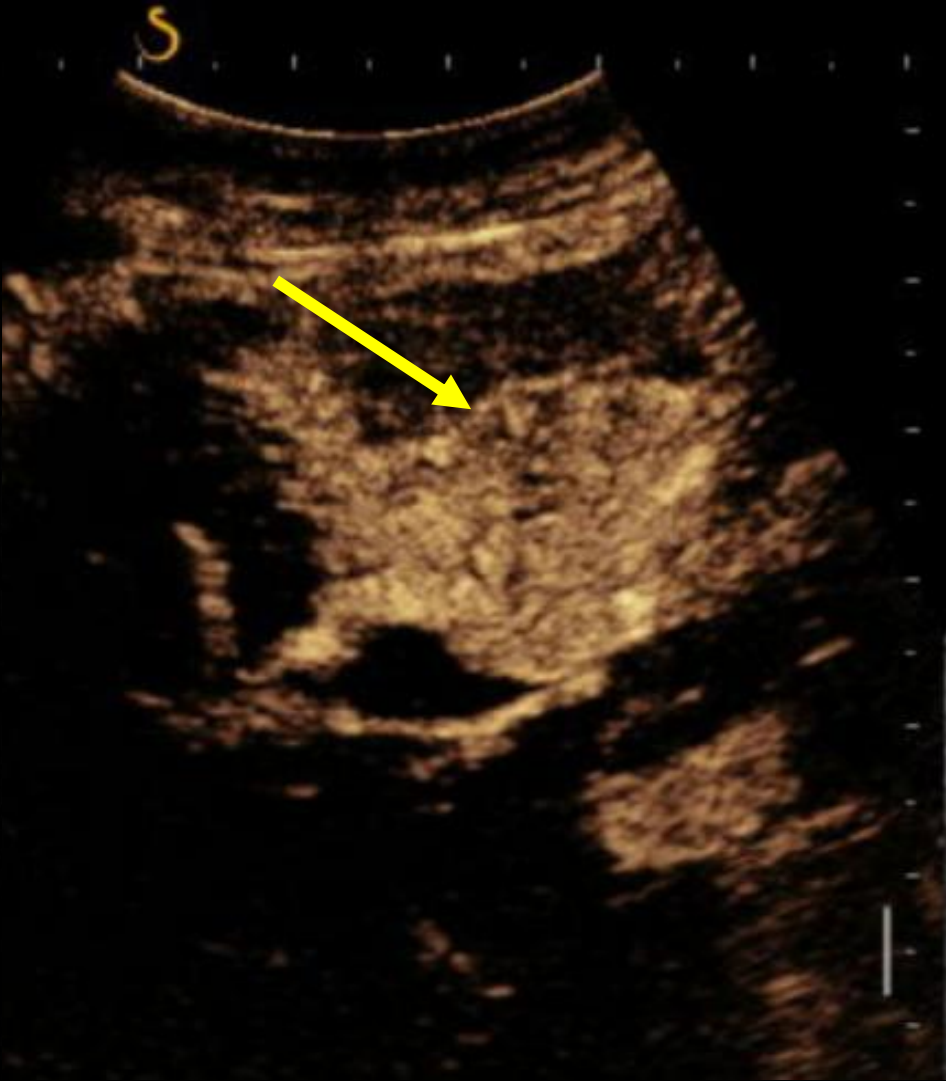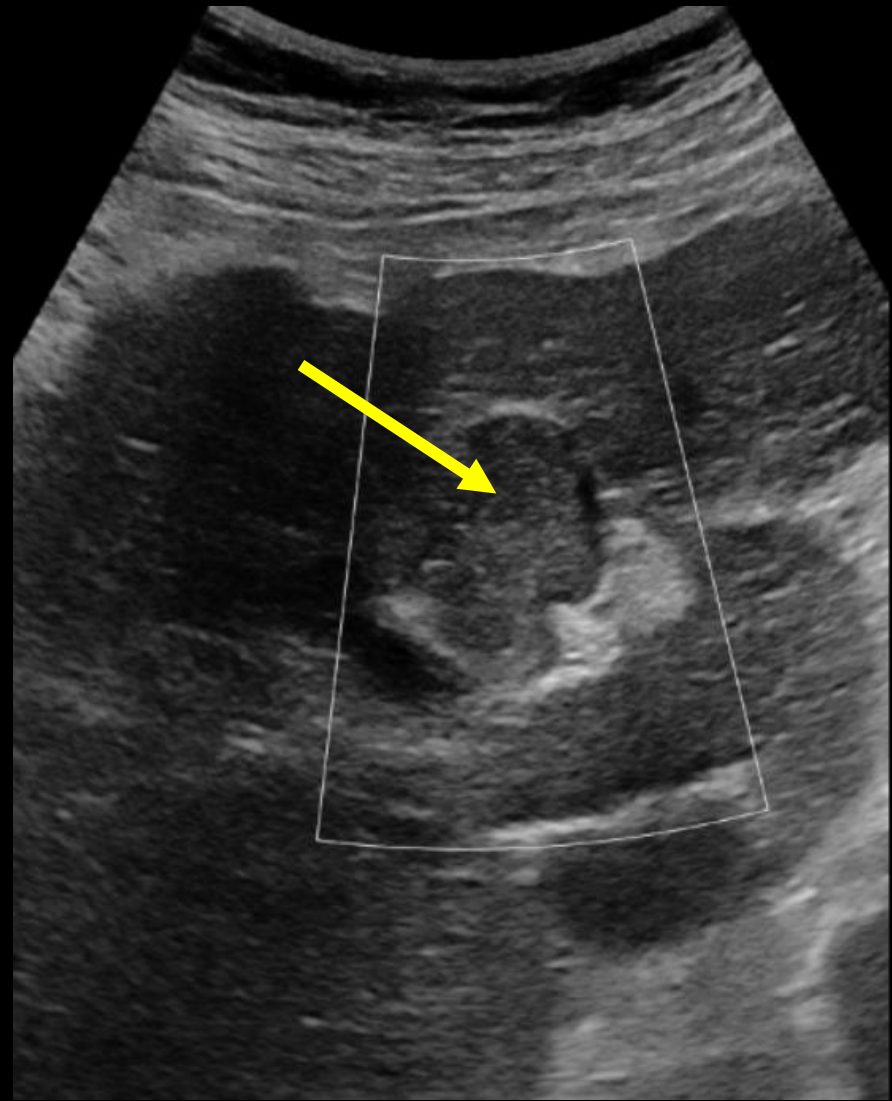
If not obvious: CEUS



Wash-in

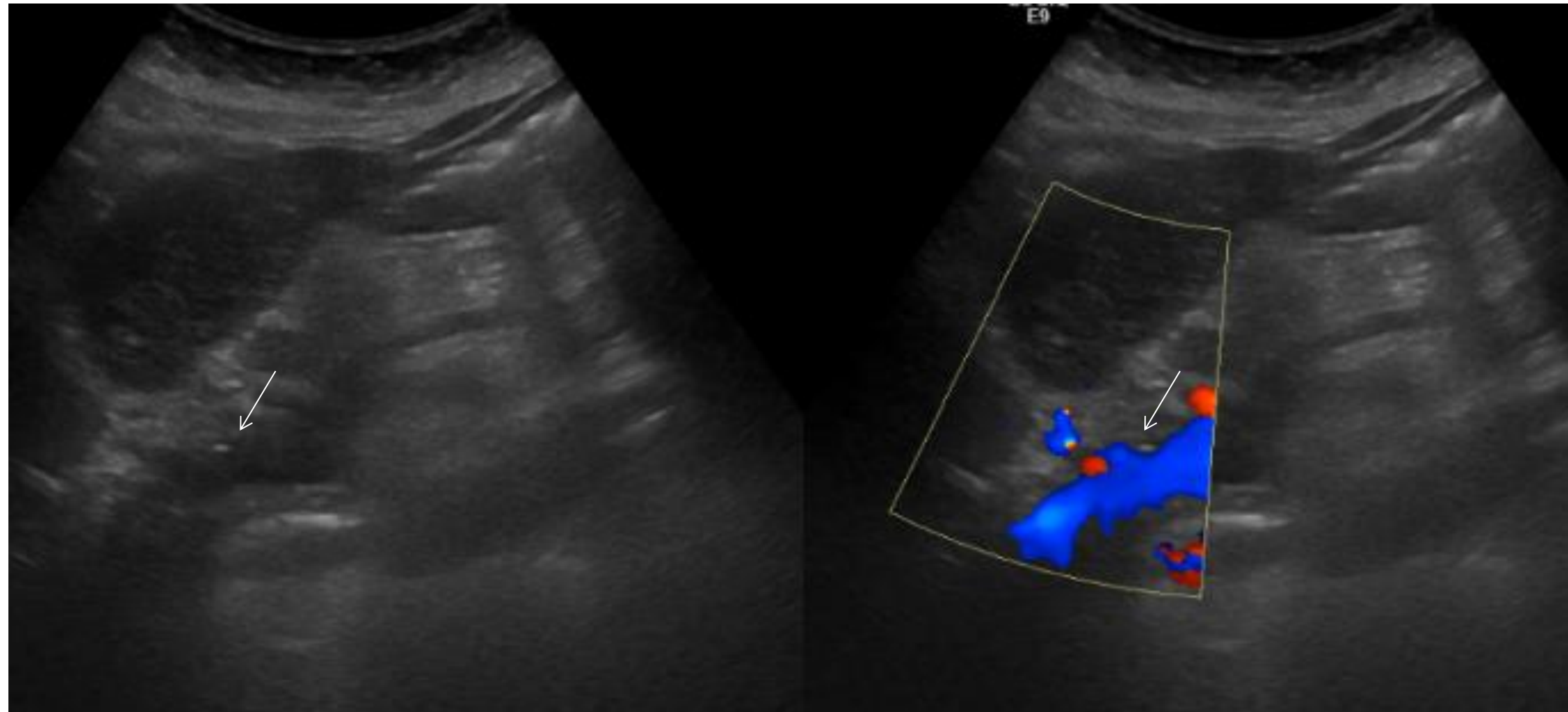


Wash-out



Chronic PVT

Calcifications of the wall: specific sign

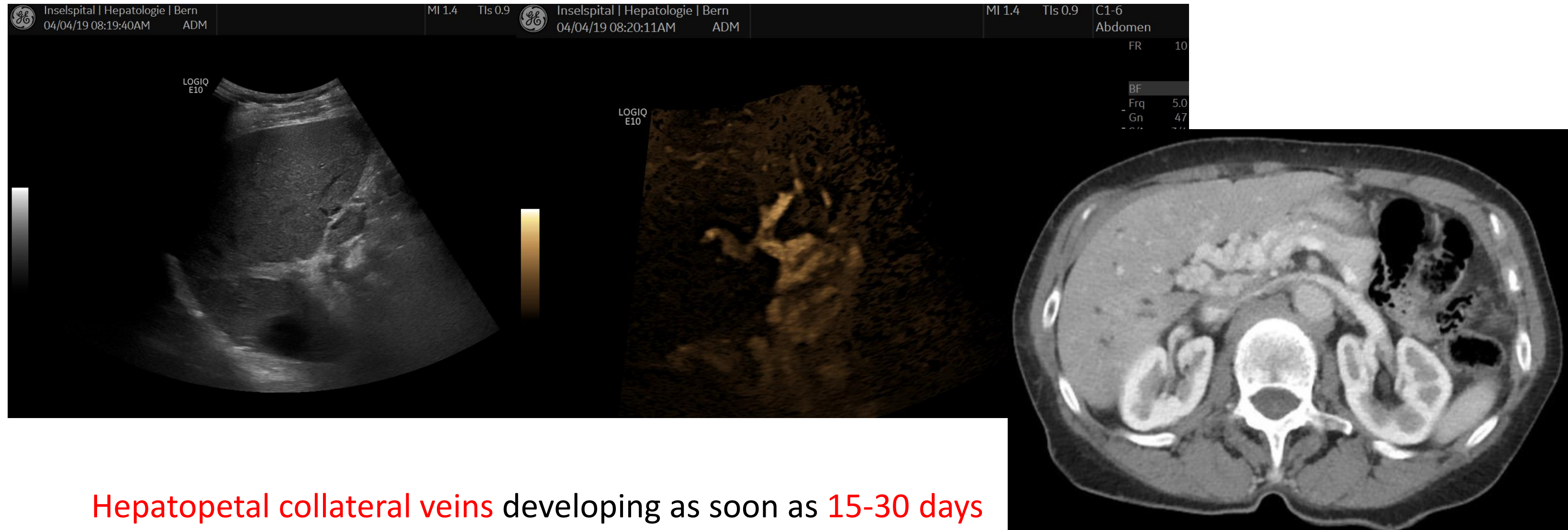

Even if the vessel is patent, calcifications indicate that thrombosis had occurred

Important in candidate to LT

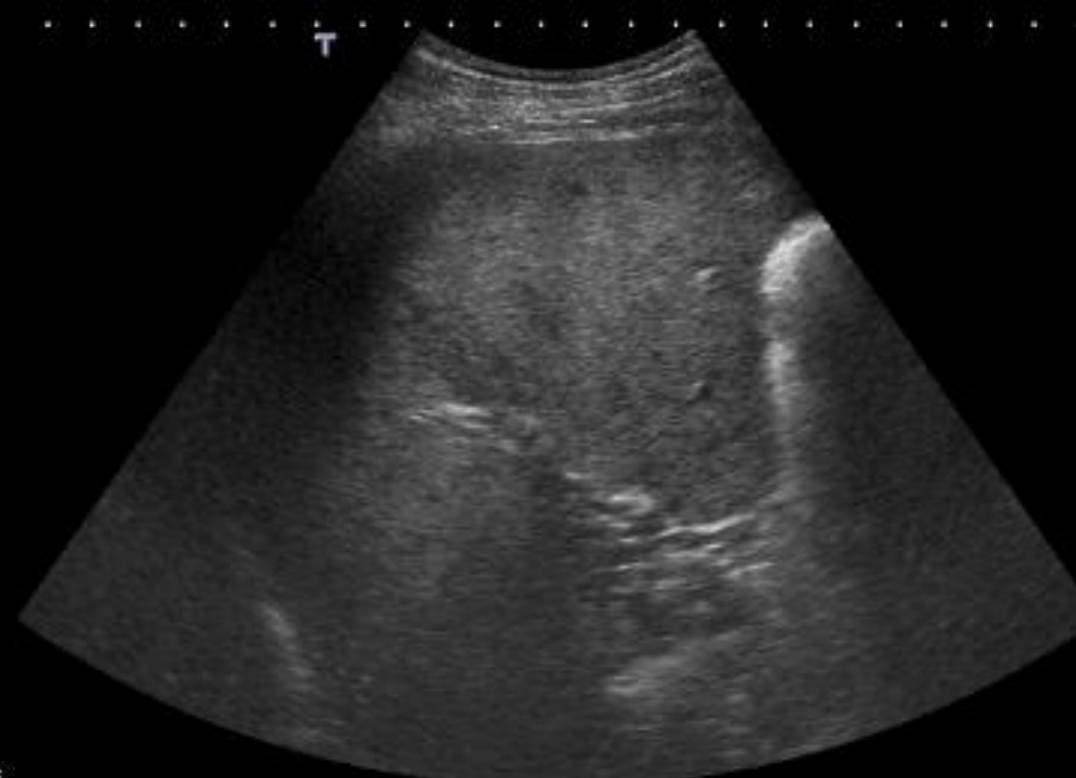
(PV wall more prone to dissection)

Cavernous Transformation

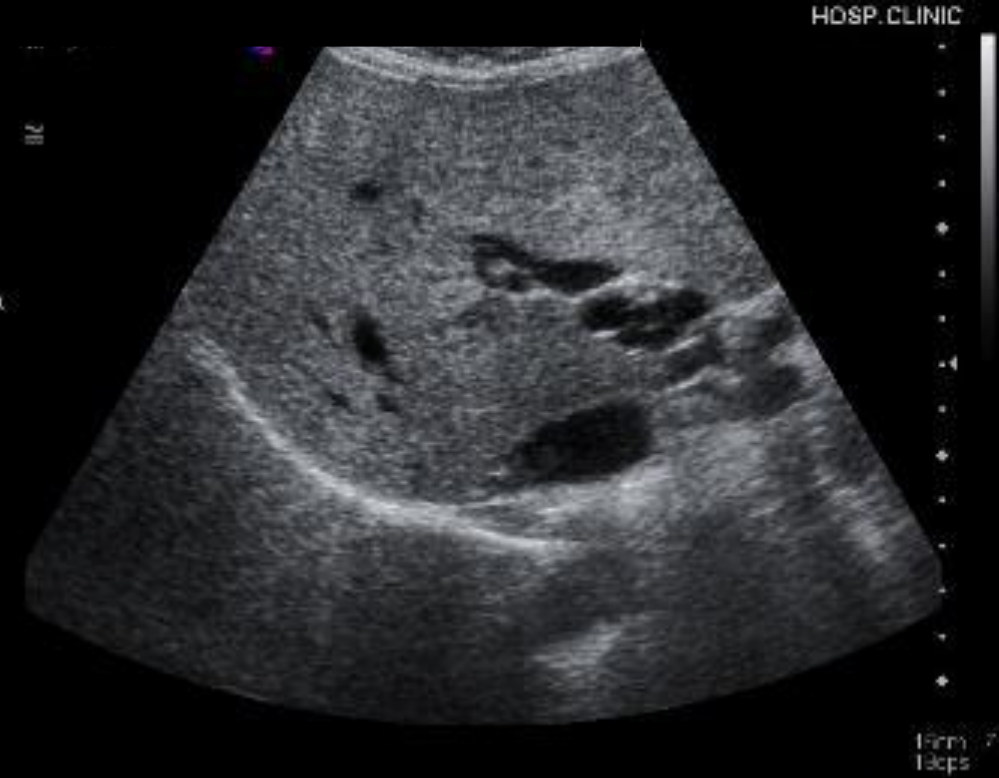

Hepatopetal collateral veins developing as soon as **15-30 days** after the onset of portal vein thrombosis.

Zhang, World J Gastroenterol, 2011; reviewed in Berzigotti et al. Nature Reviews Gastroenterol Hepatol 2014; De Gottardi, Berzigotti, et al. Ultraschall in Med, 2018; Rodrigues et al. Abdom Radiol 2018



30/09/2008
17:44:42
CH4-1
GENERAL
18fps
THI/2.2 MHz
1dB/DR80
MapH/VEAps
RS1/SCAps



HOSP. CLINIC

18cm
7
18cps

SIEMENS

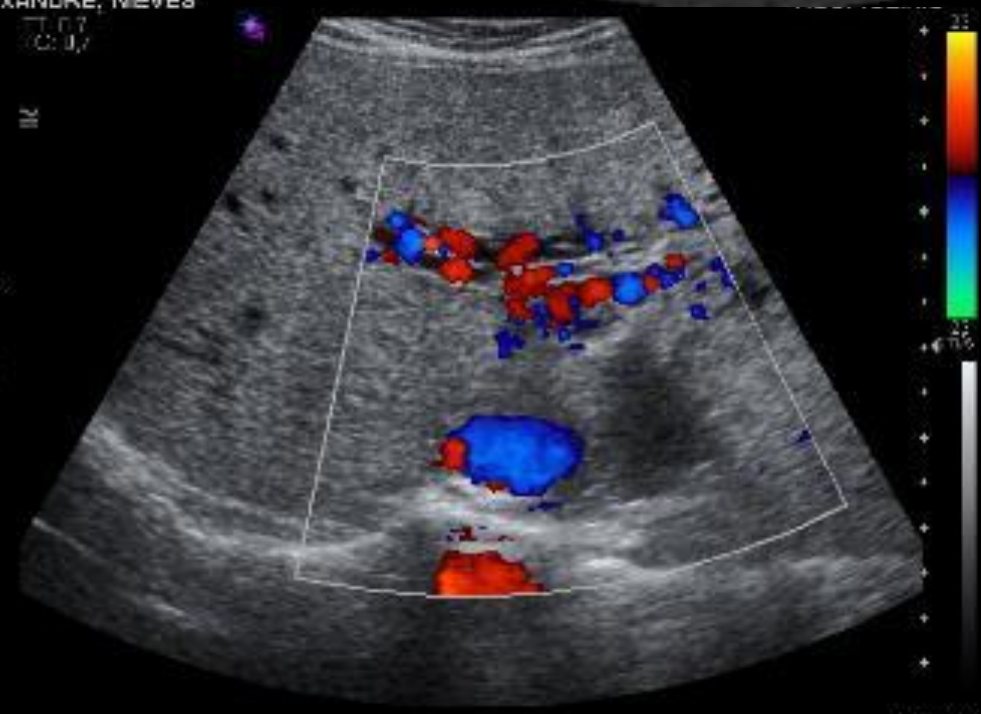
Cavernous Transformation

RIVERA ALEIXANDRE, NIEVES
0070347111
30/09/2008
17:44:28

CH4-1
GENERAL
7fps

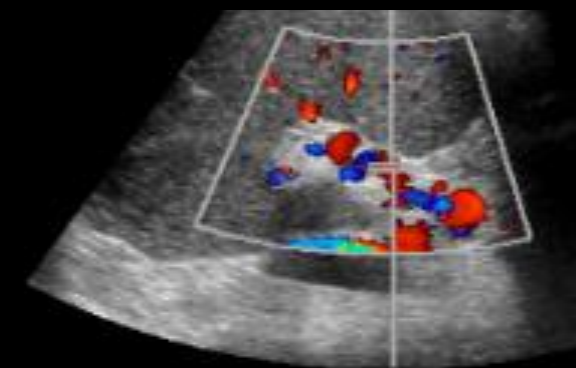
THI/2.2 MHz
1dB/DR80
MapH/VEAps
RS1/SCAps

VEL/1.8 MHz
Flow Gen
-5dB/P2
PRF1099/F2

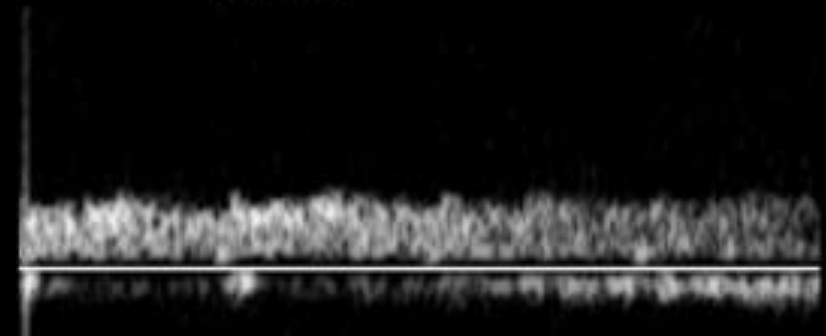


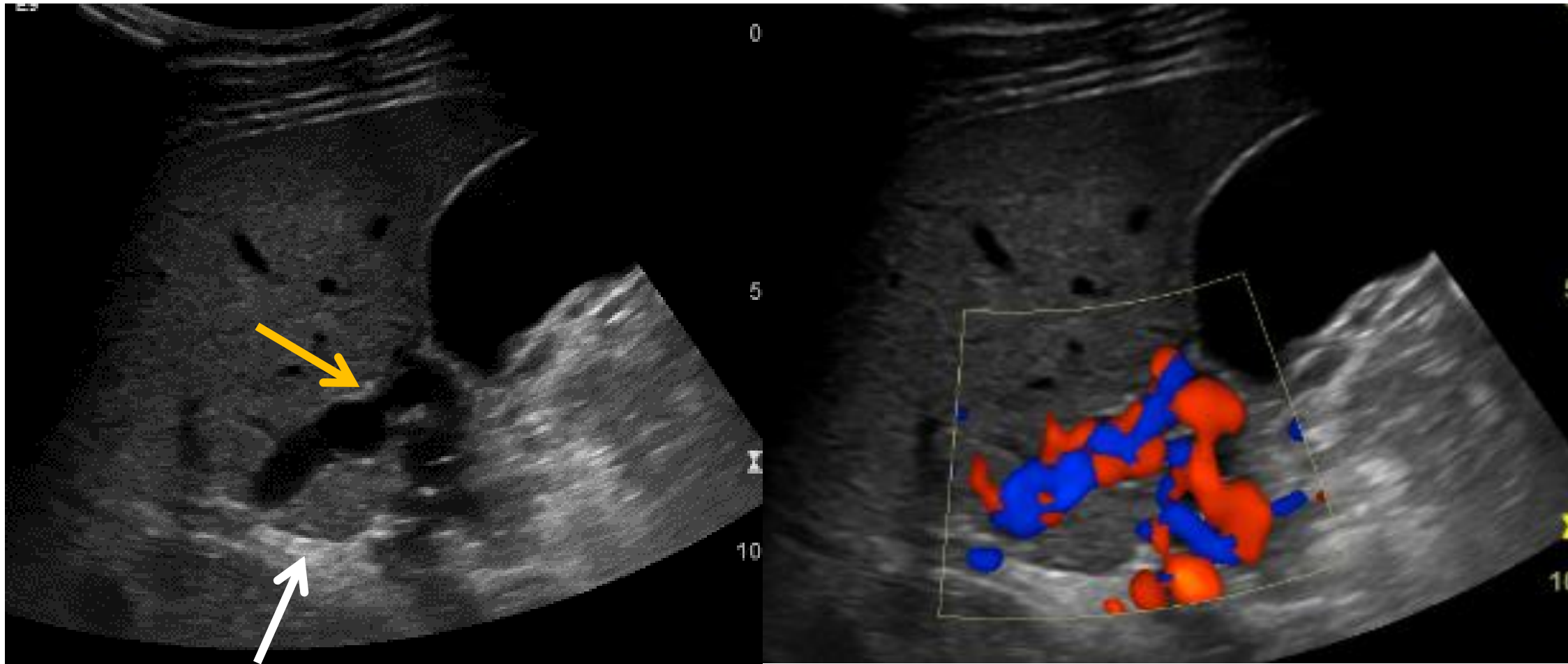
18cm
7
18cps

SIEMENS



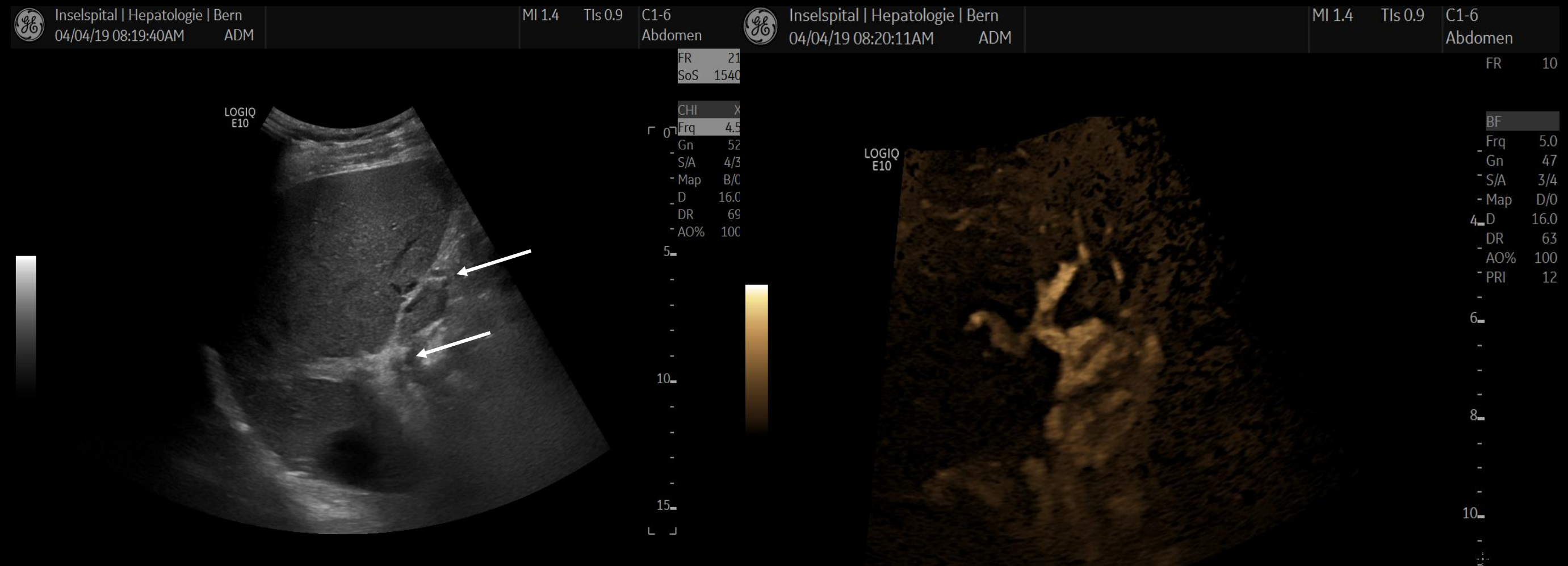
87mm



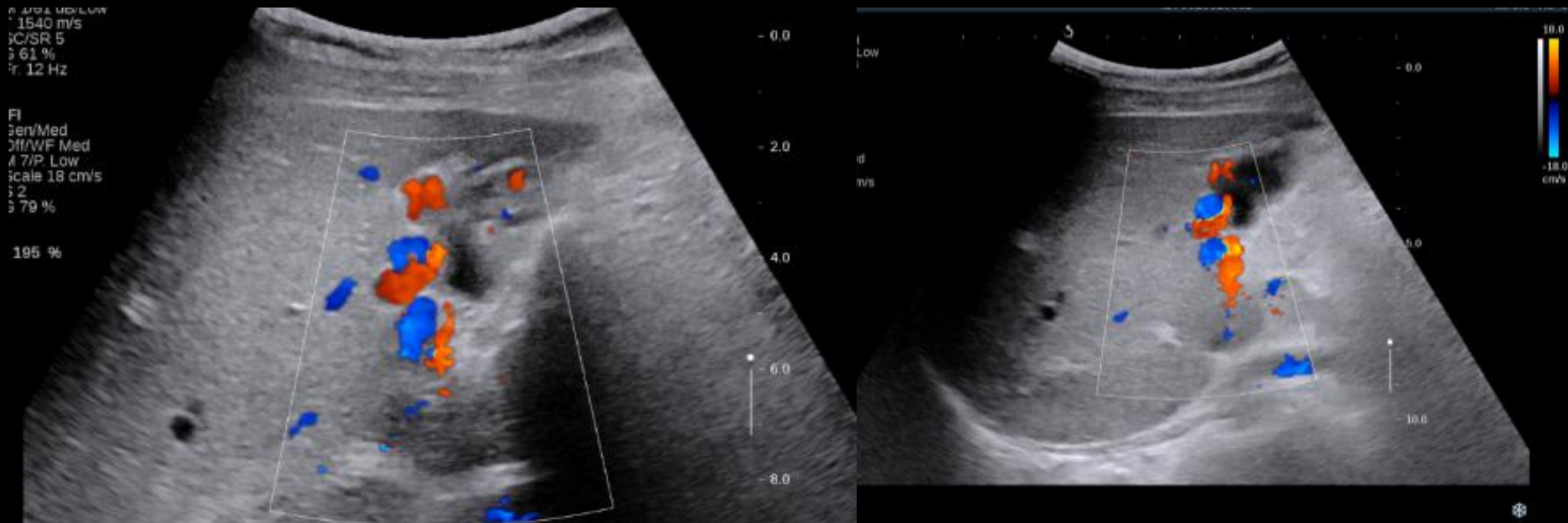


White arrow: native portal vein shows complete old thrombosis replaced by fibrous tissue
Yellow arrow: Cavernous transformation; note that a large dominant vessel (9 mm) is observed

DETAILED DEPICTION OF THE CAVERNOUS TRANSFORMATION OF THE PV



Collaterals at the gallbladder wall



Take home messages: BCS and PVT

- **Ultrasound/CDUS** is the first line technique to be performed in case of suspected BCS and PVT, allowing > 90% accuracy in expert hands
- In difficult cases the use of **CEUS** allows a better evaluation of PV and HVs patency
- Look for signs of chronic disease (collateral circulation; calcifications in PVT)
- Assessment of **extension** of PVT needs to be done (**CT or MRI**); mapping of **collaterals** can be done with these techniques
- Imaging **report** should describe patency/thrombosis of all vessels at first examination AND in the follow-up

Vascular liver diseases @Baveno VII consensus

Budd-Chiari syndrome

Portal vein thrombosis

Congenital vascular malformations


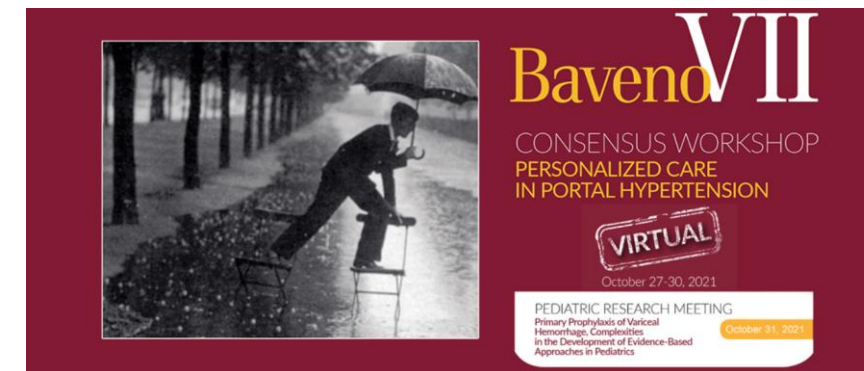
Porto-sinusoidal vascular disorder (PSVD)

Hepatic artery diseases (aneurysm, thrombosis)

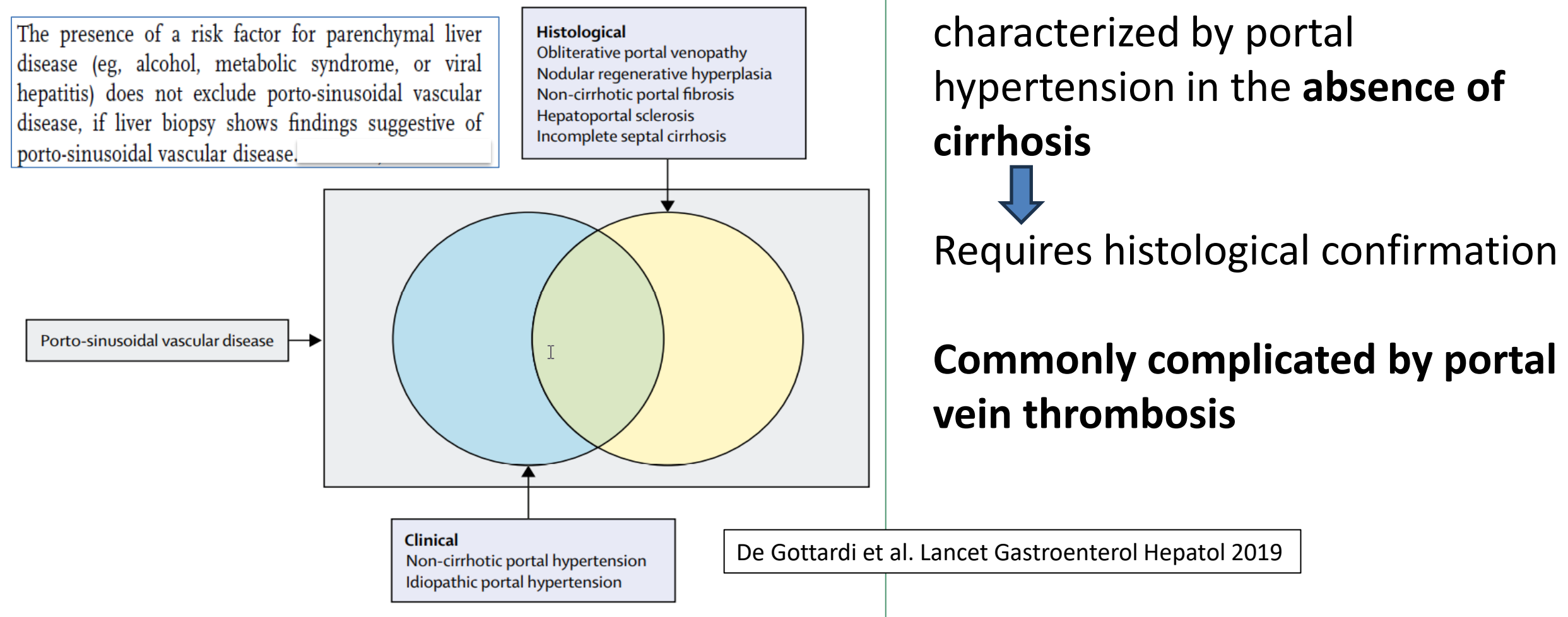
Sinusoidal obstruction syndrome

Radiation-induced liver disease

Peliosis hepatis and sinusoidal dilatation

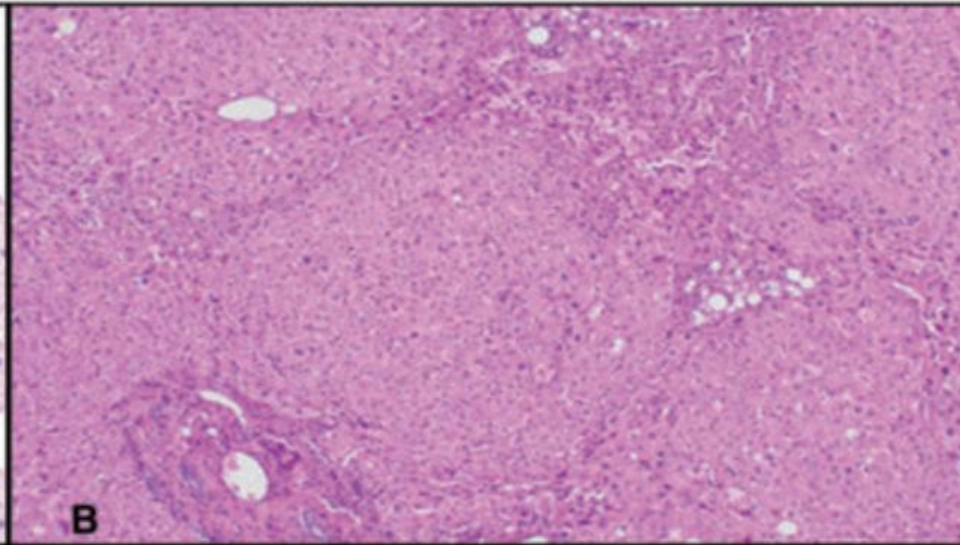
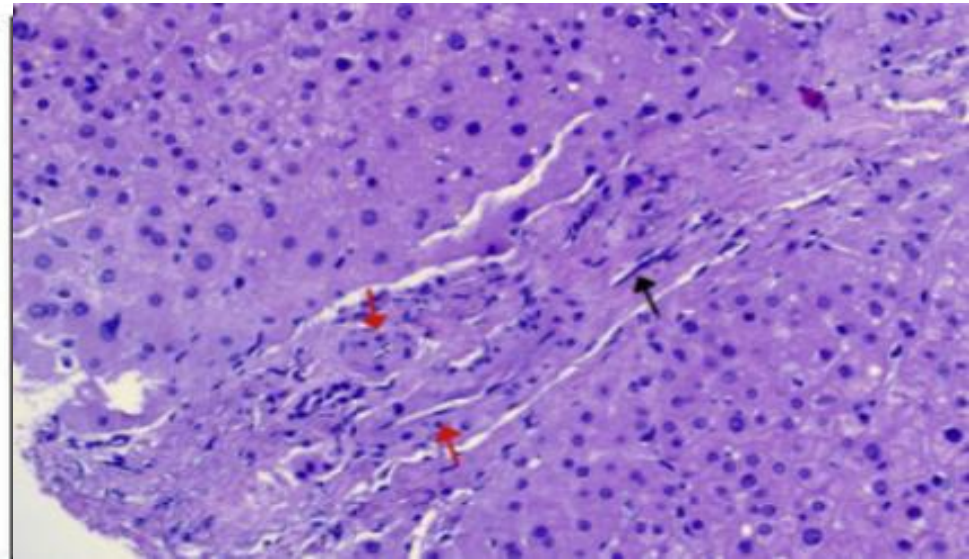


Porto-sinusoidal vascular disease (PSVD)/ Non cirrhotic portal fibrosis (NCPF)



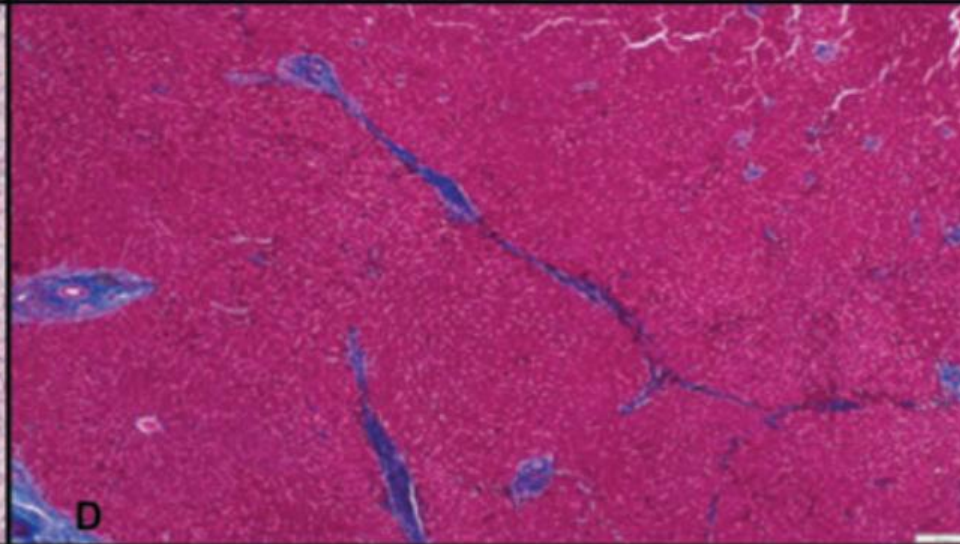
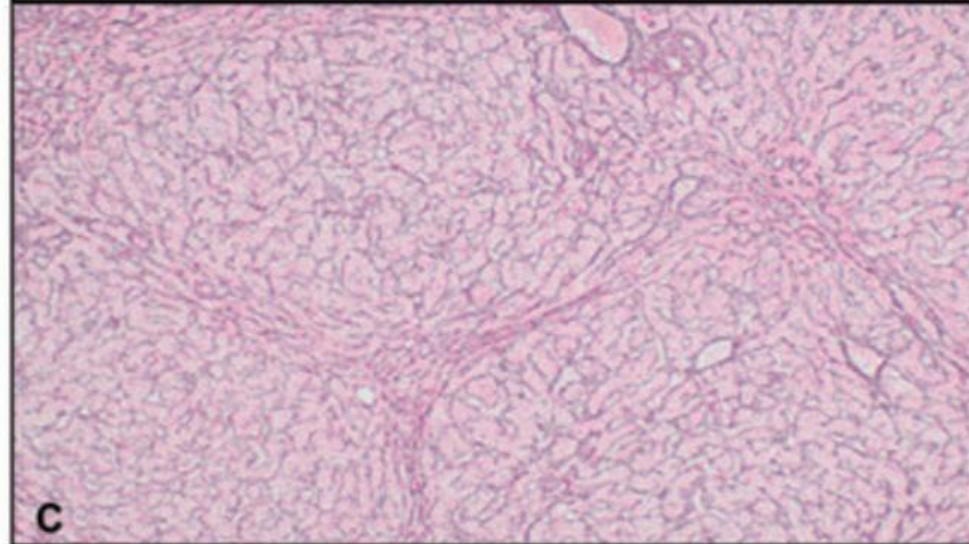
Specific histological signs

Obliterative
portal
venopathy (PV
stenosis)



NRH (HE)

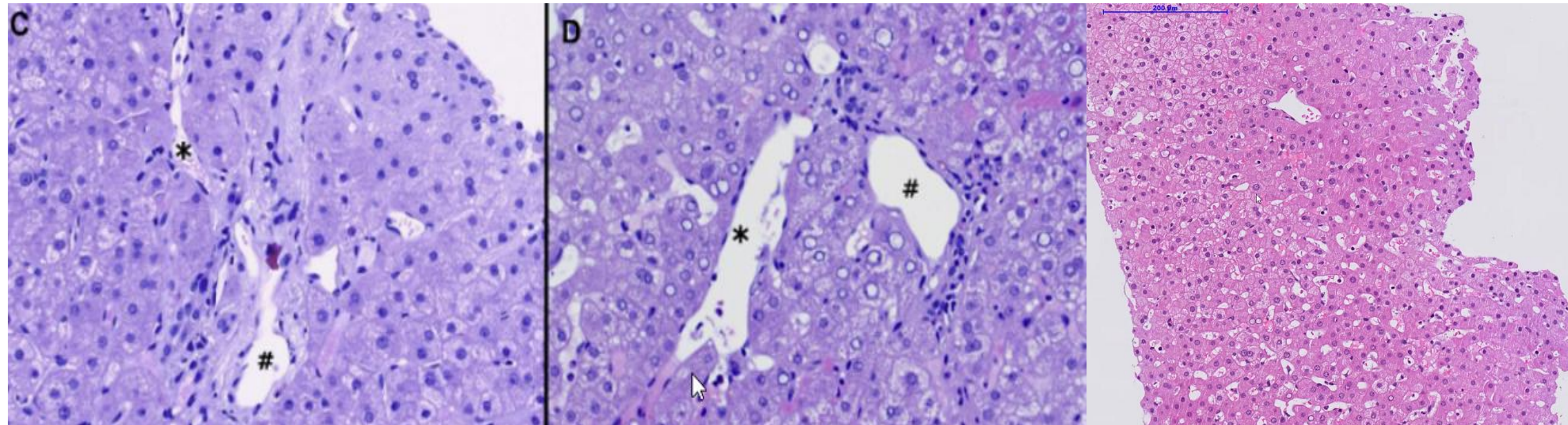
NRH
(reticulin
staining)



Incomplete
septal
fibrosis

<https://www.valdig.eu/wp-content/uploads/2025/11/PSVD-Atlas.pdf>

Non-specific histological signs



Periportal
vascular
channels

Architectural
abnormality of the
PV (e.g. herniation)

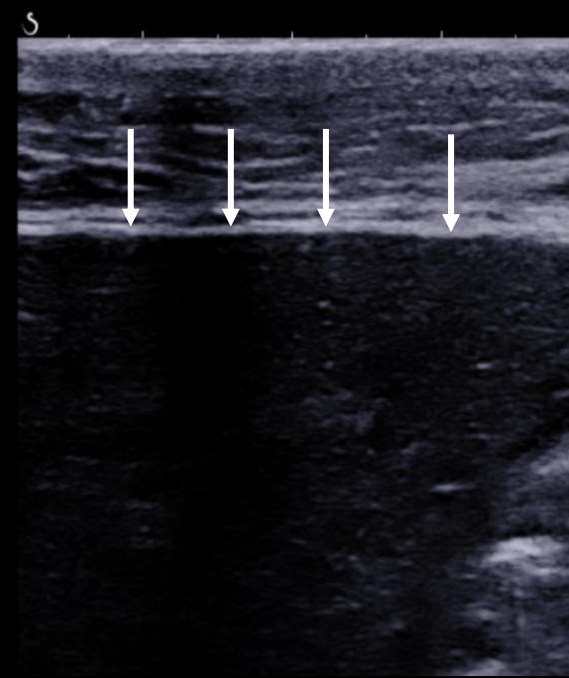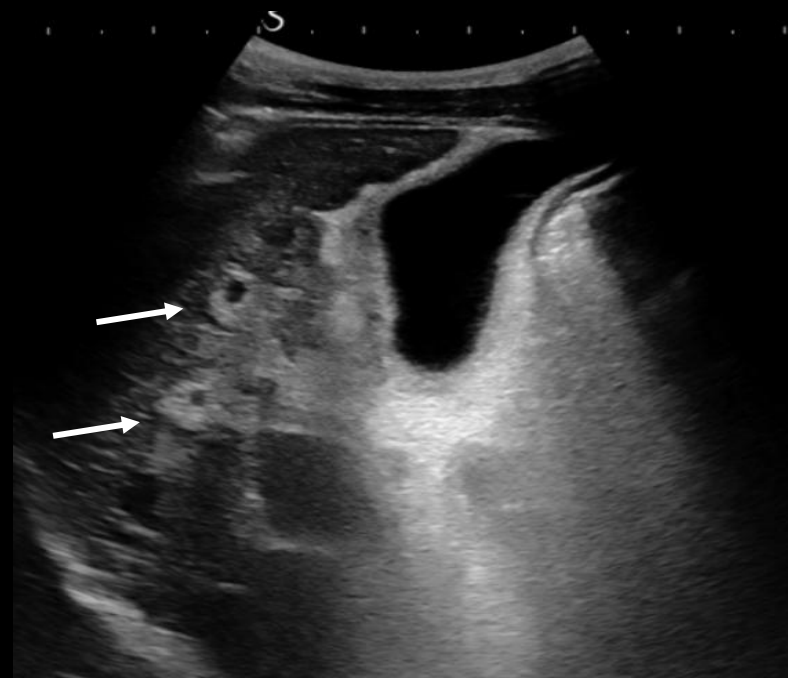
Non-zonal
sinusoidal
dilatation

<https://www.valdig.eu/wp-content/uploads/2025/11/PSVD-Atlas.pdf>

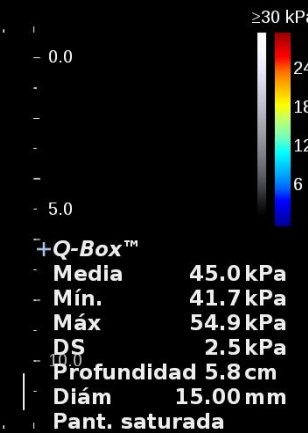
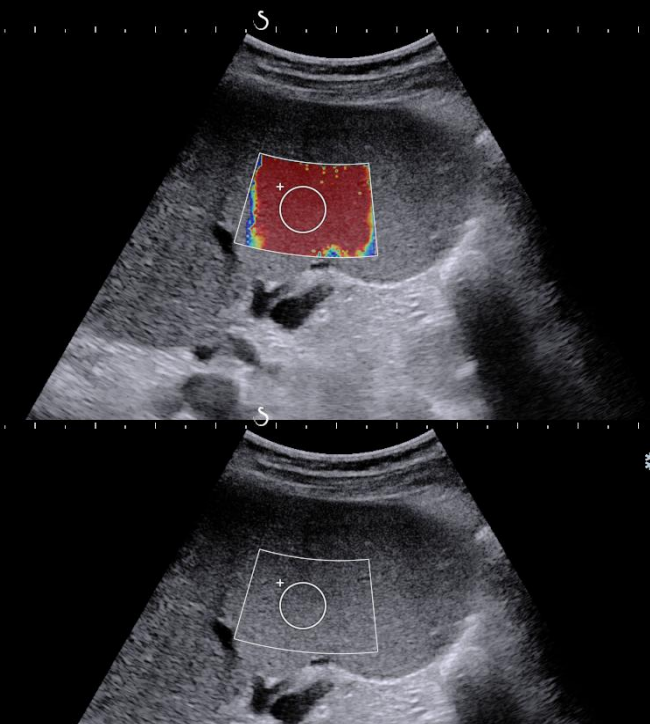
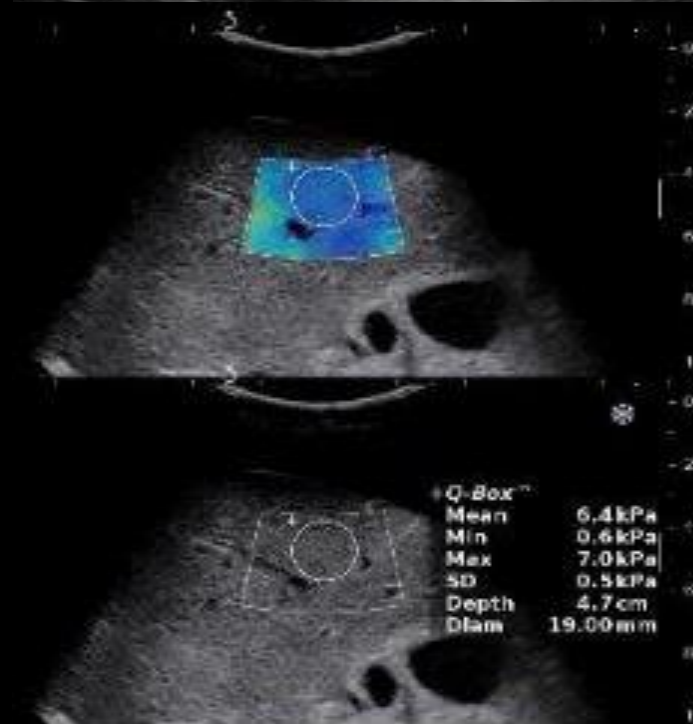Associated conditions

Hematological and Thrombophilic conditions	Genetic diseases	Autoimmune diseases/gut diseases	Exposure to chemotherapy/ Toxic substances	Acquired or congenital immune defects
<p>Myeloproliferative neoplasm (PV, ET, MDS)</p> <p>Lymphoprolif. Diseases</p> <ul style="list-style-type: none"> -Hodgkin and NH lymphoma, - CLL - MM <p>Spherocytosis</p> <p>Protein S, C def.</p> <p>Antiphospholipid antibodies/LAC</p> <p>Factor V Leiden</p> <p>Prothrombin mutation;</p> <p>ADAMTS13 def.</p>	<p>Cystic fibrosis</p> <p>Turner's disease</p> <p>Adams Oliver syndrome</p> <p>+ genetic mutations in familiar cases: TERT variants, KCNN3 variants, FOPV variants</p> <p style="text-align: center; color: blue;">See EASL CPGs on VLD J Hepatol 2025 (in press)</p>	<p>Rheumatoid arthritis</p> <p>Systemic lupus erythematosus</p> <p>Systemic sclerosis</p> <p>Scleroderma</p> <p>IBD (RC; Crohn)</p> <p>Celiac disease</p>	<p>Oxaliplatin</p> <p>Azathioprine</p> <p>6-thioguanine</p> <p>Arsenic</p> <p>Busulfan</p> <p>Cytosine arabinoside</p> <p>Cyclophosphamide</p> <p>Bleomycin</p> <p>Chlorambucil</p> <p>Doxyrubicin</p> <p>Carmustine</p>	<p>Primary antibody-deficiency syndrome</p> <ul style="list-style-type: none"> - Common variable immunodeficiency - X-linked agammaglobulinemia (XLA) - Selective IgA deficiency - IgG subclass deficiency - Specific antibody deficiency <p>Acquired immune deficiency (HIV infection)</p>

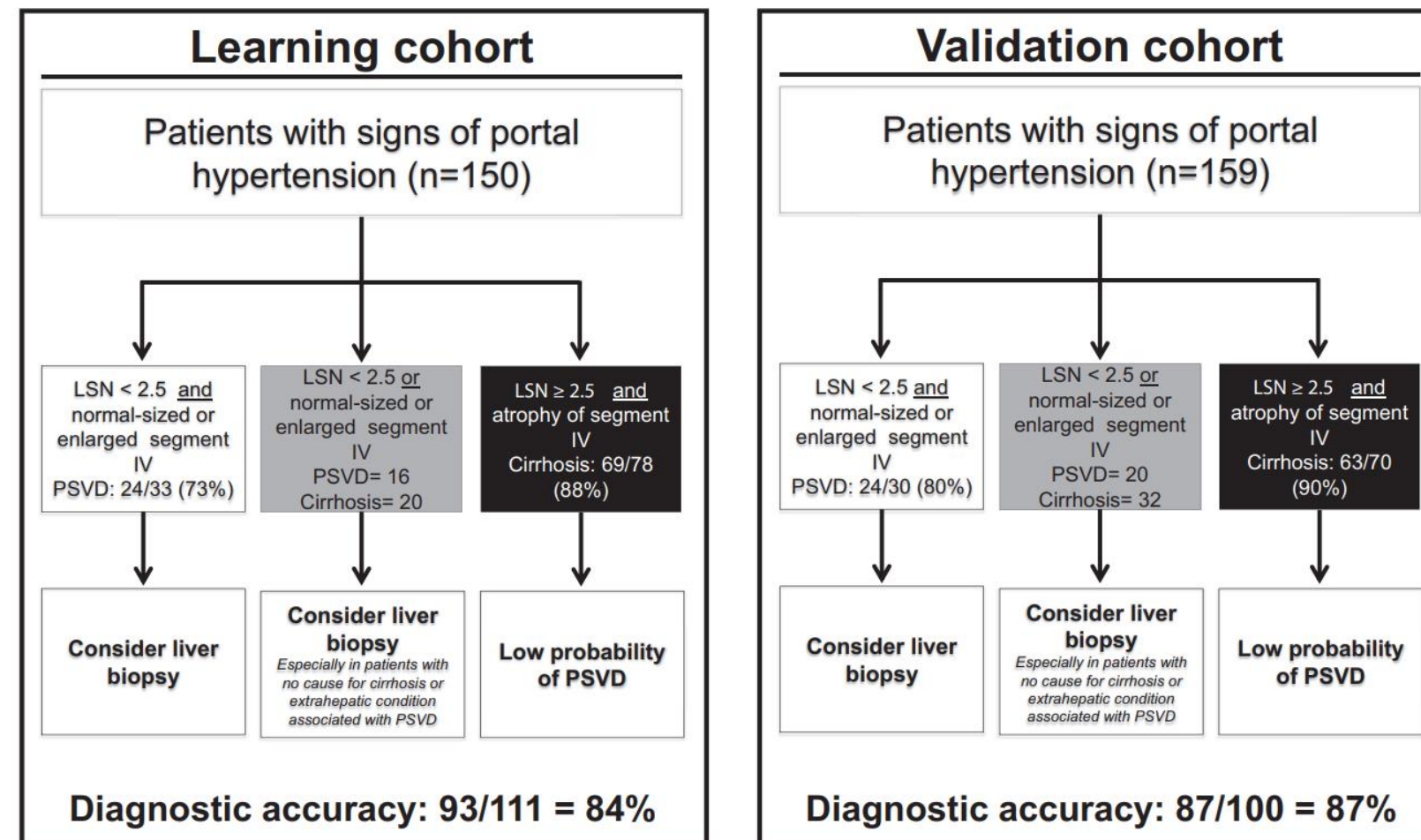
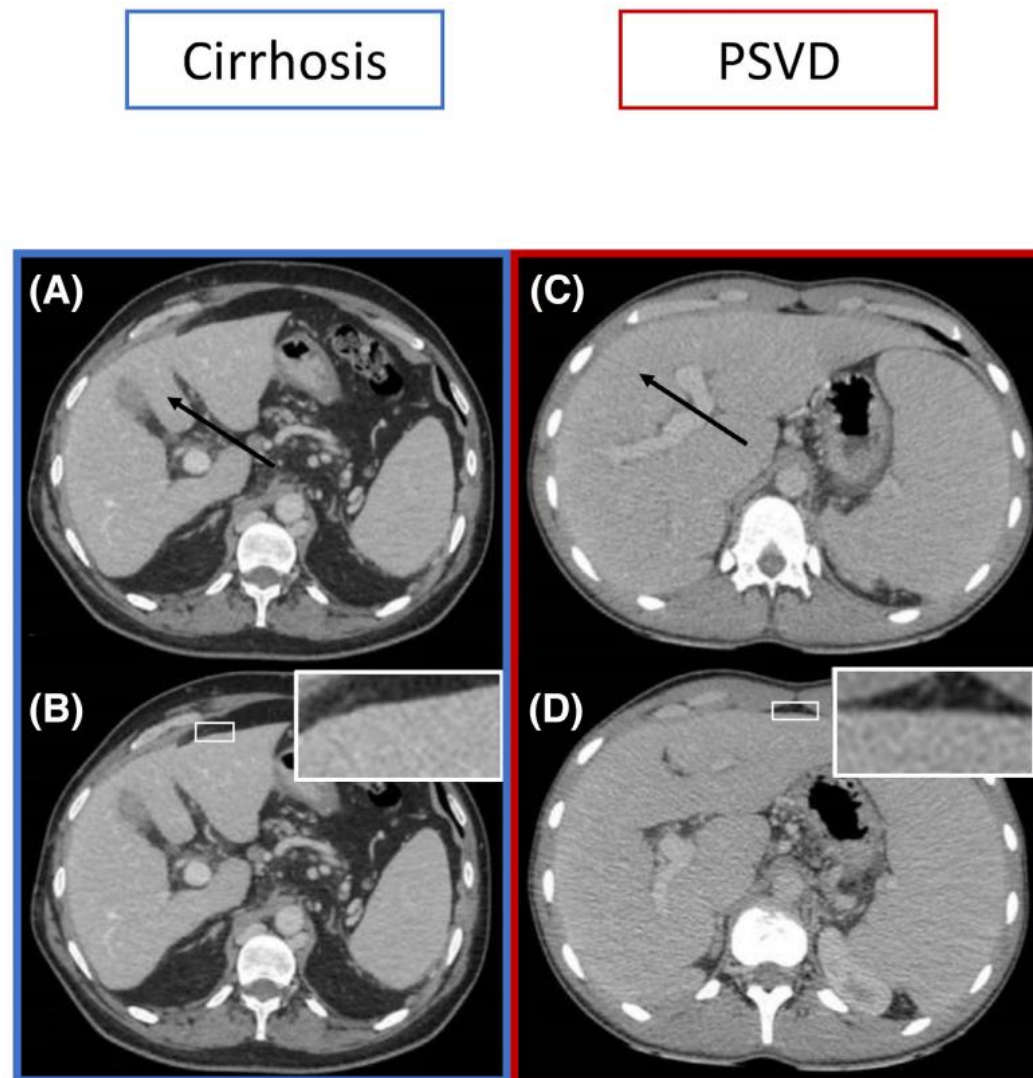
US signs of PSVD/IPH



Thickening of portal walls
(Schistosomiasis-like)
+ dysmorphic liver
(«Almond shaped»)
+ splenomegaly and PH
+ low LSM

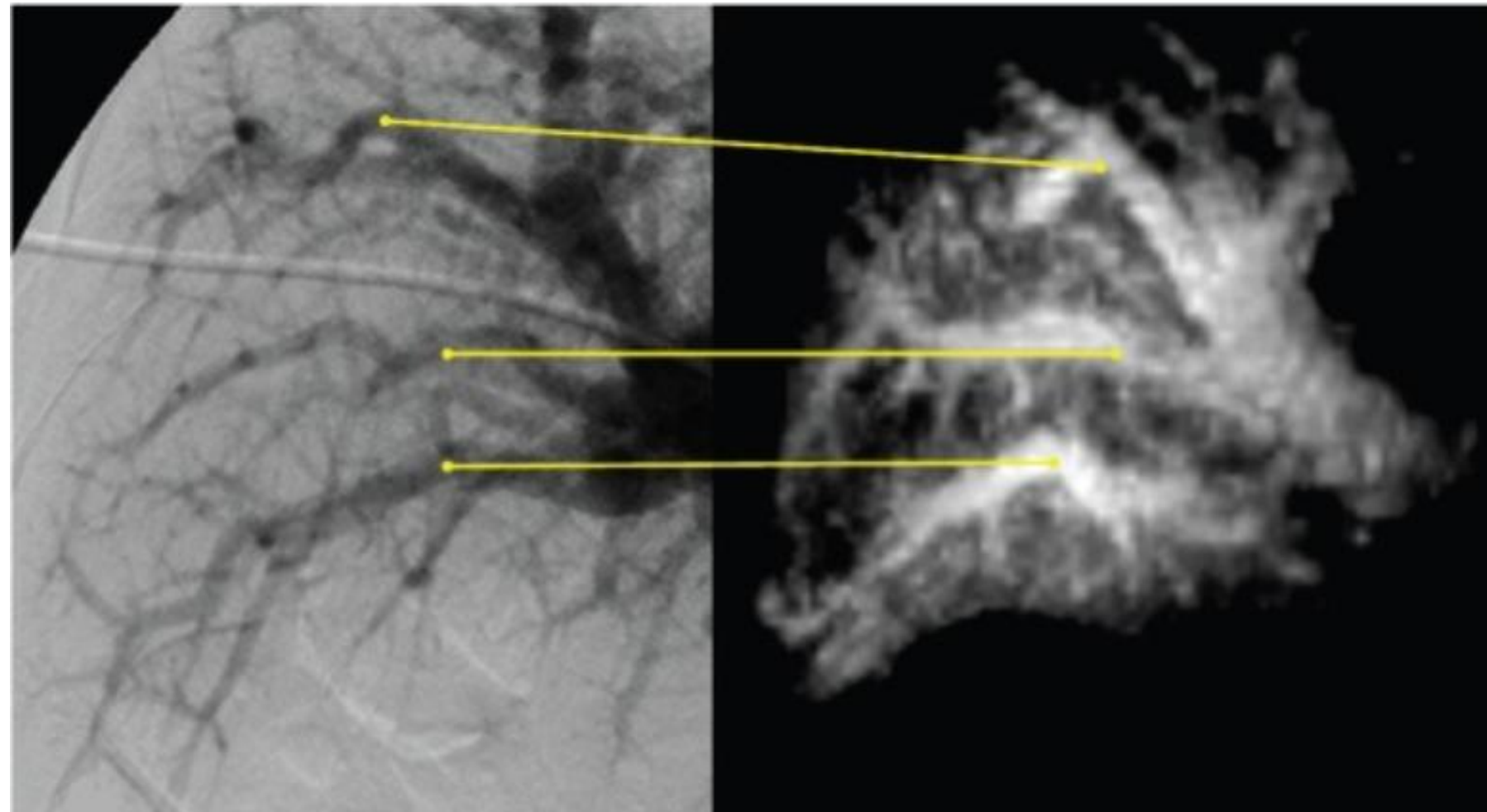


Liver surface nodularity on CT can be useful



Valainathan SR et al. Hepatology 2022

CEUS using Sonazoid for non-invasive portography to diagnose PSVD/IPH



5 with biopsy-proven IPH

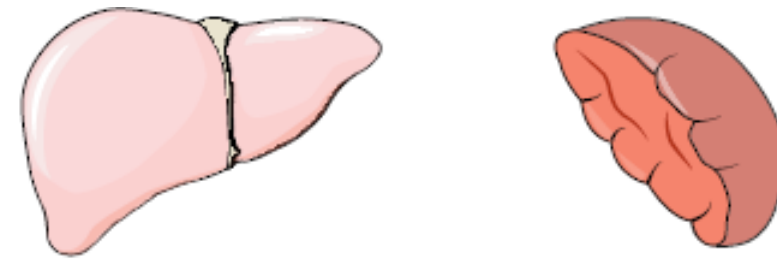
3D CEUS compared to invasive portography

Maruyama et al.
Br J Radiol 2012

1. Periportal delayed enhancement in the liver strongly suggests PSVD
2. In the post-vascular phase greater accumulation of intrahepatic microbubbles

Maruyama et al. Radiology 2009
Maruyama et al. Hep Intern 2012

Elastography in PSVD: very useful



Site of increased resistance to portal flow	Liver stiffness	Spleen stiffness
PSVD: intrahepatic pre-sinusoidal	< 10 kPa Is 97% specific	Elevated If < 40 kPa + Bilirubin < 1 mg/dl no HRV

**No cirrhosis
or severe
liver
fibrosis!**

62

Elkrief L et al Hepatology 2021

Moga L et al Hepatology 2024

Conditions excluded from the definition of PSVD

History of bone marrow transplantation

Budd-Chiari syndrome or hepatic venous outflow obstruction

Hepatic schistosomiasis diagnosed on liver biopsy

Cardiac failure or Fontan surgery

Abernethy syndrome

Hereditary hemorrhagic telangiectasia

Chronic cholestatic diseases

Liver infiltration by tumor cells

Sarcoidosis

Congenital hepatic fibrosis

These are not
included in the
term PSVD

<https://www.thieme-connect.de/products/ejournals/pdf/10.1055/s-0031-1299145.pdf?update=true>

Ultraschall bei Pfortaderhochdruck – Teil 2 – und EFSUMB-Empfehlungen zur Durchführung und Dokumentation von Ultraschalluntersuchungen bei Pfortaderhochdruck

Ultrasound in Portal Hypertension – Part 2 – and EFSUMB Recommendations for the Performance and Reporting of Ultrasound Examinations in Portal Hypertension



Ultraschall Med 2012

Autoren

A. Berzigotti^{1,2}, F. Piscaglia^{*3}, and the EFSUMB



<https://learning.easl.eu/course/index.php?categoryid=2>

Clinical Practice Guidelines

JOURNAL OF HEPATOLOGY

EASL Clinical Practice Guidelines on vascular diseases of the liver[☆]

European Association for the Study of the Liver^{*}

<https://baveno8.org/registration/>

The logo features a yellow background with a blue vertical bar on the left. The text 'Baveno' is in a large, blue, lowercase sans-serif font, with 'VIII' in a smaller, blue, uppercase serif font to its right. Below this, 'CONSENSUS WORKSHOP' is written in a thin, blue, uppercase sans-serif font, followed by the tagline 'Advancing consensus in portal hypertension' in a slightly larger, blue, uppercase sans-serif font. At the bottom, a dark blue rectangular box contains the text 'BAVENO, ITALY 27-28 March 2026' in white and yellow, and 'PEDIATRIC SYMPOSIUM 29 March' in white and yellow, preceded by two white icons of a person's face.

Baveno
COOPERATION
an EASL Consortium

baveno VIII
CONSENSUS WORKSHOP
Advancing consensus in portal hypertension

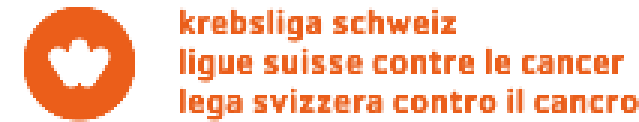
BAVENO, ITALY 27-28 March 2026

  **PEDIATRIC SYMPOSIUM 29 March**

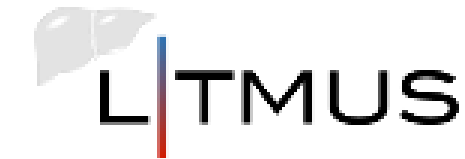Thank you for your attention

u^b

UNIVERSITÄT
BERN



Hepatological Diseases
(ERN RARE-LIVER)



LUCIE BOLTE

STIFTUNG

BMUS))