

BMUS General Ultrasound Study Day 2026

# Acute Pathology Of The Scrotum and Diagnostic Dilemmas In Practice

**Dean Huang**

Consultant Radiologist

Honorary Senior Lecturer

King's College Hospital, London

 KING'S HEALTH PARTNERS

# The Acute Scrotum: Differential Diagnosis

**Testicular (Spermatic Cord) Torsion**

**SURGICAL EMERGENCY**

*Absent flow on CDUS → theatre*

**Epididymo-Orchitis**

**Medical Rx**

*Hypervascularity on CDUS*

**Appendix Testis / Epididymis Torsion**

**Conservative**

*Blue dot sign; avascular nodule*

**Segmental Testicular Infarction**

**Dilemma**

*Tumour mimic — key diagnostic challenge*

**Scrotal Trauma**

**Surgery if rupture**

*Tunica albuginea integrity crucial*

**Intratesticular Haematoma / Abscess**

**Context-dependent**

*Mimic of tumour / torsion*

# Guidelines and Recommendations

## SCROTAL US



### EFSUMB Testis Multiparametric Ultrasound Guidelines

Michele Bertolotto, Simon Freeman, Dean Huang, Paul S Sidhu, Irene Campo, Dirk-André Clevert, Vikram Dogra, Francesco M Drudi, Thomas Fischer, Andrea M. Isidori, Christian Jensen, Markus H Lerchbaumer, Guntram Lock, Lotti Francesco, Malene R Pedersen, Carlotta Pozza, Subramaniyan Ramanathan, Jonathan Richenberg, Valeria Scotti, Paul Spiesecke, Christoph F Dietrich, Vito Cantisani.

Affiliations below.

DOI: 10.1055/a-2785-3267

Please cite this article as: Bertolotto M, Freeman S, Huang D et al. EFSUMB Testis Multiparametric Ultrasound Guidelines. *Ultraschall in der Medizin - European Journal of Ultrasound* 2026. doi: 10.1055/a-2785-3267



European Radiology (2021) 31:4918–4928  
<https://doi.org/10.1007/s00330-020-07631-w>

UROGENITAL

### Imaging in scrotal trauma: a European Society of Urogenital Radiology Scrotal and Penile Imaging Working Group (ESUR-SPIWG) position statement

Subramaniyan Ramanathan<sup>1,2</sup> · Michele Bertolotto<sup>3</sup> · Simon Freeman<sup>4</sup> · Jane Belfield<sup>5</sup> · Lorenzo E. Derchi<sup>6,7</sup> · Dean Y. Huang<sup>8</sup> · Francesco Lotti<sup>9</sup> · Karolina Markiet<sup>10</sup> · Olivera Nikolic<sup>11</sup> · Parvati Ramchandani<sup>12</sup> · Jonathan Richenberg<sup>13</sup> · Laurence Rocher<sup>14</sup> · Paul S. Sidhu<sup>8</sup> · Katarzyna Skrobisz<sup>15</sup> · Athina Tsili<sup>16</sup> · Pieter De Visschere<sup>17</sup> · Irene Campo<sup>18</sup> · Oliwia Kozak<sup>15</sup> · Vikram Dogra<sup>19</sup>

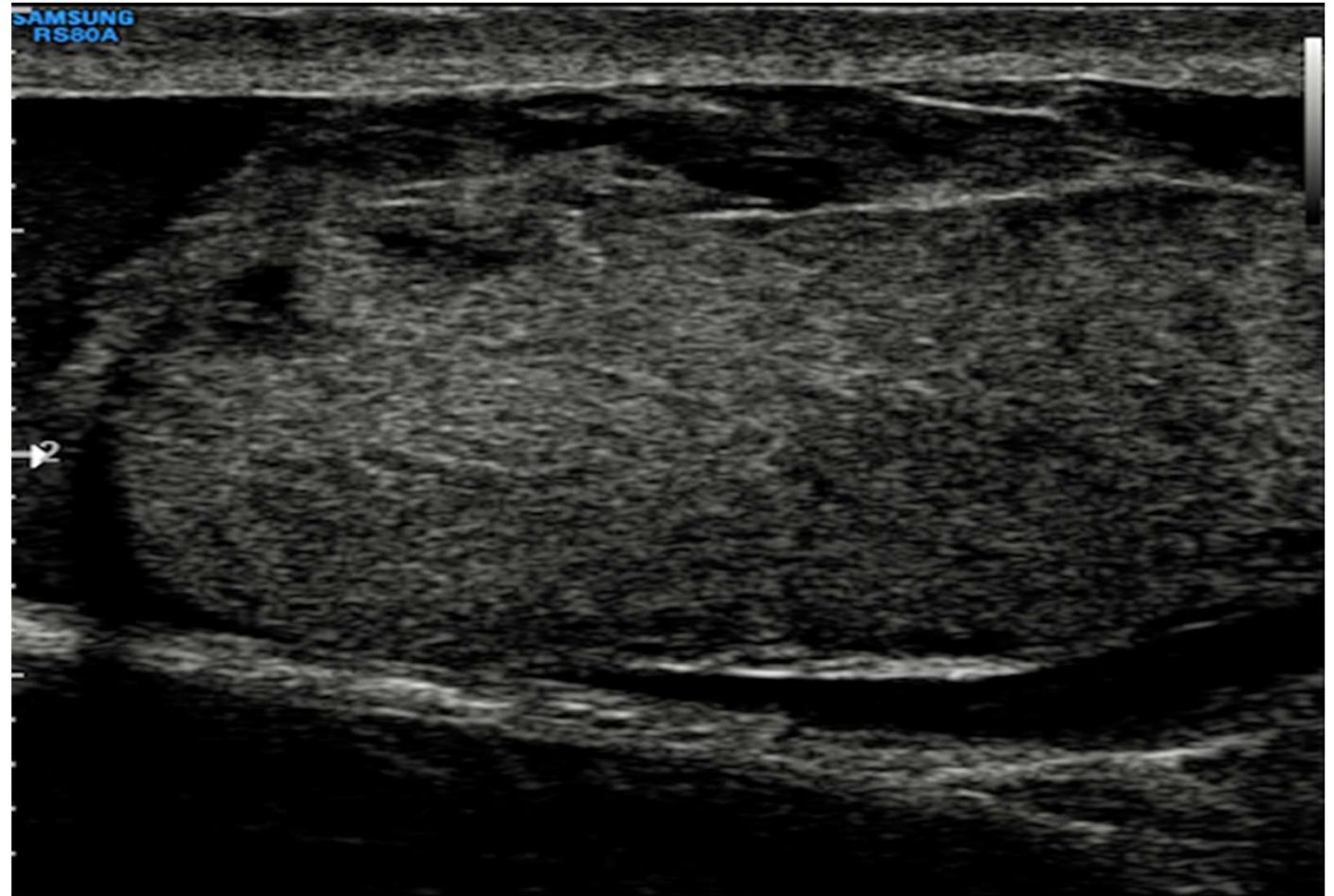
## TRAUMA

SECTION 01

# Trauma: Rupture and Viability

*Findings that matters*

# Scrotal Trauma



# Scrotal Trauma: Defining the Surgical Threshold

The single most important question: *Is the tunica albuginea intact?*

## What B-mode + Doppler Tell You

- **Parenchymal heterogeneity** — haemorrhage, oedema
- **Contour abnormality** + heterogeneous echotexture: 100% sensitive / 93.5% specific for rupture\*
- **Intratesticular haematoma**: iso/hyperechoic — difficult to distinguish from testis
- **Haematocele**: complex fluid — common; usually conservative
- **Limitation**: injured testis often hypovascular even if VIABLE — oedema compresses vessels

## Surgical Decision Criteria

Tunica albuginea disrupted?

**IMMEDIATE SURGERY**

Extrusion of testicular tissue?

**IMMEDIATE SURGERY**

Viable vs non-viable tissue?

**MVI/CEUS determines extent**

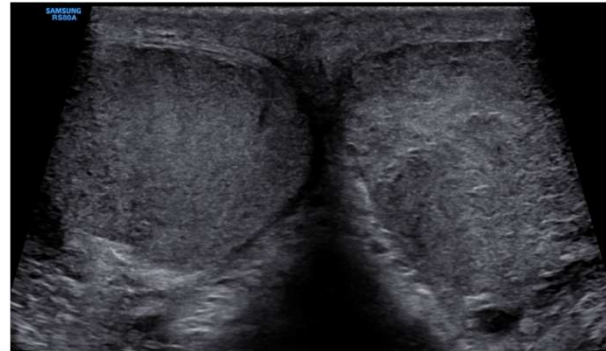
Haematocele with uncertainty?

**Consider exploration within 72h**

# Scrotal Trauma: Ultrasound Technique

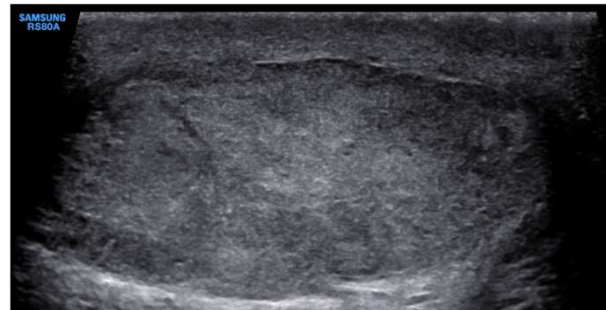
## Position statement 4

Transverse images including both testes should be acquired when anatomy permits, to allow side-to-side comparison of echotexture and vascularity.



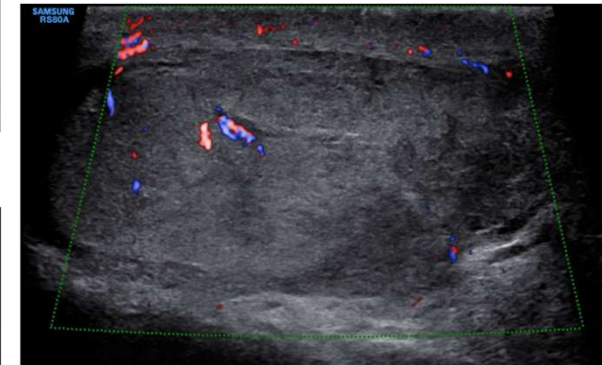
## Position statement 5

During US in scrotal trauma, it is important to document the continuity of echogenic tunica albuginea and smooth maintained testicular contour to rule out testicular rupture.



## Position statement 6

Changes in testis echotexture may be the clue of underlying testicular parenchymal injury.



# Scrotal Trauma: Testicular Rupture

## Position statement 5

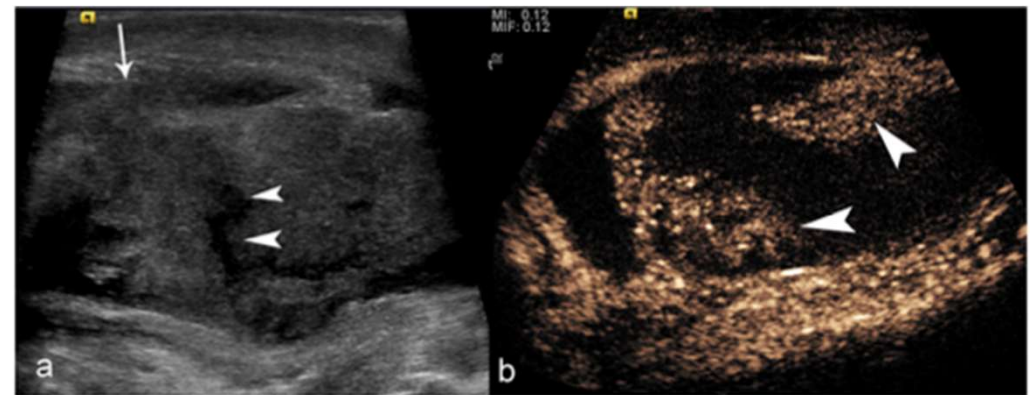
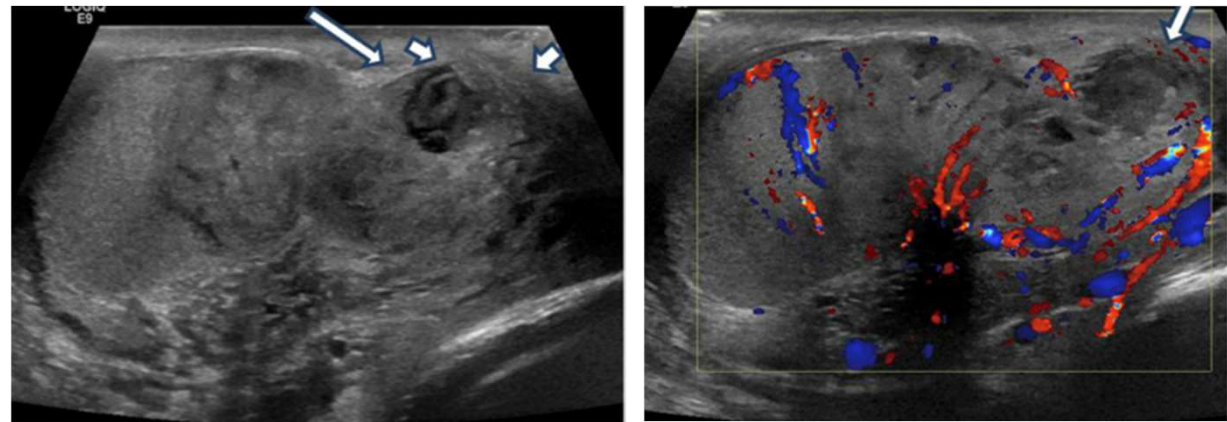
During US in scrotal trauma, it is important to document the continuity of echogenic tunica albuginea and smooth maintained testicular contour to rule out testicular rupture.

## Position statement 6

Changes in testis echotexture may be the clue of underlying testicular parenchymal injury.

## Position statement 7

Testicular vascularity should be demonstrated using CDUS as an aid in deciding between surgery and nonoperative management in mild injury and between orchiectomy and testicular repair in severe injury.



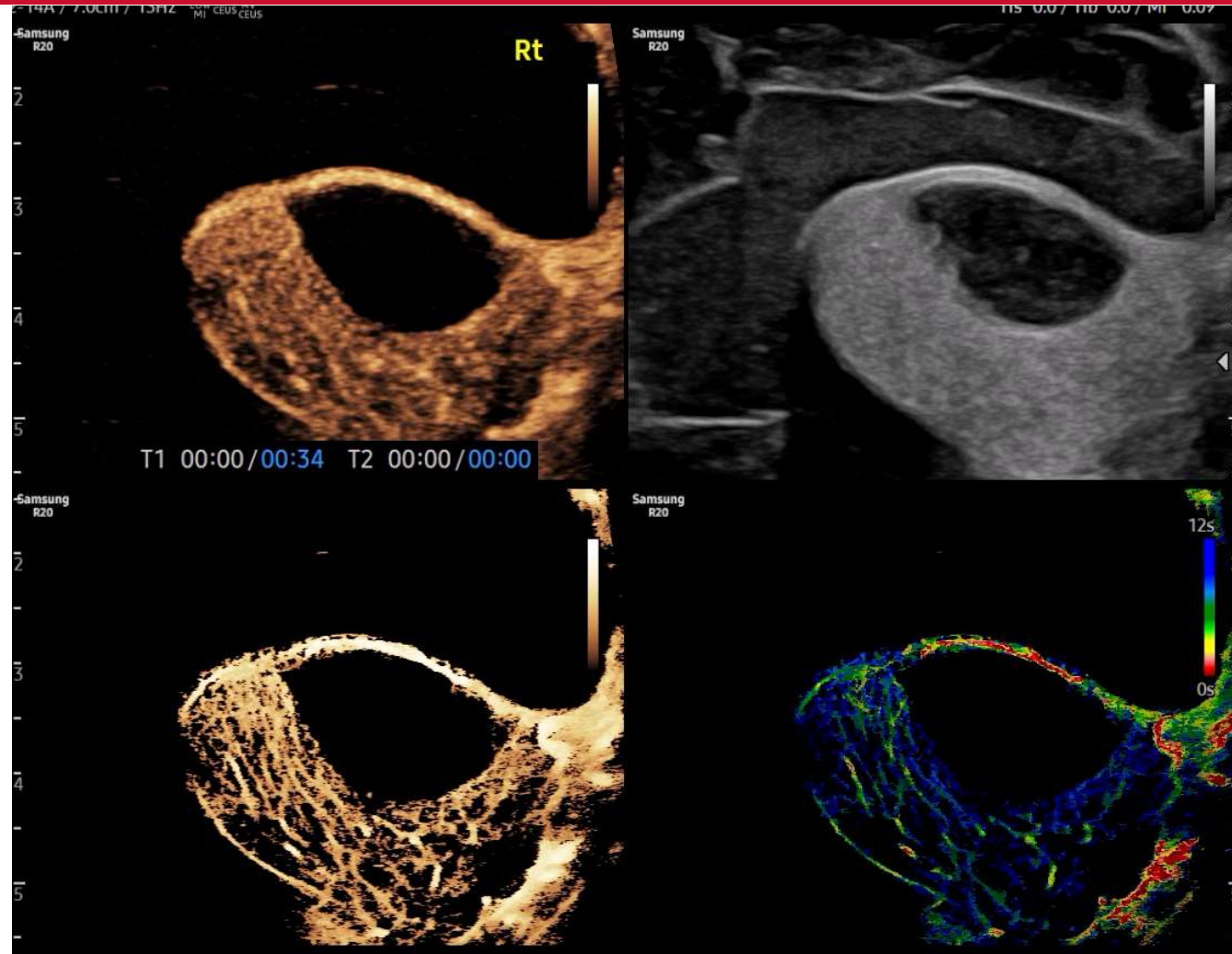
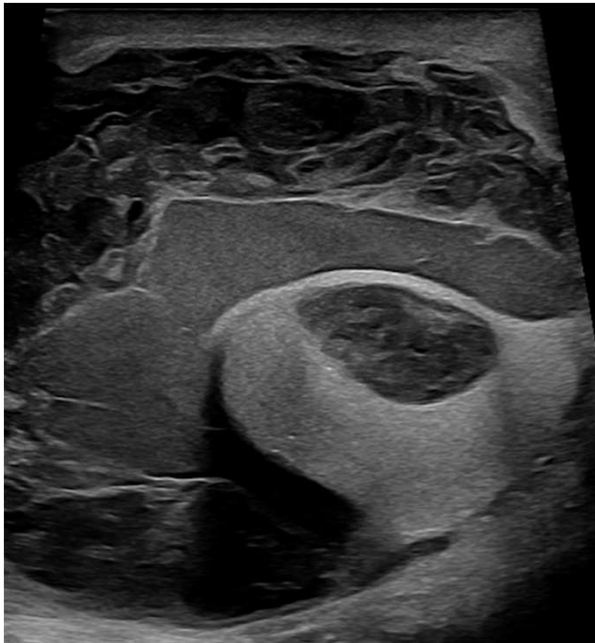
RAMANATHAN, S., BERLOLOTTO, M., FREEMAN, S., BELFIELD, J., DERCHI, L. E., HUANG, D. Y., LOTTI, F., MARKIET, K., NIKOLIC, O., RAMCHANDANI, P., RICHENBERG, J., ROCHER, L., SIDHU, P. S., SKROBISZ, K., TSILI, A., DE VISSCHERE, P., CAMPO, I., KOZAK, O. & DOGRA, V. 2021. Imaging in scrotal trauma: a European Society of Urogenital Radiology Scrotal and Penile Imaging Working Group (ESUR-SPIWG) position statement. *Eur Radiol.*

YUSUF, G. T., RAFAILIDIS, V., MOORE, S., HAWTHORN, B., FANG, C., HUANG, D. Y., SELLARS, M. E. & SIDHU, P. S. 2020. The role of contrast-enhanced ultrasound (CEUS) in the evaluation of scrotal trauma: a review. *Insights Imaging*, 11, 68.

# Scrotal Trauma: Haematoma and Haematocele

## Position statement 8

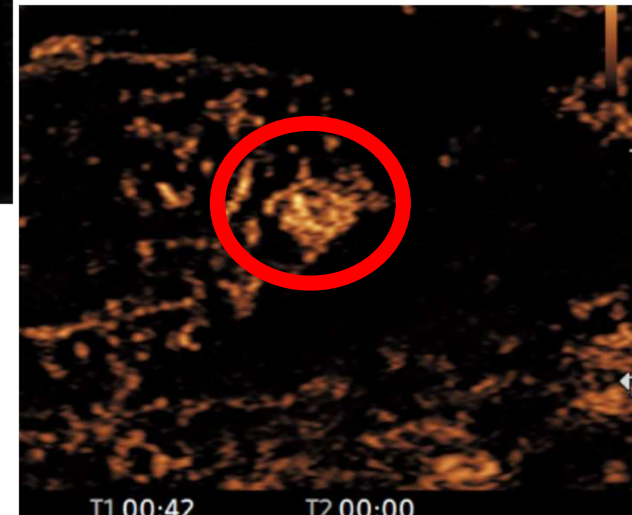
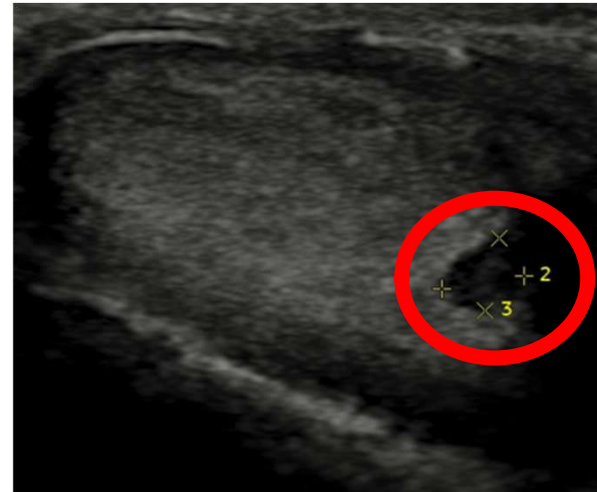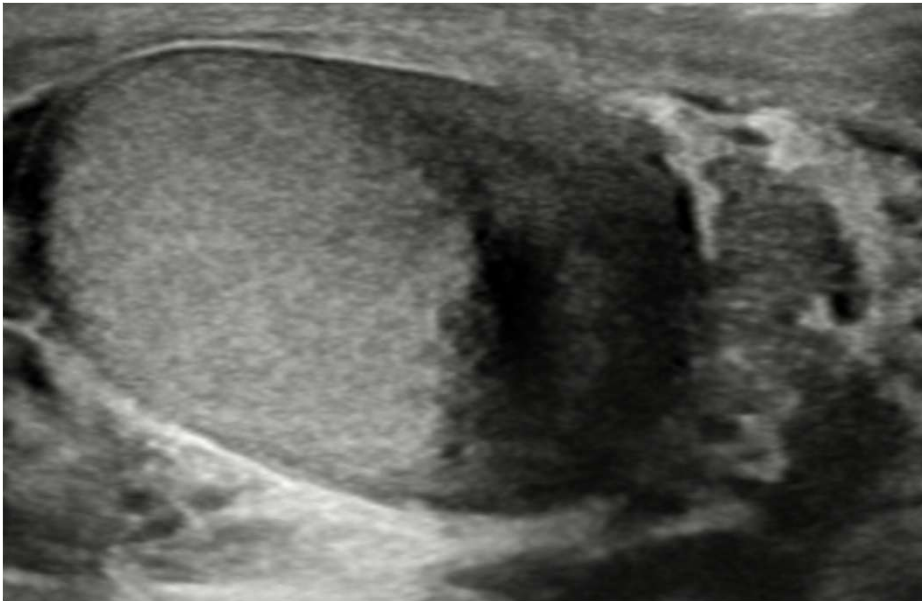
Although any intratesticular focal lesion in the setting of scrotal trauma is more likely to represent intratesticular haematoma, follow-up is recommended to exclude an underlying tumour.



# Scrotal Trauma: Follow Up Is Clinical Safety Net

## Position statement 20

US follow-up of patients with testicular traumas should be considered to ensure resolution/healing of parenchymal changes and to assess postoperative changes.



# Scrotal Trauma: What To Look For?

## Position statement 1

Knowledge of testicular anatomy and vascularisation is necessary to investigate patients with scrotal trauma.

## Position statement 2

When performing an US investigation for scrotal trauma, sonologists should have adequate knowledge and understanding of the mechanism and type of trauma.

## Position statement 3

A standard US examination for scrotal trauma includes greyscale US, Colour Doppler and spectral Doppler.

## Position statement 4

Transverse images including both testes should be obtained when anatomy permits, to allow side-to-side comparison of echotexture and vascularity.

## Position statement 5

During US in scrotal trauma, it is important to maintain continuity of echogenic tunica albuginea and an intact testicular contour to rule out testicular rupture.

## Position statement 6

Changes in testis echotexture may be the clue of underlying testicular parenchymal injury.

## Position statement 7

Testicular vascularity should be demonstrated using CDUS as an aid in deciding between surgery and nonoperative management in mild injury and between orchiectomy and testicular repair in severe injury.

## Position statement 13

Post-traumatic testicular torsion should be considered in a polytrauma patient presenting with severe scrotal pain.

## Position statement 14

In the setting of testicular traumas, US can be used to evaluate testis viability and locate foreign bodies.

## Position statement 15

US is used to identify presence or absence of flow in the testis, which is diagnostic.

## Position statement 16

CEUS can be used to identify testicular rupture, fracture lines, haematomas and ischaemic changes in equivocal cases at conventional US.

## Position statement 17

US is used to distinguish between avascular and poorly vascularised testes, thus helping to differentiate between testicular rupture and torsion.

US is recommended to exclude underlying testicular lesions are usually recommended to exclude underlying testicular lesions.

## Position statement 19

US is used in cases of equivocal US findings to identify testicular rupture, to characterise haematomas, to differentiate tumours from haematomas, to assess presence/absence of flow and to localise a dislocated testis.

## Position statement 20

US follow-up of patients with testicular traumas should be considered to ensure resolution/healing of parenchymal changes and to assess postoperative changes.

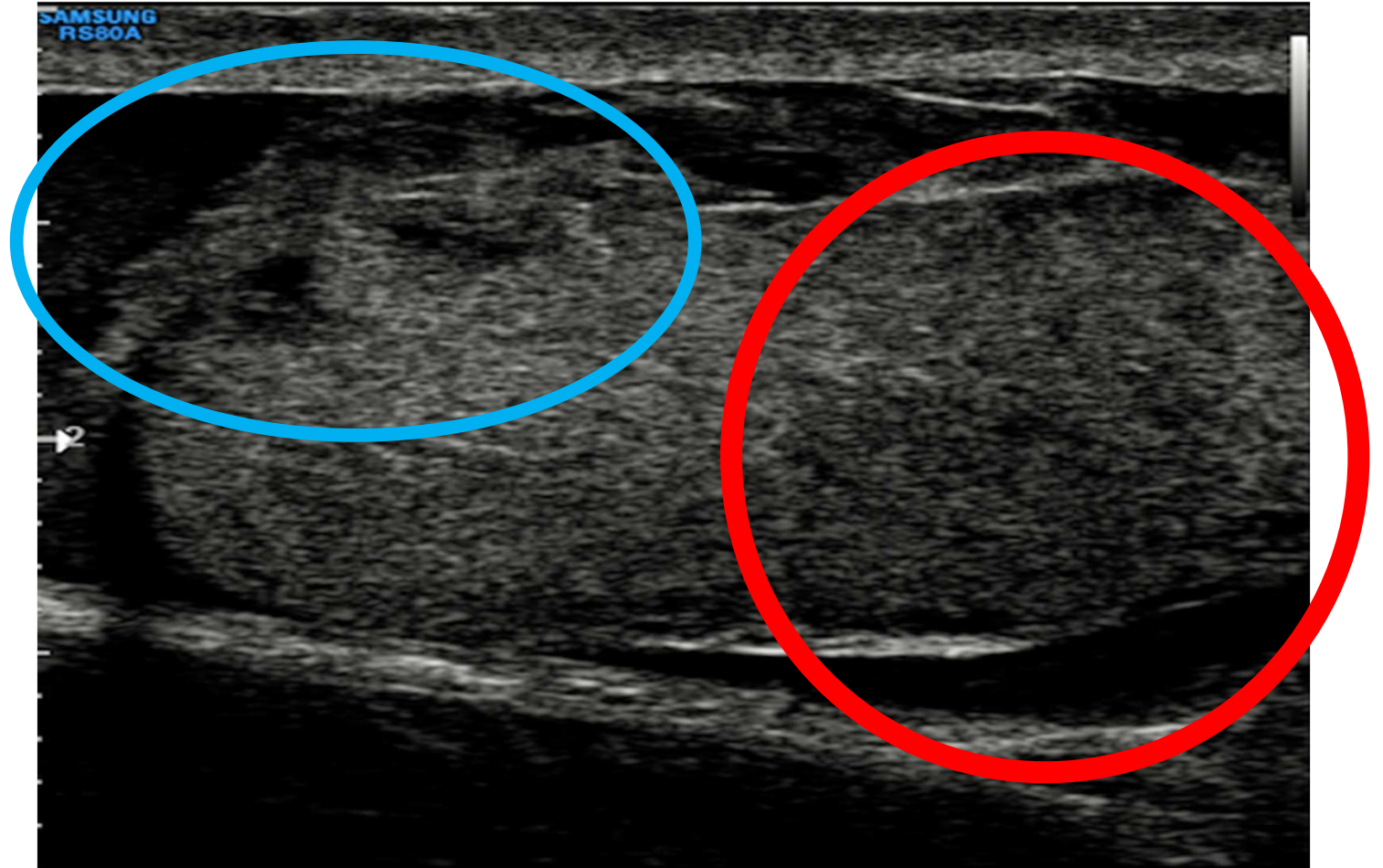
## Position statement 12

If testicular dislocation is identified clinically, US can be used to locate the testis, identify intratesticular injuries and assess parenchymal viability. CT or MRI may be considered in cases of inconclusive US findings.

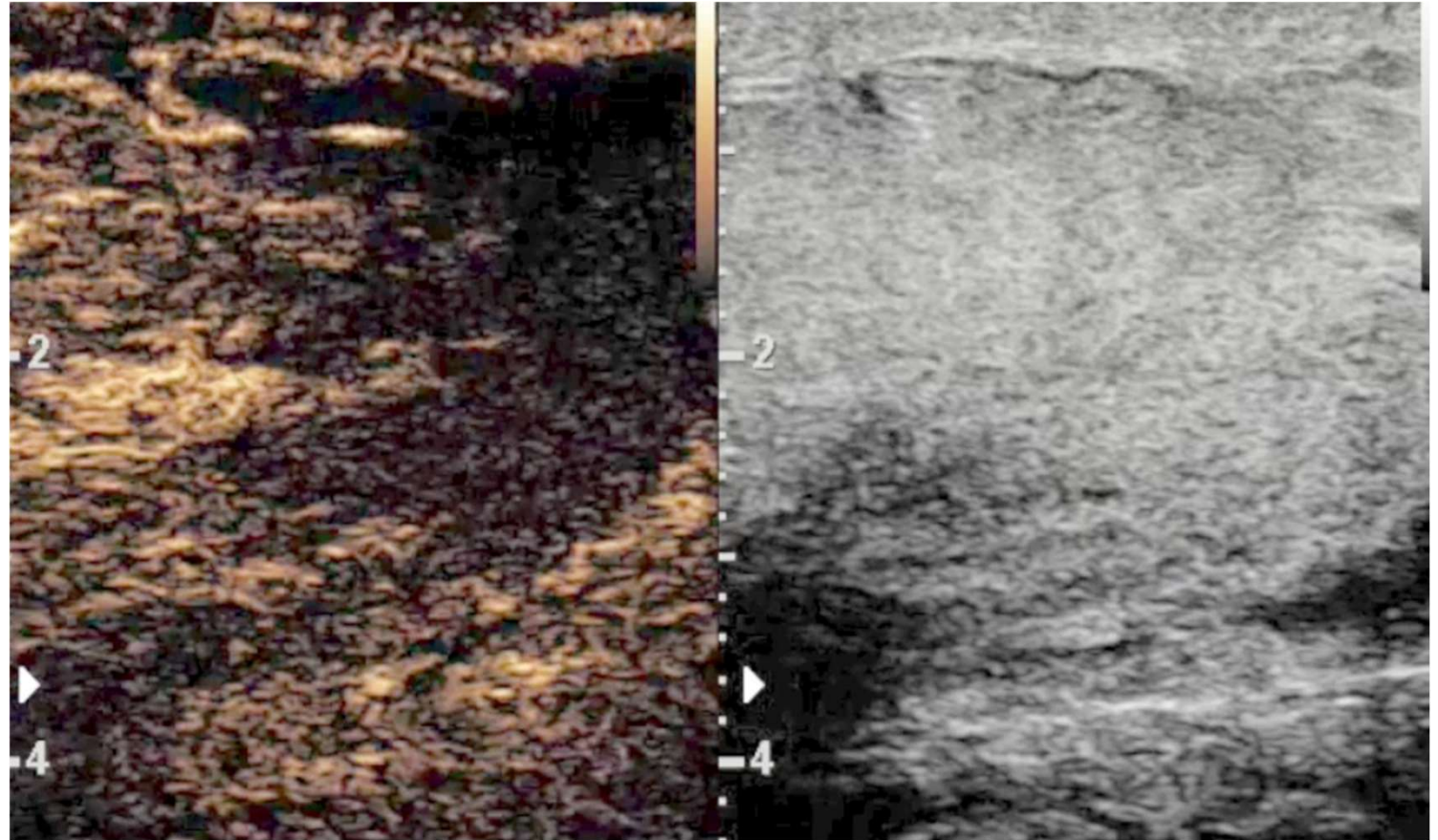

## Checklist:

- *Parenchyma*
- *Tunica*
- *Vascularity*
- *Haematoma*

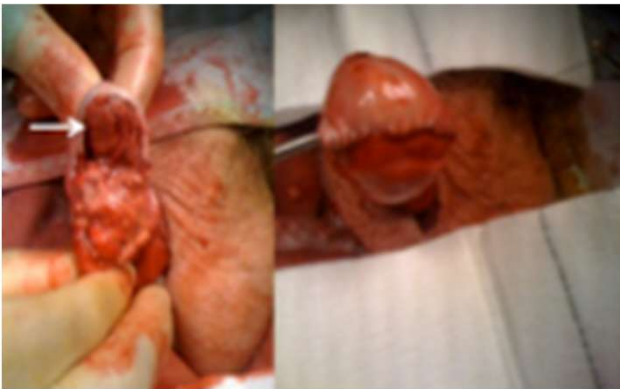# Scrotal Trauma: What To Look For?



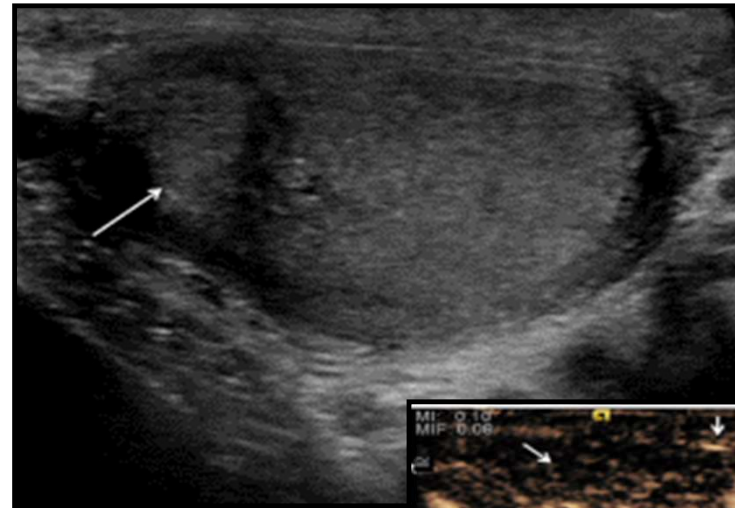
# Scrotal Trauma: What To Look For?



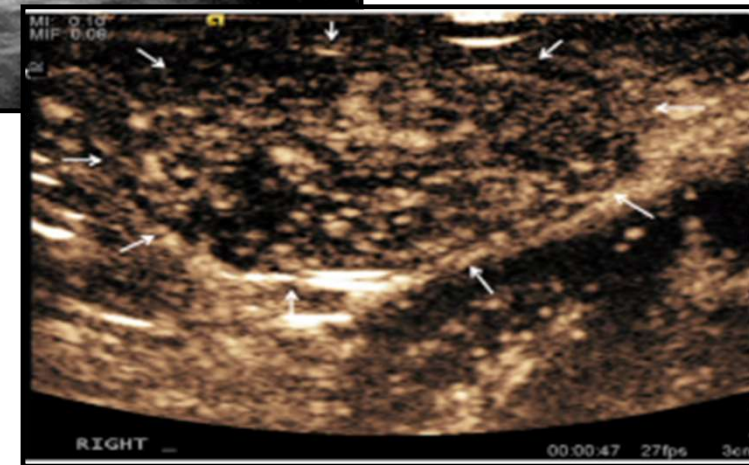
# Scrotal Trauma: What To Look For?



**Surgical excision of ischaemic area and preservation of viable tissue**



**3 months post surgery**



SECTION 02

# Torsion: Every Second Counts

*Time is testis – your scan, their future*

# Time Is Testis

## The Clock Is Running

**< 6 h** >90% salvage

**6–12 h** 50% salvage

**> 24 h** <10% salvage

## Pathophysiology

Venous outflow blocked first

Then arterial occlusion → ischaemia

Low-degree: venous only — flow may be PRESENT

## What To Look For

### B-mode

Initially NORMAL → enlarges, hypoechoic > heterogeneous

### Colour Doppler

Absent/markedly reduced flow vs contralateral — most critical finding

### Whirlpool Sign

Twisted spermatic cord — coiled mass above testis

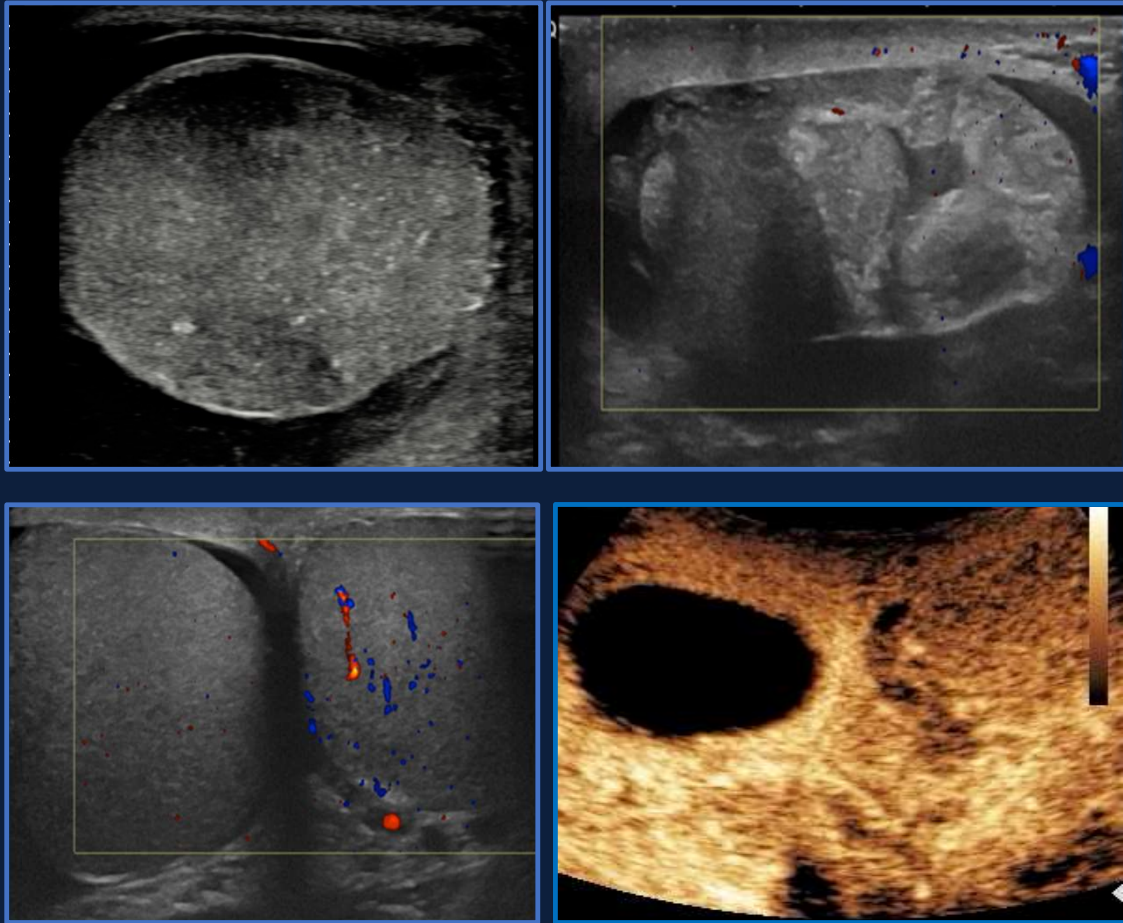
### Spectral Doppler

Monophasic waveforms, reversed diastolic flow in low-degree torsion

### Sensitivity/Spec

84–99% sensitive, 93–99% specific (CDUS for torsion)

# What To Look For



## What To Look For

### B-mode

Initially NORMAL → enlarges, hypoechoic > heterogeneous

### Colour Doppler

Absent/markedly reduced flow vs contralateral — most critical finding

### Whirlpool Sign

Twisted spermatic cord — coiled mass above testis

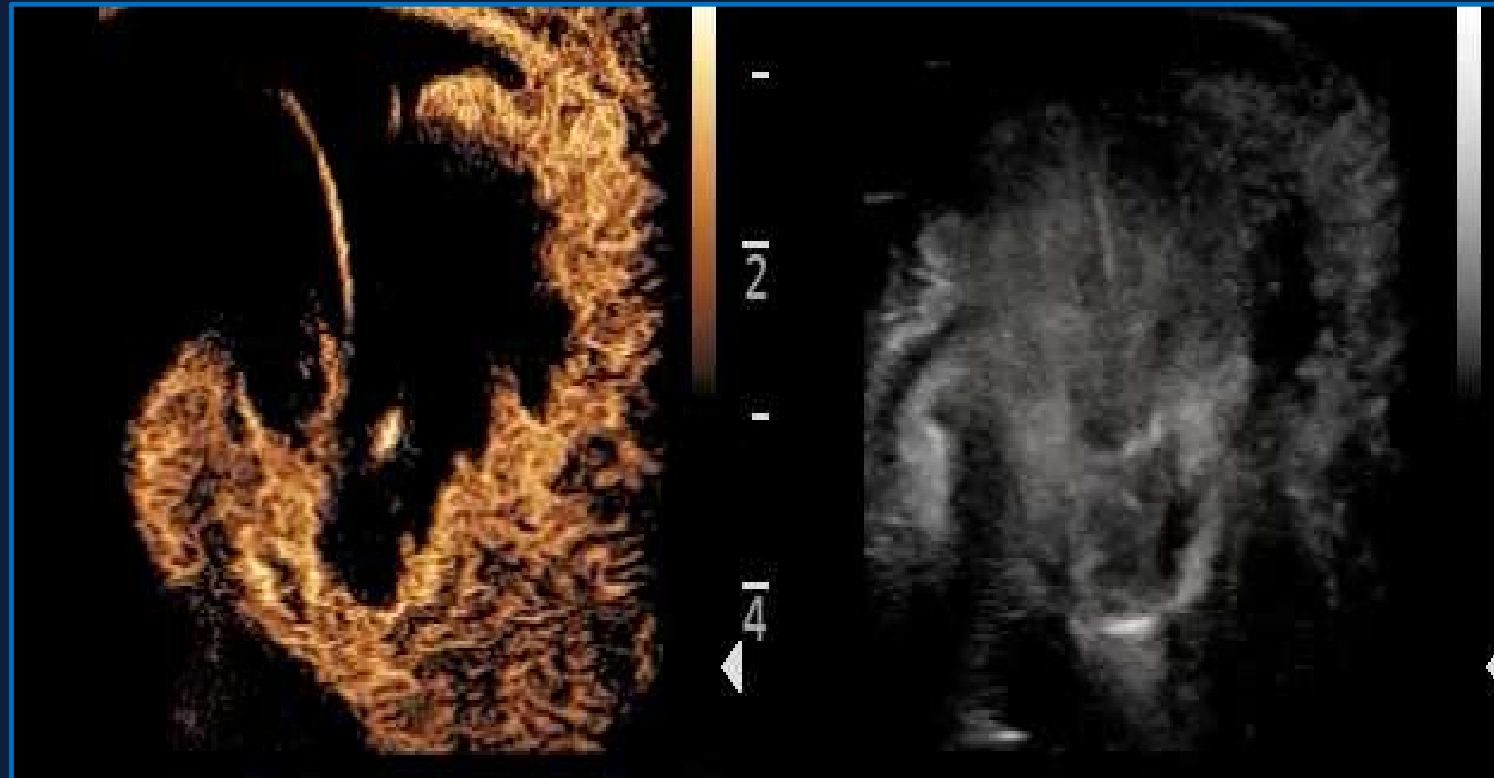
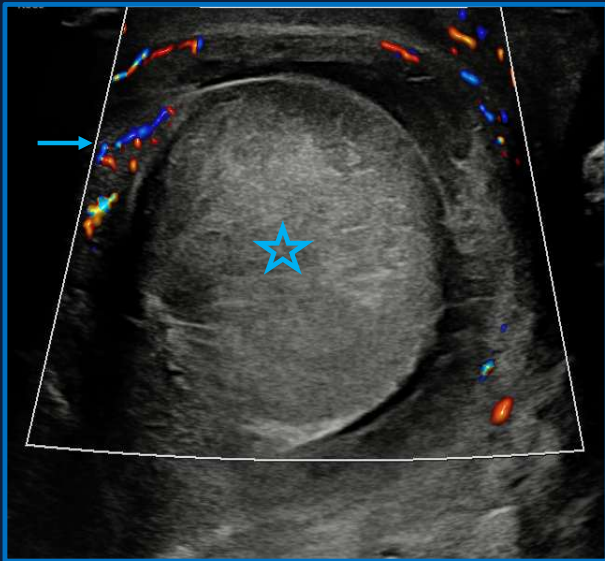
### Spectral Doppler

Monophasic waveforms, reversed diastolic flow in low-degree torsion

### Sensitivity/Spec

84–99% sensitive, 93–99% specific (CDUS for torsion)

# Flow May Be PRESENT



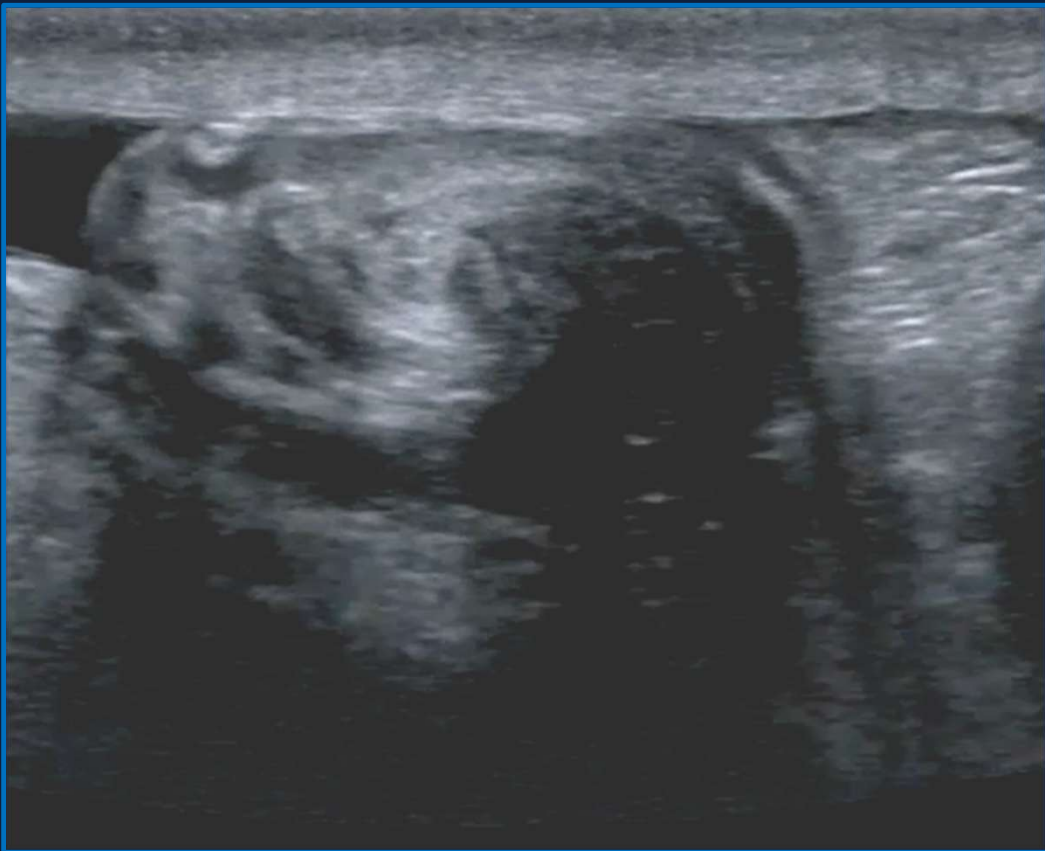## Pathophysiology

Venous outflow blocked first

Then arterial occlusion → ischaemia

Low-degree: venous only — flow may be PRESENT

# The Whirlpool Sign



## What is it?

Abrupt spiral twist of the spermatic cord — seen as a coiled mass above the affected testis on grey-scale or CDUS.

## Why important?

Detects torsion regardless of Doppler findings — crucial in low-degree / partial torsion where flow may still be present.

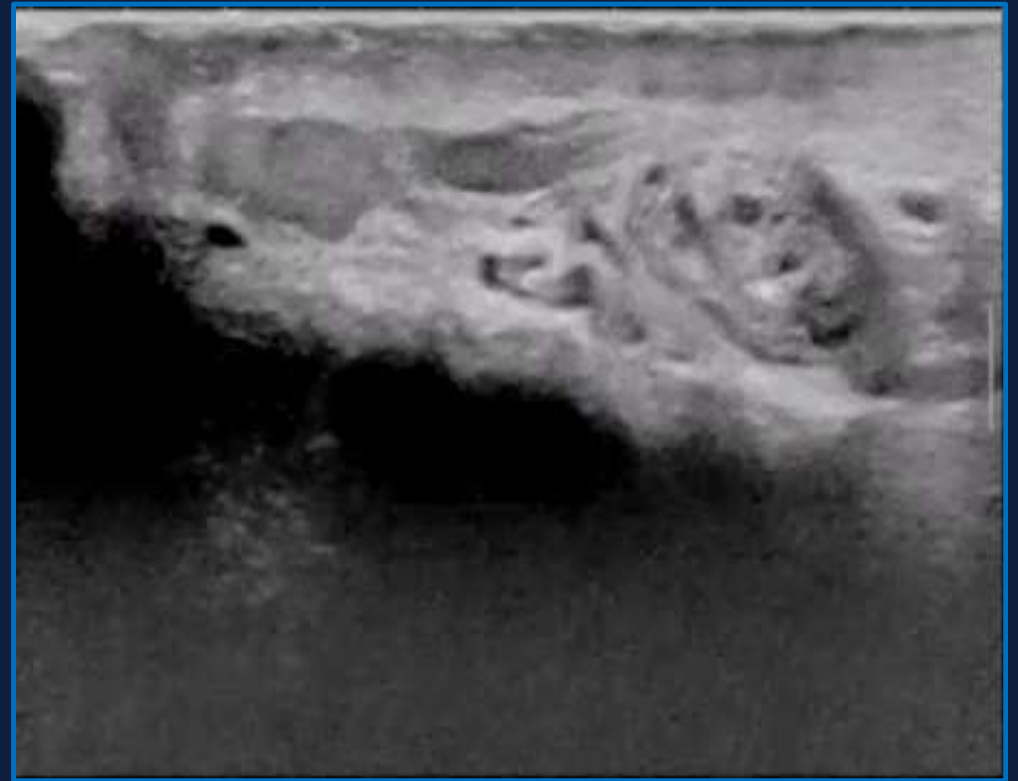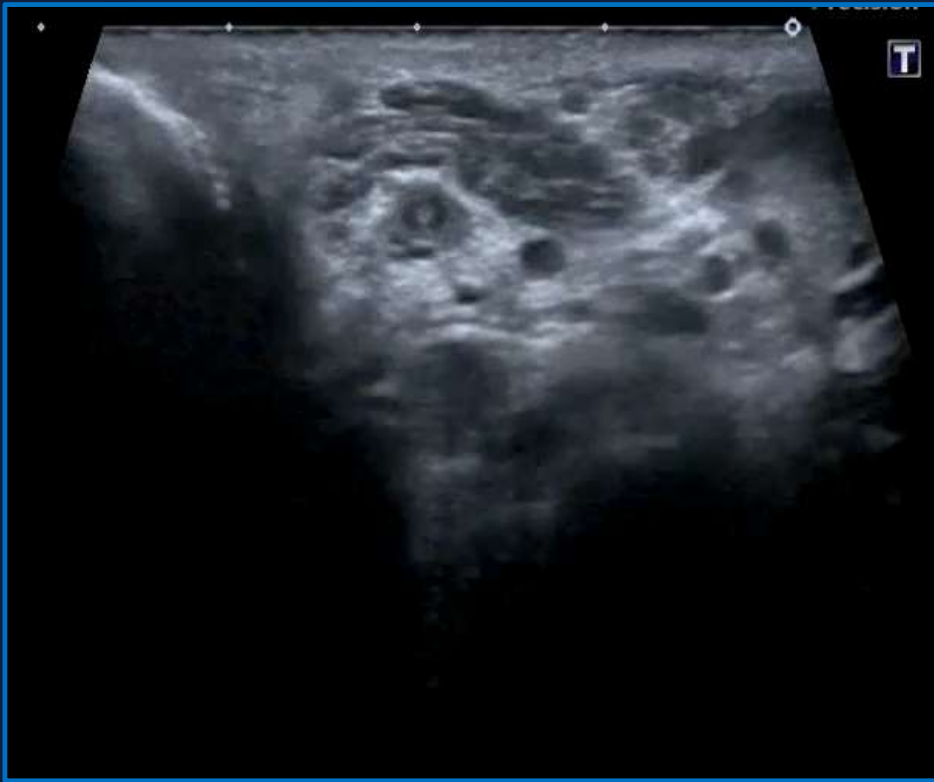
## How to find it?

Trace the spermatic cord from the superficial inguinal ring downward; look for the whirlpool or pseudomass in both transverse and longitudinal planes.

## Performance?

Sensitivity ~84–99%, Specificity ~93–99% when combined with CDUS (Vijayaraghavan 2006, Ota 2019).

# A Normal Spermatic Cord May Twist...



# ⚠ Diagnostic Traps In Testicular Torsion

## Preserved Flow ≠ No Torsion

Partial torsion (<360°) spares arterial flow — venous outflow obstructs first. Capsular flow can persist. Ensure signal is truly intratesticular.

**Elevated RI (>0.75) or reversed diastolic**

## Detorsion on Induction

Confirmed torsion at scan → no torsion at surgery. Muscle relaxant allows spontaneous detorsion. Reactive hyperaemia then mimics orchitis.

**prophylactic orchidopexy.**

## Torsion on Tumour

Gross heterogeneity + avascularity in a disproportionately large testis — consider tumour predisposing to torsion. Both conditions require surgery.

**Report heterogeneity explicitly.**

 **CRITICAL RULE: If clinical suspicion is high, imaging should not delay surgery.**

The EFSUMB 2026 guidelines are explicit: USS is an adjunct - NOT a gatekeeper when clinical probability is high.

## Hypervascular 'Orchitis' that isn't

Reactive hyperaemia after spontaneous detorsion looks identical to orchitis. Normal flow does not exclude previous torsion.

**No epididymal involvement favours detorsion.**

## Twist with normal cord

Cord can twist without pain or congestion signs — asymptomatic twist is a normal variant. Distinguish by clinical context + downstream venous congestion.

**Clinical context of pain is important**

## The Pre-Pubertal Testis

Small testes in children may show no Doppler signal bilaterally — this is normal. Avoid false-positive diagnosis based on 'no flow' alone.

**B-mode dominates. Asymmetric swelling + cord twist = surgery.**

SECTION 03

# Infection & Inflammation

*Uncomplicated epididymitis is a clinical diagnosis — so what is imaging actually for?*

# Epididymo-orchitis: When Imaging Matters

## Key principle

**Uncomplicated epididymitis is a clinical diagnosis.**

### Imaging is indicated when:

- Symptoms persist or worsen on antibiotic treatment
- Clinically indeterminate (exclude torsion)
- Suspected abscess or infarct
- Immunocompromised patient
- Atypical organisms suspected (TB, syphilis)

### US features of epididymitis

- Enlarged, hypoechoic epididymis (head >> body > tail)
- Reactive hydrocele
- Scrotal wall thickening
- Testicular involvement in ~58%

## Complications That Change Management

### Abscess Formation

Hypervascular rim + avascular necrotic centre. CDUS + CEUS confirm extent. May need drainage.

### Venous Infarction

Severe oedema occludes venous drainage → global infarction. Avascular testis on CDUS. CEUS essential — confirms non-perfusion.

### Segmental Infarction

Focal avascular wedge or round lesion — tumour mimic. Most important diagnostic dilemma.

### Post-inflammatory Changes

Fibrosis → heterogeneous echotexture. Awareness prevents false alarm on follow-up.

# Scrotal Infection: Complication Spectrum

## URGENT

### Venous Infarction

Avascular testis on Colour Doppler; late arterial flow on CEUS confirms venous mechanism (intact arterial supply)

*Mx: Surgical decompression if worsening; conservative if limited + confirmed on CEUS*

## URGENT

### Epididymal Abscess

Mixed reflective epididymal mass; avascular centrally (CDUS); CEUS → absent core + surrounding hyperaemia

*Mx: Aspiration / surgical drainage; CEUS confirms non-enhancing core*

## URGENT

### Testicular Abscess

Lobulated partly cystic intra-testicular lesion; solid components vascularised on MVI; CEUS → ring-enhancement

*Mx: Histology if uncertain; chronic abscess mimics tumour — follow-up scan essential*

## EMERGENCY

### Fournier's Gangrene

Scrotal wall thickening; hyperechoic subcutaneous gas ('dirty shadowing'); avascular necrotic zones; testicular perfusion often initially preserved

*Mx: Do NOT delay surgery for imaging if clinically obvious. CT for extent mapping. Urgent debridement.*

## URGENT

### Scrotal Wall Abscess

Complex subcutaneous collection; CEUS confirms avascular core vs oedema in enhancing tissue; delineates septations for drainage

*Mx: CEUS-guided drainage; MRI for deep extension (ischioanal fossa, pelvic floor)*

## NON-URGENT

### Hidradenitis Suppurativa

Dermal/subdermal thickening; hypoechoic tunnels; sinus tracts (follow with gentle probe pressure); hyperaemia at active foci

*Mx: Dermatology-led; surgical excision for refractory tracts; US maps extent for planning*

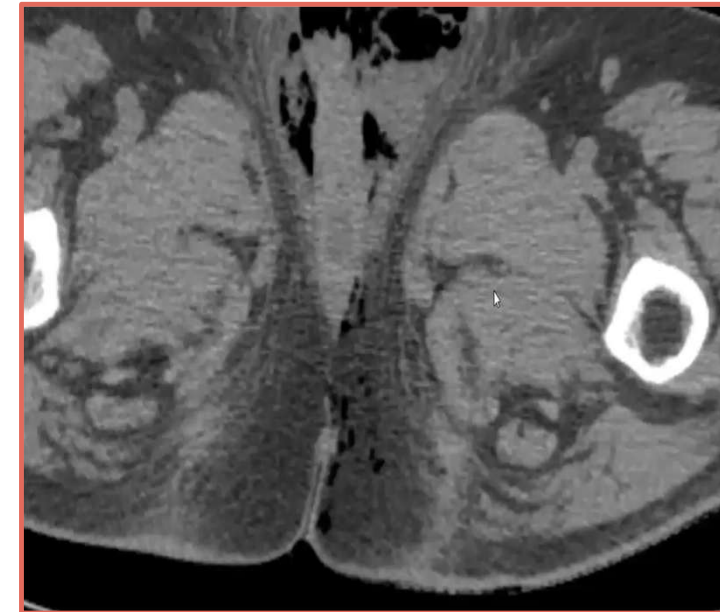
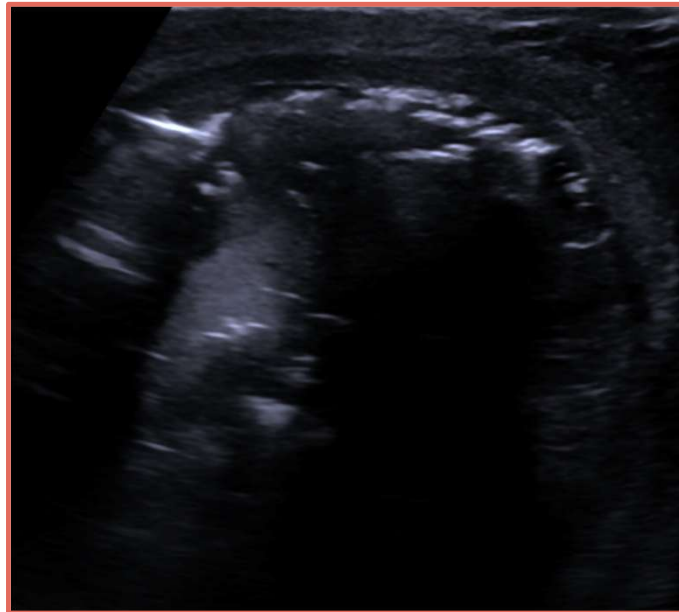# Scrotal Infection: Complication Spectrum

## EMERGENCY

### Fournier's Gangrene

Scrotal wall thickening; hyperechoic subcutaneous gas ('dirty shadowing'); avascular necrotic zones; testicular perfusion often initially preserved

*Mx: Do NOT delay surgery for imaging if clinically obvious. CT for extent mapping. Urgent debridement.*



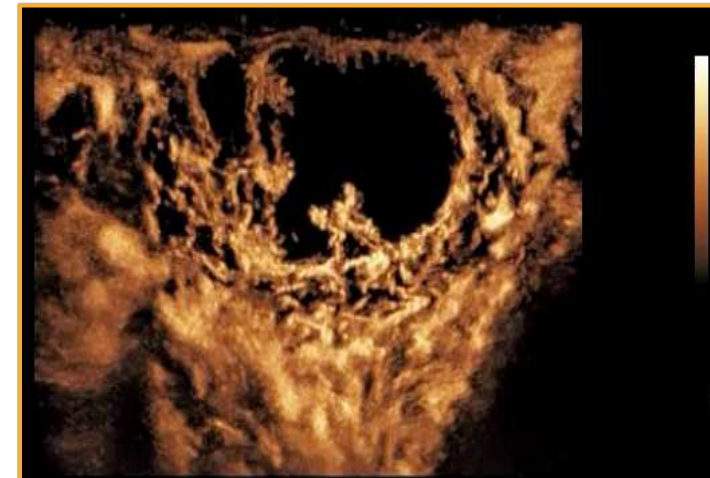
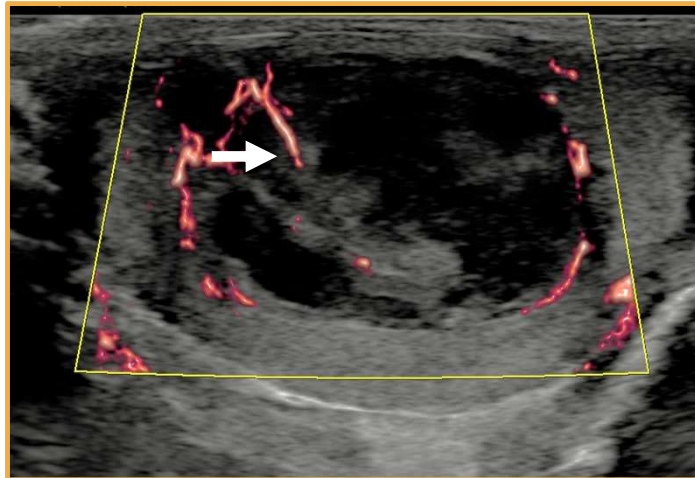
# Scrotal Infection: Complication Spectrum

URGENT

## Testicular Abscess

Lobulated partly cystic intra-testicular lesion; solid components vascularised on MVI; CEUS → ring-enhancement

*Mx: Histology if uncertain; chronic abscess mimics tumour — follow-up scan essential*

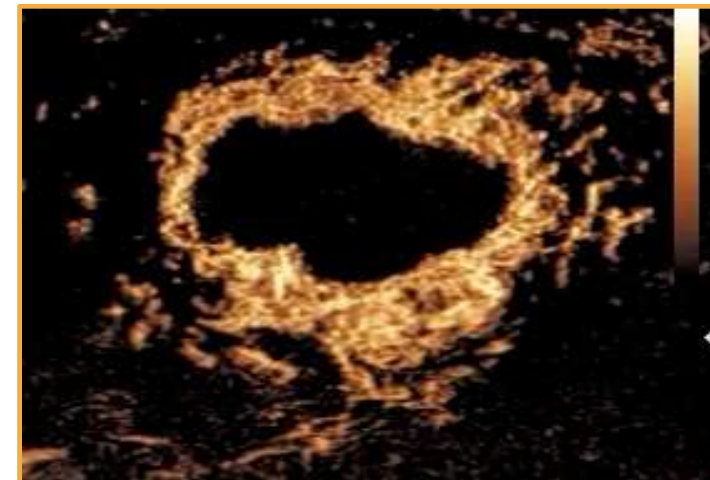
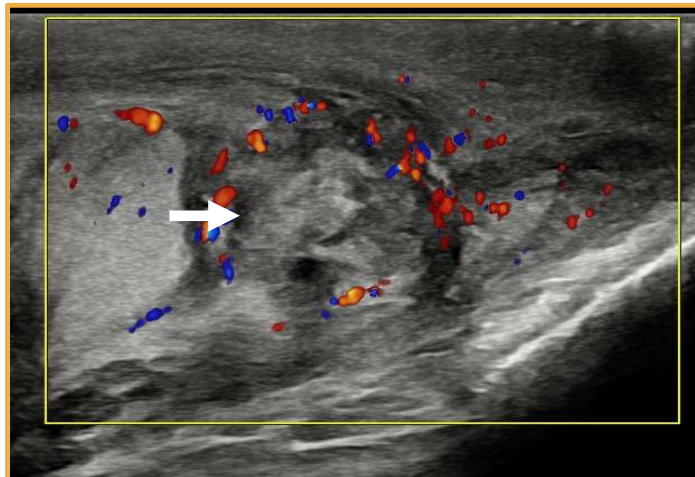


URGENT

## Epididymal Abscess

Mixed reflective epididymal mass; avascular centrally (CDUS); CEUS → absent core + surrounding hyperaemia

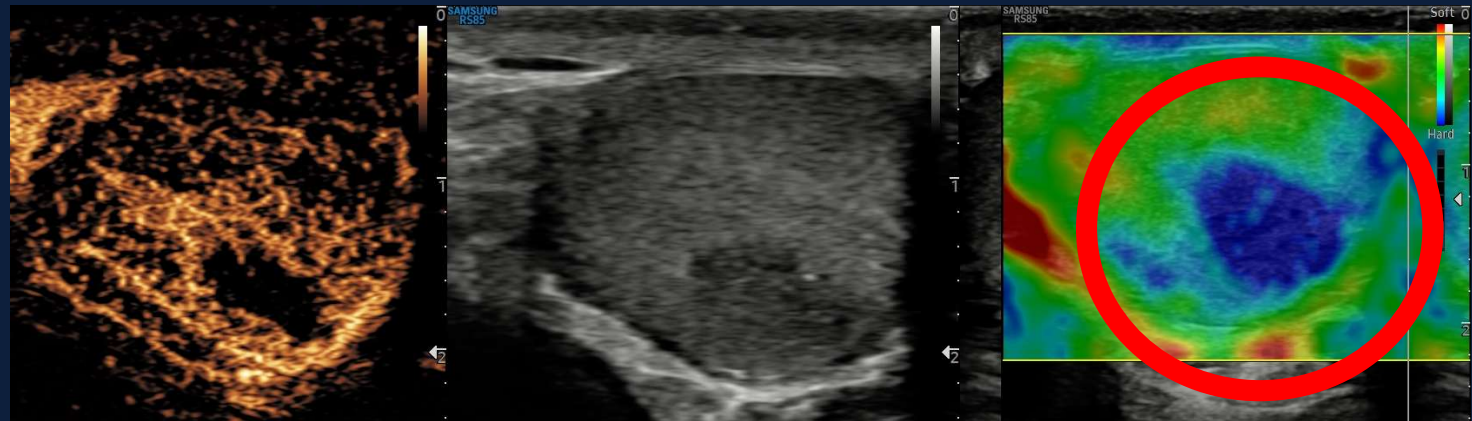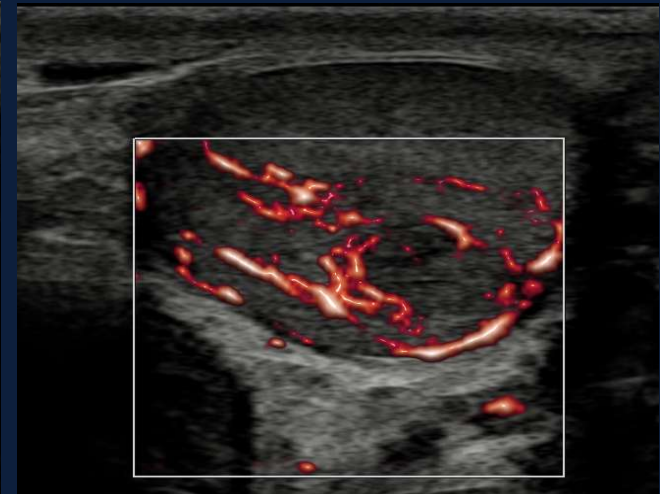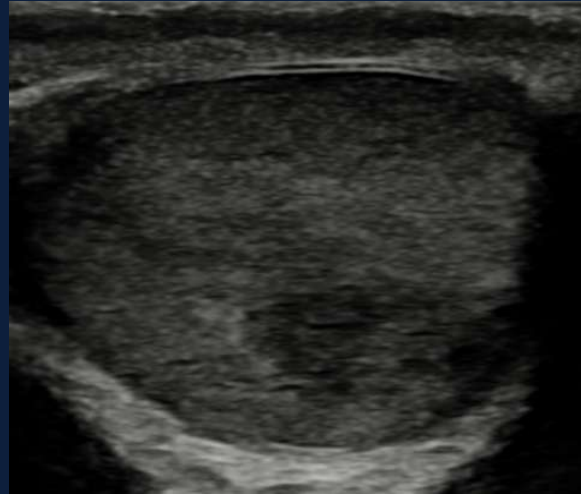
*Mx: Aspiration / surgical drainage; CEUS confirms non-enhancing core*



# Another Testicular Abscess??

**A 41-year-old with a right testicular pain with a clinical diagnosis of epididymitis.**

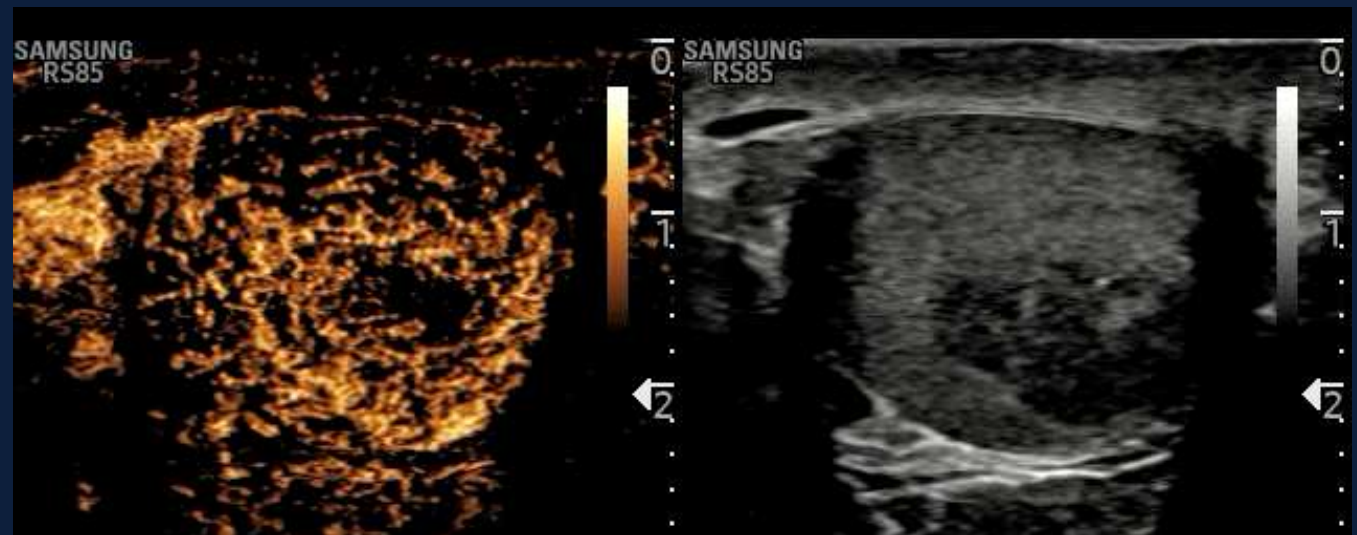
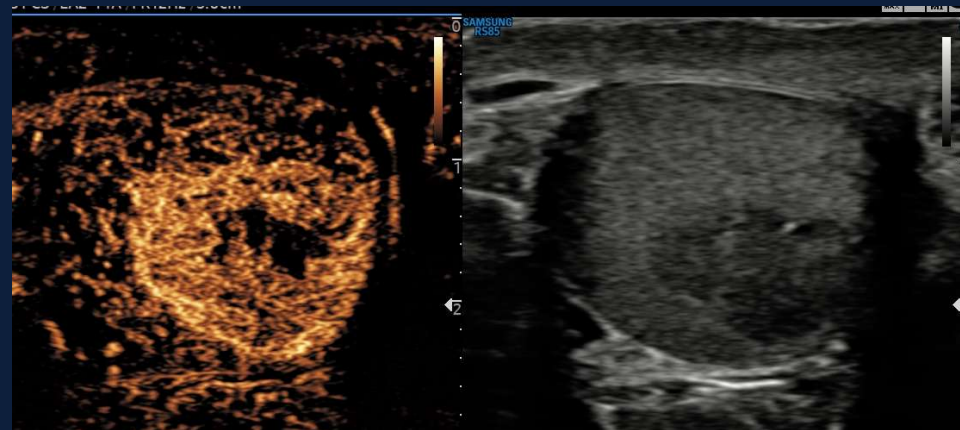
- The lesions are of reduced reflectivity and do not demonstrate increased flow on microvascular imaging.
- The lesion is avascular centrally with some rim enhancement. This however, appears 'hard' on strain elastograph



# Tumour With Infarction

## Pure Seminoma with Necrosis

- A follow up scan showed an increase in size of the abnormality and the enhancing rim.



SECTION 04

# When the Scrotum Looks Normal



*How can we  
know??*

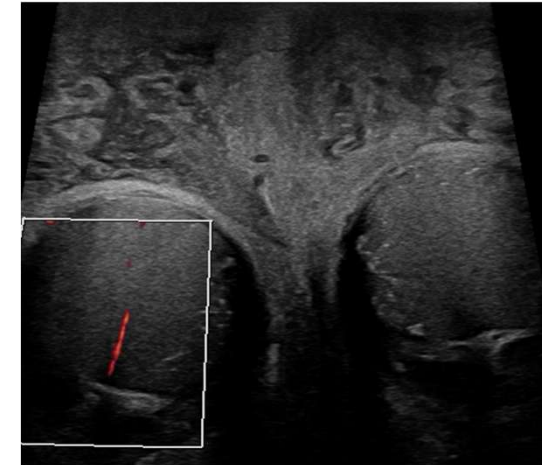
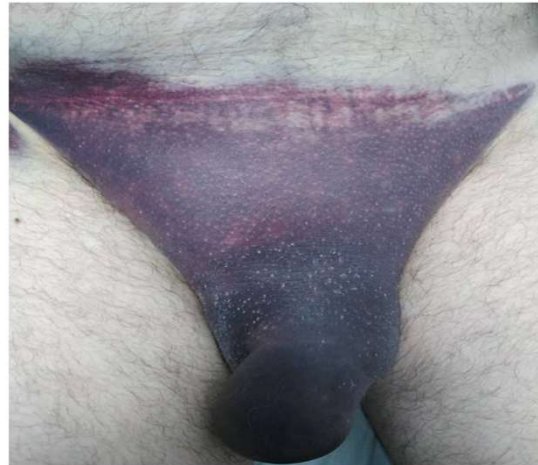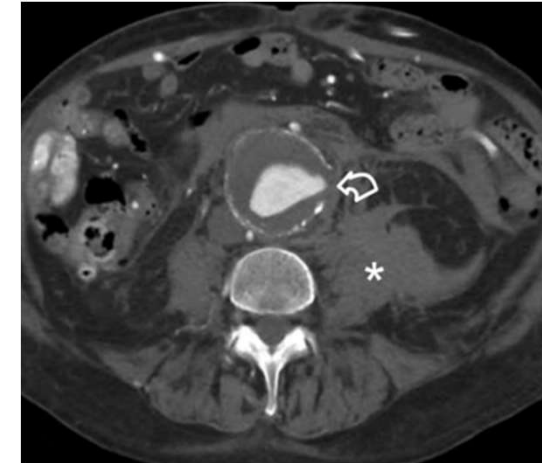
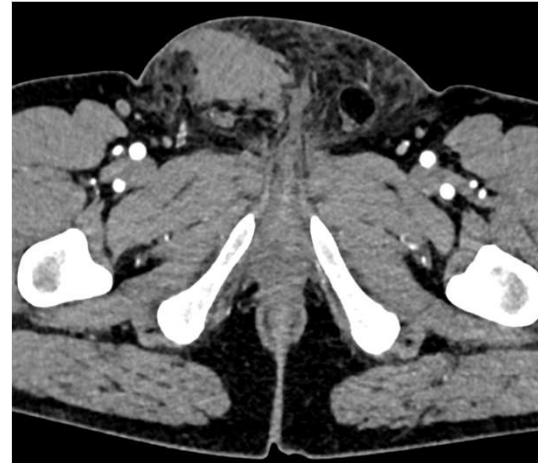*The Dunning - Kruger effect: We don't know what we don't know*

# Scrotal Pain – Non-Scrotal Causes

## Causes when the scrotum is normal

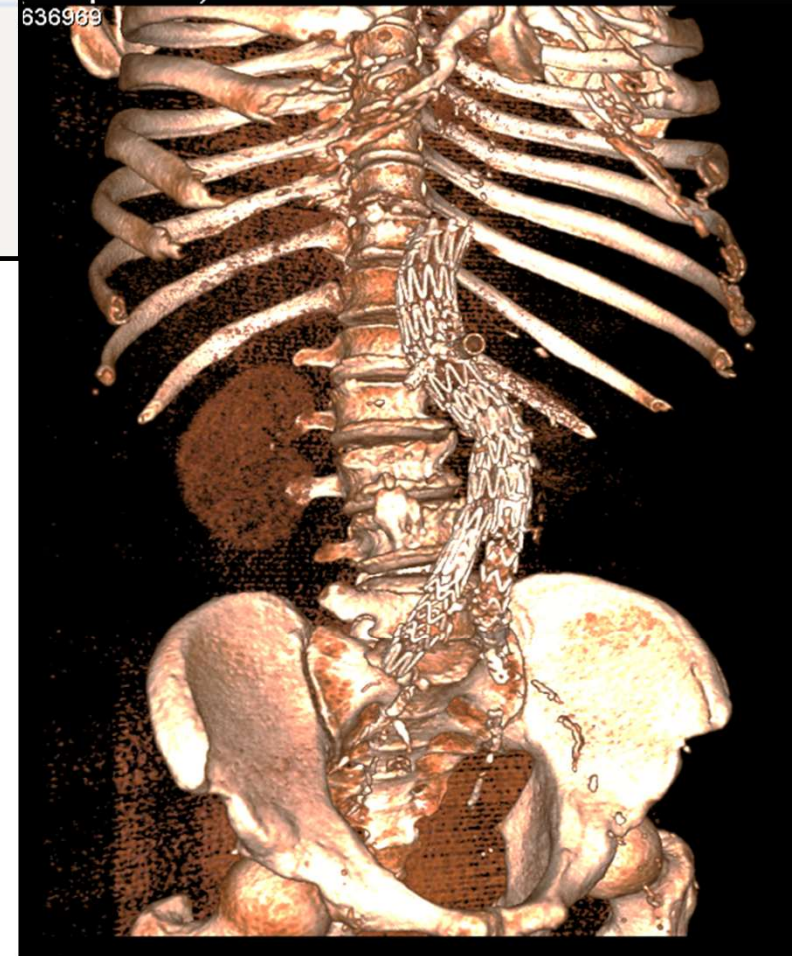
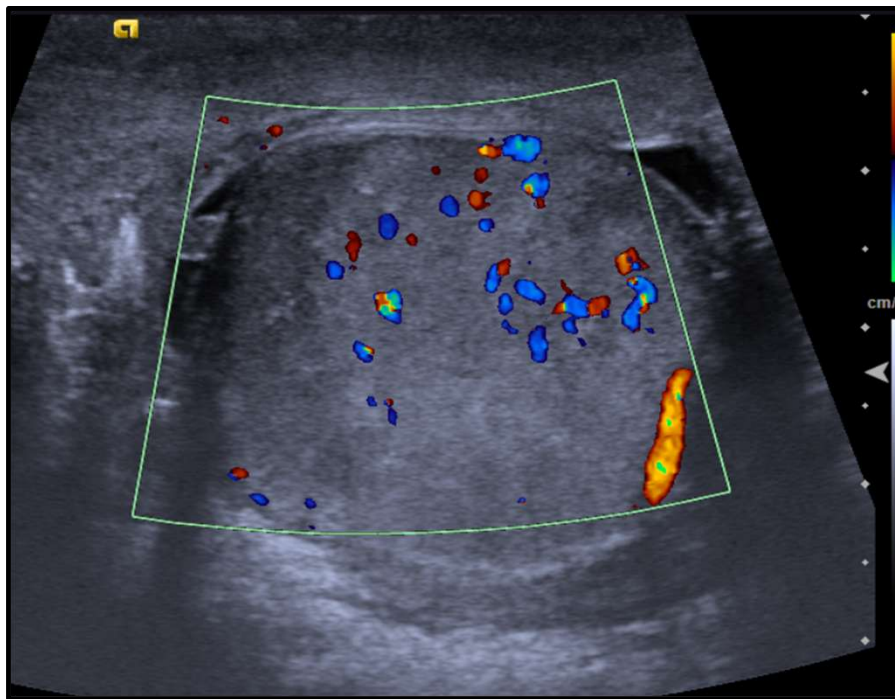
- Renal colic
- Ruptured AAA
- Retroperitoneal tumour
- Acute pancreatitis
- Incarcerated inguinal hernia
- Acute prostatitis
- Thigh haematoma / femoral pathology

**Bryant's sign** : scrotal ecchymosis from retroperitoneal haemorrhage tracking along fascial planes

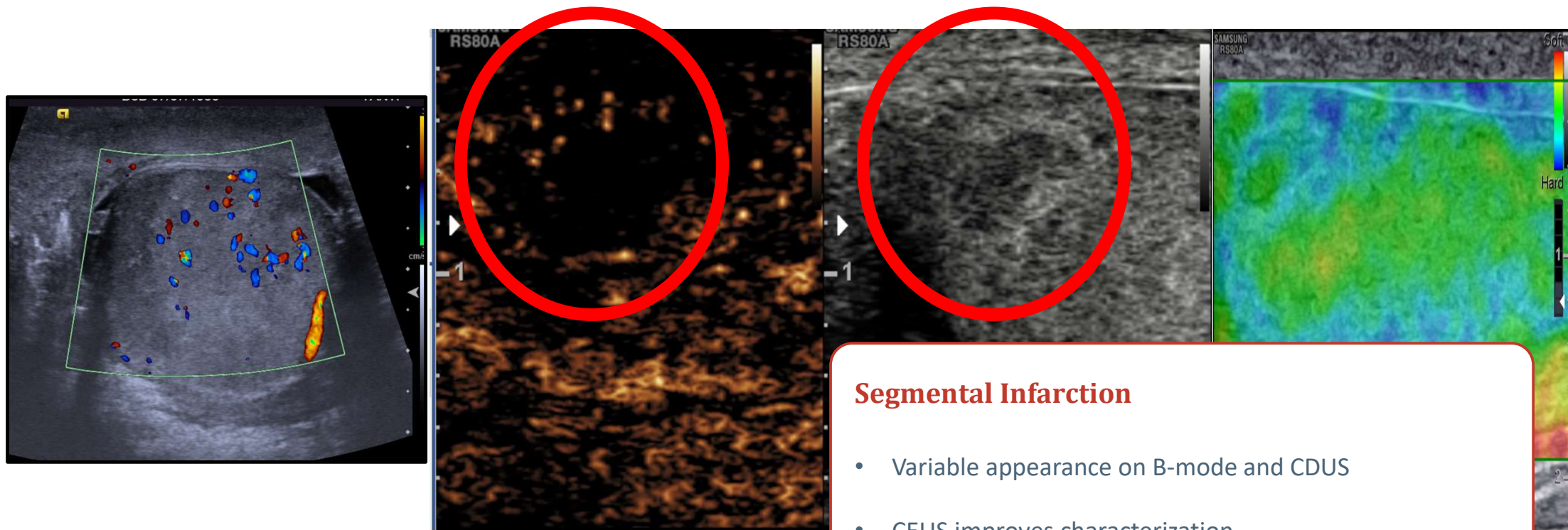


# Scrotal Pain – Unexpected Causes

Clinical Details: post EVAR. swollen tender right testicle.  
?post surgical haematoma ?varicocele. Exclude torsion  
Inpatient/Outpatient: Inpatient



# Scrotal Pain – Segmental Infarction



## Segmental Infarction

- Variable appearance on B-mode and CDUS
- CEUS improves characterization

SECTION 05

# Summary

*Key evidences, dilemmas in practice and take-home*

# Guidelines and Recommendations

## SCROTAL US



### EFSUMB Testis Multiparametric Ultrasound Guidelines

Michele Bertolotto, Simon Freeman, Dean Huang, Paul S Sidhu, Irene Campo, Dirk-André Clevert, Vikram Dogra, Francesco M Drudi, Thomas Fischer, Andrea M. Isidori, Christian Jensen, Markus H Lerchbaumer, Guntram Lock, Lotti Francesco, Malene R Pedersen, Carlotta Pozza, Subramaniyan Ramanathan, Jonathan Richenberg, Valeria Scotti, Paul Spiesecke, Christoph F Dietrich, Vito Cantisani.

Affiliations below.

DOI: 10.1055/a-2785-3267

Please cite this article as: Bertolotto M, Freeman S, Huang D et al. EFSUMB Testis Multiparametric Ultrasound Guidelines. *Ultraschall in der Medizin - European Journal of Ultrasound* 2026. doi: 10.1055/a-2785-3267



European Radiology (2021) 31:4918–4928  
<https://doi.org/10.1007/s00330-020-07631-w>

UROGENITAL

### Imaging in scrotal trauma: a European Society of Urogenital Radiology Scrotal and Penile Imaging Working Group (ESUR-SPIWG) position statement

Subramaniyan Ramanathan<sup>1,2</sup> · Michele Bertolotto<sup>3</sup> · Simon Freeman<sup>4</sup> · Jane Belfield<sup>5</sup> · Lorenzo E. Derchi<sup>6,7</sup> · Dean Y. Huang<sup>8</sup> · Francesco Lotti<sup>9</sup> · Karolina Markiet<sup>10</sup> · Olivera Nikolic<sup>11</sup> · Parvati Ramchandani<sup>12</sup> · Jonathan Richenberg<sup>13</sup> · Laurence Rocher<sup>14</sup> · Paul S. Sidhu<sup>8</sup> · Katarzyna Skrobisz<sup>15</sup> · Athina Tsili<sup>16</sup> · Pieter De Visschere<sup>17</sup> · Irene Campo<sup>18</sup> · Oliwia Kozak<sup>15</sup> · Vikram Dogra<sup>19</sup>

## TRAUMA

# Dilemmas In Practice

*Where practice may vary...*

## Imaging Before Surgery in Suspected Torsion

Clinical suspicion = surgery; US as adjunct only.

Guideline clear; practice variable

## CEUS Role in Acute Torsion

No advantage of CEUS over CDUS in acute torsion.

Adjunct only — not first-line

## Management of Avascular Hypoechoic Lesions

No standardised recommendation for follow-up interval (or criteria for surgery vs observation).

No consensus — multidisciplinary discussion essential

## Elastography in Acute Torsion

currently considered clinically useful for routine practice. 'Some data on prognostic stiffness values. Limited role as stand-alone technique.

Research tool; not routine

## MVI / Microvascular Imaging

Emerging evidence (case reports, animal models) shows superiority over CDUS in small testes. Not yet in major guidelines. Equipment-dependent. Promising but not validated in large cohorts.

Watch this space — not yet recommended

# TAKE-HOME MESSAGES

*The acute scrotum is one of the few true ultrasound emergencies.*

*Your scan directly determines whether a man loses a testis.*

01

Torsion is time-critical — salvage falls sharply after 6 hours. Don't delay surgery for imaging if clinical suspicion is high.

04

Detorsion on induction is real. A hypervascular testis with resolving pain is torsion-detorsion until proved otherwise.

02

Colour Doppler is highly accurate, but preserved flow does NOT exclude torsion — always examine the cord.

05

Epididymitis can cause venous infarction — avascular testis in an infected scrotum still needs urgent imaging and management.

03

The whirlpool sign — use it alongside Doppler and clinical context

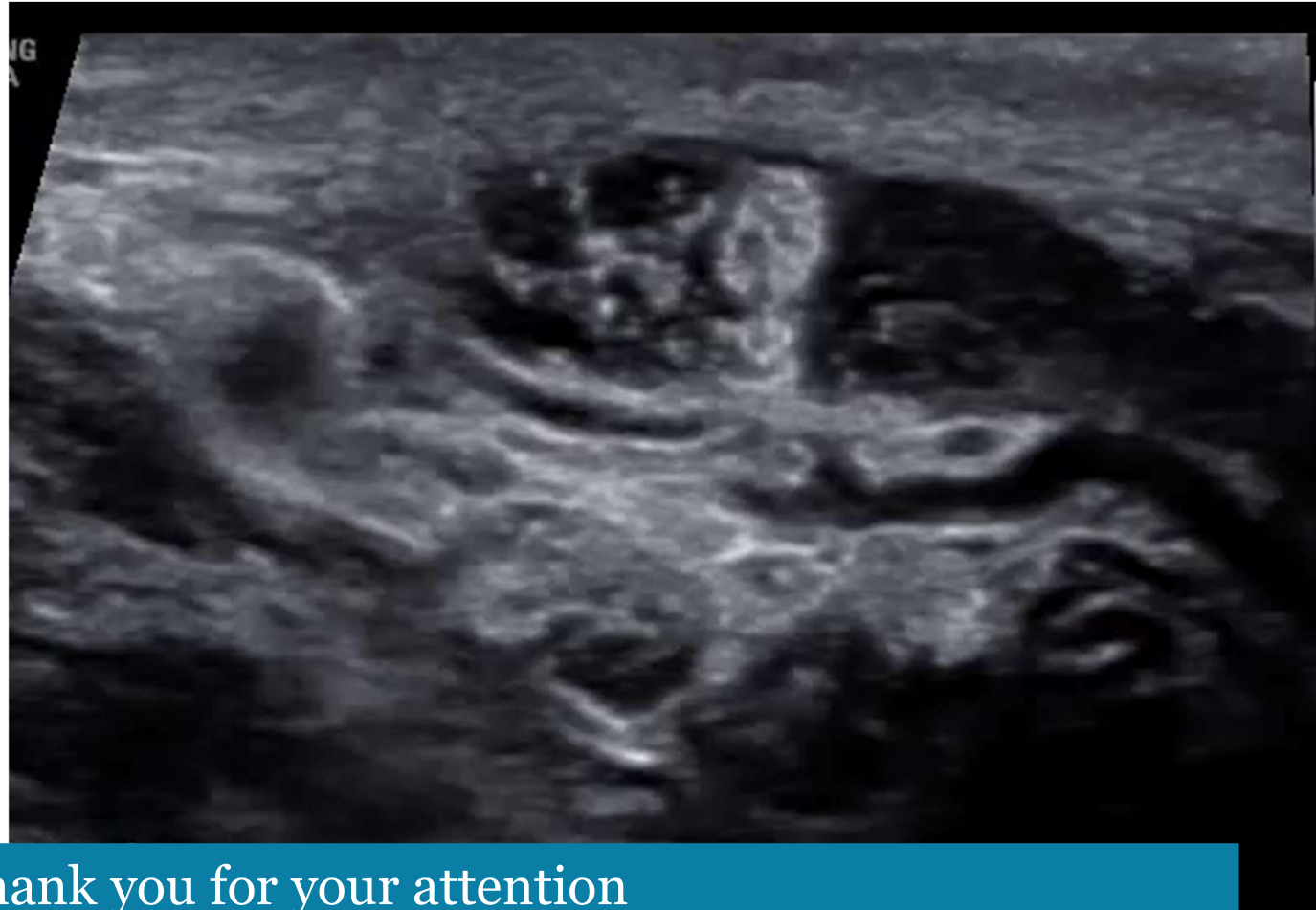06

CEUS adds decisive value in indeterminate cases: confirms true avascularity, maps abscesses, and preserves testes.

# Spread The Love

*“To be fond of dancing  
was a certain step  
towards falling in  
love...”*

*Jane Austen*



Thank you for your attention