Ultrasound of Herniae

Andrew Longmead
MSK Sonographer

Session overview

- Abdominal wall hernia, what? Types
- History, technique, different types of imaging
- Abdominal wall anatomy
- Upper abdominal wall hernia and other pathology

- Groin anatomy
- Inguinal canal and inguinal herniae
- Femoral hernia

- Differential diagnosis
- Reporting tips

- Practical

Anterior abdominal wall hernia

A hernia occurs when an internal part of the body pushes through a weakness in the muscle or surrounding tissue wall.

- Can occur at any site where there is weakness in a fascia
- Anywhere post surgical
- Most common inguinal
- Congenital predisposition
- Sex M>F
- Age
- BMI > 30
- Lifting
- Prolonged coughing
- Constipation
- Ascites
- Inter-peritoneal dialysis

Types of hernia

- Epigastric
- Umbilical / Paraumbilical
- Incisional –anywhere
- Spigelian –Semilunar line
- Inguinal –direct /indirect
- Femoral

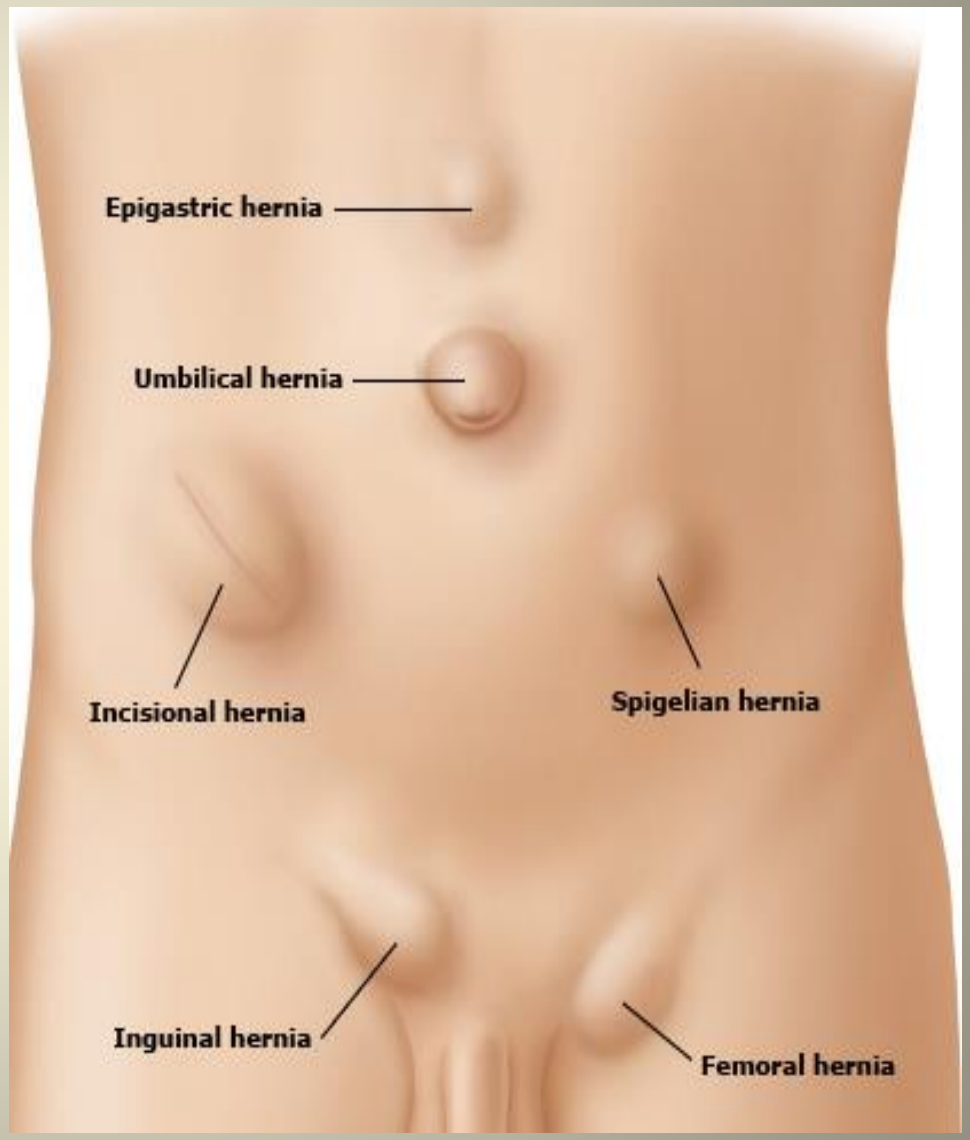

Important to take history

- Location, point to it
- Duration of symptoms
- Type of pain-dragging, sharp, fullness
- Constant/ intermittent
- Exacerbating conditions/movements
- Previous surgery –traumatic/ acquired hernia
- Scrotal swelling /pathology
- Any other ongoing illness, treatment – lymphadenopathy, radiotherapy
- Sports injury/ strain

Why image?

- To assist where there is clinical uncertainty
- ? obvious hernia does not require imaging
- Location of hernia
- Contents –fat, bowel, fluid, vascularity, cystic lesions
- Size of neck opening and volume/size of sac
- Reducibility
- Differential diagnosis

Types of imaging

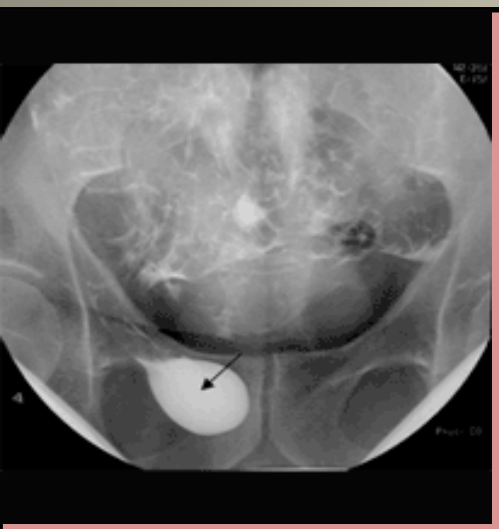

Water soluble contrast injected into the peritoneum
Maneuver patient & Valsalva to try and fill sac

Fluroscopic herniography

Good for
Large incisional herniae

Assess bowel
Confirm size of defect

Computer Tomography (CT)

Useful for less-specific groin pain

Particularly when hernia not expected

Magnetic Resonance Imaging (MRI)

PROS:
- Dynamic and interactive with patient
- Allows for wider diagnosis of differentials
- Can scan supine/erect
- Sensitivity: 86-100%
- Specificity : 82-97%

CONS:
- Habitus challenged
- Operator dependent
- Patient's inability to engage in Valsalva technique

Ultrasound

Technique

- Check previous
- Get good clinical history from patient
  - How long has the lump been there
  - Is painful? , getting bigger, any trauma
- Scan with the patient in different positions, lay , stood etc
- For suspected hernia, instruct patient to strain, raise head, raise legs, cough
- Use probe to vary pressure to assess hernia
- Colour Doppler for vascular localisation
- Contra-lateral side for comparison
- Always other imaging modalities, ask for help etc

Anterior abdominal wall anatomy

2 groups of muscles

Flat muscles
- Lateral margin
 - External obliques
- Internal obliques
-Tranversus abdominis

Ventral muscles:
- Central
- Rectus abdominis
(“Six pack”)

Aponeurosis (broad sheet like tendon)
 - Rectus sheath
 - Inguinal canal

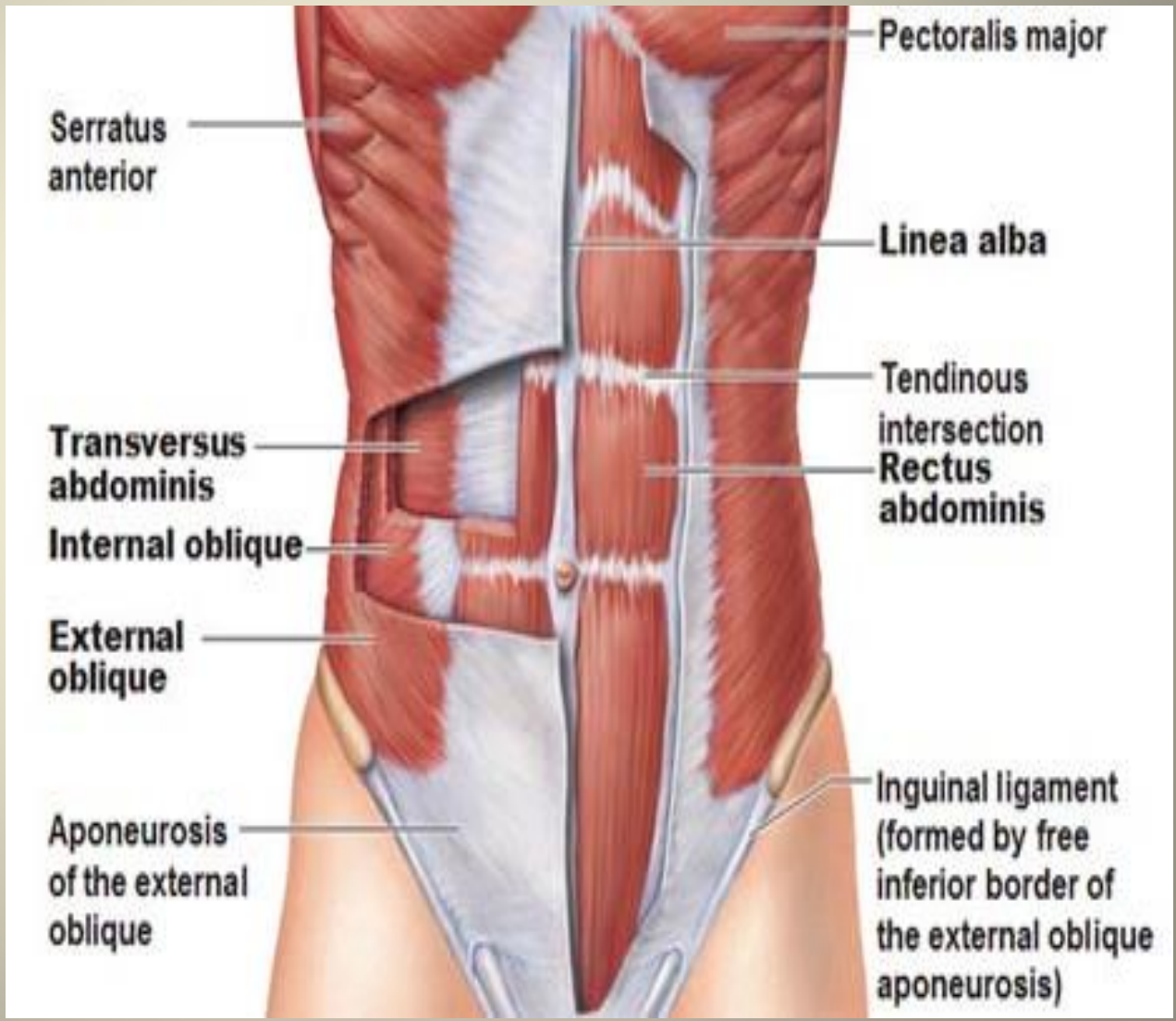

Anterior abdominal wall anatomy
Cross section

Anterior

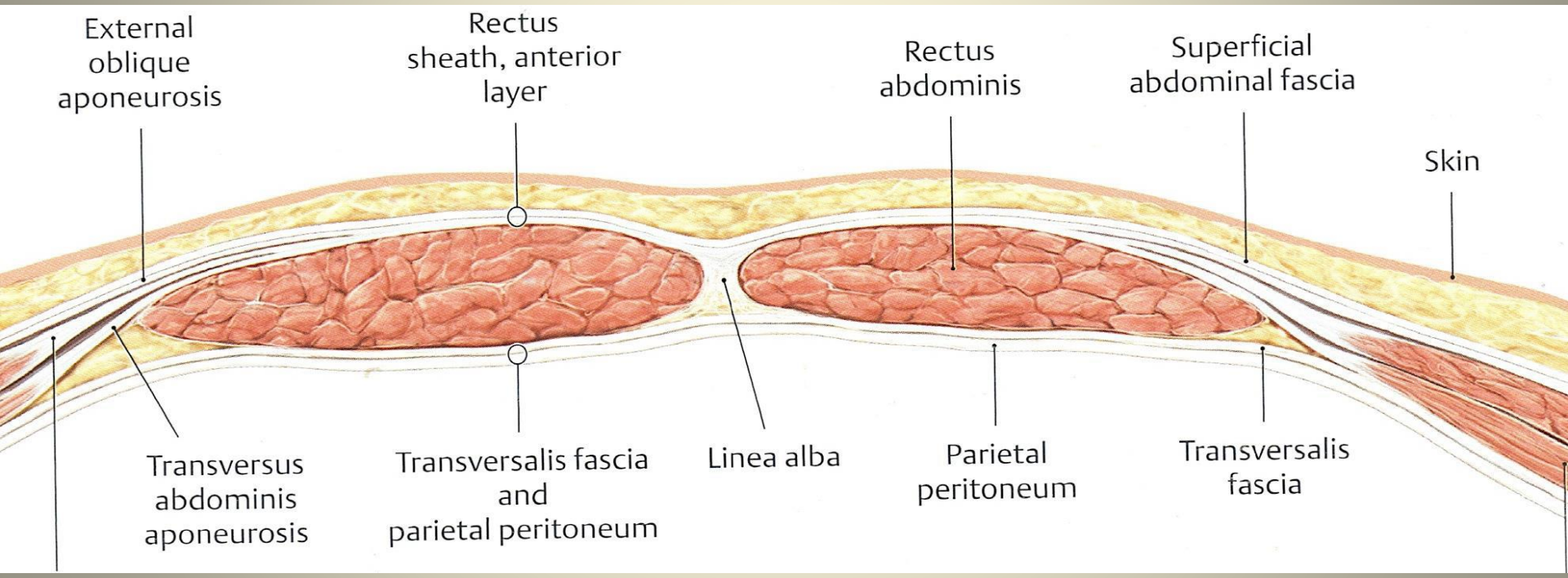

Internal oblique

Posterior

Ultrasound anterior abdominal wall anatomy

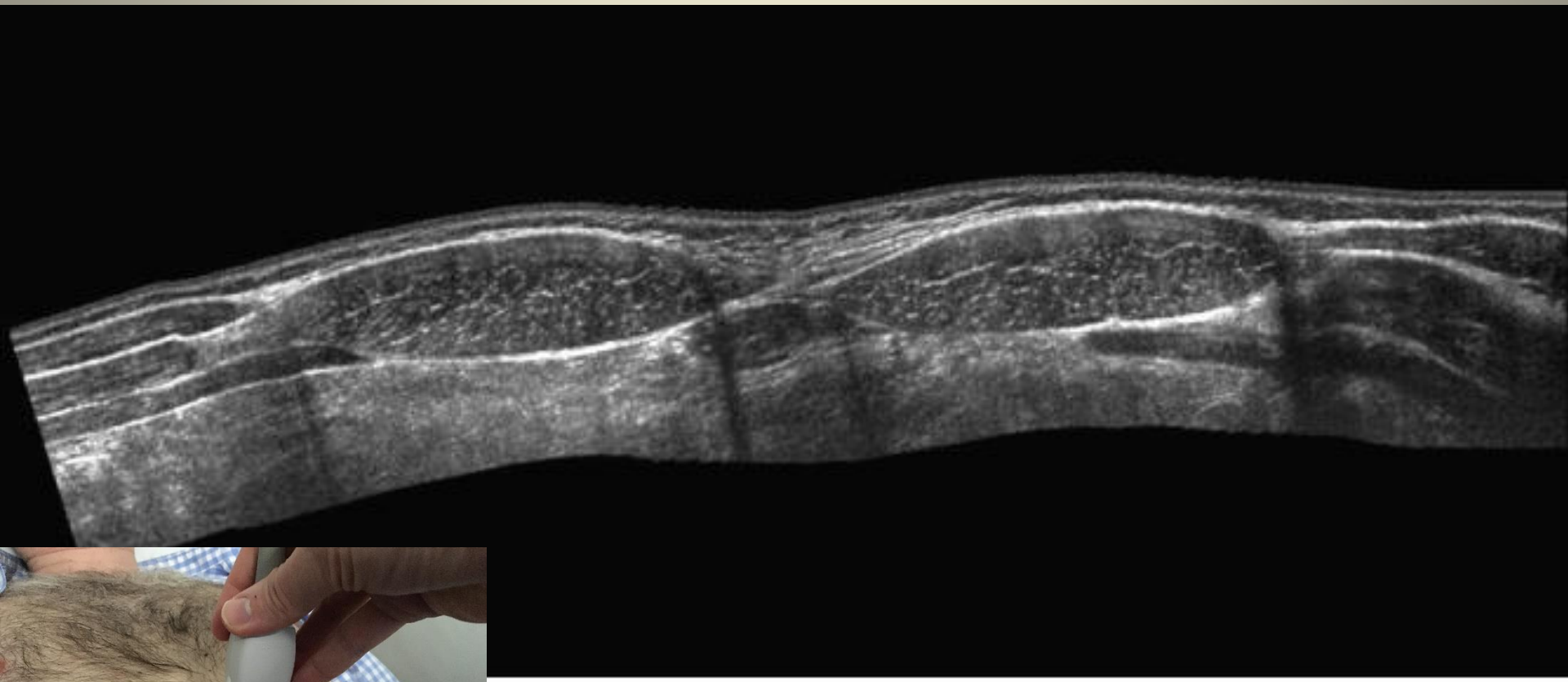

Rectus abdominis and linea alba

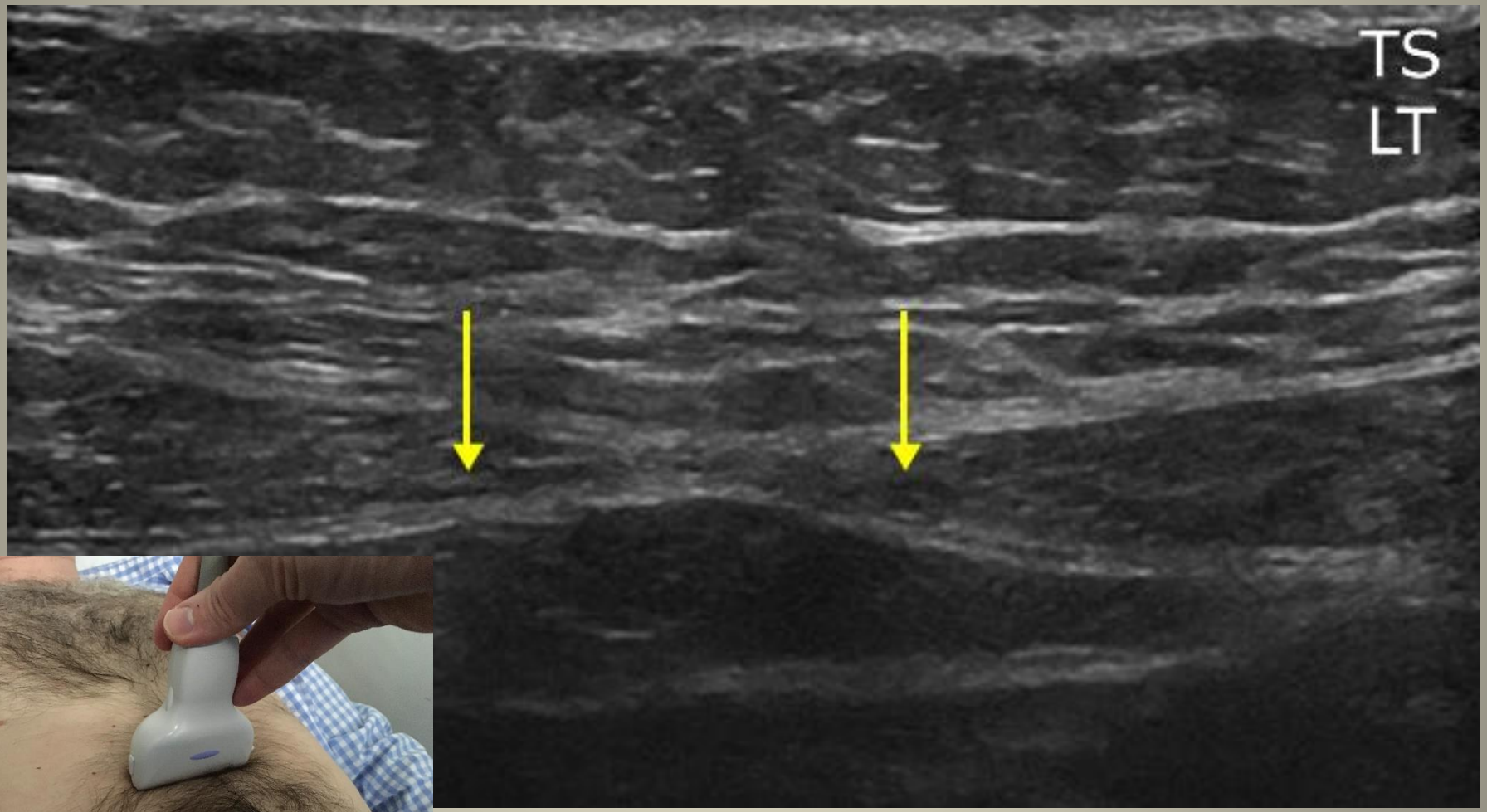

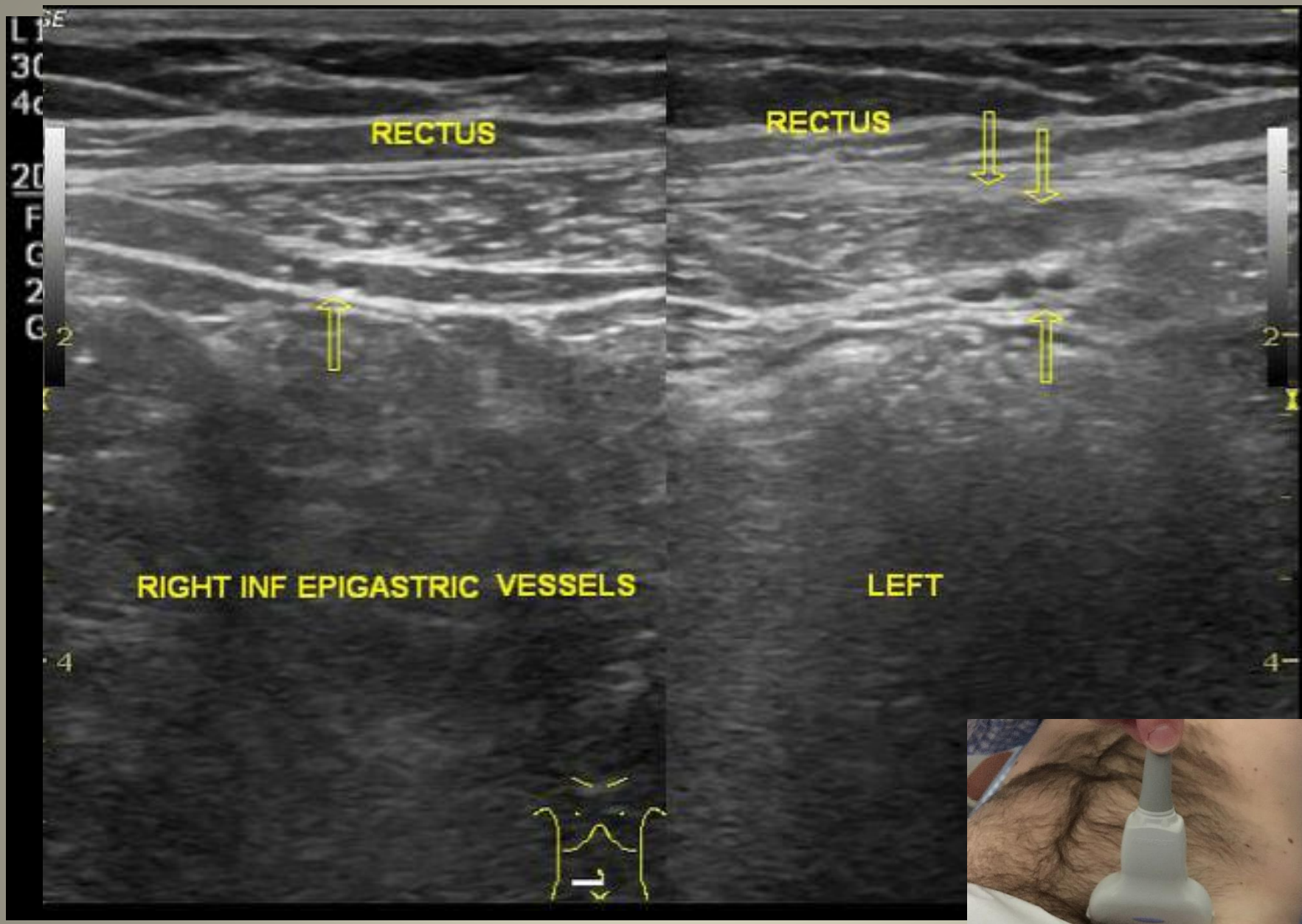
RECTUS
RECTUS
RIGHT INF EPIGASTRIC VESSELS
LEFT

Anterior abdominal wall

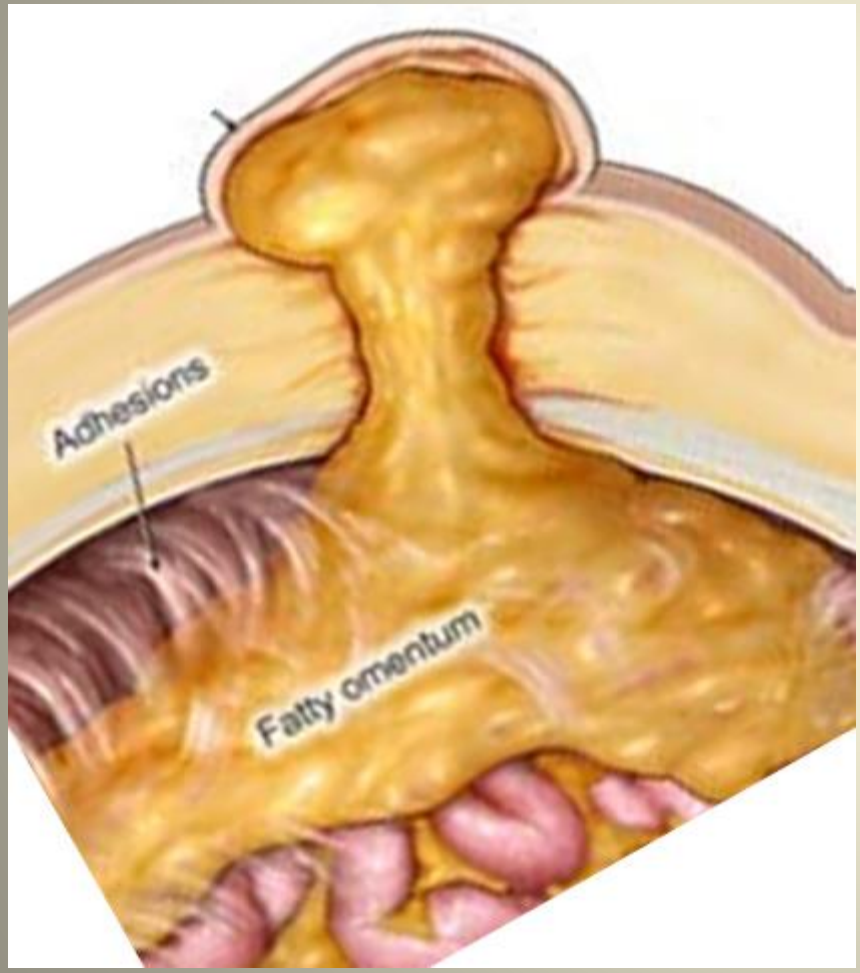

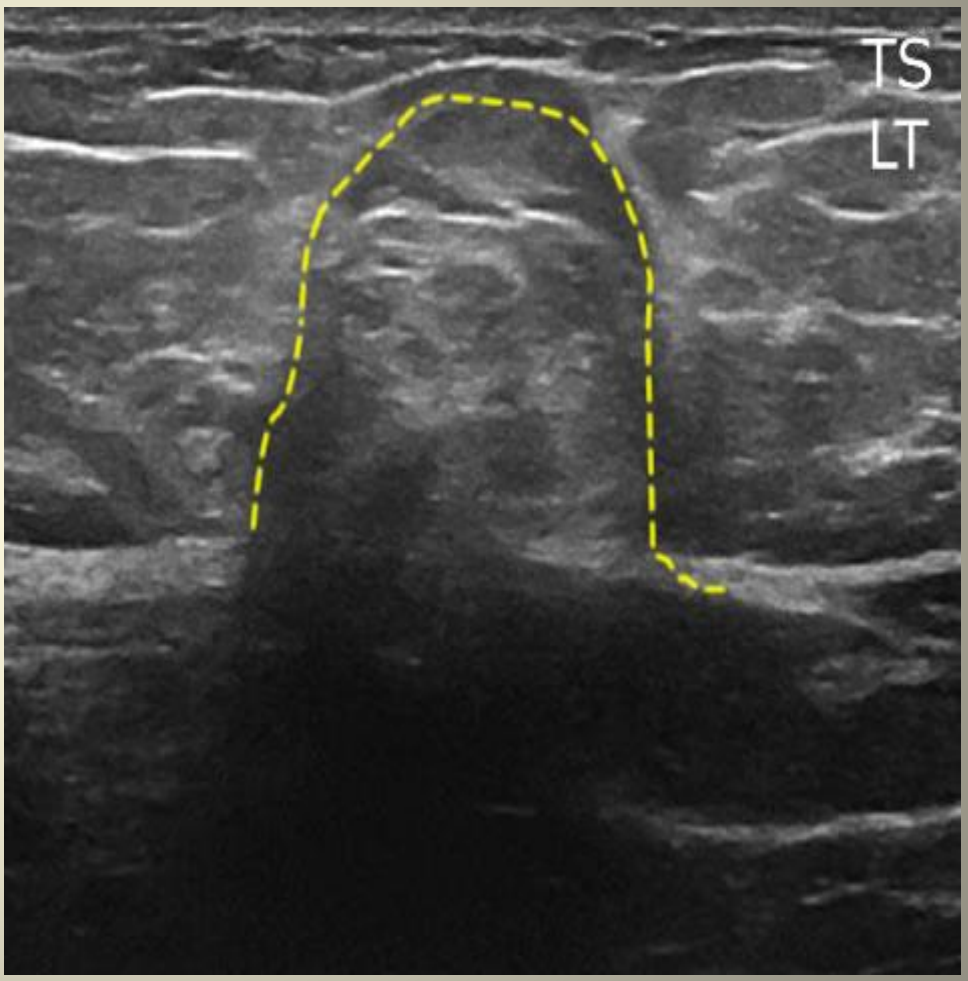

Anterior abdominal wall

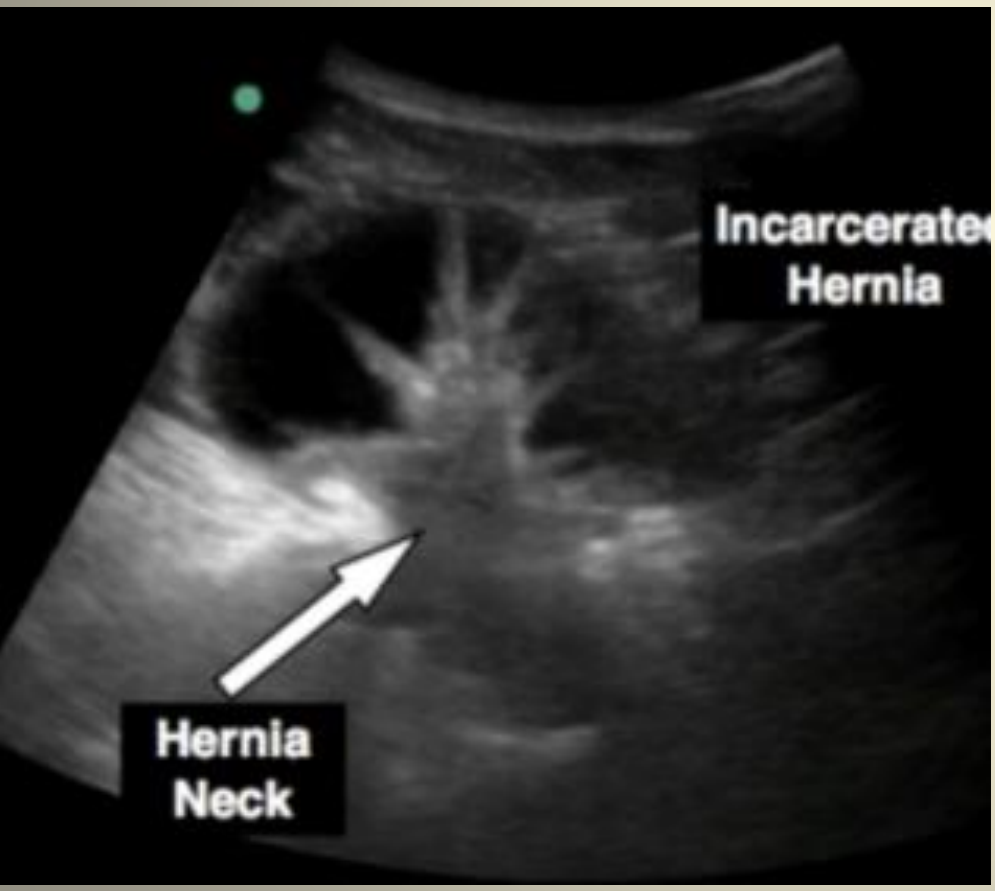

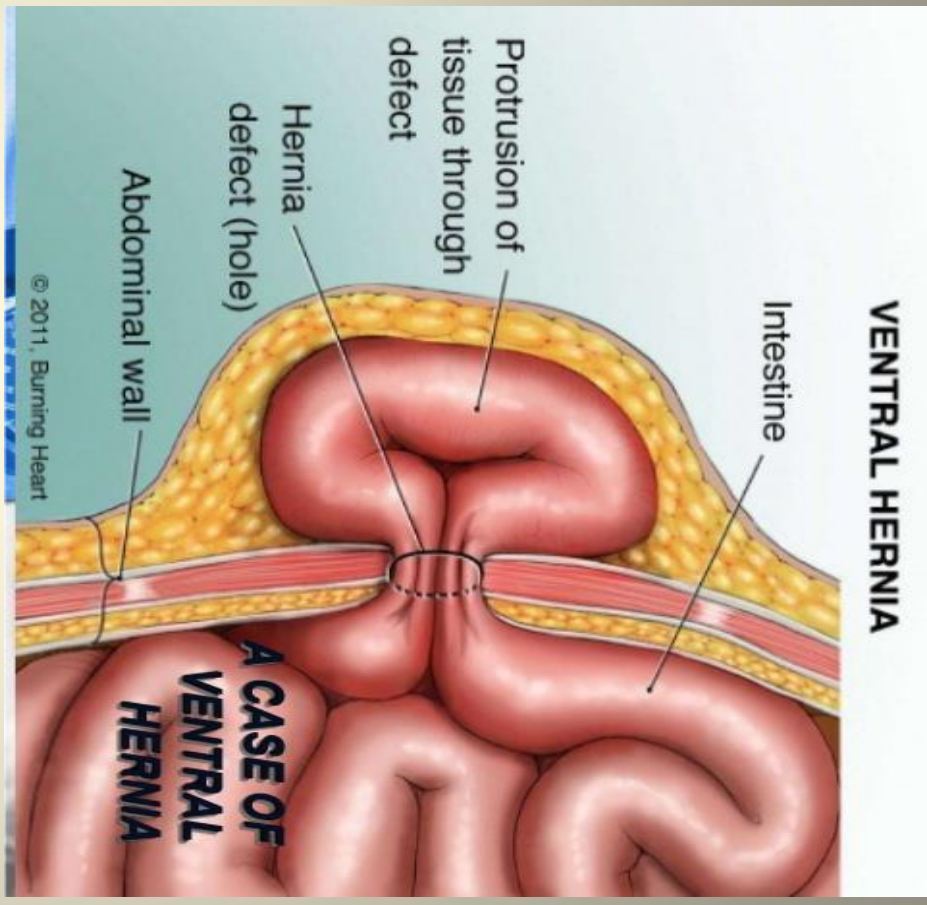

Epigastric hernia

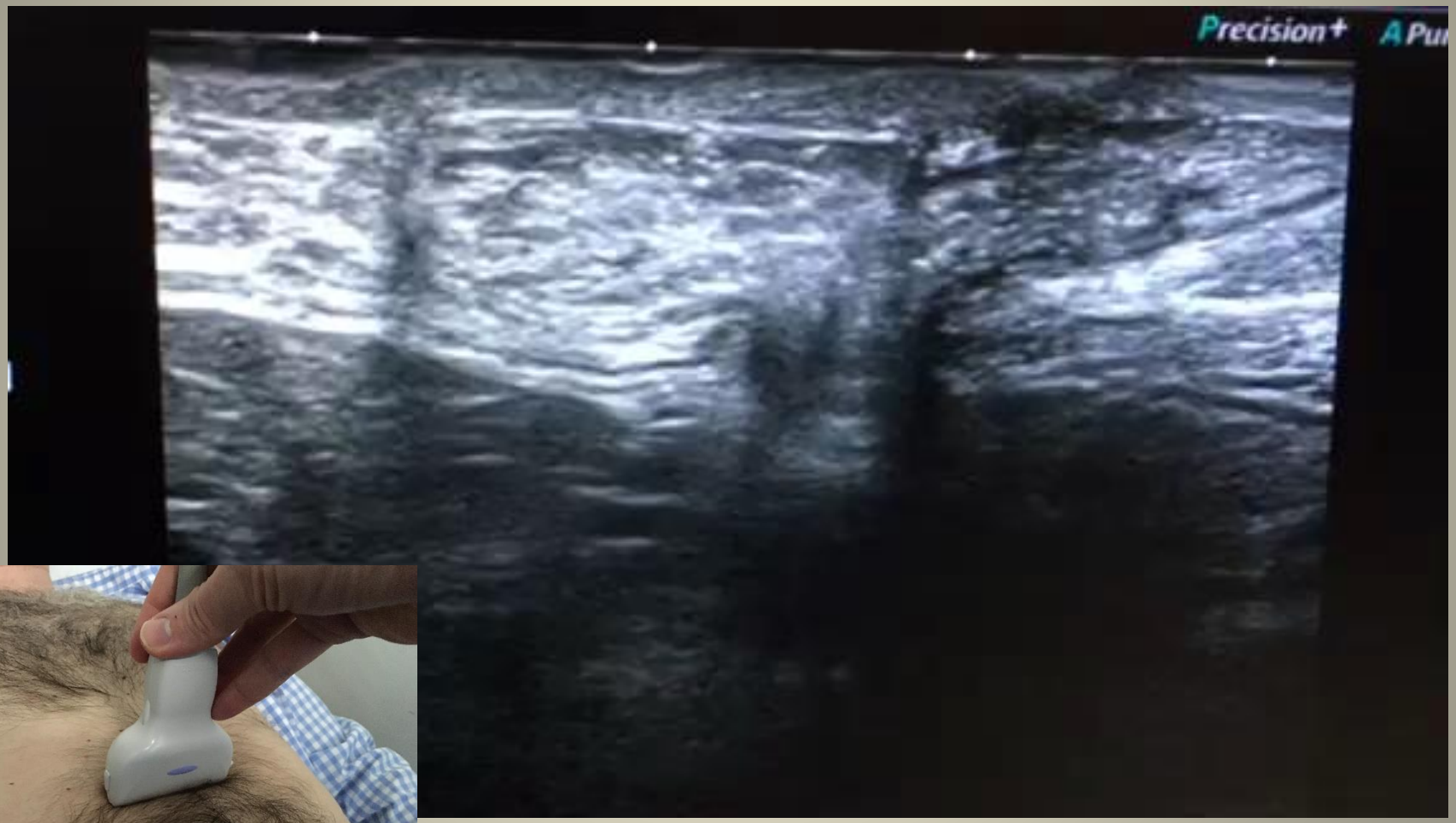

Spigelian hernia

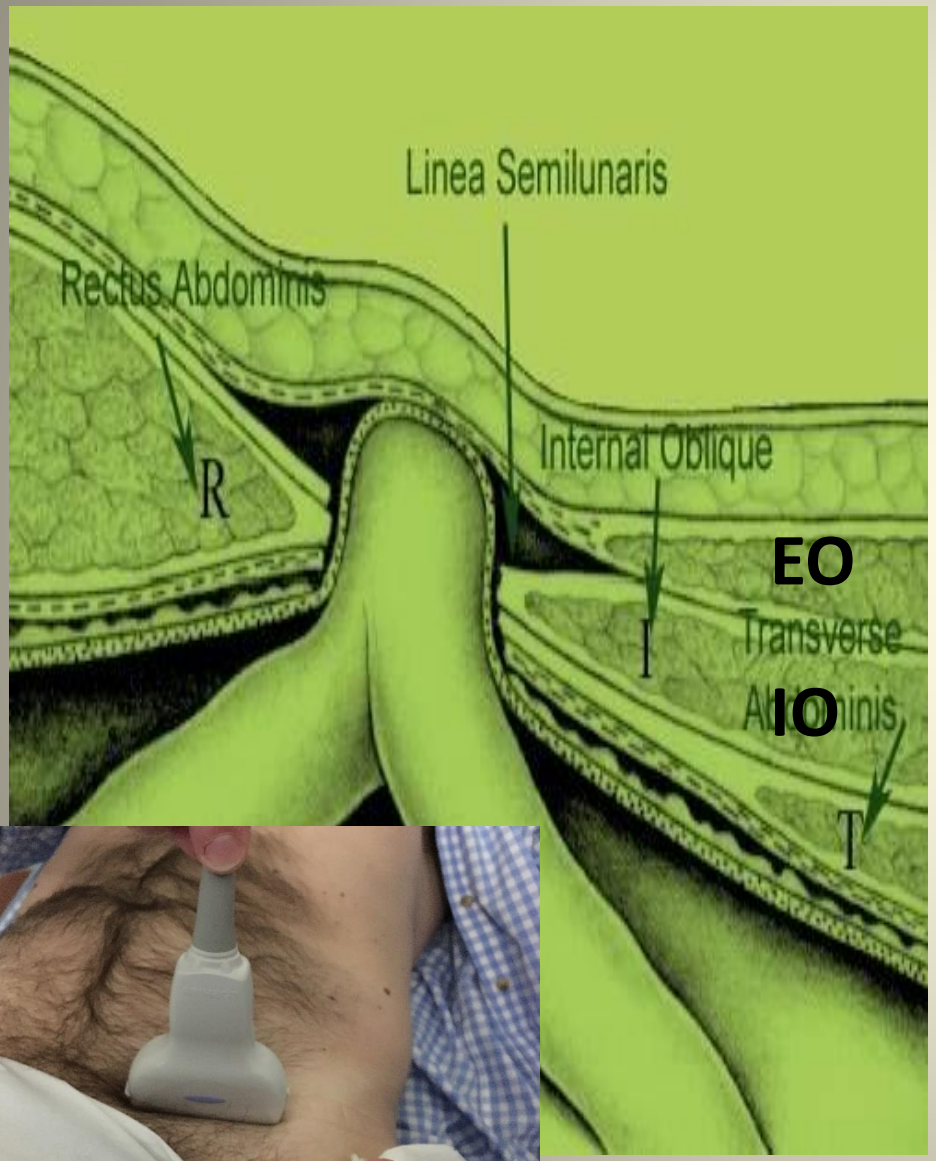

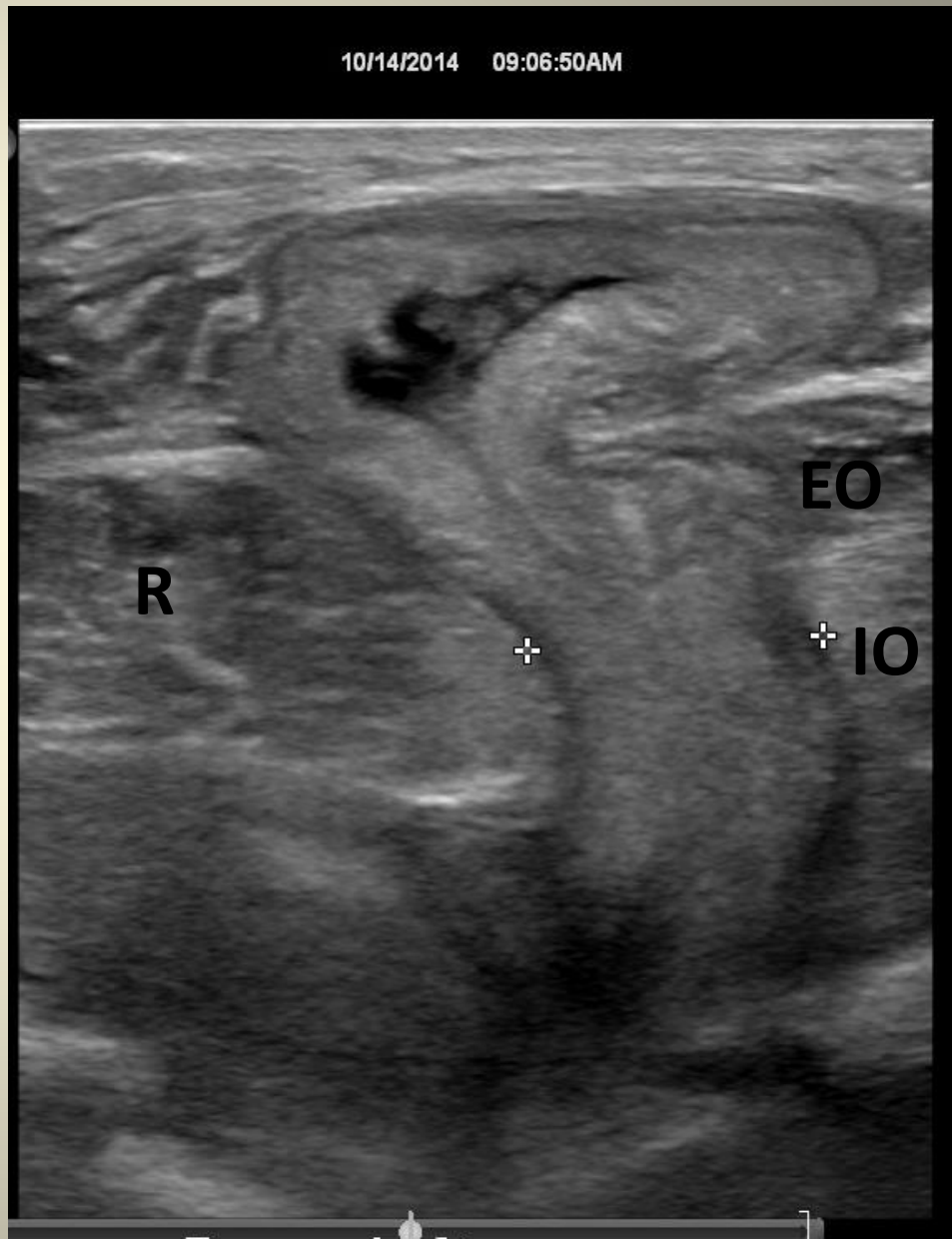

Incisional type hernia

Incisional hernia
- Through scar or defect
- Risk increased with age > poor healing
- Obesity
- Post op complications –infection, haematoma
- Steroid therapy
- Radiotherapy

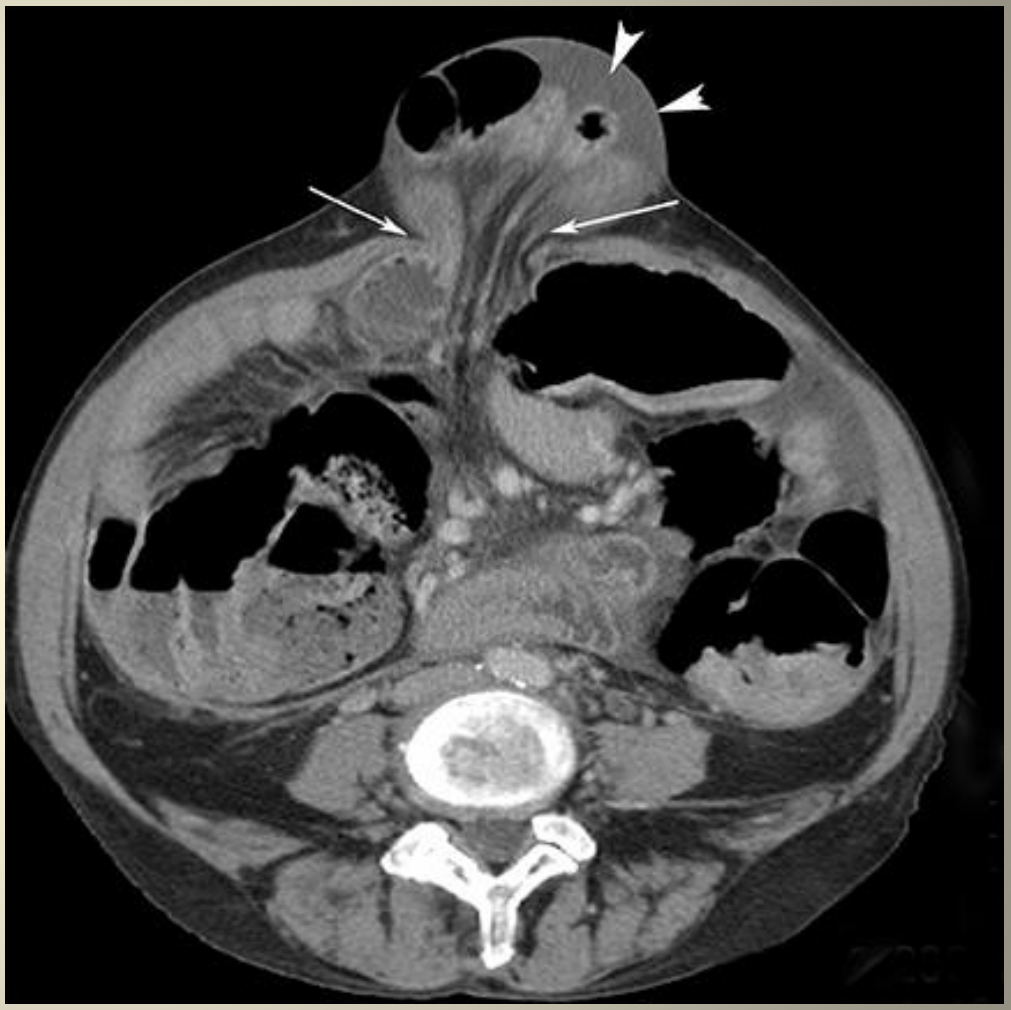

Divarication of the rectus abdominis muscles

Seroma

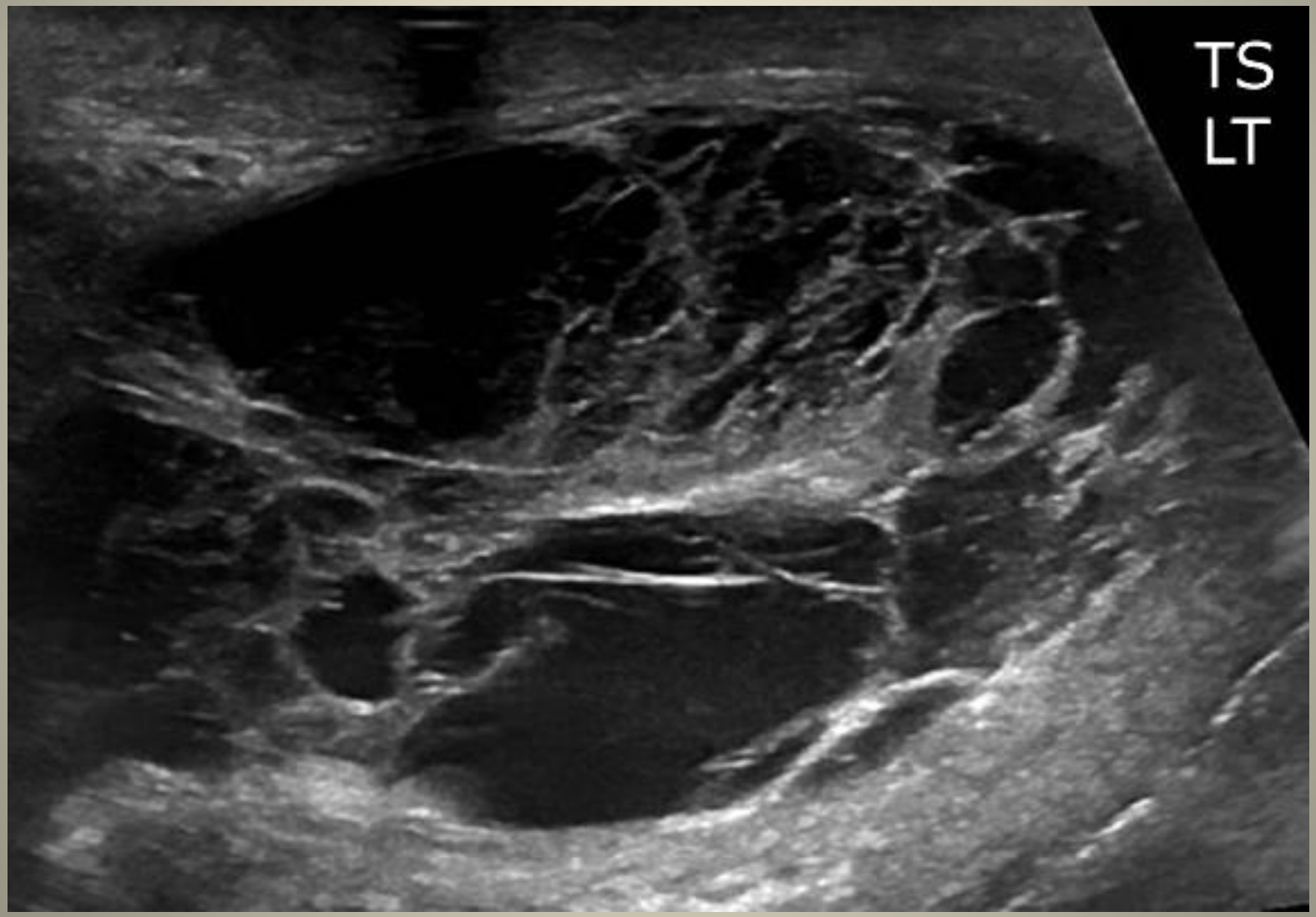

Abscess

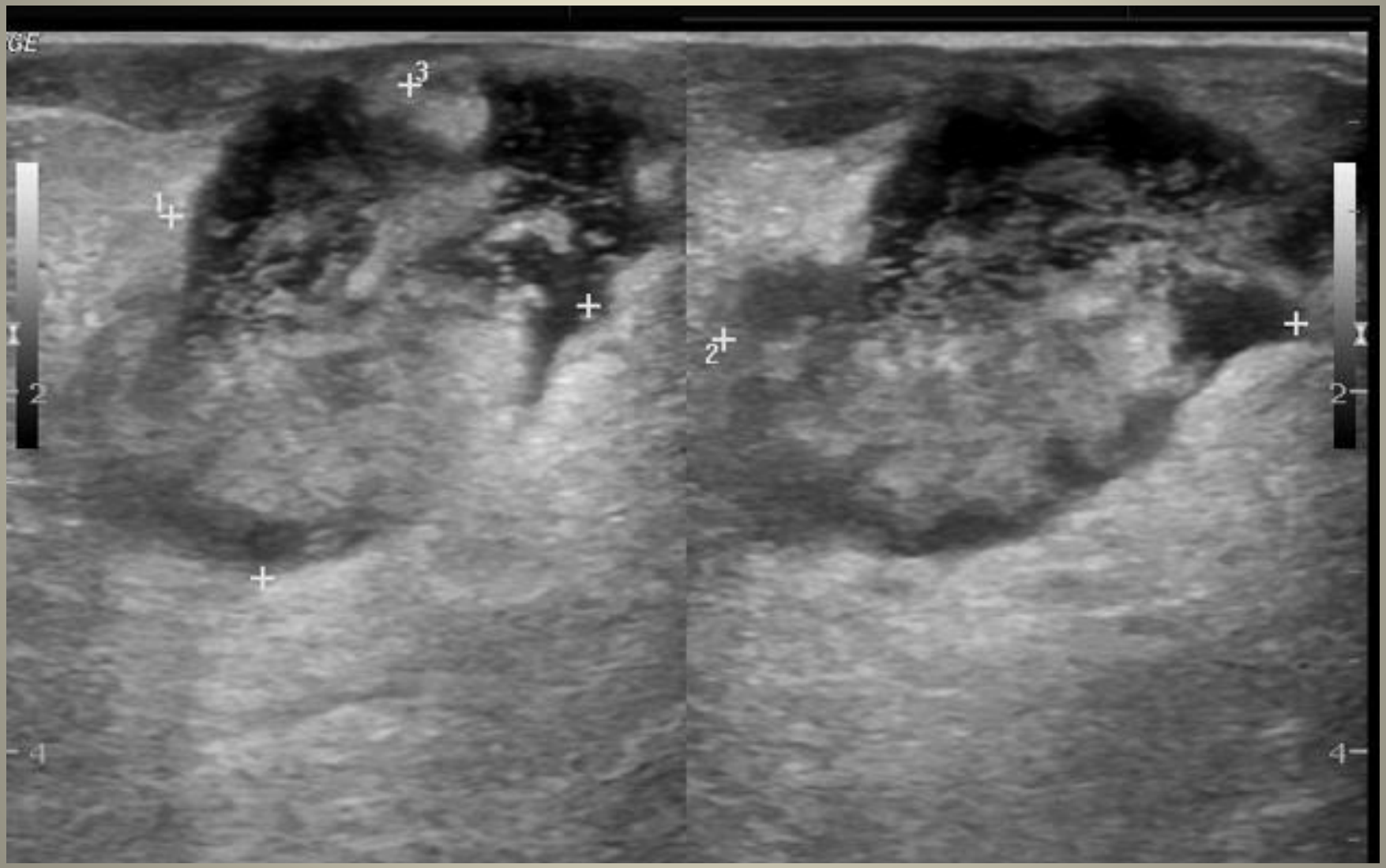

Groin anatomy

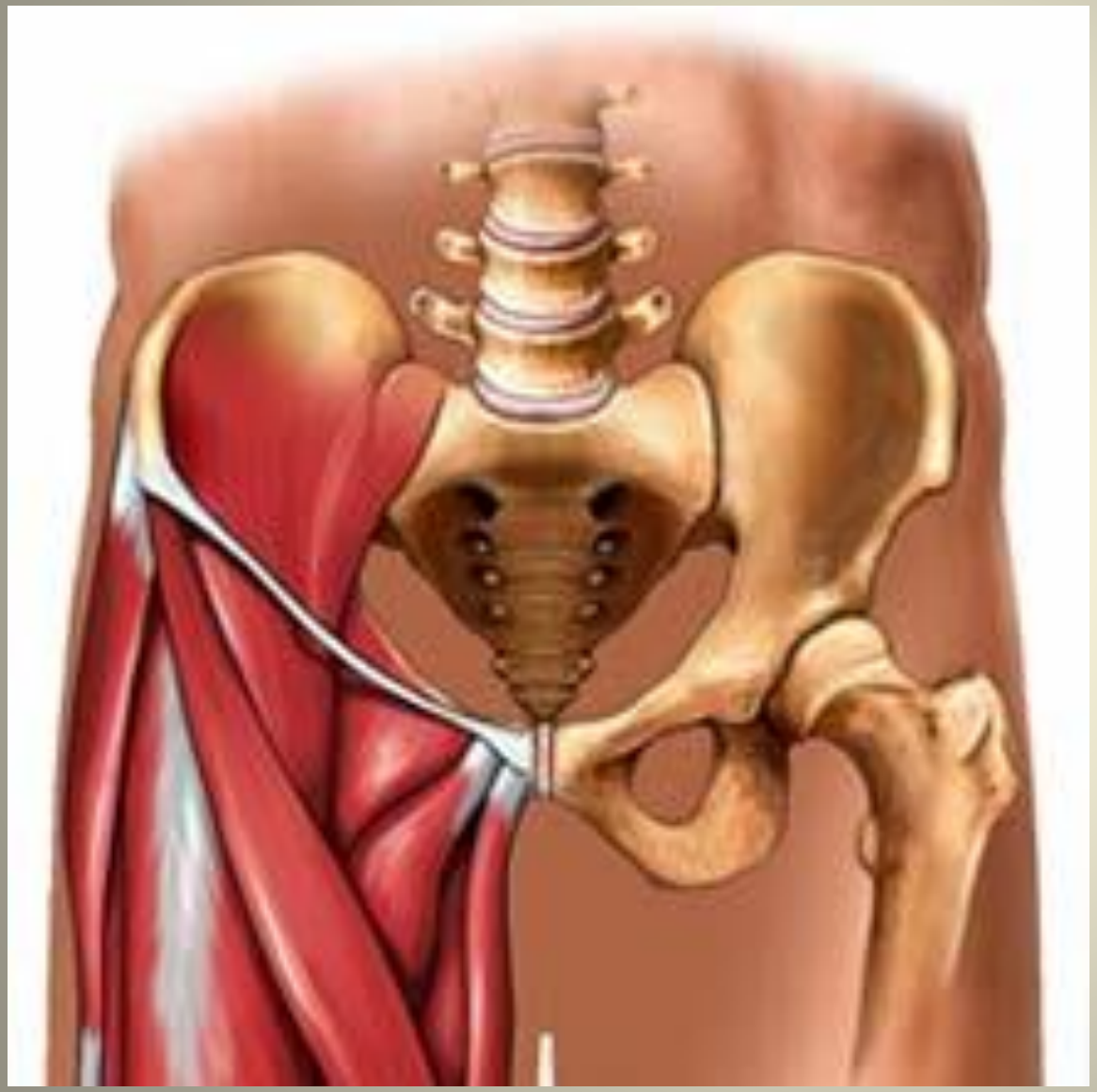

Groin contains the soft tissues of the inguinofemoral region between the ASIS and the symphsis pubis

Femoral vessels

Lymph nodes

Inguinal ligament

Inguinal canal located deep and medial to the inguinal ligament.

Formation of inguinal canal

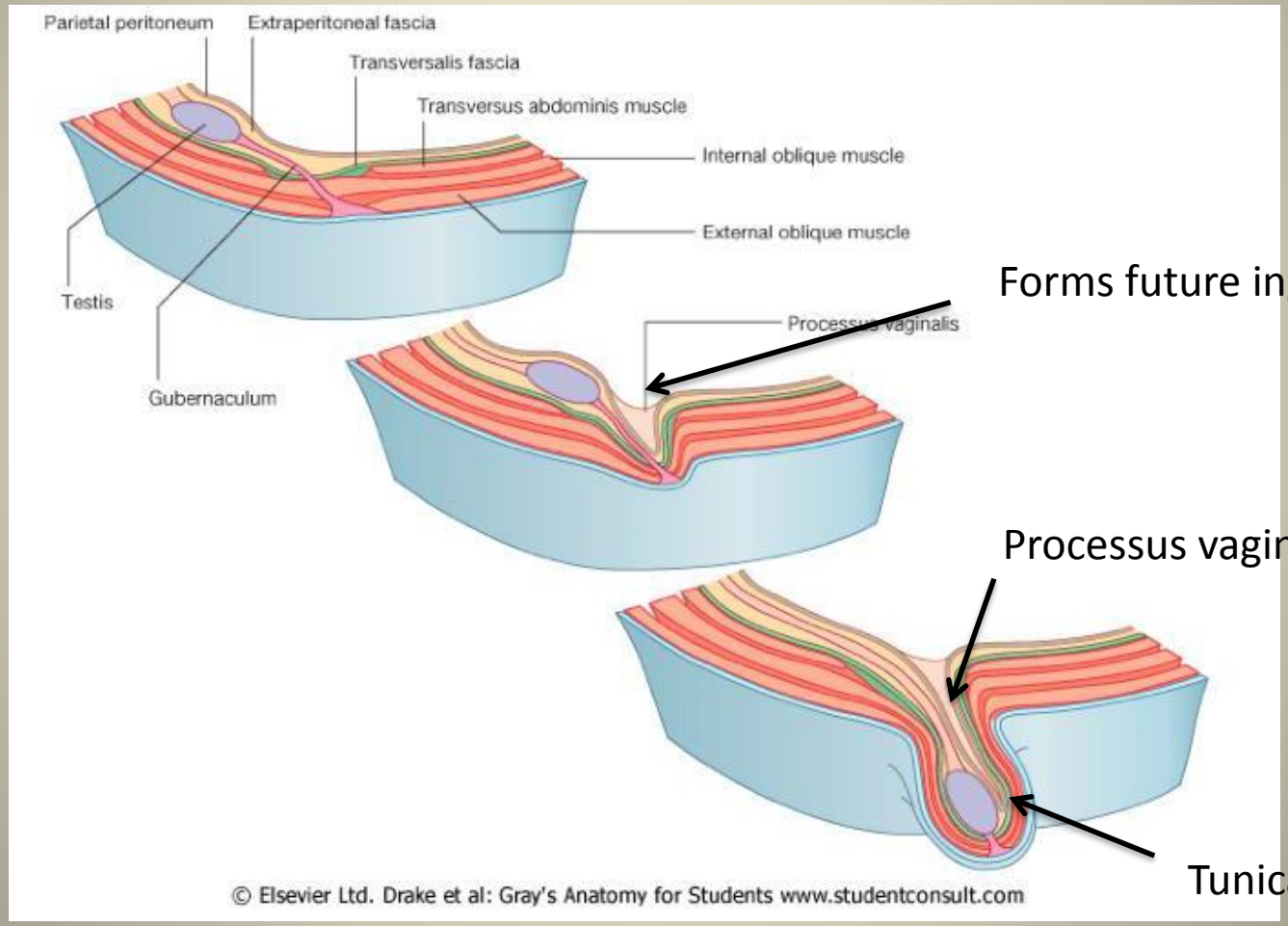

Forms future inguinal canal

Processus vaginalis closes off

Tunicavaginalis

Inguinal canal anatomy

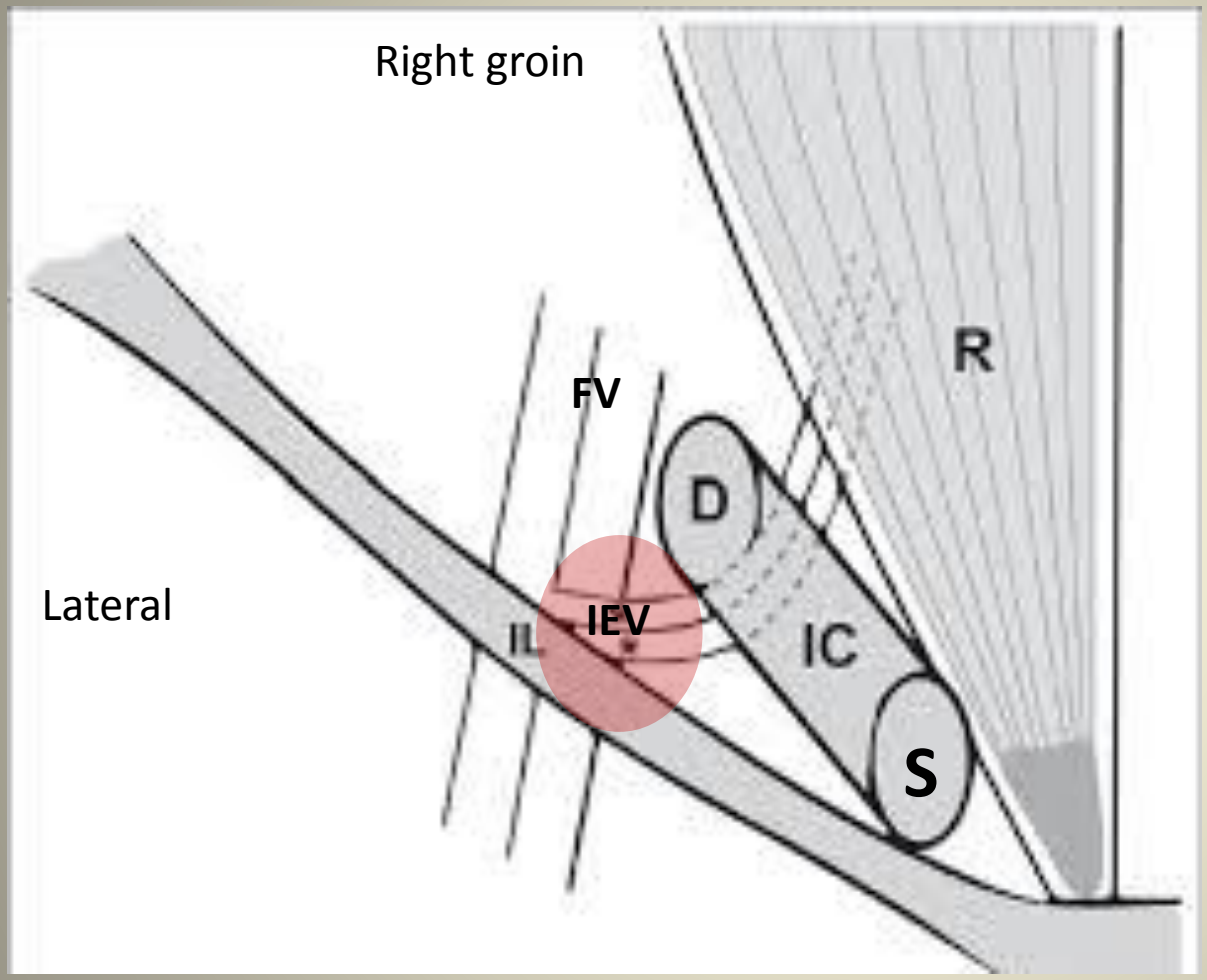

Deep ring located just medial at the point the inferior epigastric vessels meet the femoral vessels

D - deep ring, S – superficial ring, IC – inguinal canal,
IL – Inguinal ligament , R – rectus abdominis,

Ultrasound Anatomy- finding the inguinal canal

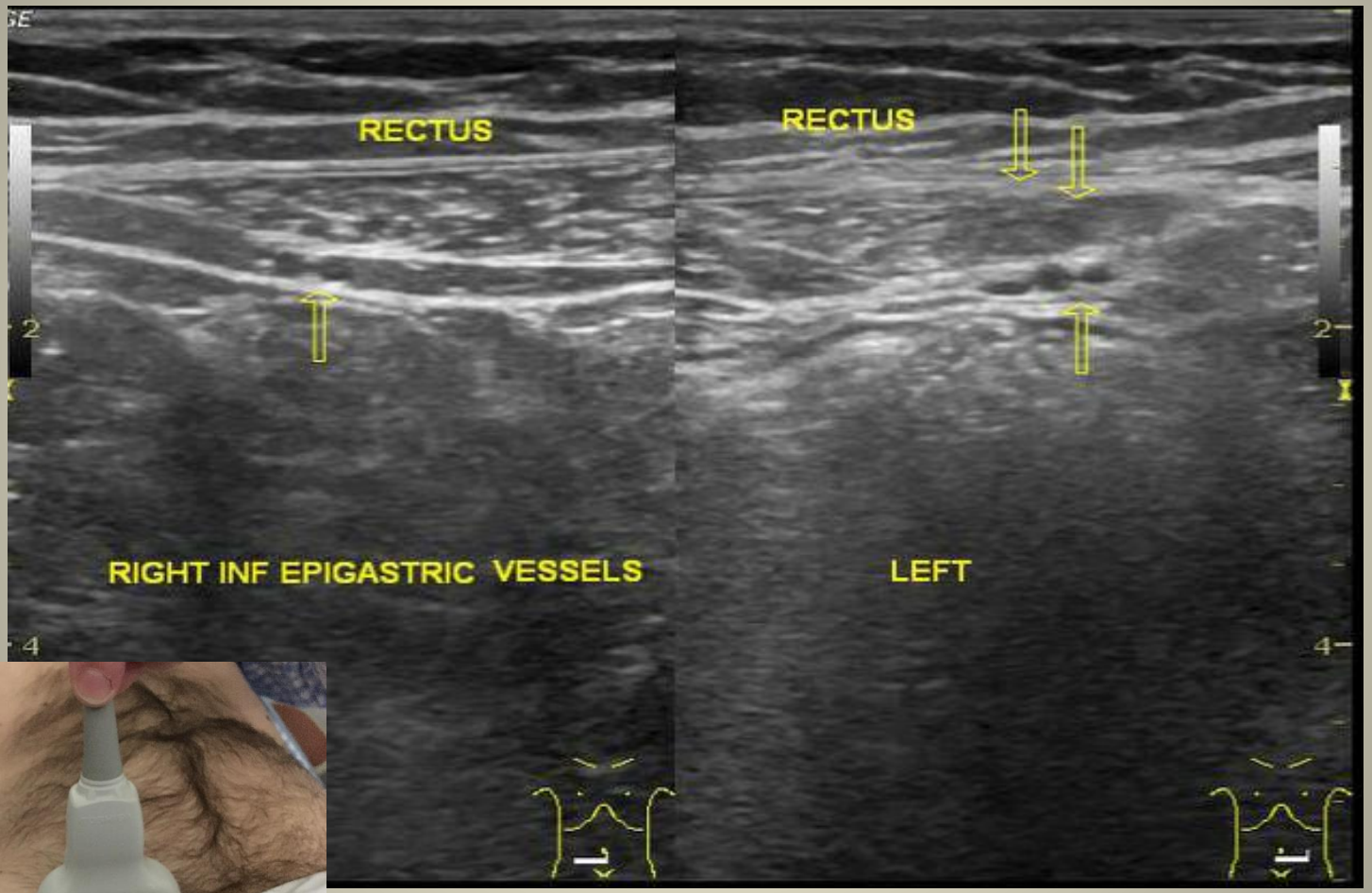

Step 1 – find the inferior epigastric vessels

Ultrasound Anatomy- finding the inguinal canal

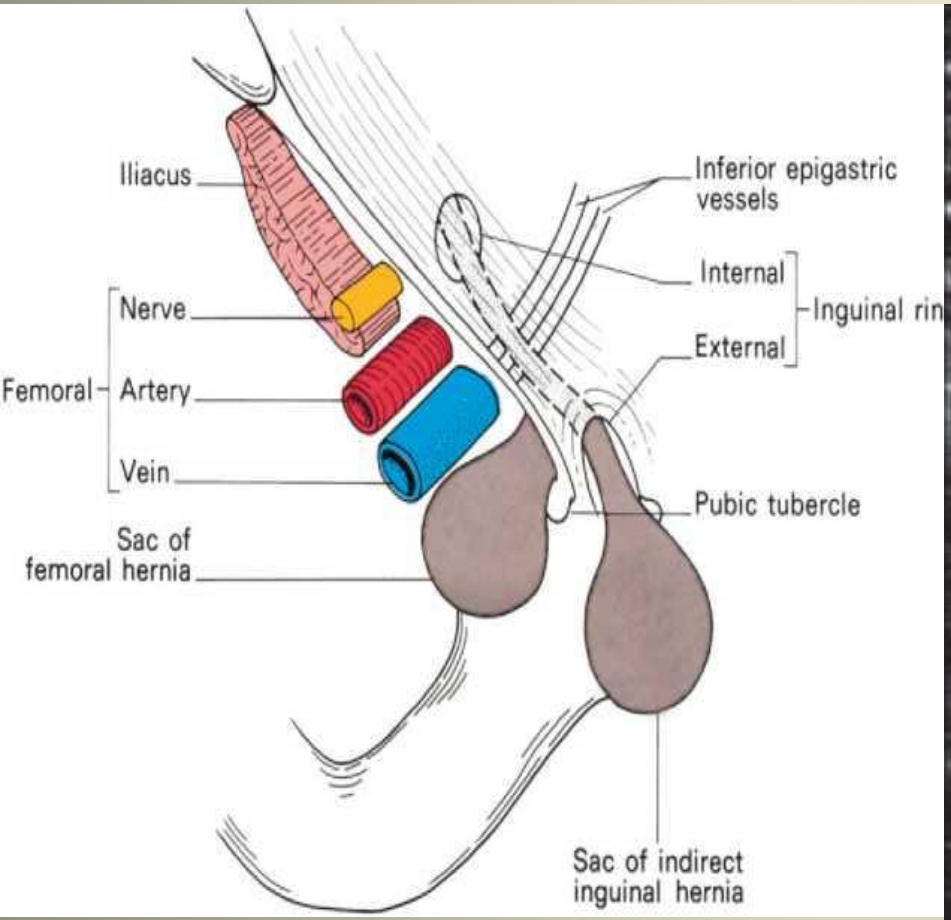

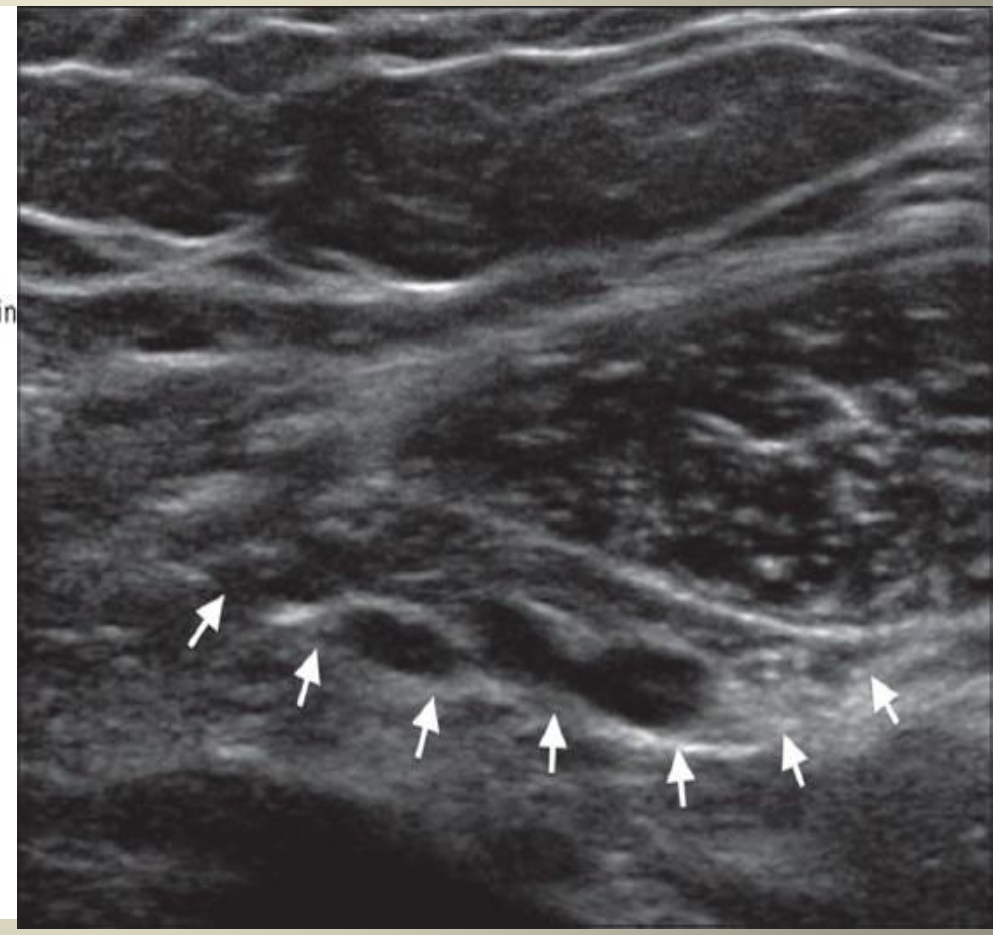

Step 2 – track the inferior epigastric vessels inferiorly and lateral to the point they joint the femoral vessels.

Ultrasound Anatomy- finding the inguinal canal

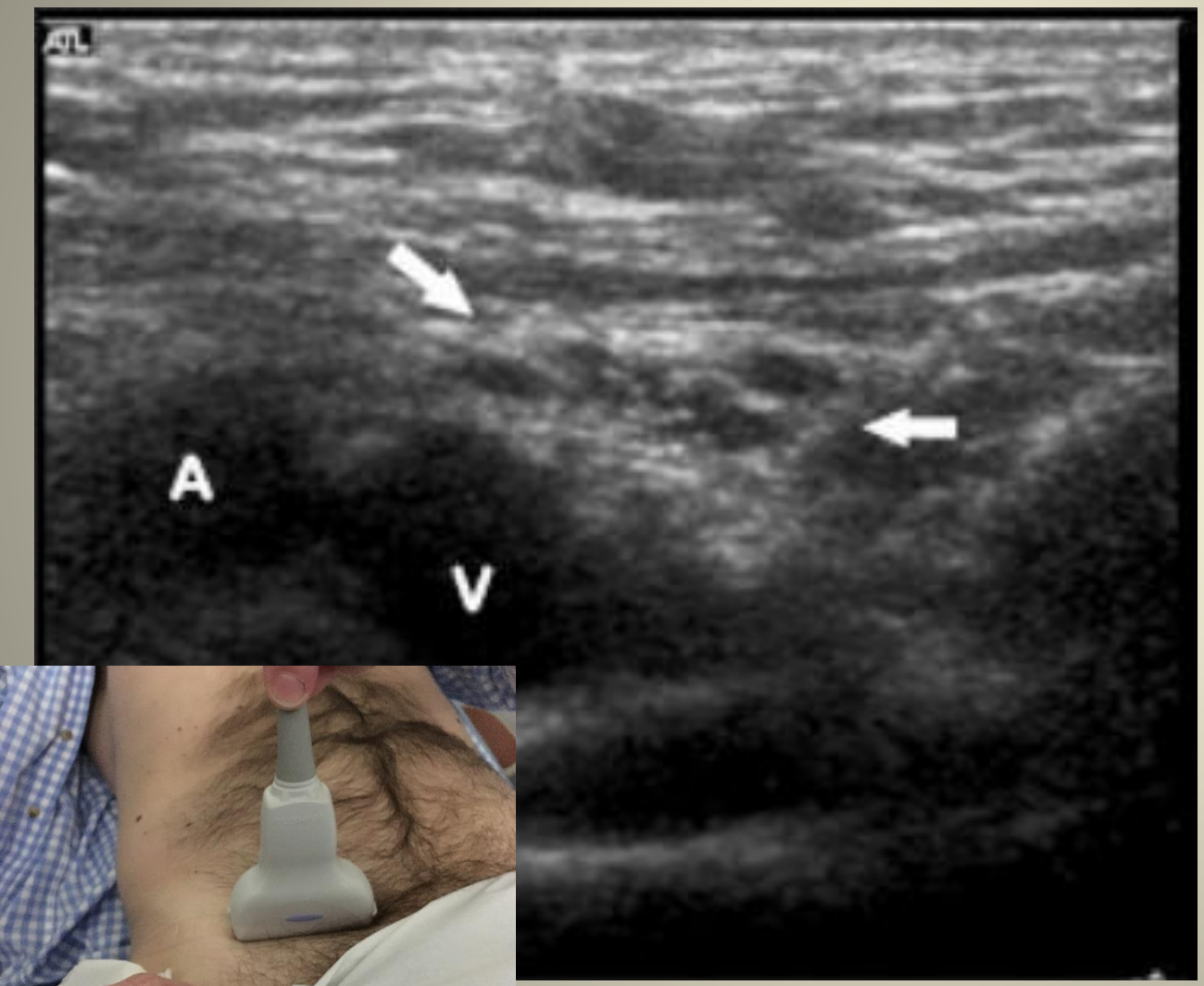

Step 3 –

At the point the inferior epigastric vessels meet the femoral vessels, the deep ring of the inguinal canal can be found.

Ultrasound Anatomy- finding the inguinal canal

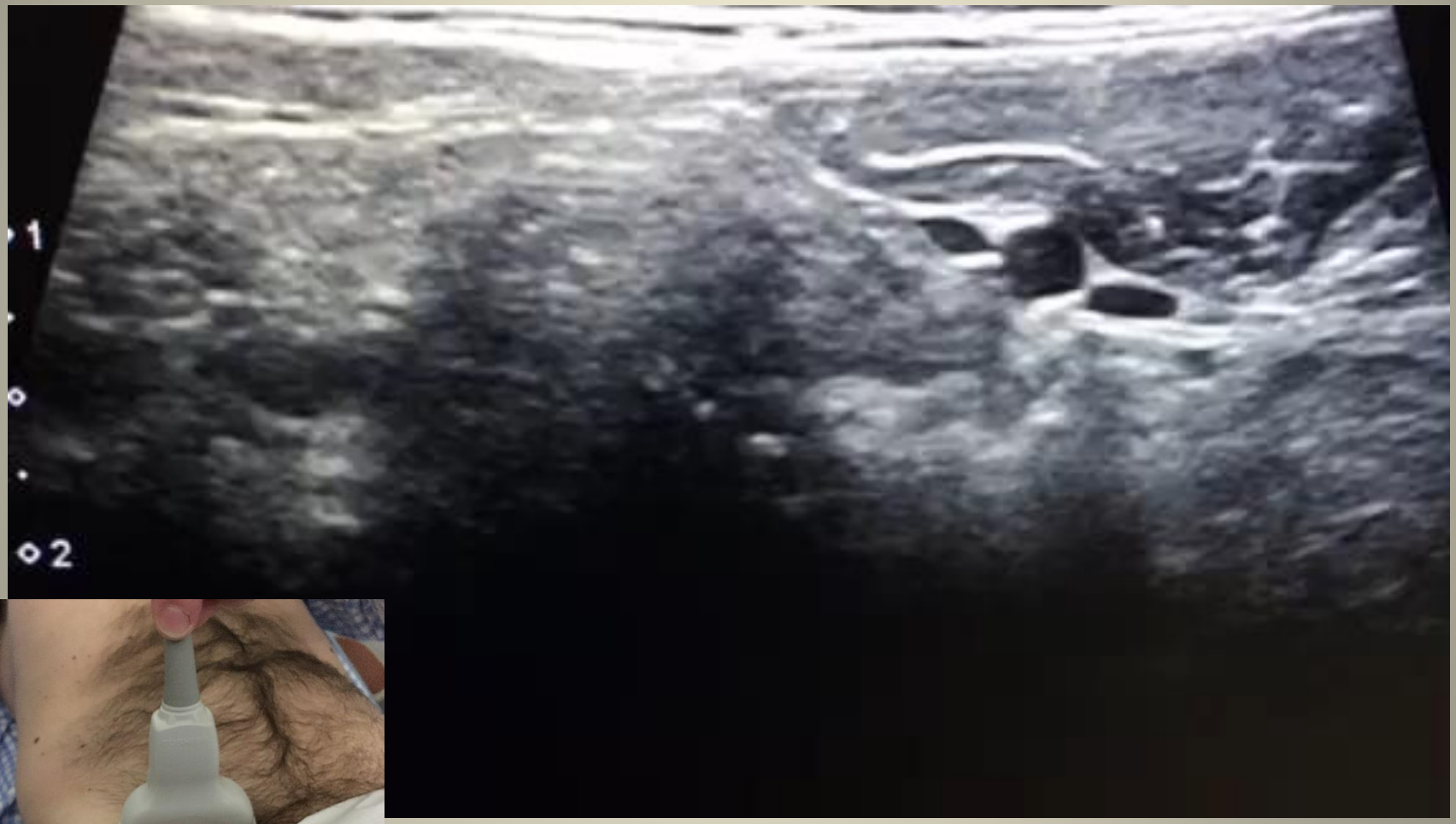

Inguinal canal transverse section

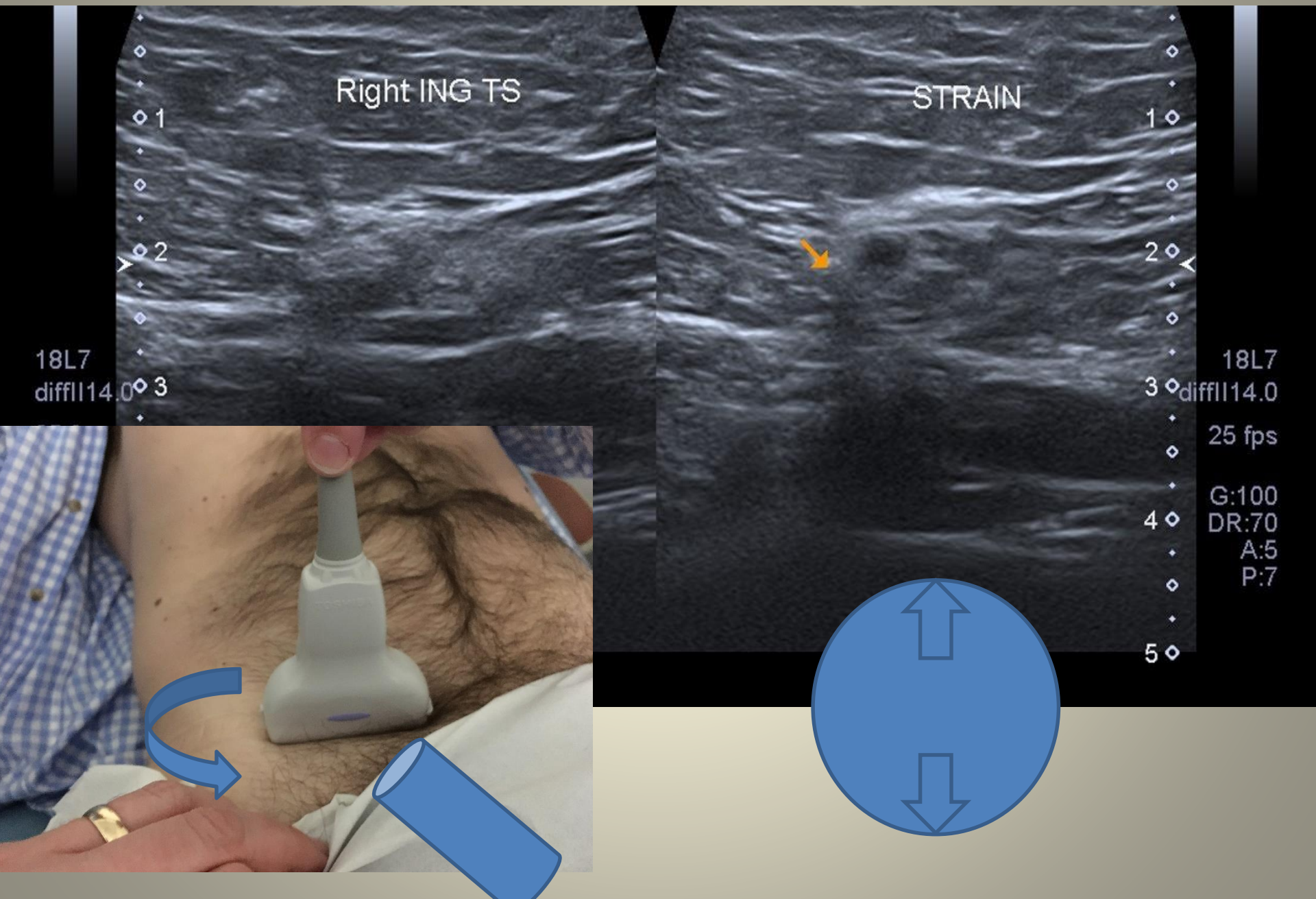

Inguinal canal longitudinal

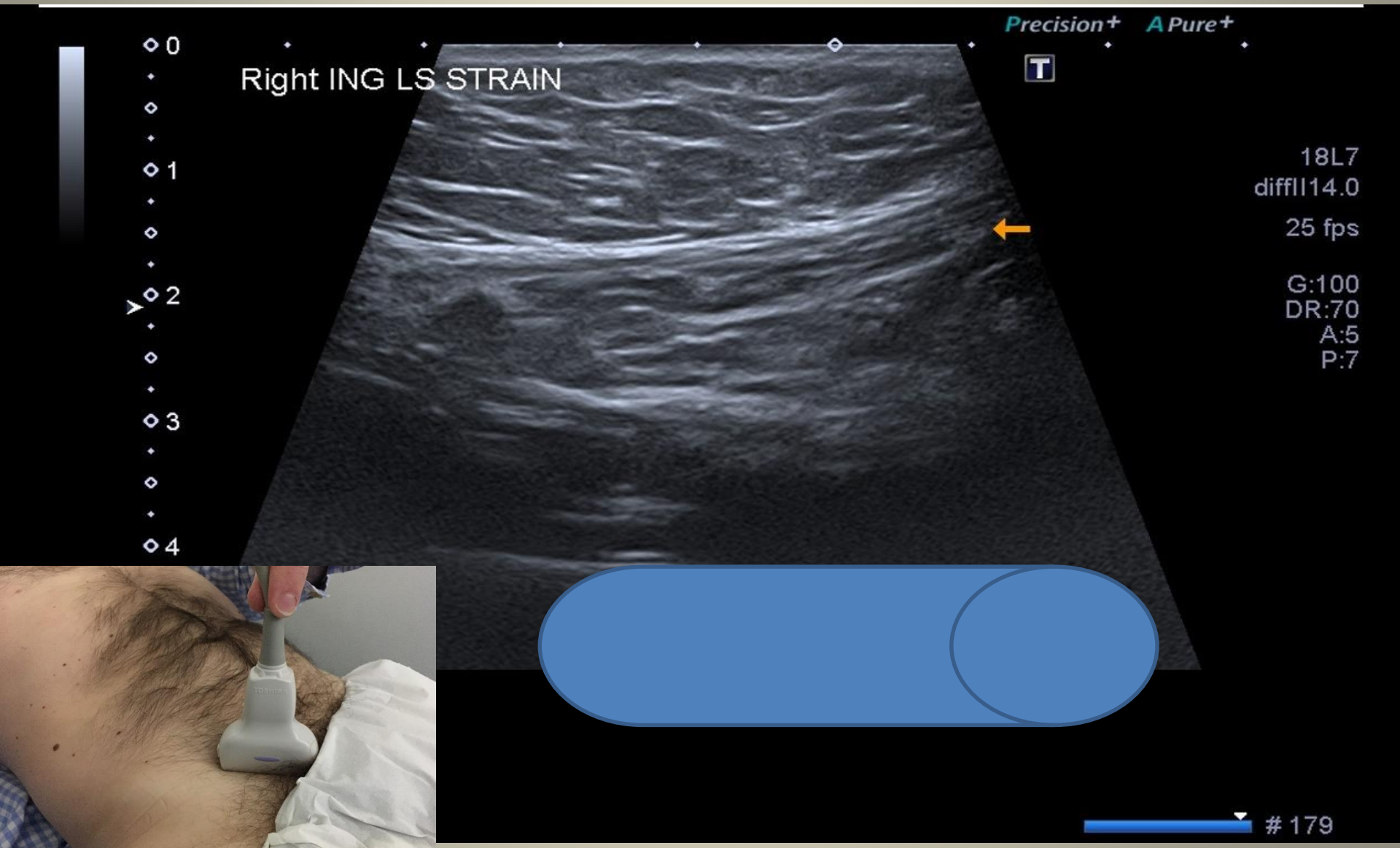

Inguinal hernia

- Male > Female
- In UK, 2011-12, 60,000 inguinal hernia repairs

Two types of inguinal hernia

Indirect - (most common) abdominal contents protrude through the deep inguinal ring into the inguinal canal

Direct – abdominal contents enter into the inguinal canal through a weak point in the posterior wall

Also: Sportman's hernia/Gilmores groin/ pre hernia.

Indirect inguinal hernia – short axis

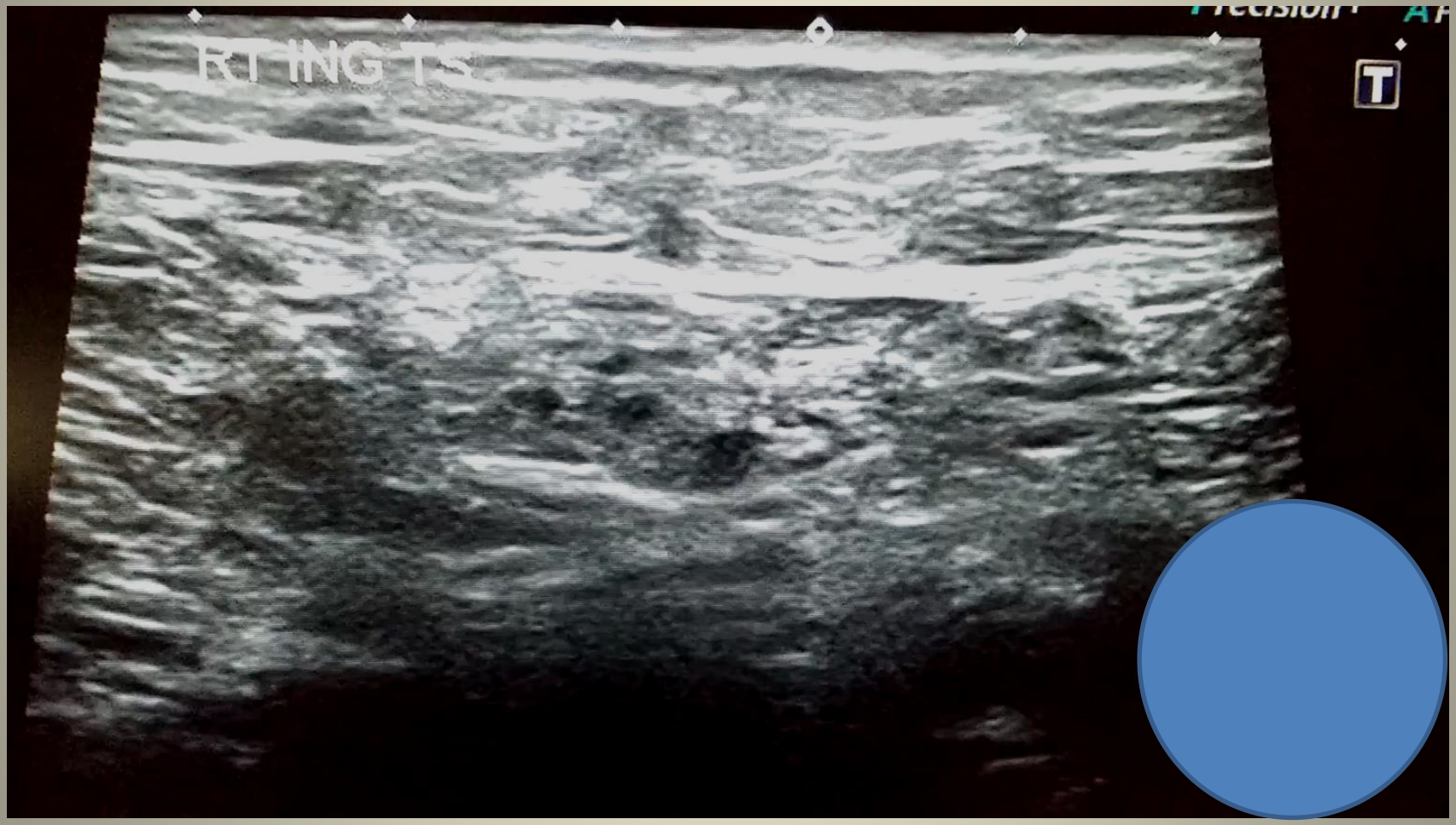

Inguinal hernia – indirect: Contents enter the inguinal canal through the deep /internal ring

Indirect inguinal hernia - longitudinal

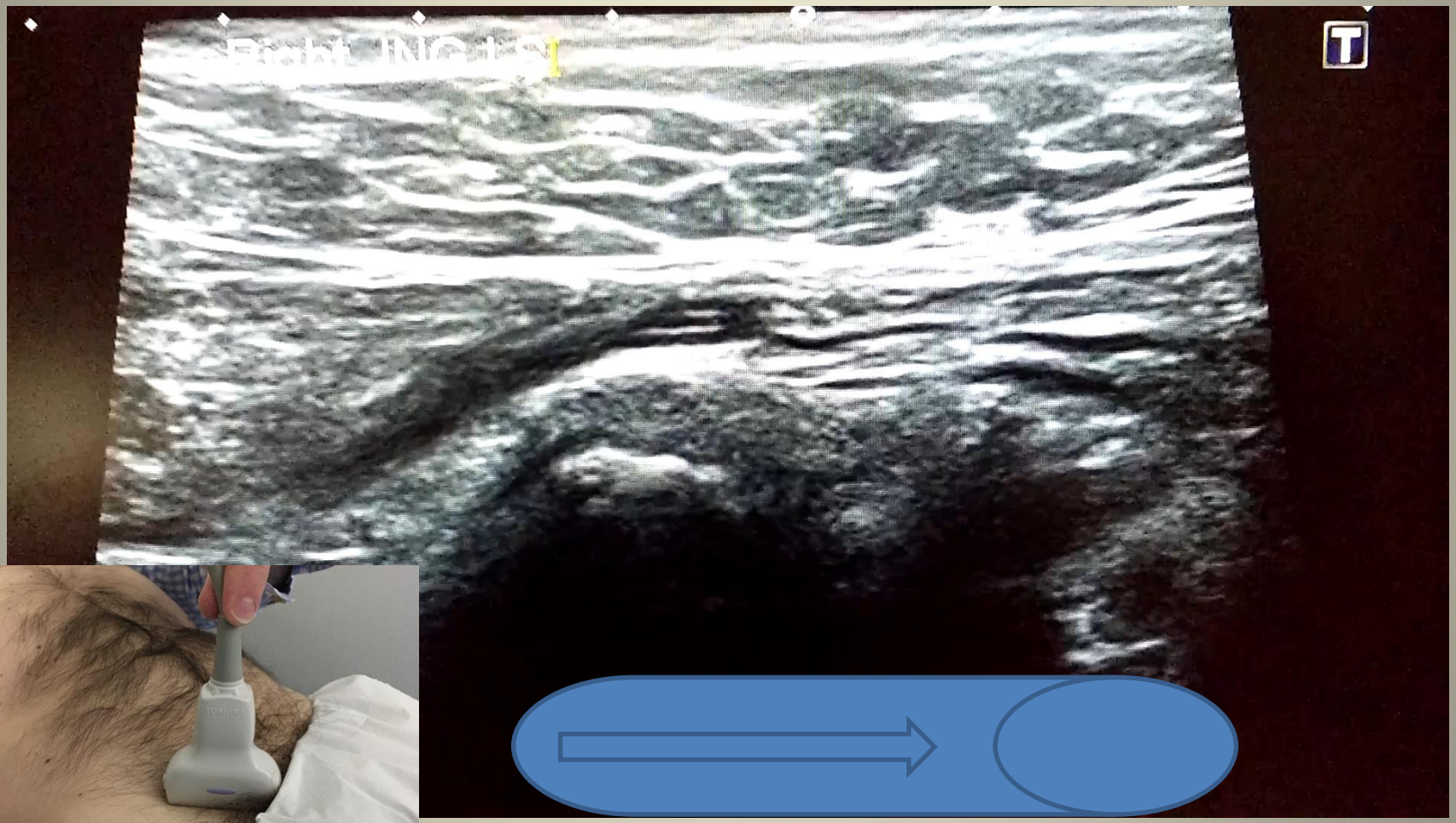

Direct inguinal hernia

Medial

Lateral

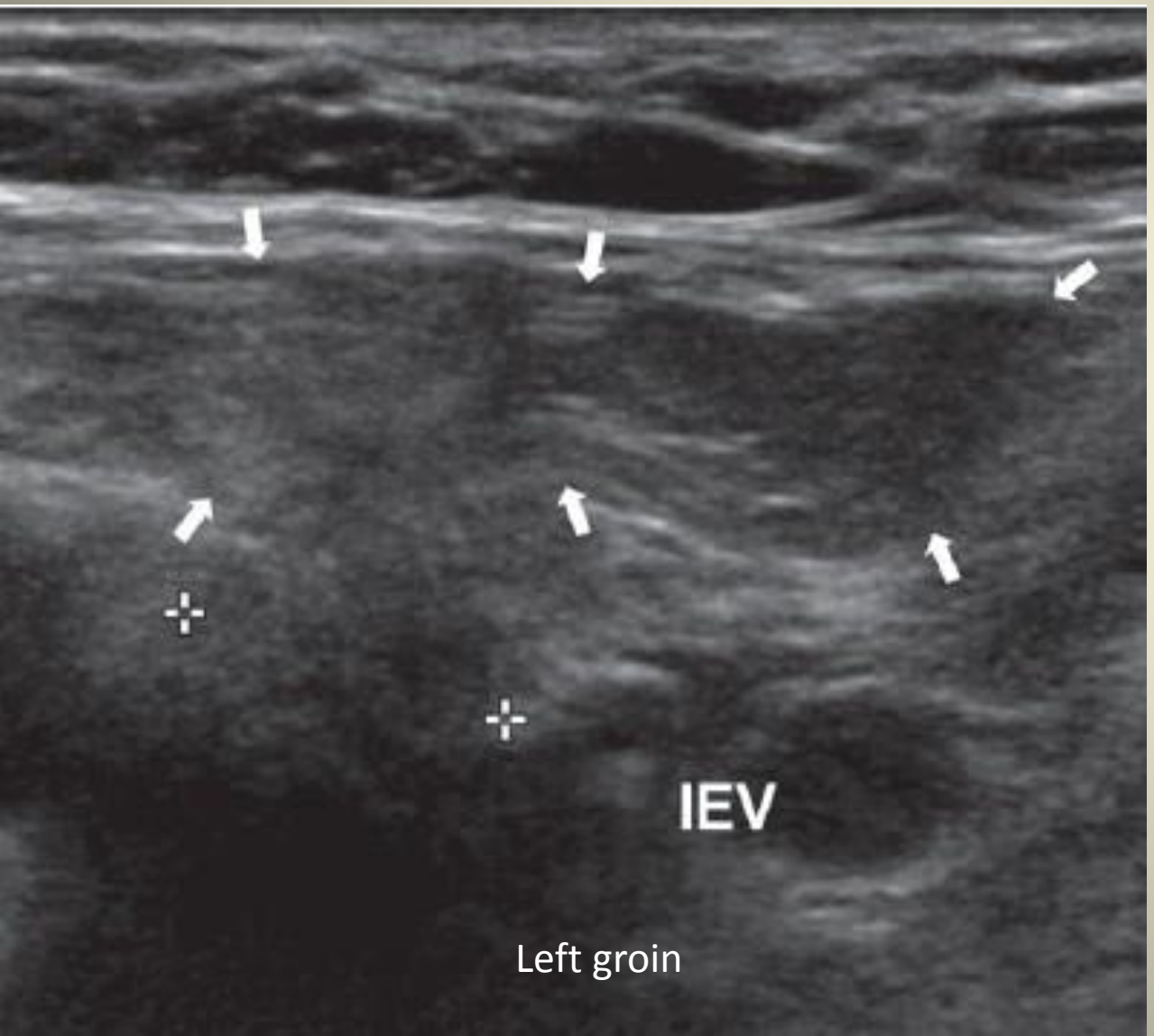

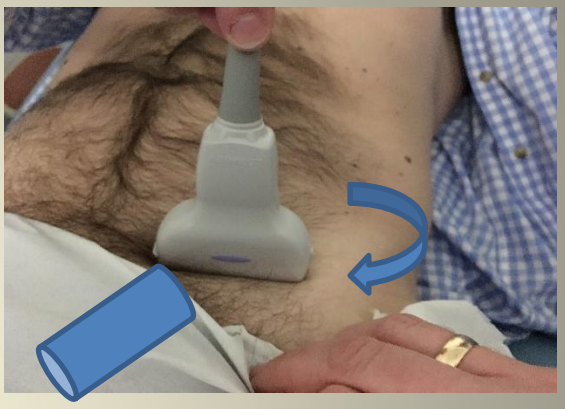

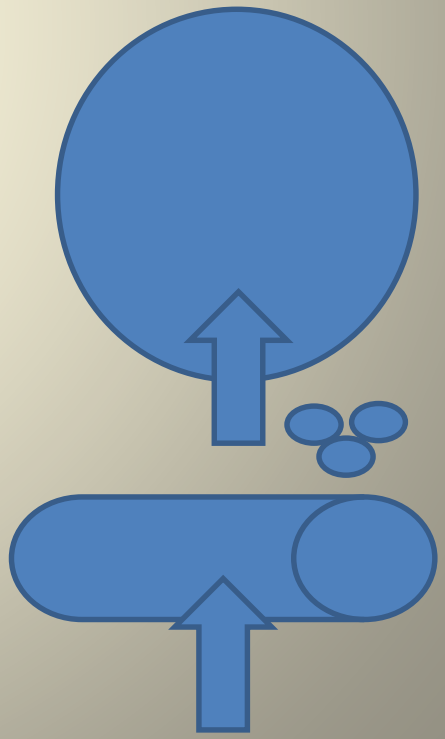

Femoral canal

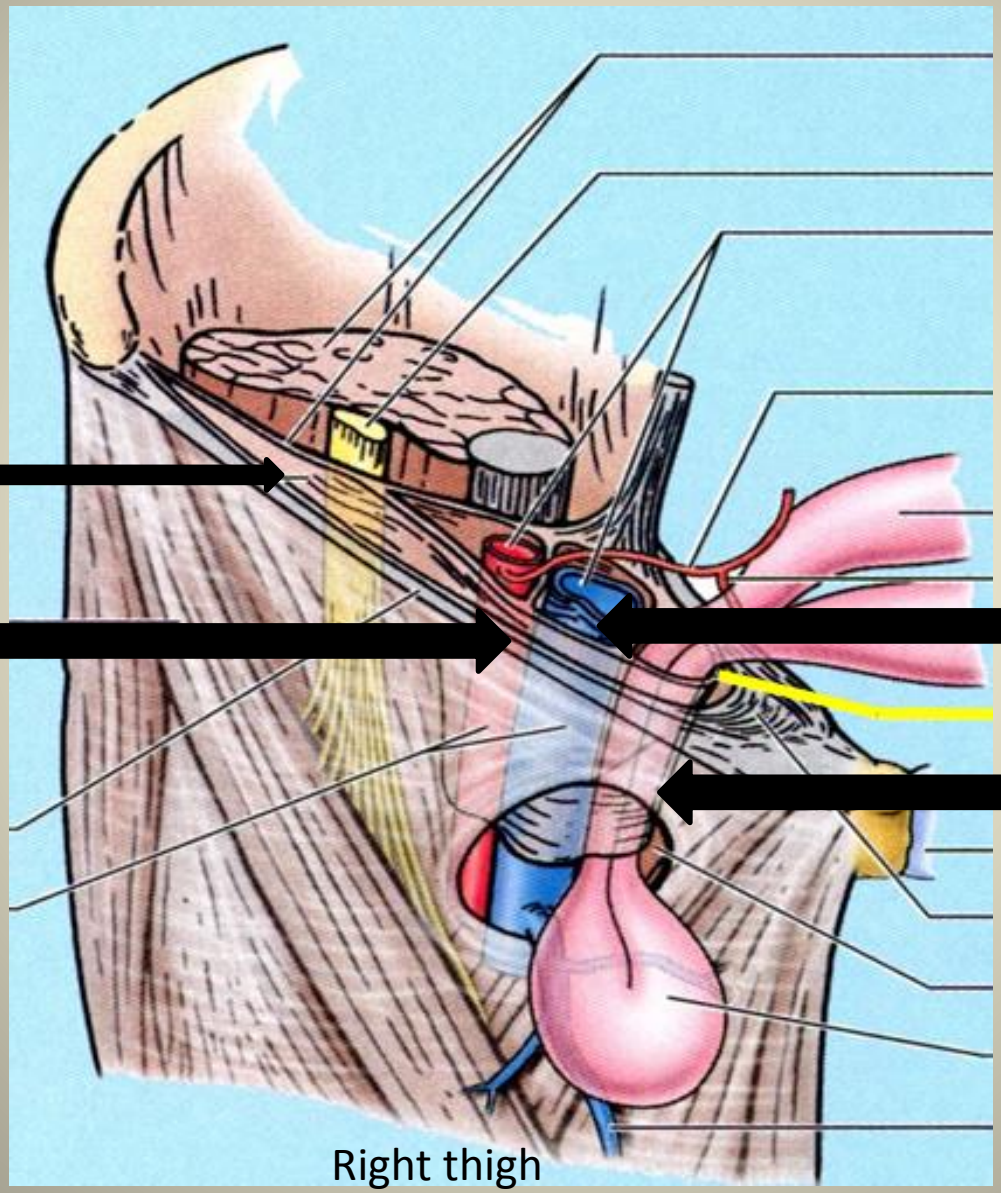

Femoral Canal – Transverse section

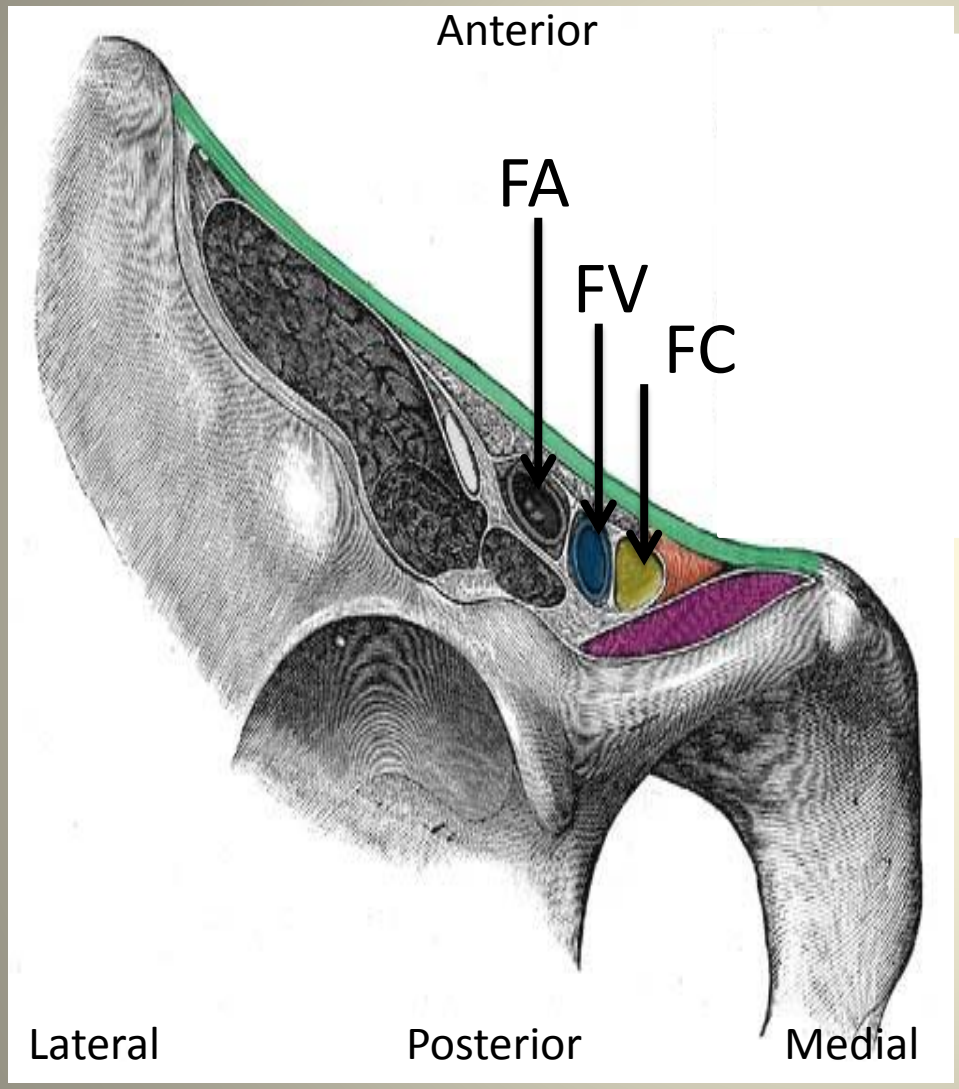

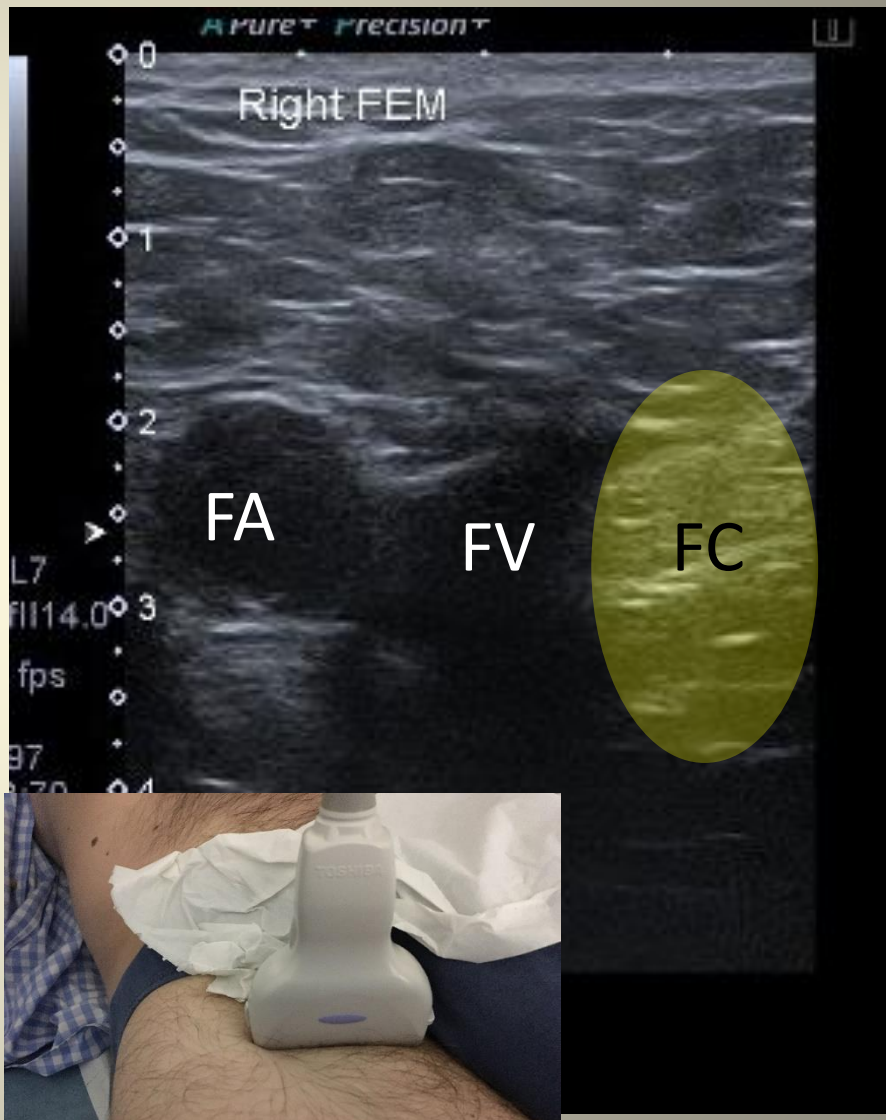

Femoral hernia

- Defect in the transversalis fascia overlying the femoral ring
- 4:1 female : male
- Risks-obesity constipation
- Contents pushed inferiorly through femoral canal into groin
- Medial of femoral vessels, inferior and lateral to pubic tubercle

Femoral Canal

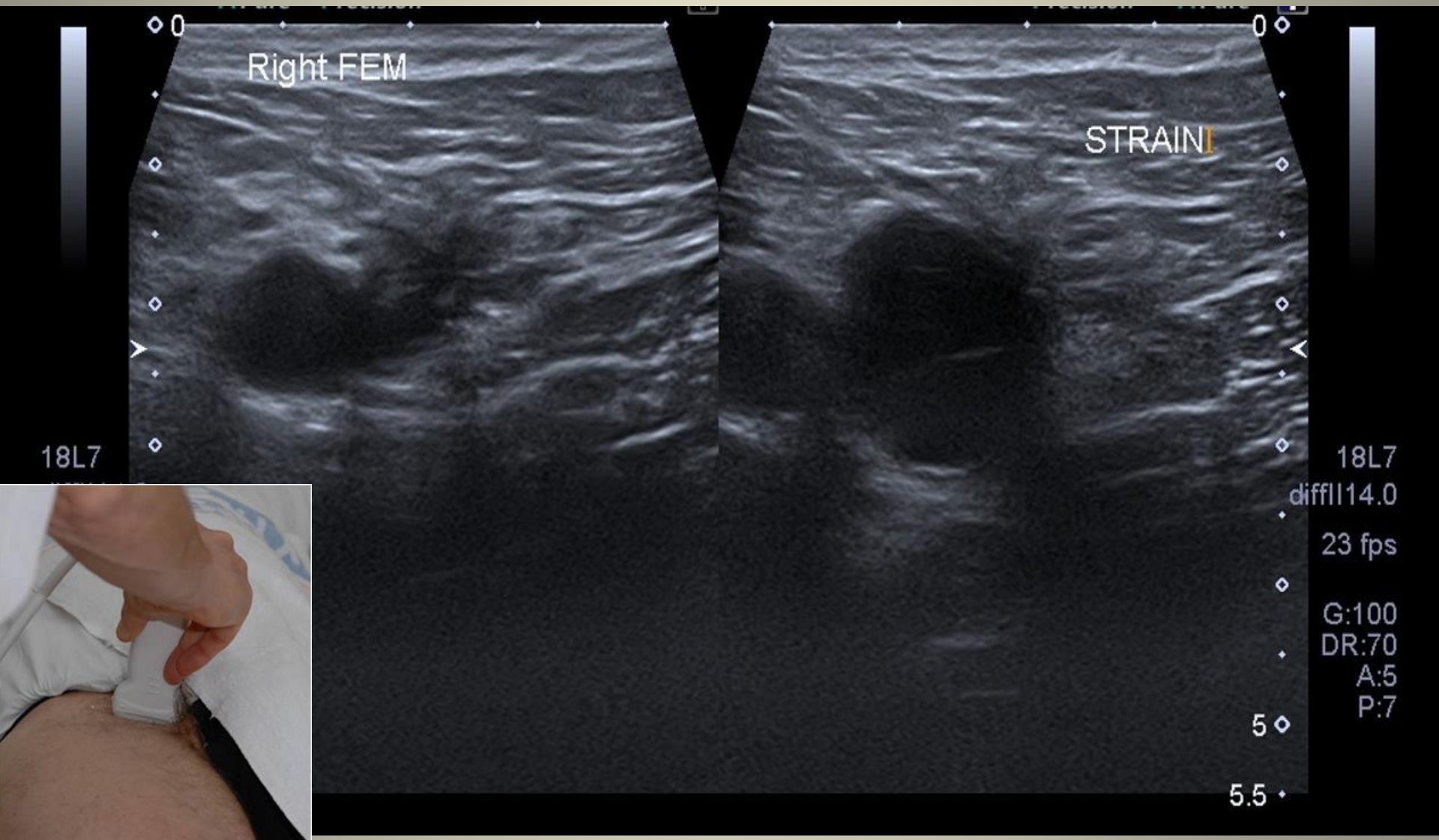

Femoral hernia

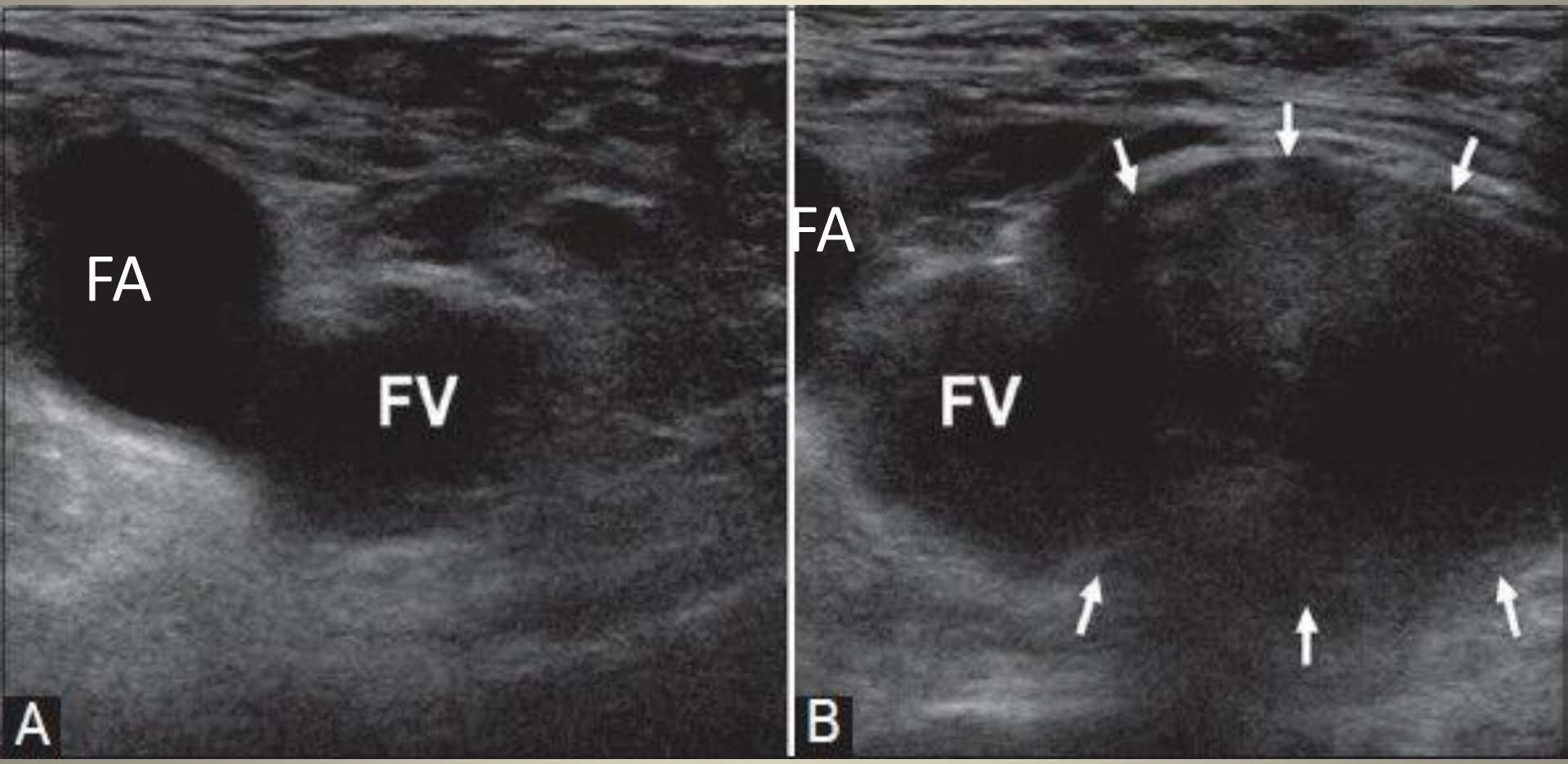

Femoral hernia

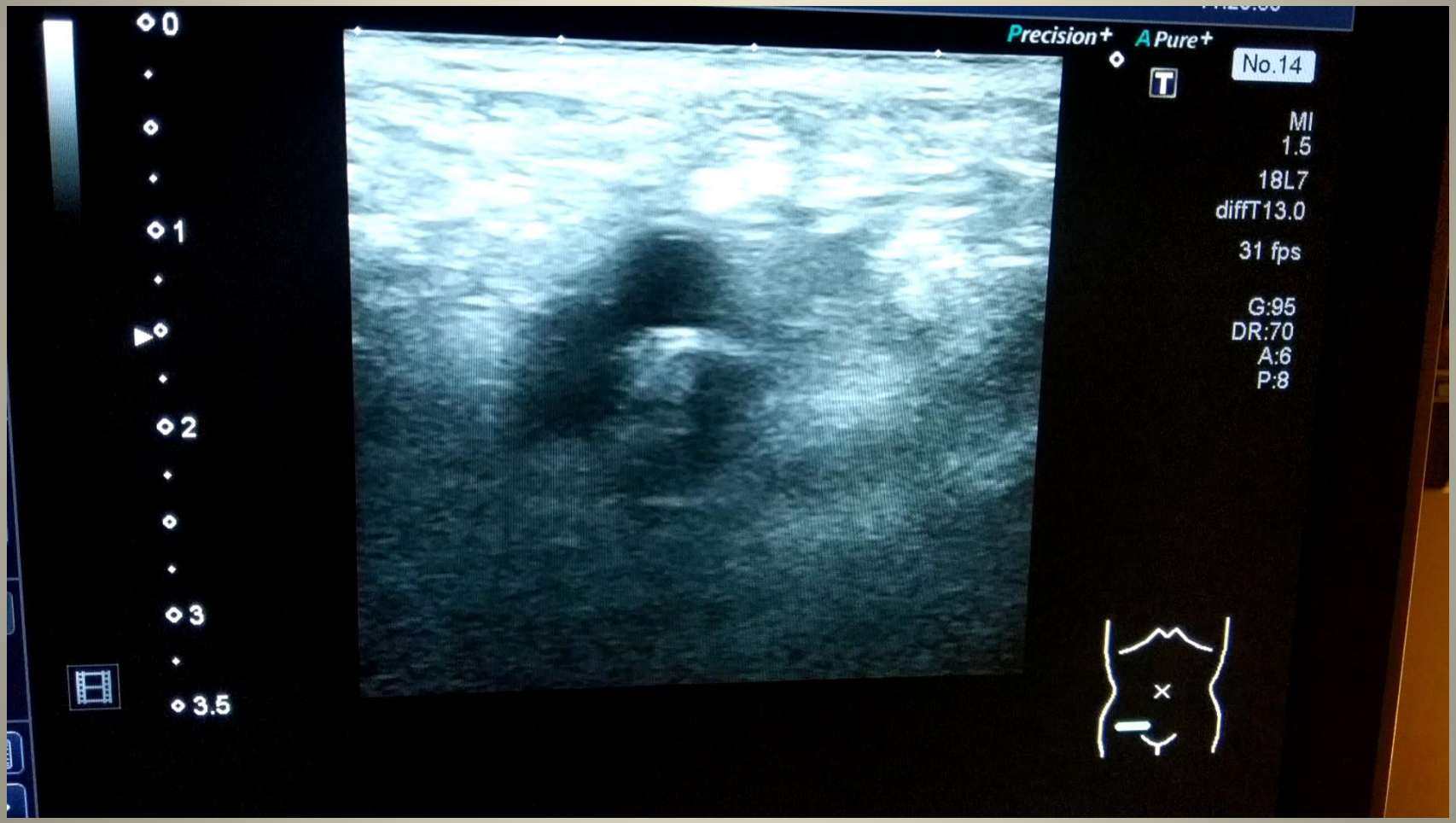

Differential diagnosis

- Seroma
- Haematoma
- Abscess
- Cord lipoma
- Undescended testes
- Lymph nodes
- Ovarian
- Bowel masses
- Iliopsoas bursitis
- Adductor tendinopathy
- Urinary bladder issues
- Vascular – aneurysm, DVT, varicose veins.
- Nothing

Reporting tips - Hernia

Reports should be concise and clear including relevant information that will allow easy assessment of the need and priority for subsequent surgical referral.

Include:

Side

Site (inguinal, femoral, umbilical etc.)

Type (indirect or direct)

Reducibility

Size of the hernia neck/fascia defect

Contents

The end

Useful websites:

E-learning for health

Ultrasound cases

You tube videos of herniae

Books:

Practical Musculoskeletal Ultrasound – E, McNally

Articles:

http://www.ijri.org/article.asp?issn=0971-3026;year=2007;volume=17;issue=4;spage=290;epage=298;aulast=Gokhale

https://www.ncbi.nlm.nih.gov/pmc/articles/PMC3932585/