


Paeds Gynae US (@GOSH)

Gorse Leung and Stacey Thomas
Specialist Paediatric Sonographers



Disclaimer

This presentation is based on research conducted to the best of the presenter's abilities, acknowledging inherent uncertainties and limitations. The findings may be influenced by factors such as data quality, methodology, and interpretation, and do not guarantee real-world accuracy.

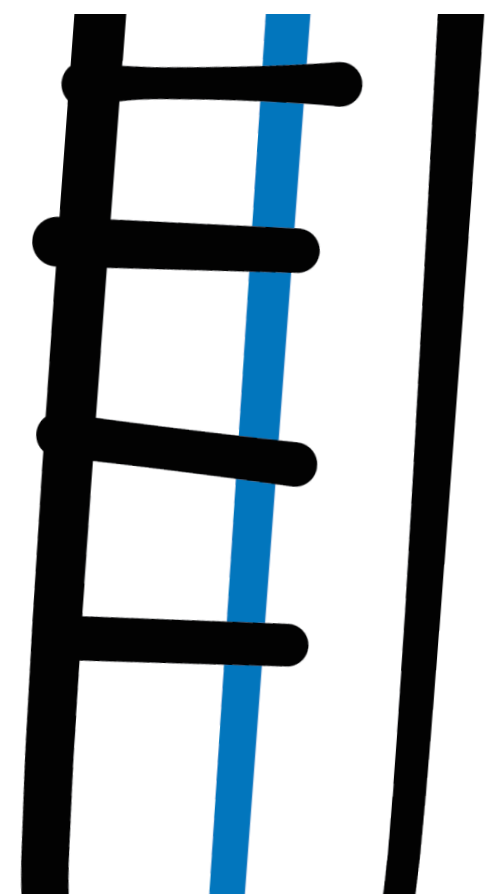
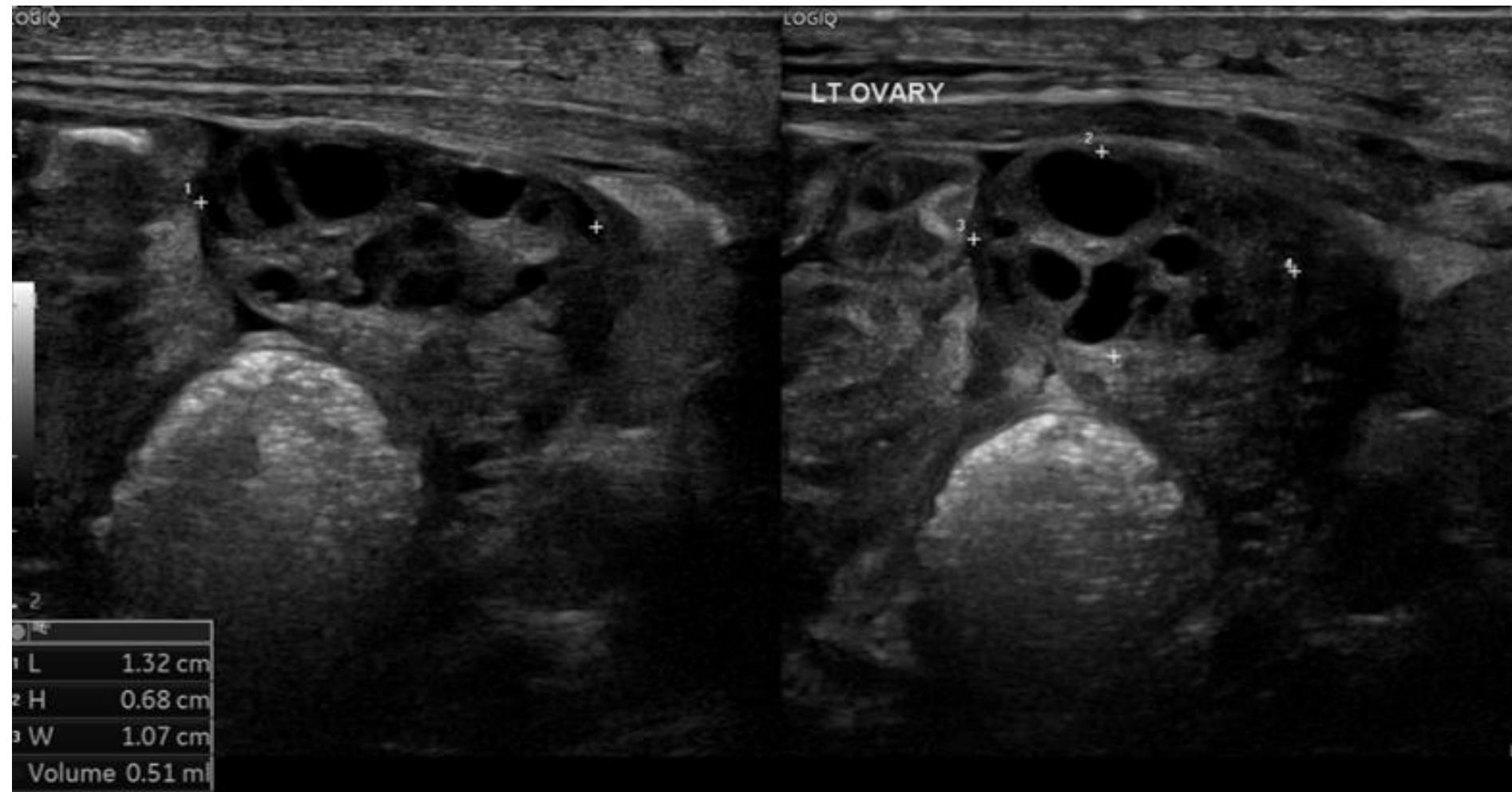
The content is intended for informational purposes only and does not necessarily reflect the views of the British Medical Ultrasound Society (BMUS) or its affiliates. The presenter is responsible for ensuring objectivity and disclosing any relevant financial/industry interests. BMUS and its affiliates disclaim liability for any claims arising from this educational activity.

Practical Considerations



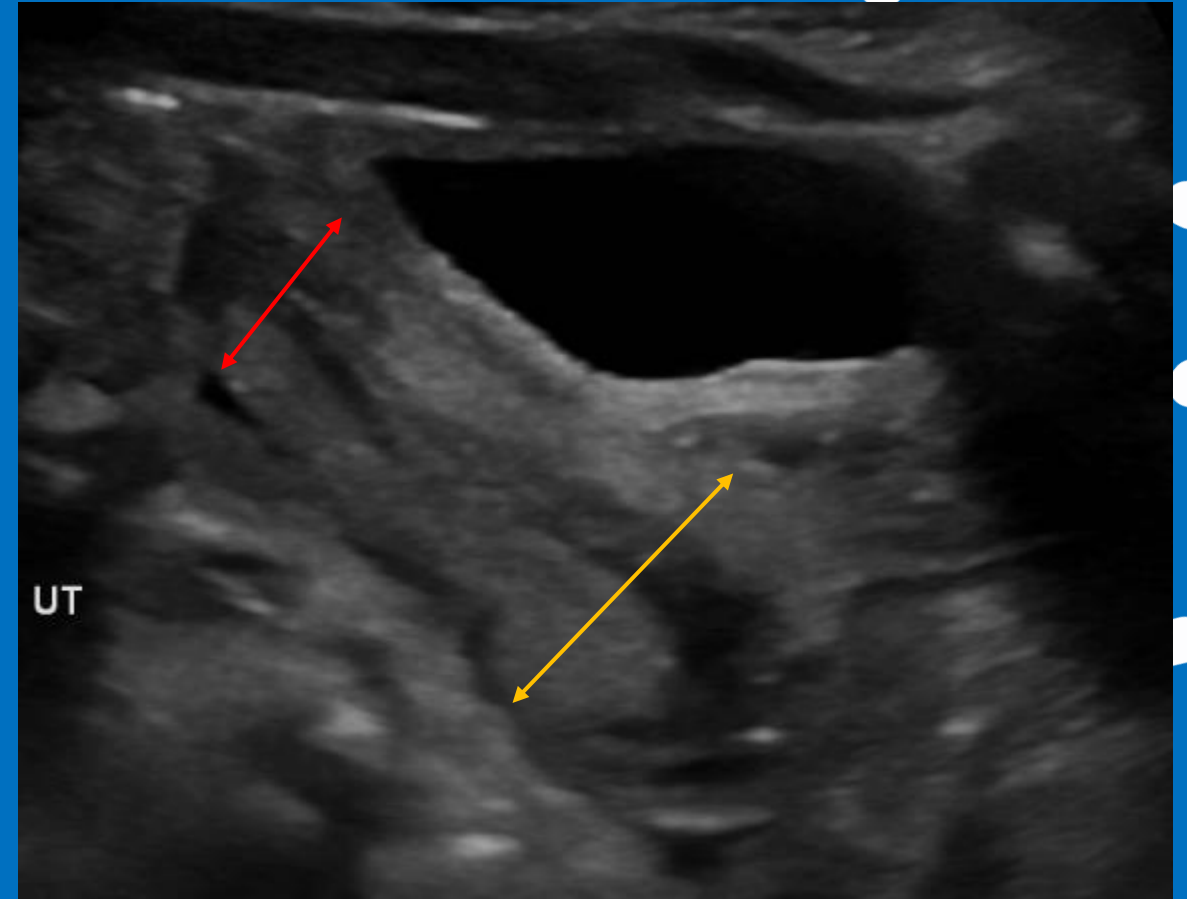
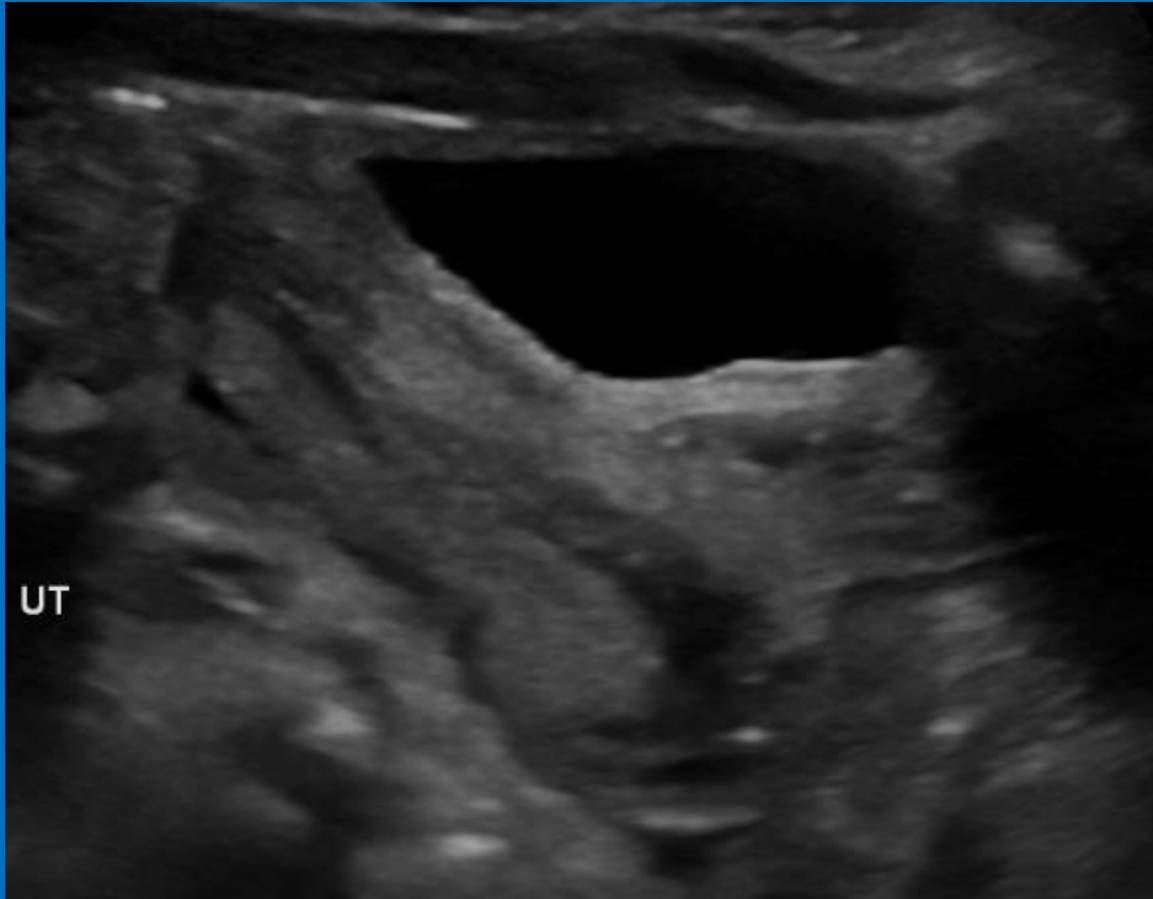
- Full bladder required (generally)
- Transabdominal ultrasound only. Highest frequency transducer if possible
- Typical gynae imaging series (include proximal vaginal vault)
- Check suprarenal spaces
- If Müllerian anomaly present, included renal tracts
- Patience – as long as tolerable (by you and the patient)

Practical Considerations



Ultrasound appearances for age

- Neonatal period (0 – 1 month)



- Fundal to cervical ratio 1:2



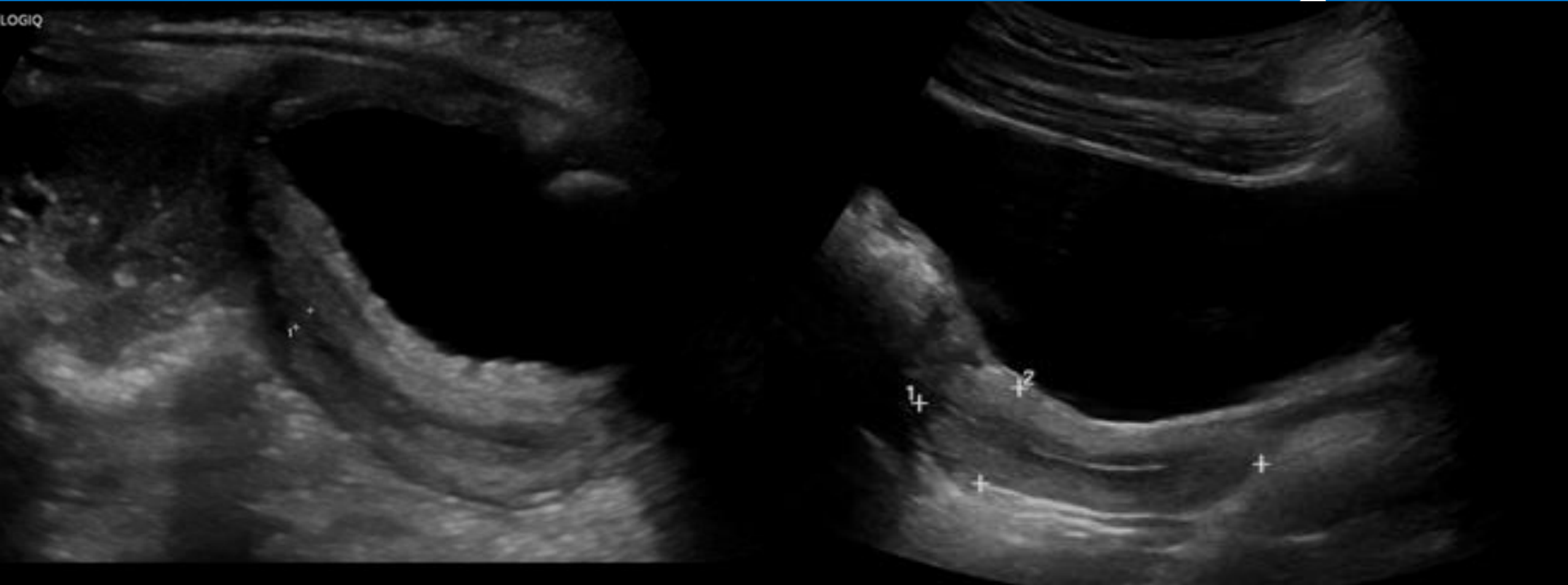
NHS

Great Ormond Street
Hospital for Children
NHS Foundation Trust

BMUS))

Ultrasound appearances for age

- Infantile/early childhood (1 month – 4 years)



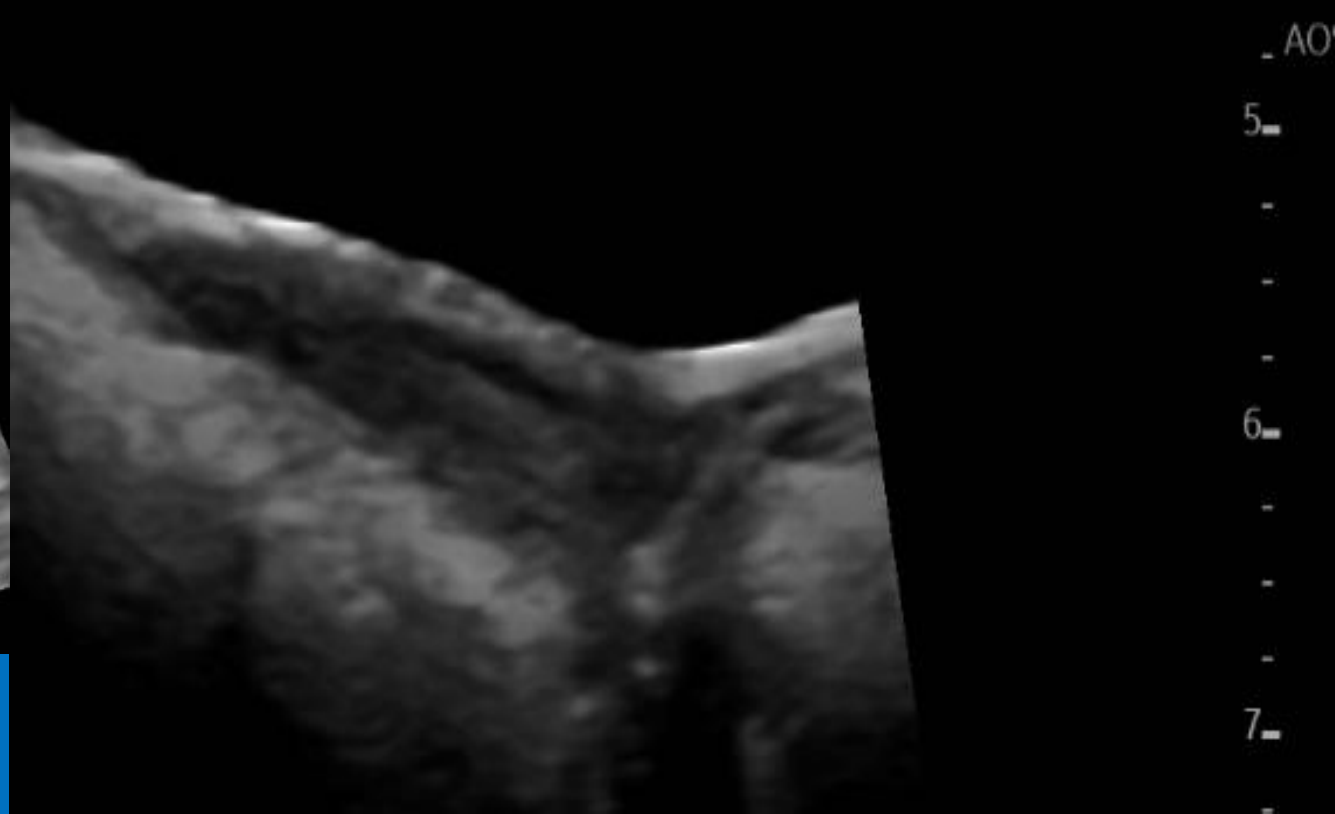
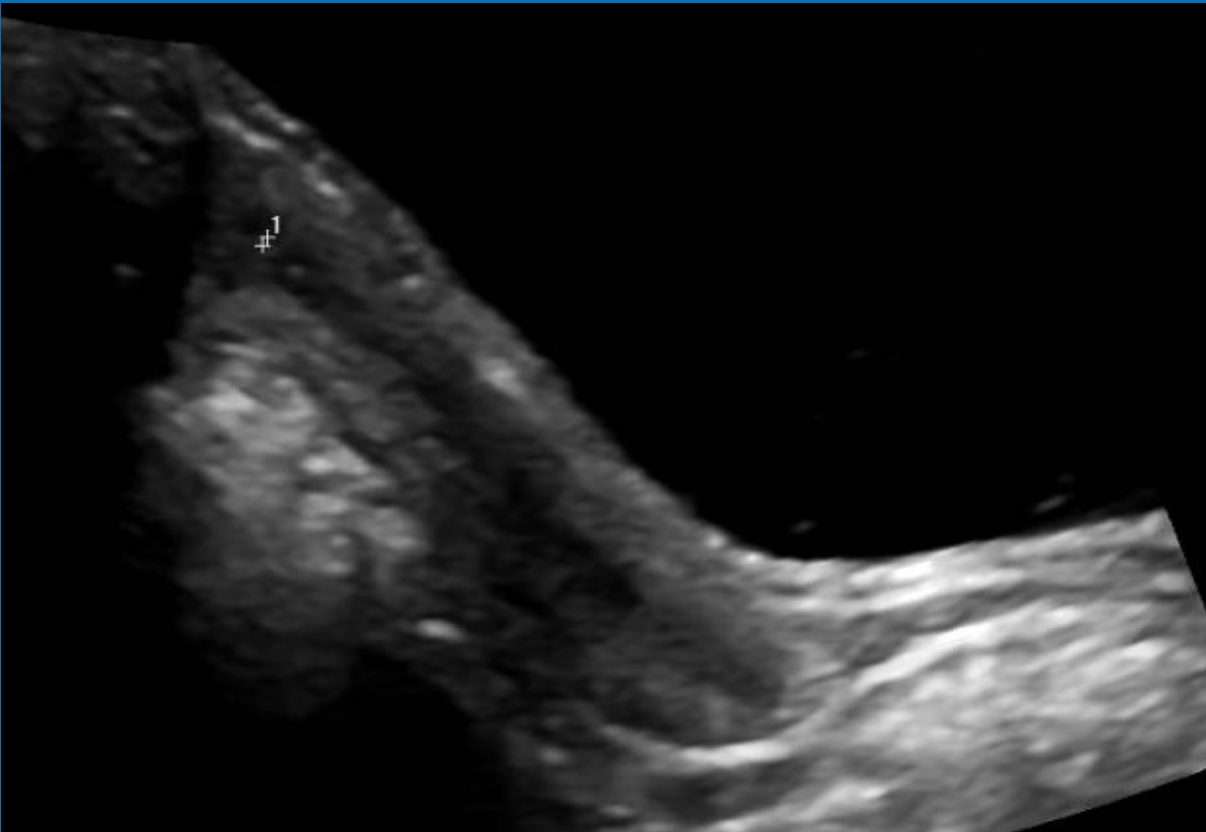

- Tubular

- Fundal to cervical ratio 1:1

Ultrasound appearances for age

- Prepubertal period (4 – 8 years)

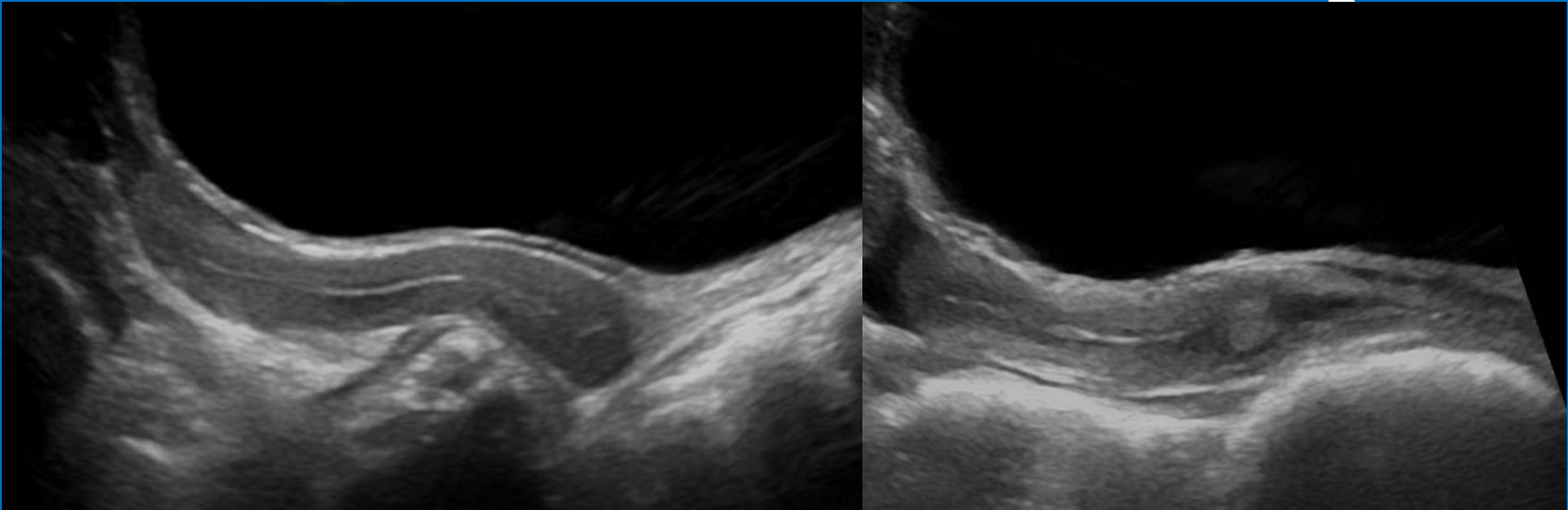
- Fundal to cervical ratio 1:1



- Remains tubular- sometimes thicker cervix

Ultrasound appearances for age

- Peripubertal period (~8 – 10 years)
 - Increasing length and fuller fundus





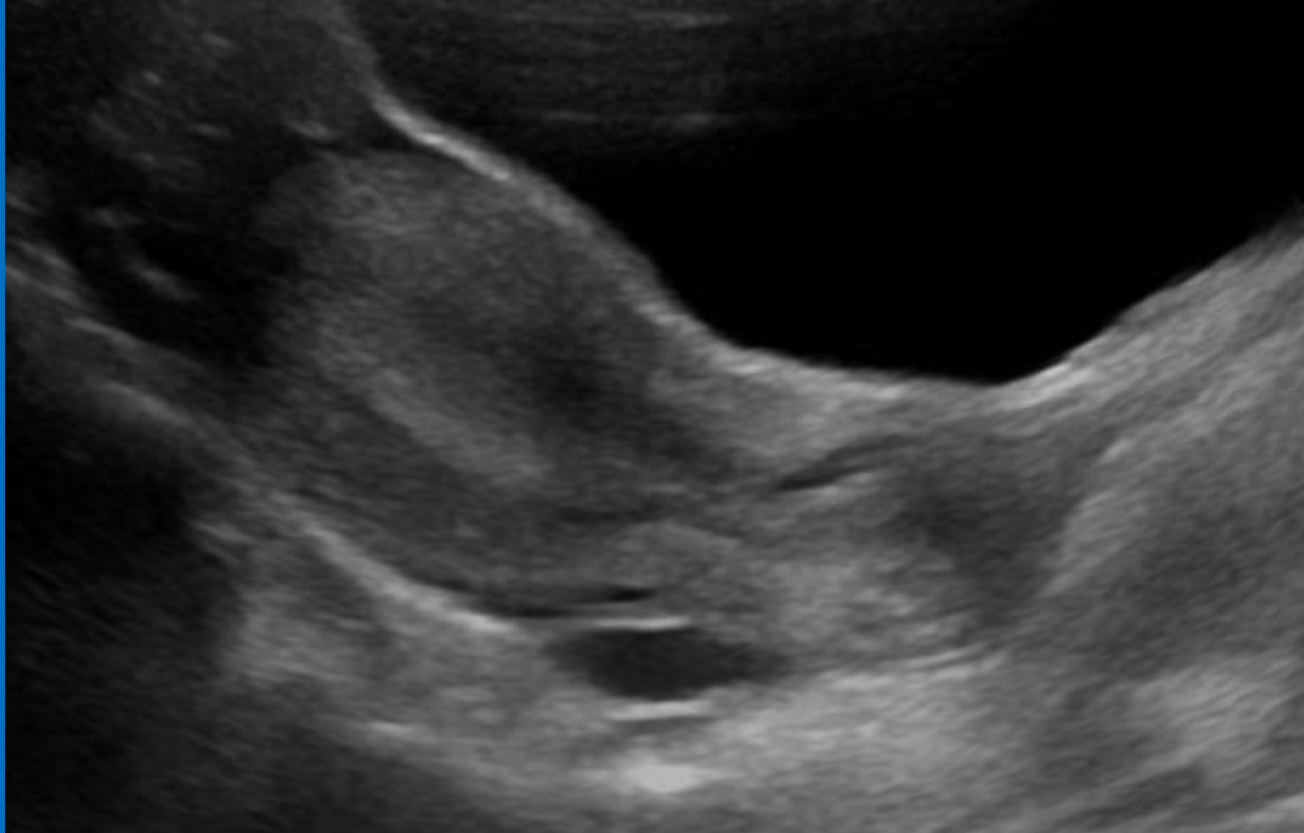
NHS

Great Ormond Street
Hospital for Children
NHS Foundation Trust


BMUS))

Ultrasound appearances for age

- Pubertal period (~10+ years)

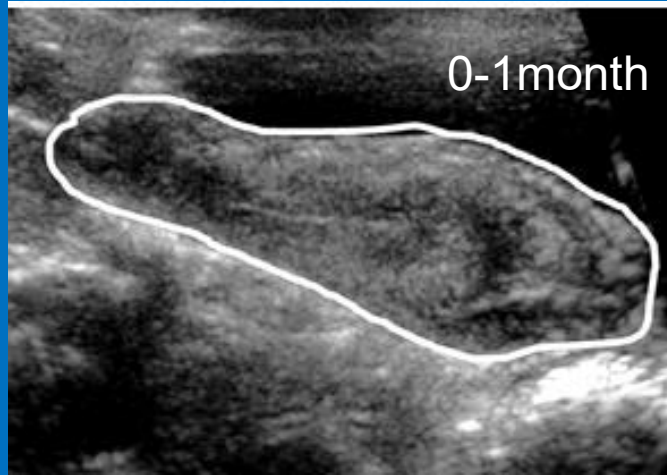


- Pear shaped with ovarian follicular activity

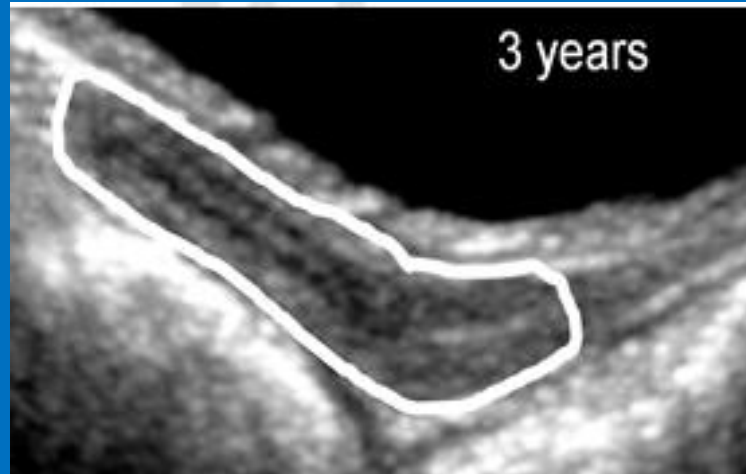

Uterine Development

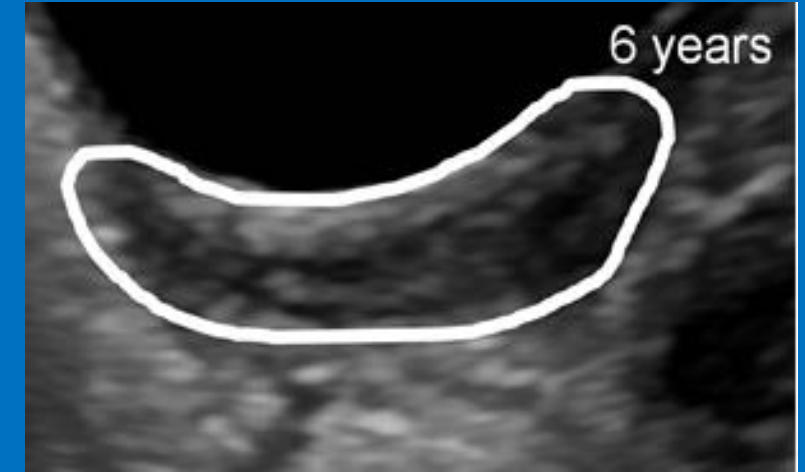
Neonatal



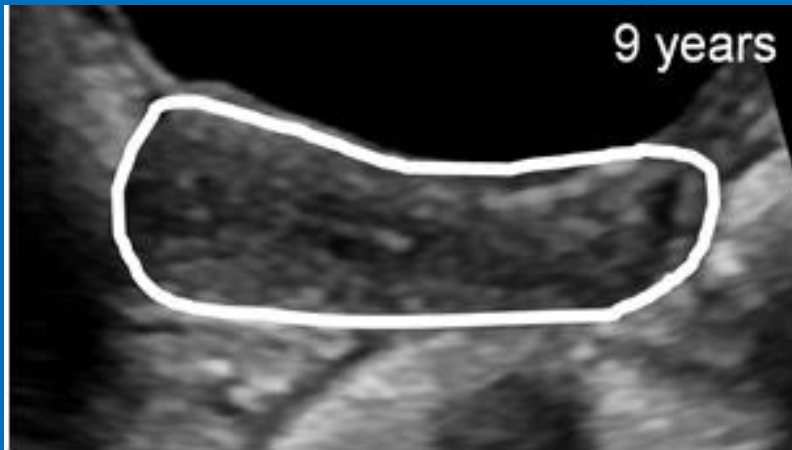
Infantile



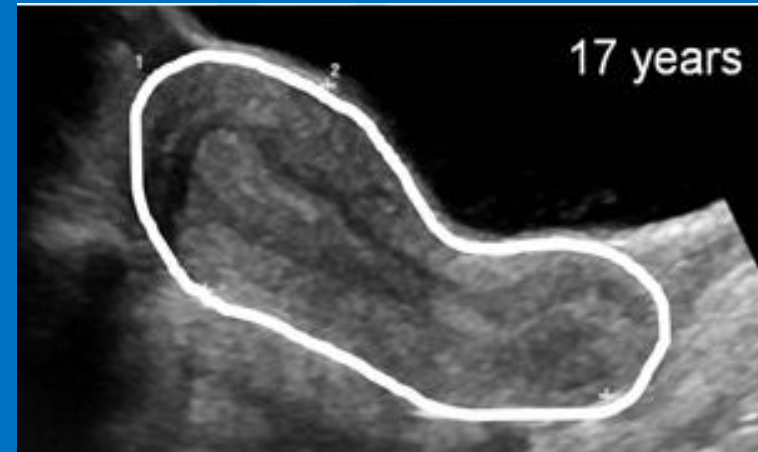
Pre-pubertal



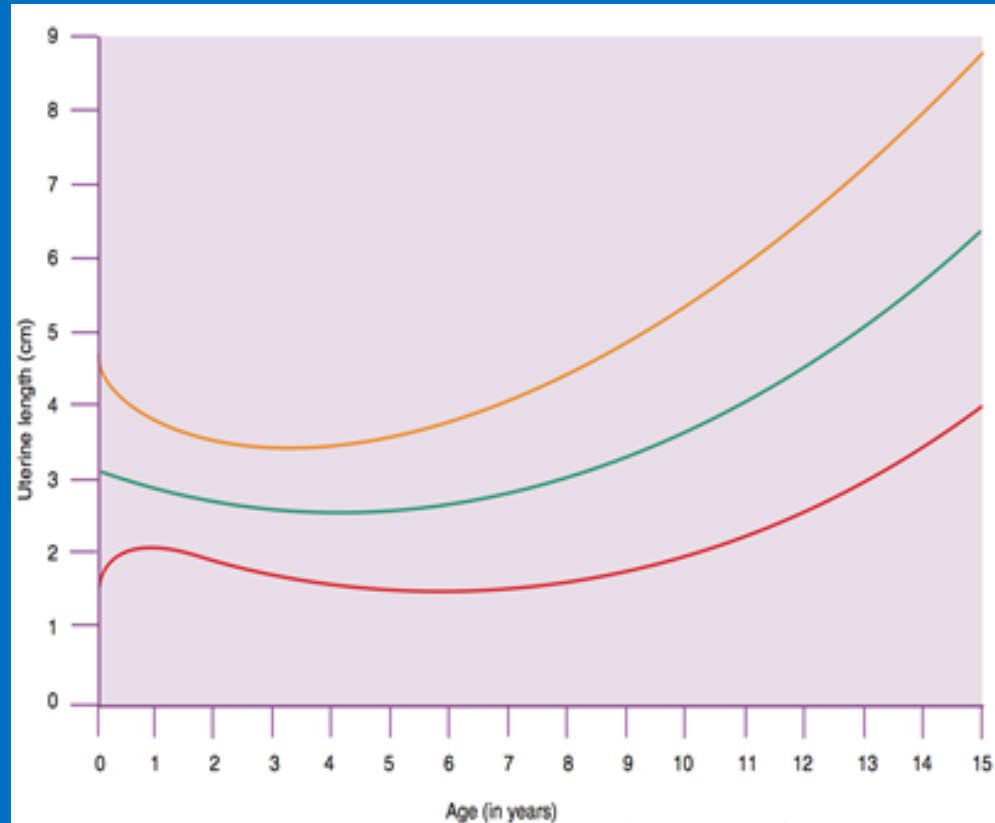
Peri-pubertal



Pubertal

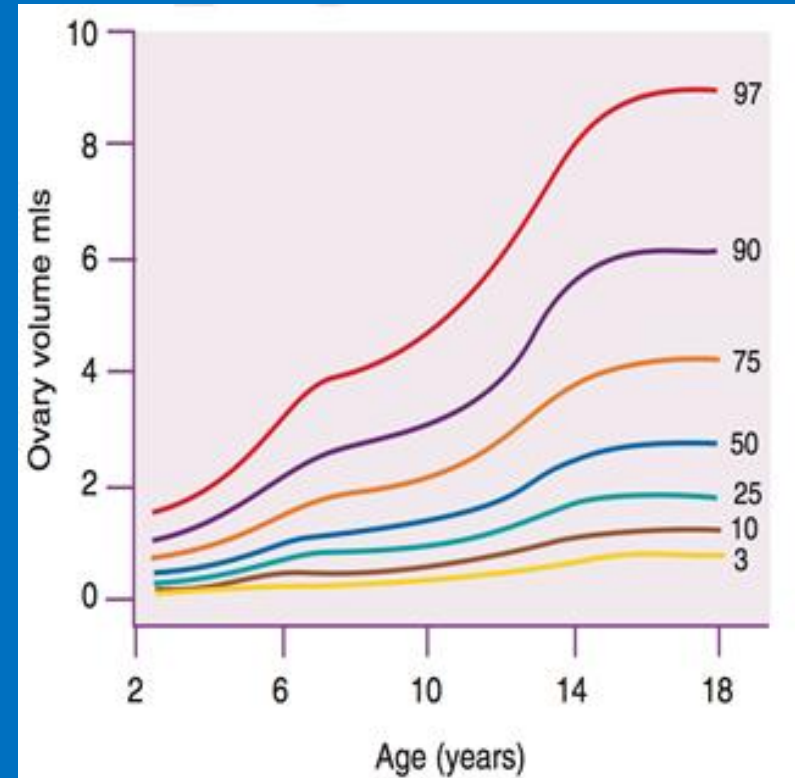


Uterine and Ovarian growth charts



Uterine length VS age (3rd, 50th and 90th centile)

Griffin IJ, Cole TJ, Duncan KA, et al. Pelvic ultrasound measurements in normal girls. *Acta Paediatr* 1995; 84:536-543



Ovarian size VS age

Bridges NA, Cooke A, Healy MJR, et al. Standards for ovarian volume in childhood and puberty. *Fertility & Sterility* 1993; 60:456-460

Some Clinical Indications for Paeds Pelvic US

- RIF pain/? Appendicitis
- Palpable mass
- Precocious puberty
- Anorexia
- ?PV loss
- Congenital adrenal hyperplasia (CAH)
- Cloaca
- Amenorrhoea
- WNT4 deficiency – syndrome of Mullerian aplasia and hyperandrogenism
- Differences in Sex Development (DSD) – 45 X (Turners syndrome – Monosomy X or Mosaicism) or 47 XXY (Klinefelter syndrome), 46 XX or 46 XY





NHS

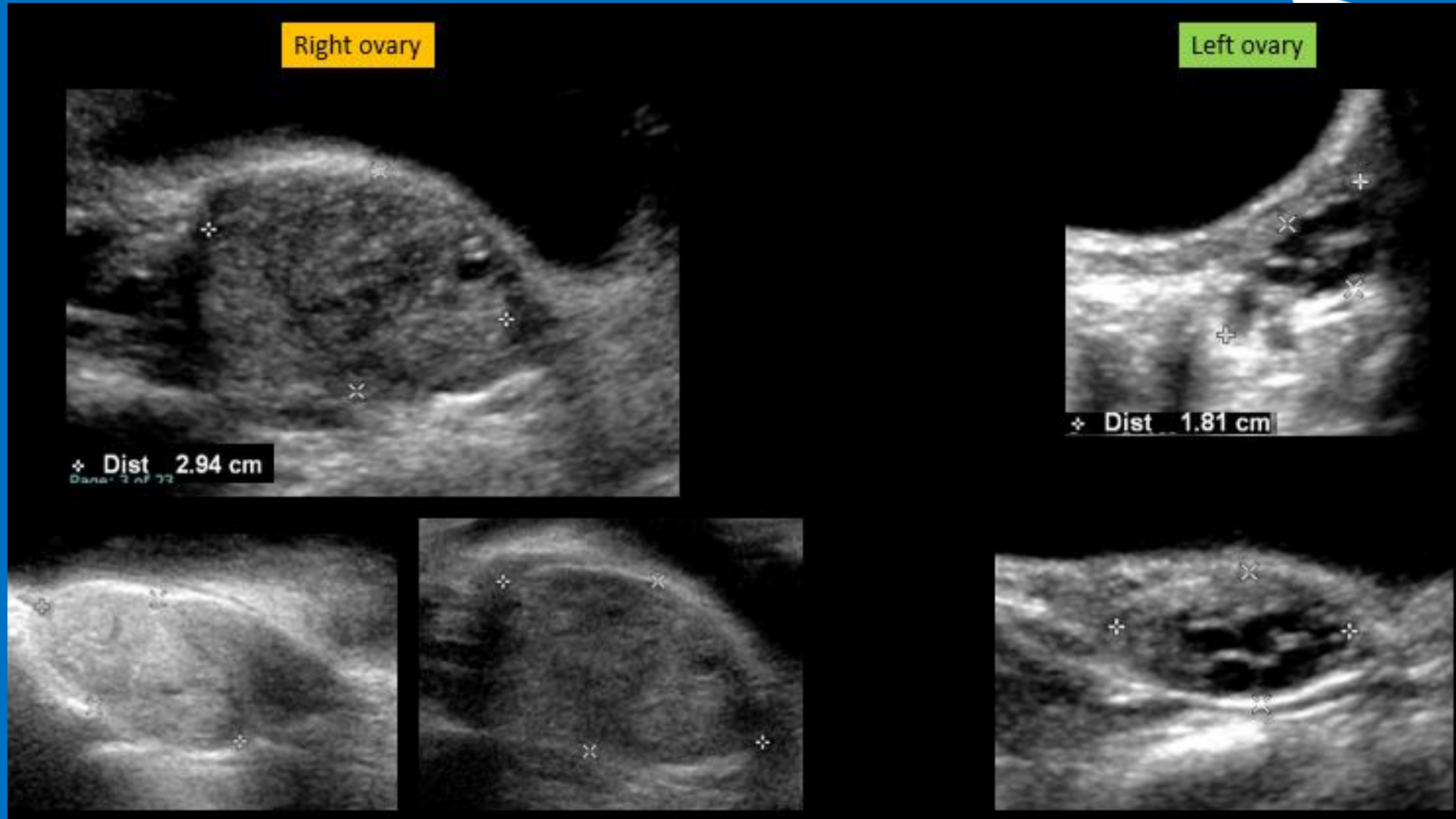
Great Ormond Street
Hospital for Children
NHS Foundation Trust

BMUS))

Interesting Cases

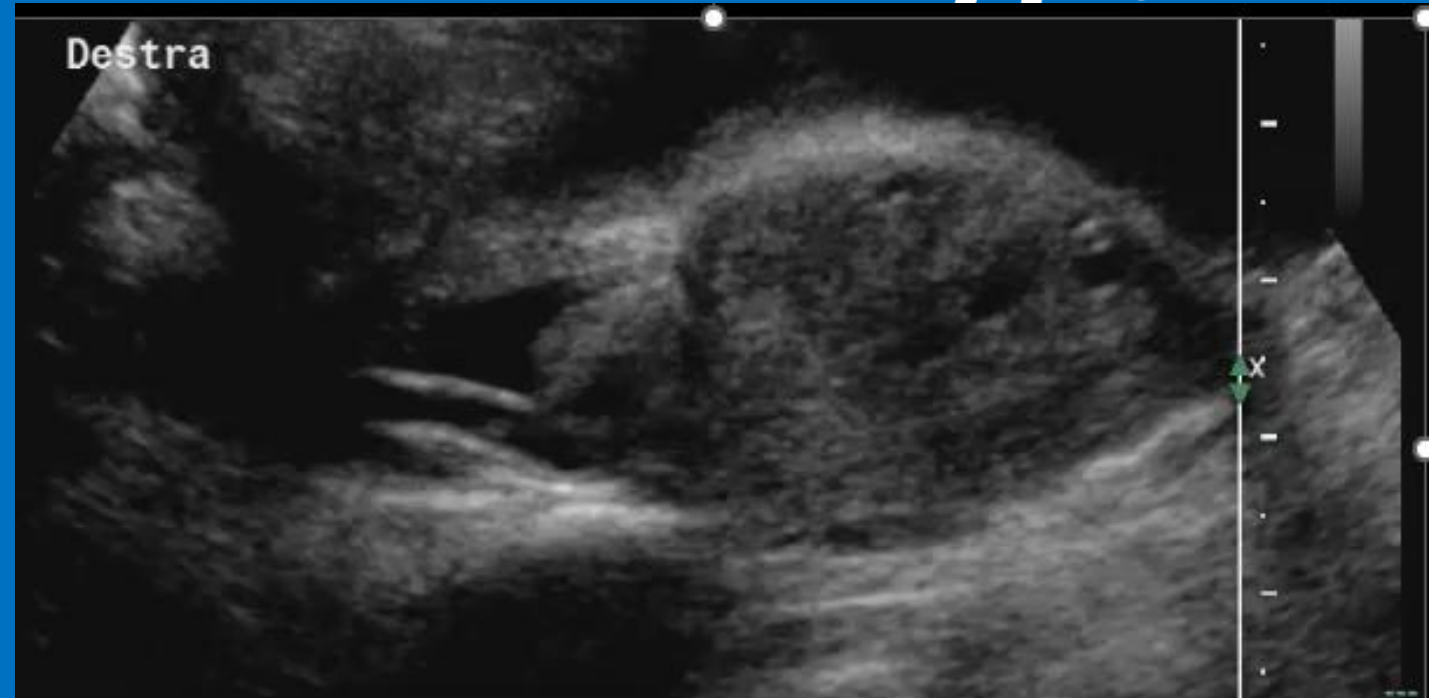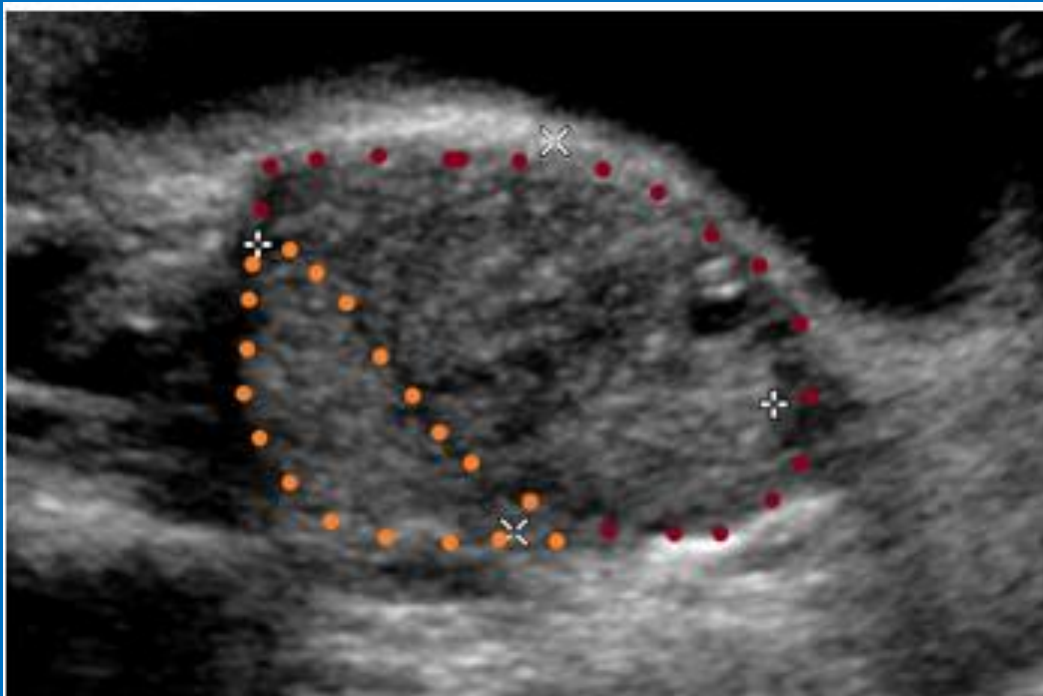


5 yr old female ? Appendicitis



5 yr old female ? Appendicitis – (Cine)

- Twisted pedicle
- Torted ovary





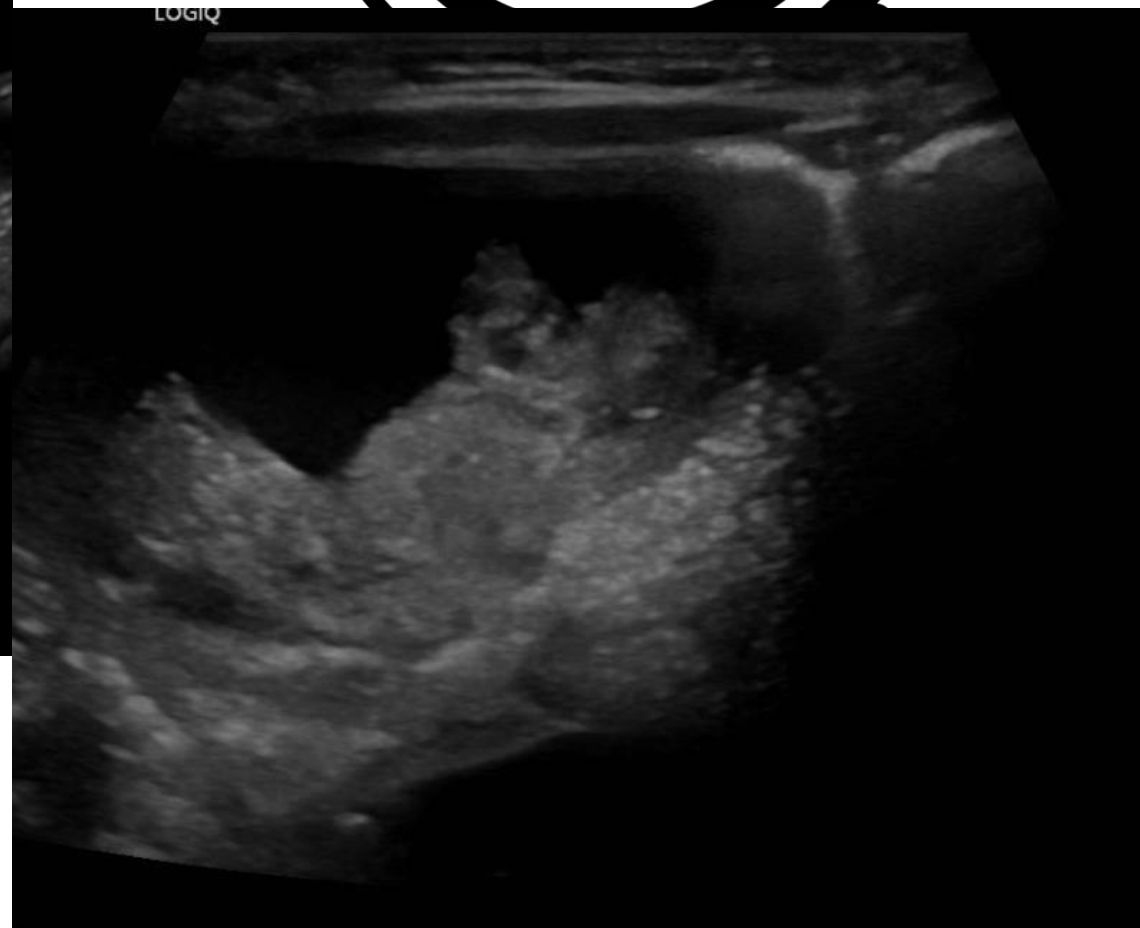
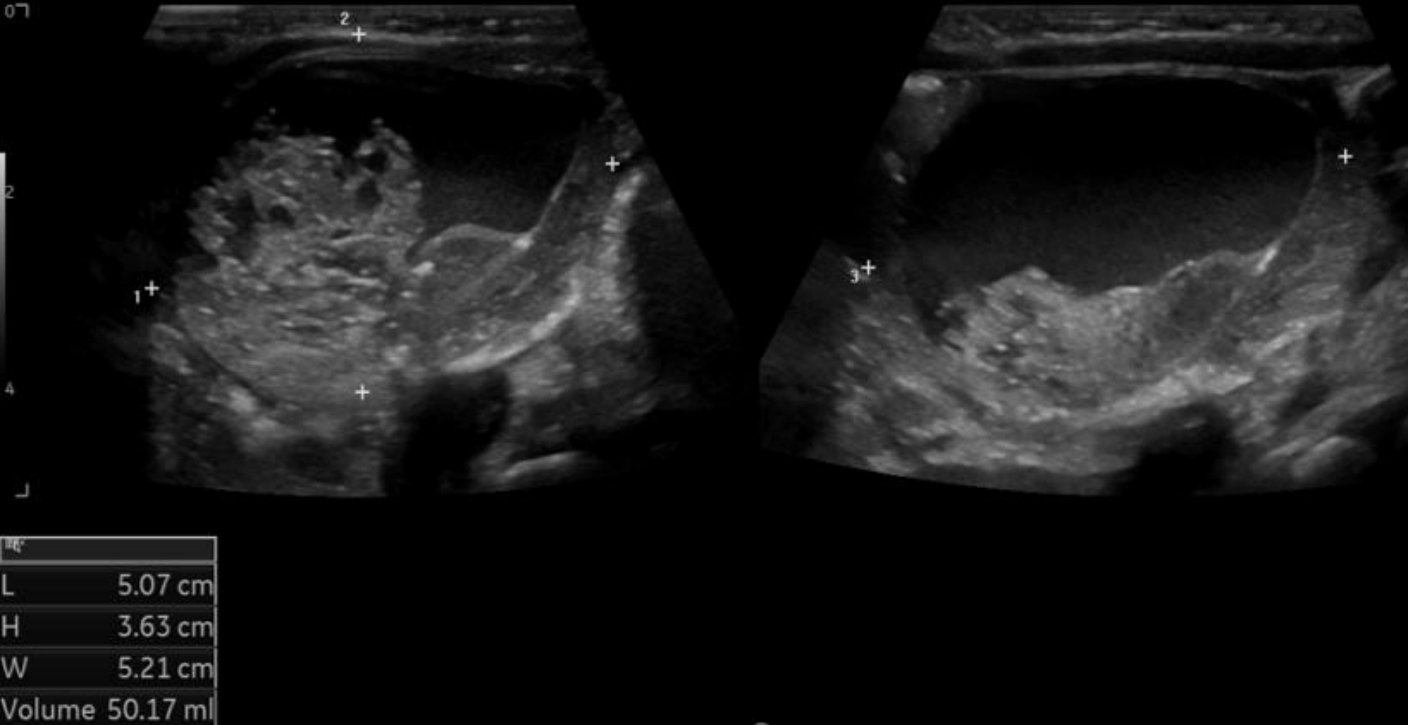
NHS

Great Ormond Street
Hospital for Children
NHS Foundation Trust

6-week-old female, RIF cyst – (Cine)

BMUS))

RT ADNEXA



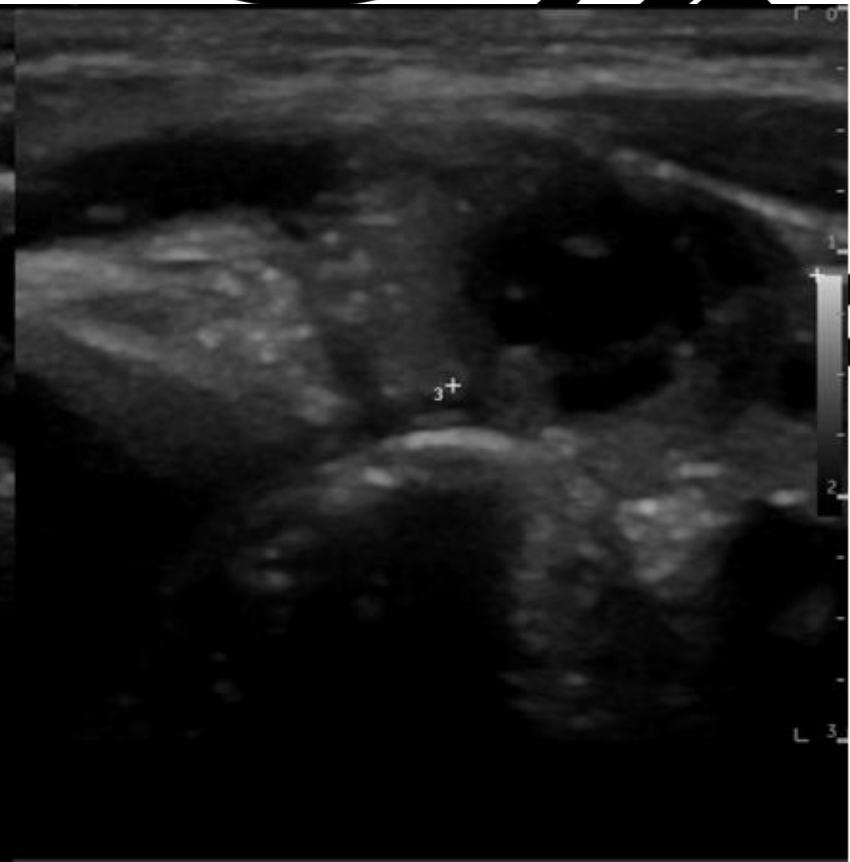
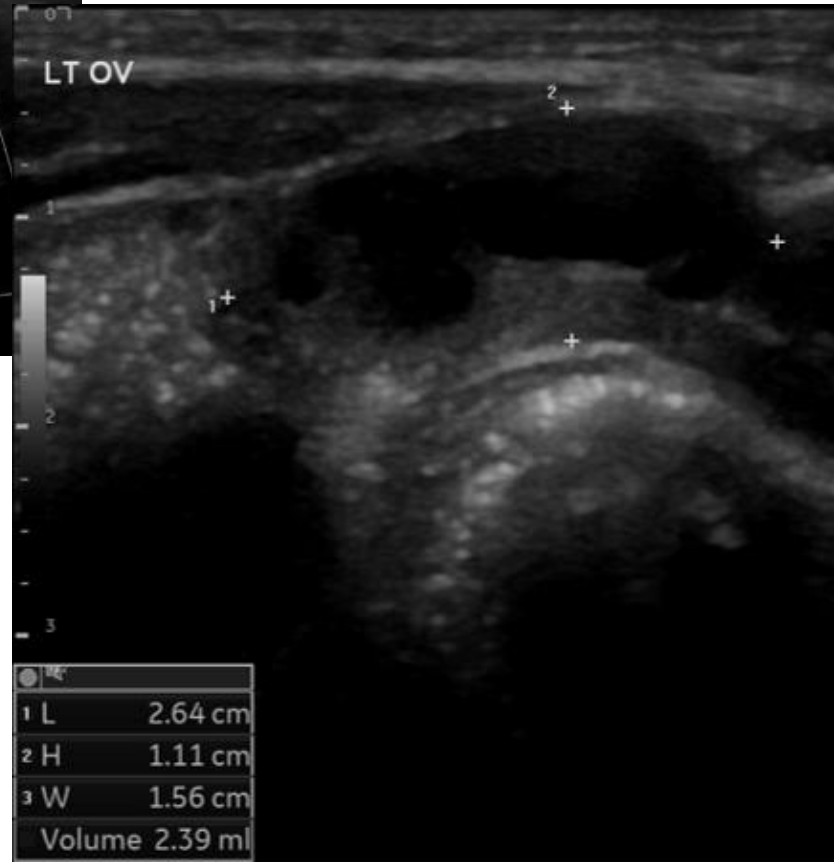
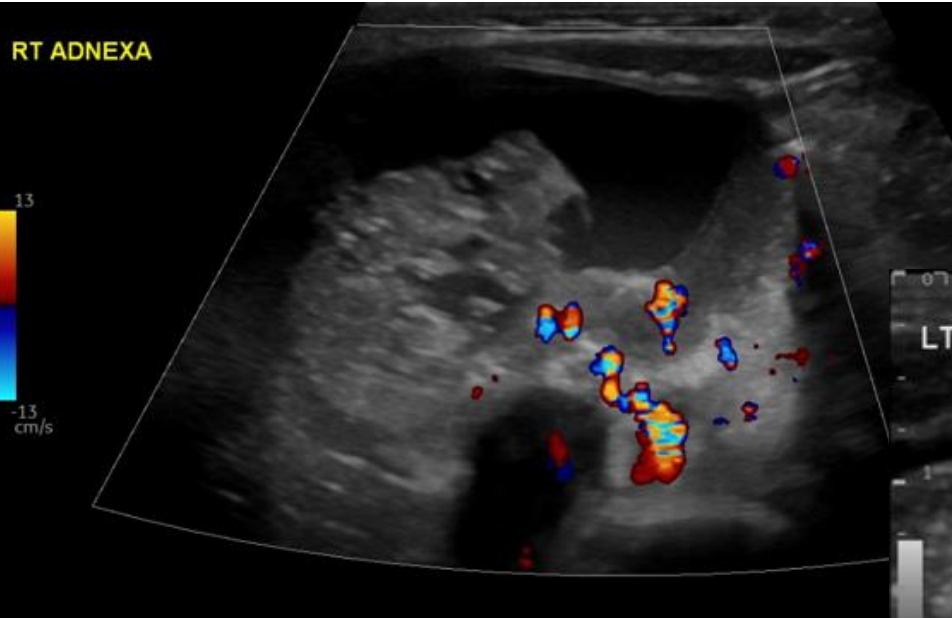


NHS

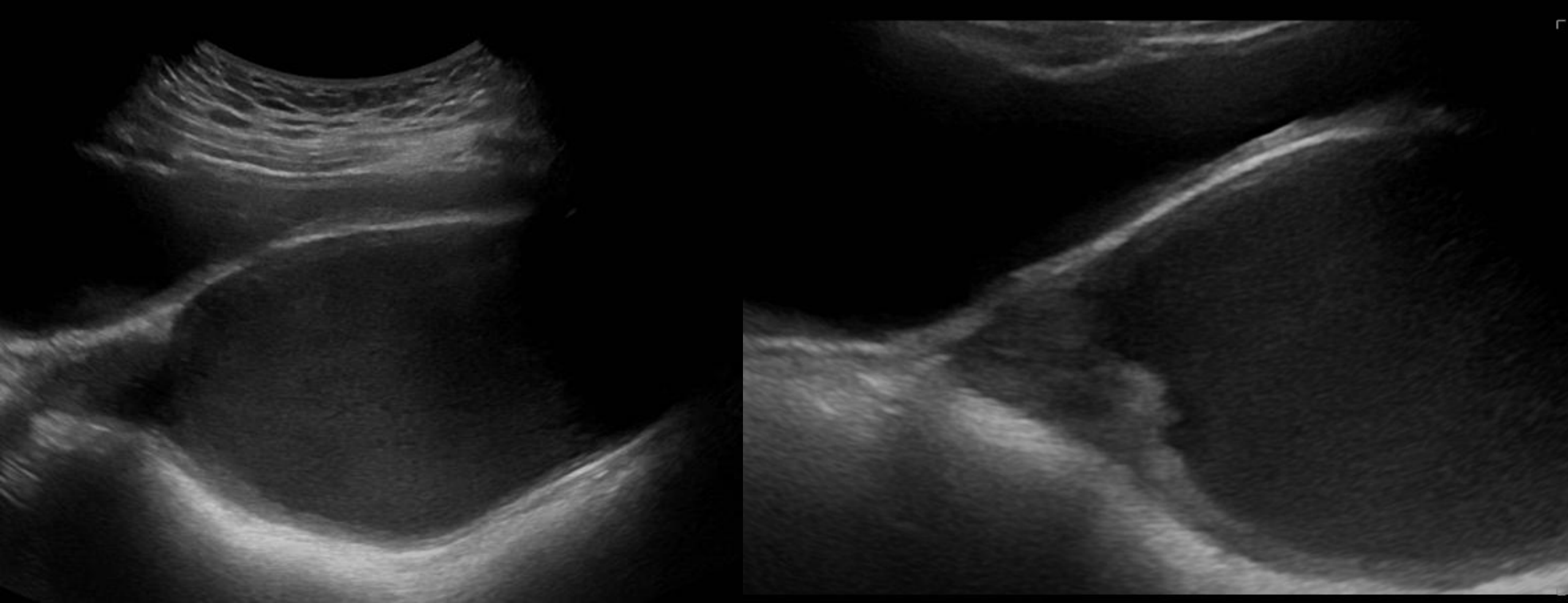
Great Ormond Street
Hospital for Children
NHS Foundation Trust

6-week-old female, RIF cyst

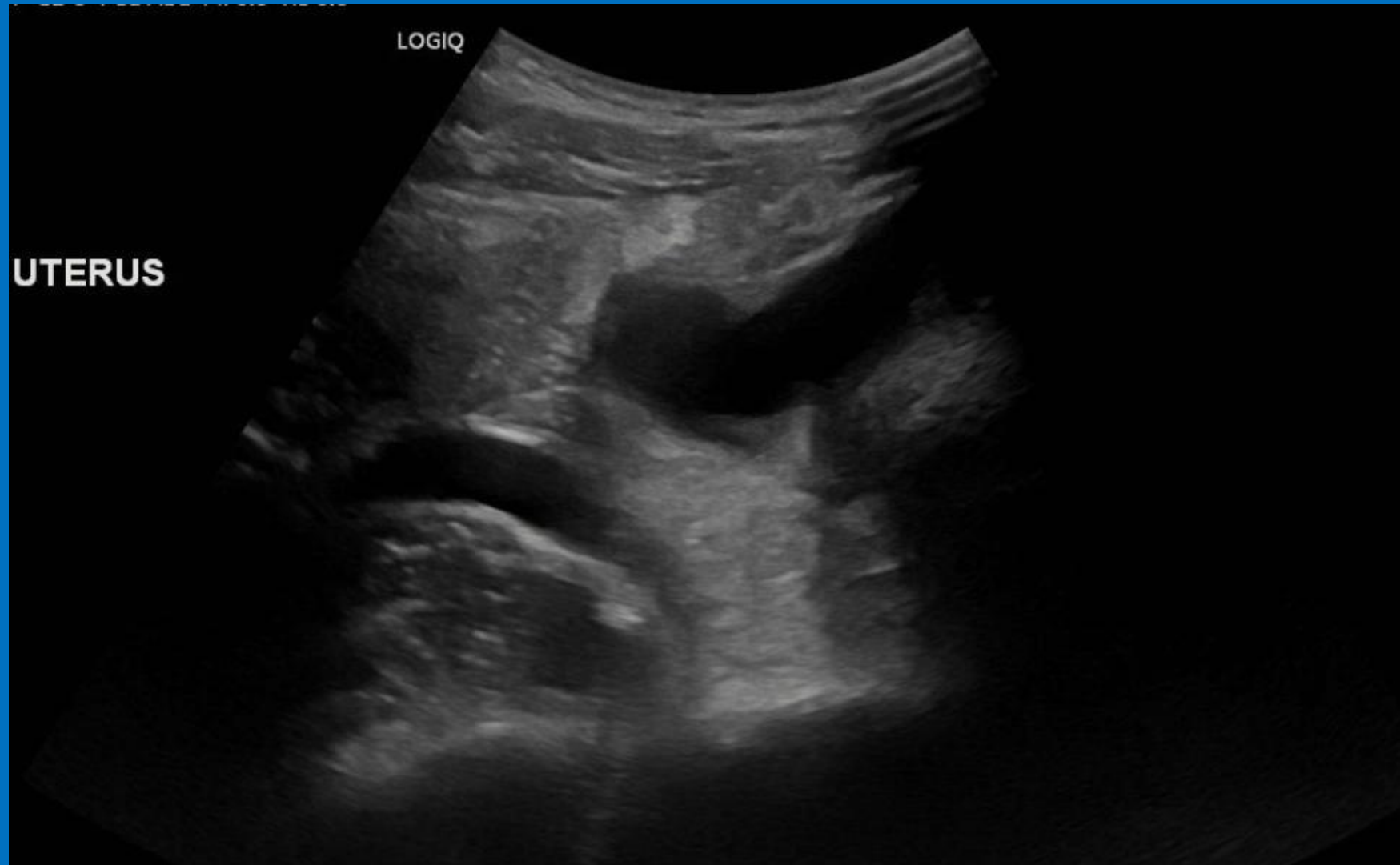
BMUS



12 yr old girl, primary amenorrhoea and pain



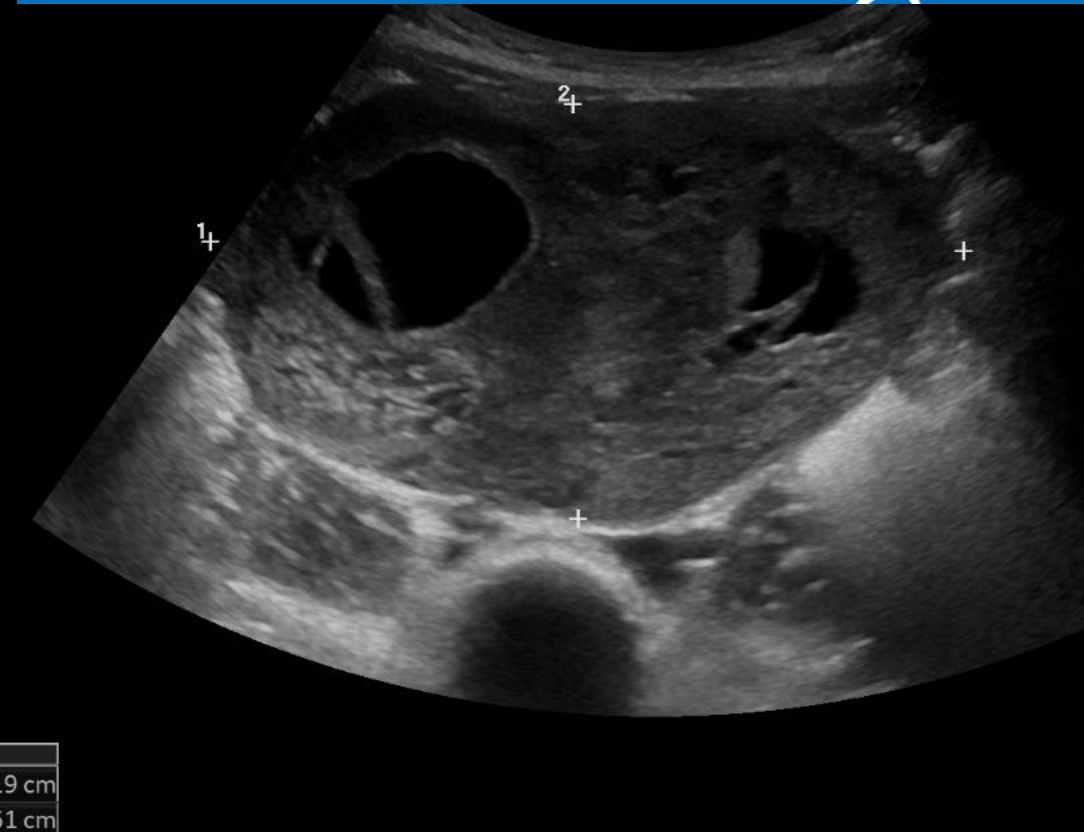
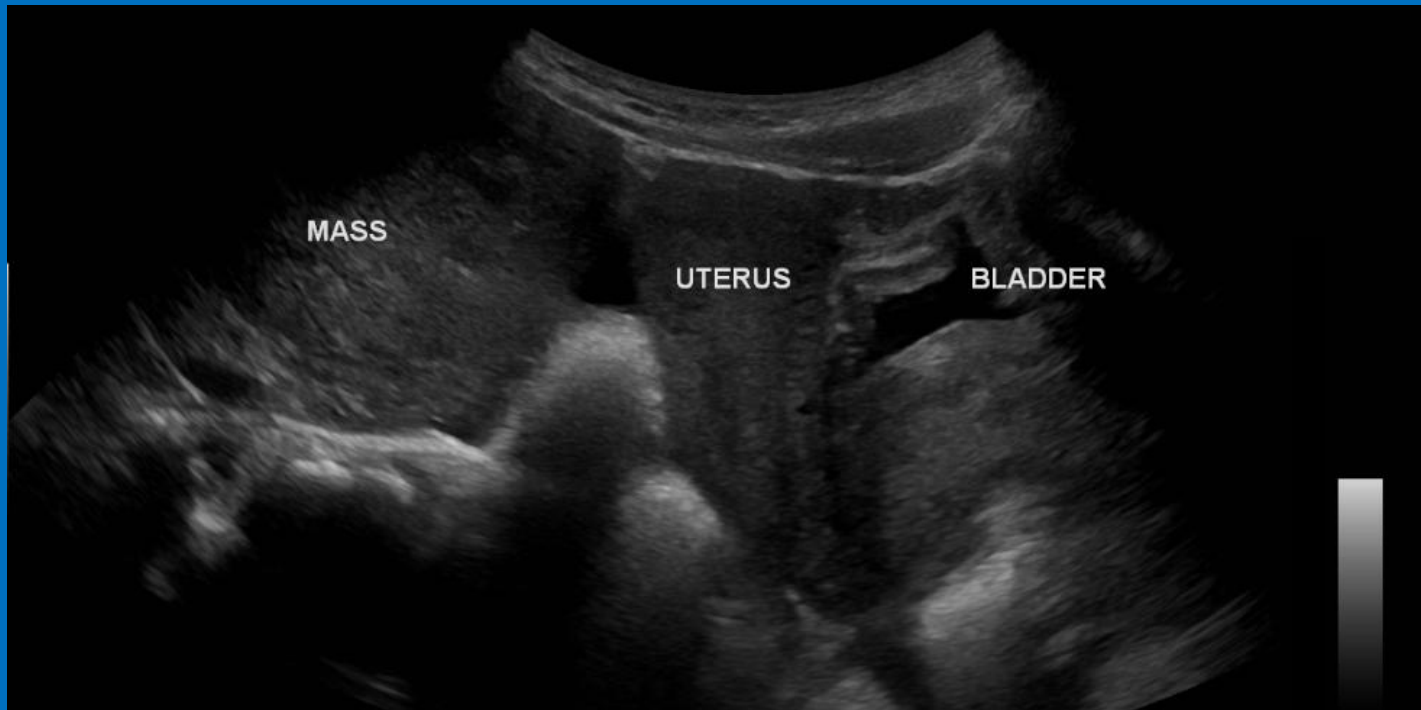
13 yr old female – hx of RIF pain ? Appendicitis/? ovarian torsion– (Cine)



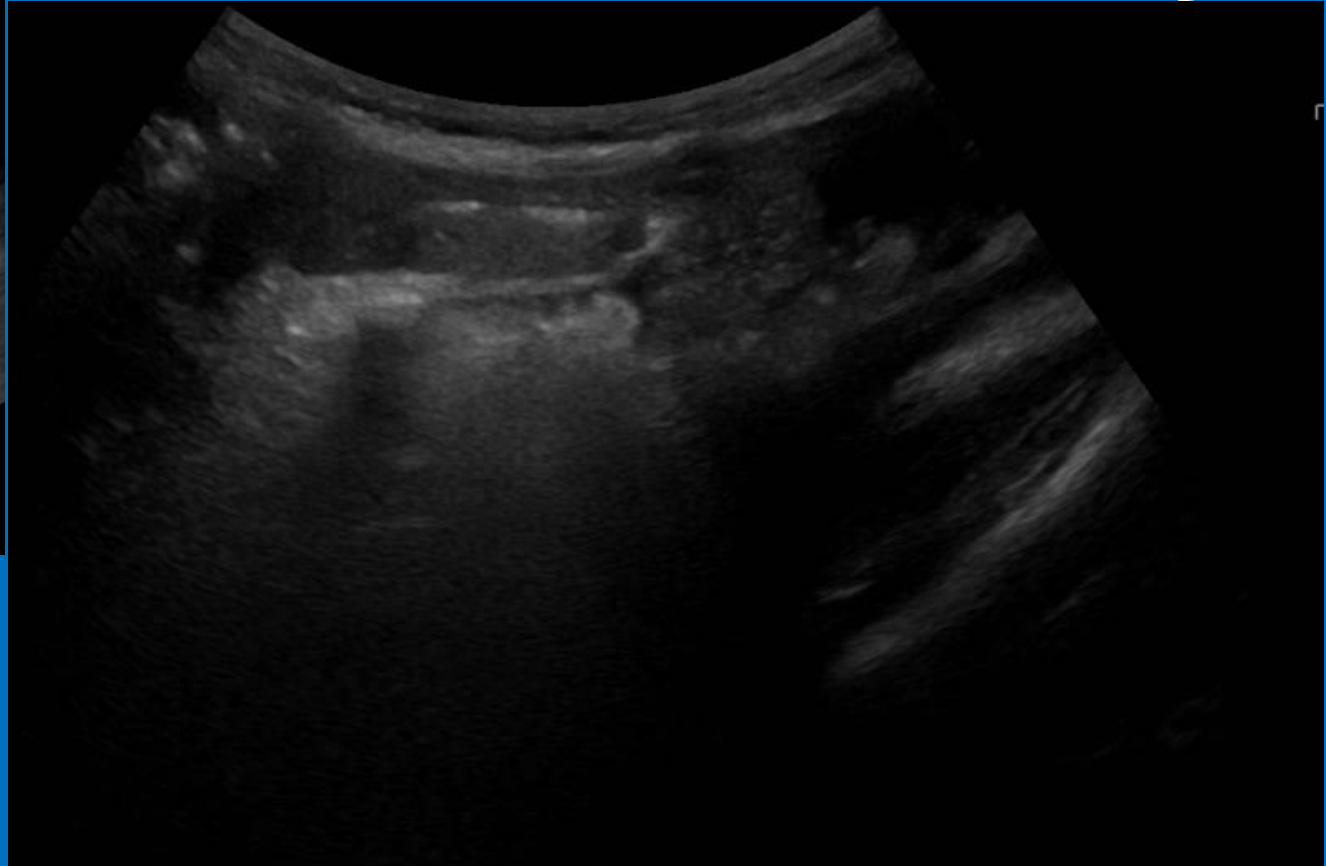
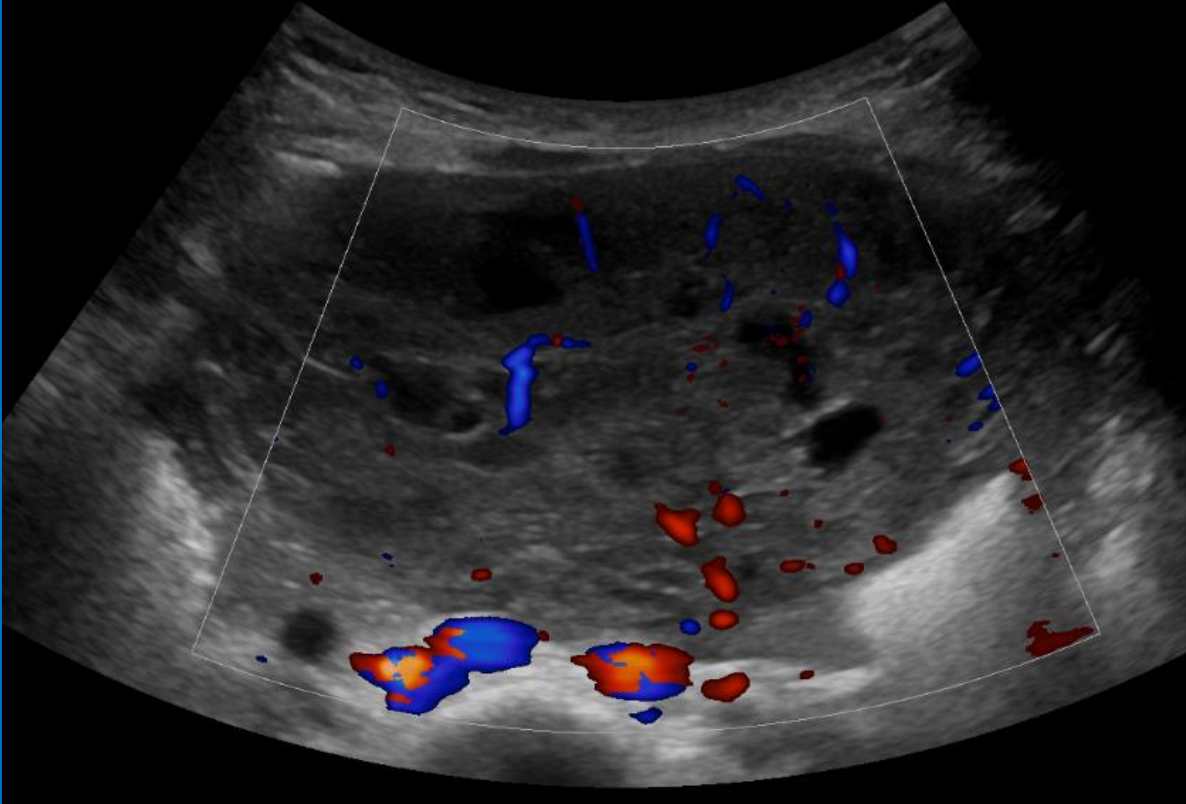
- No menarche



2 yr old female, hx of vaginal discharge and pubic hair growth

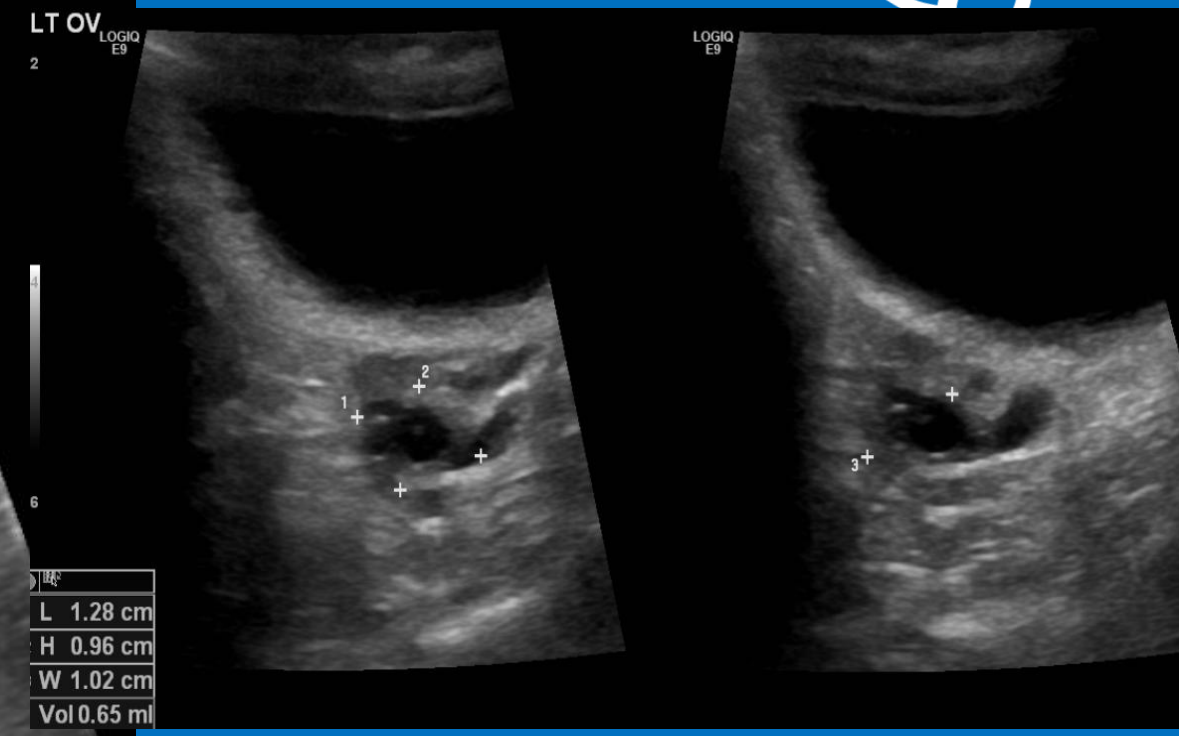
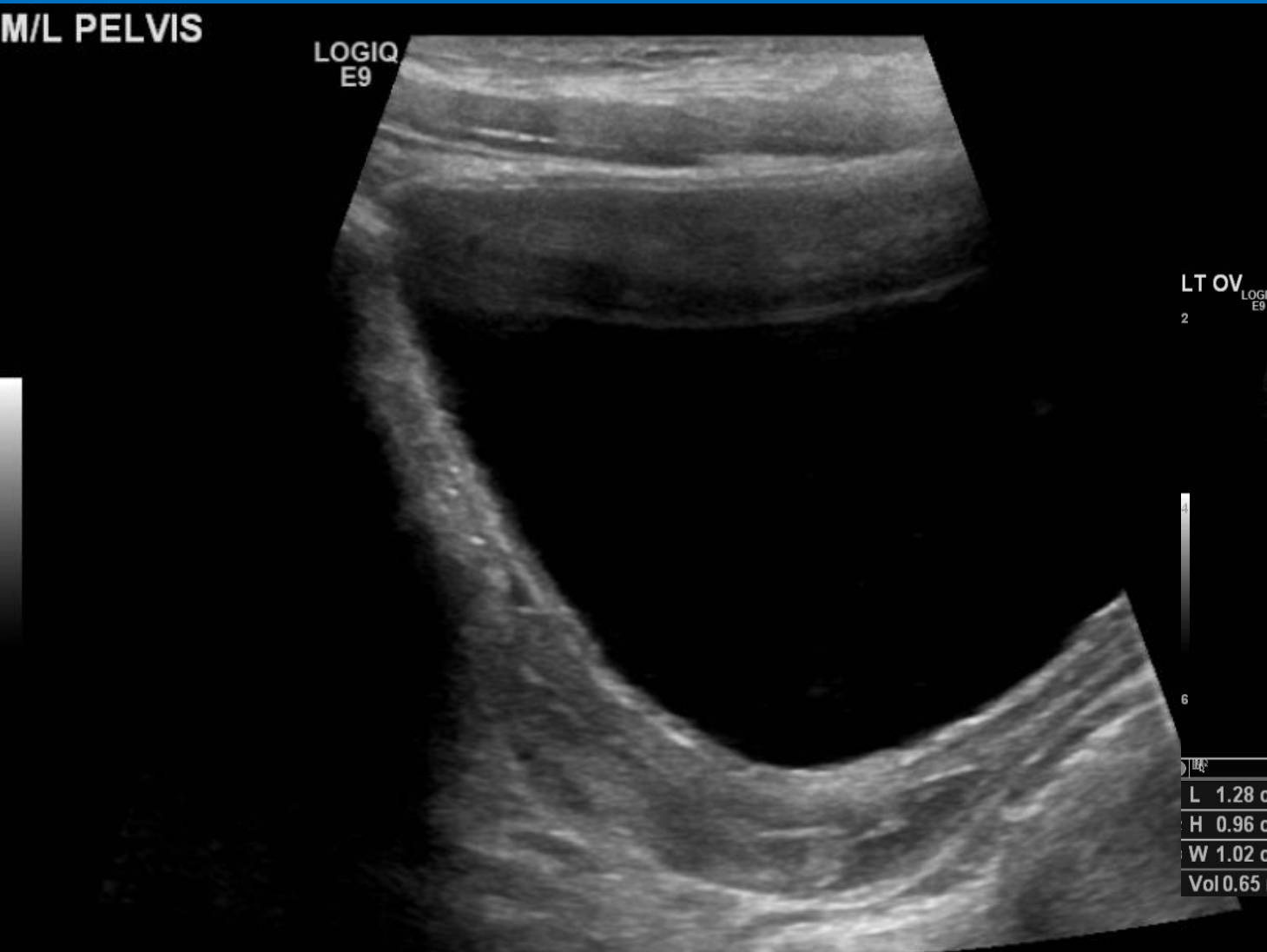


2 yr old female, hx of vaginal discharge and pubic hair growth – (Cine)

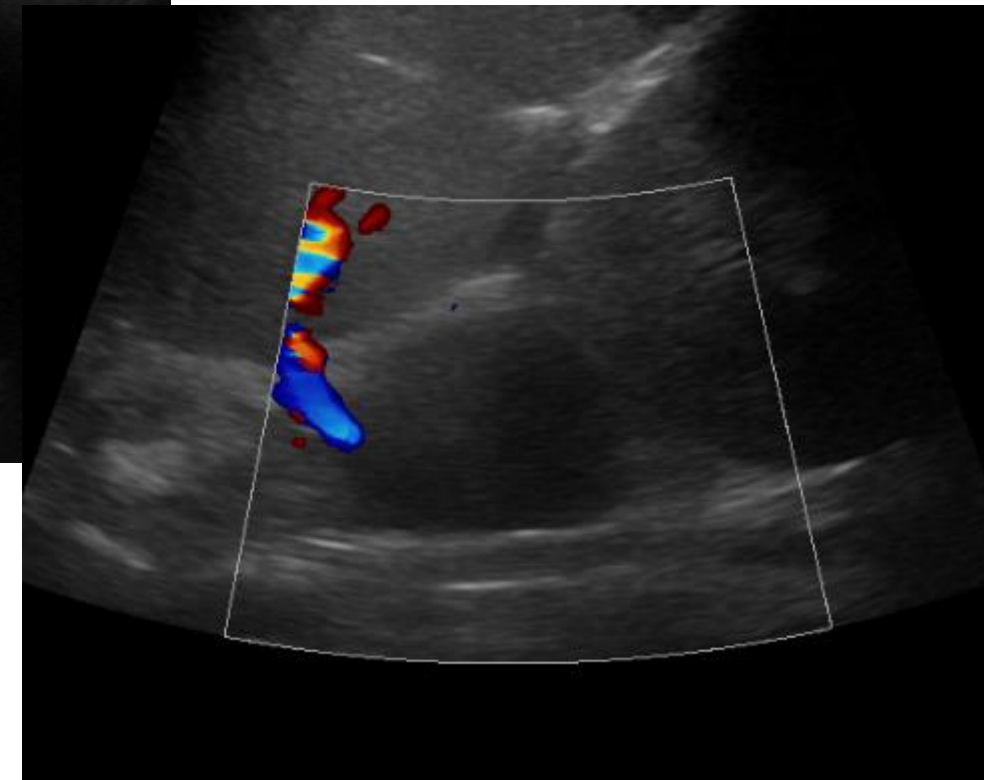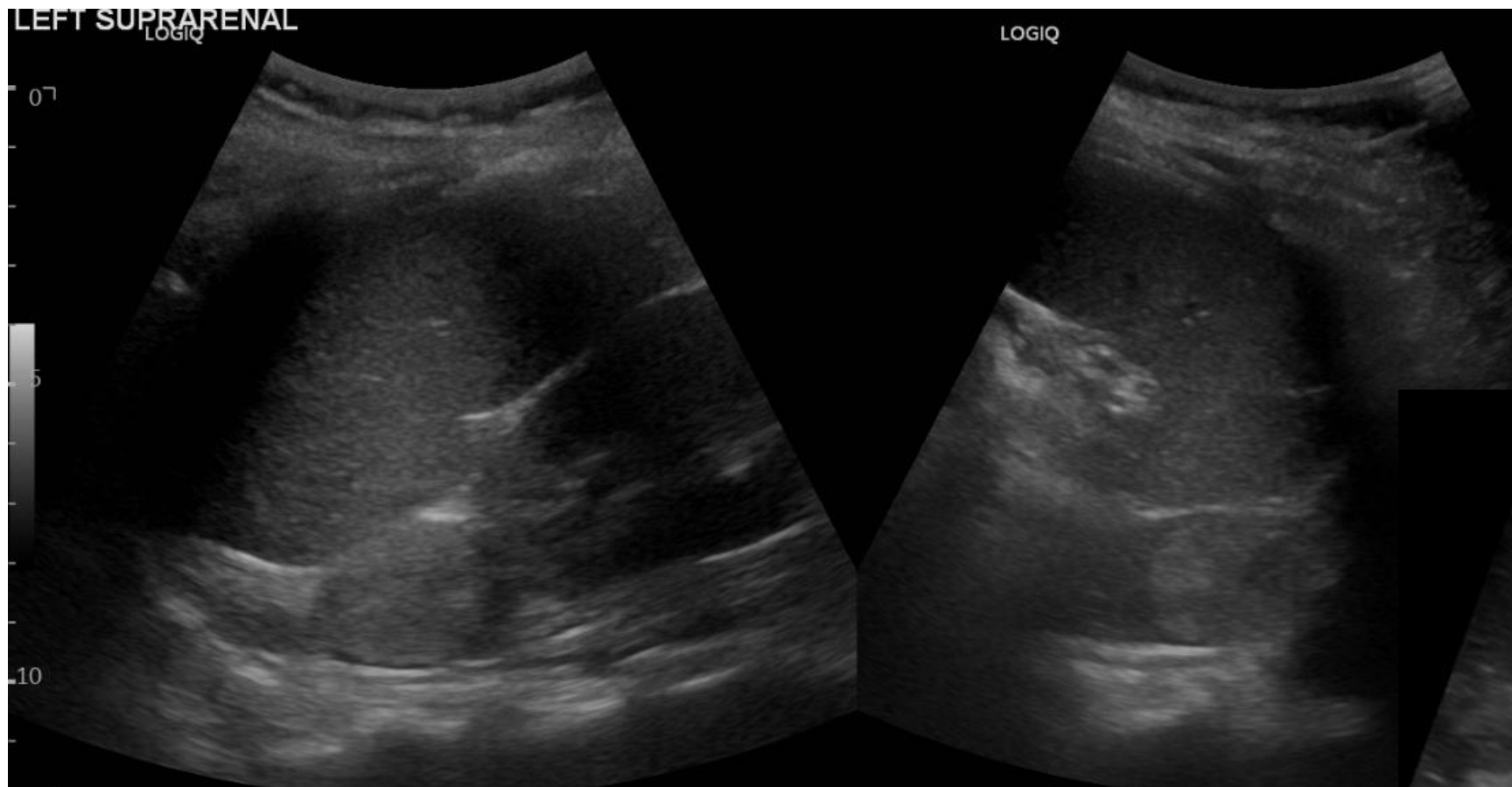


- Juvenile Granulosa Cell tumour
- Large hormonally active mass

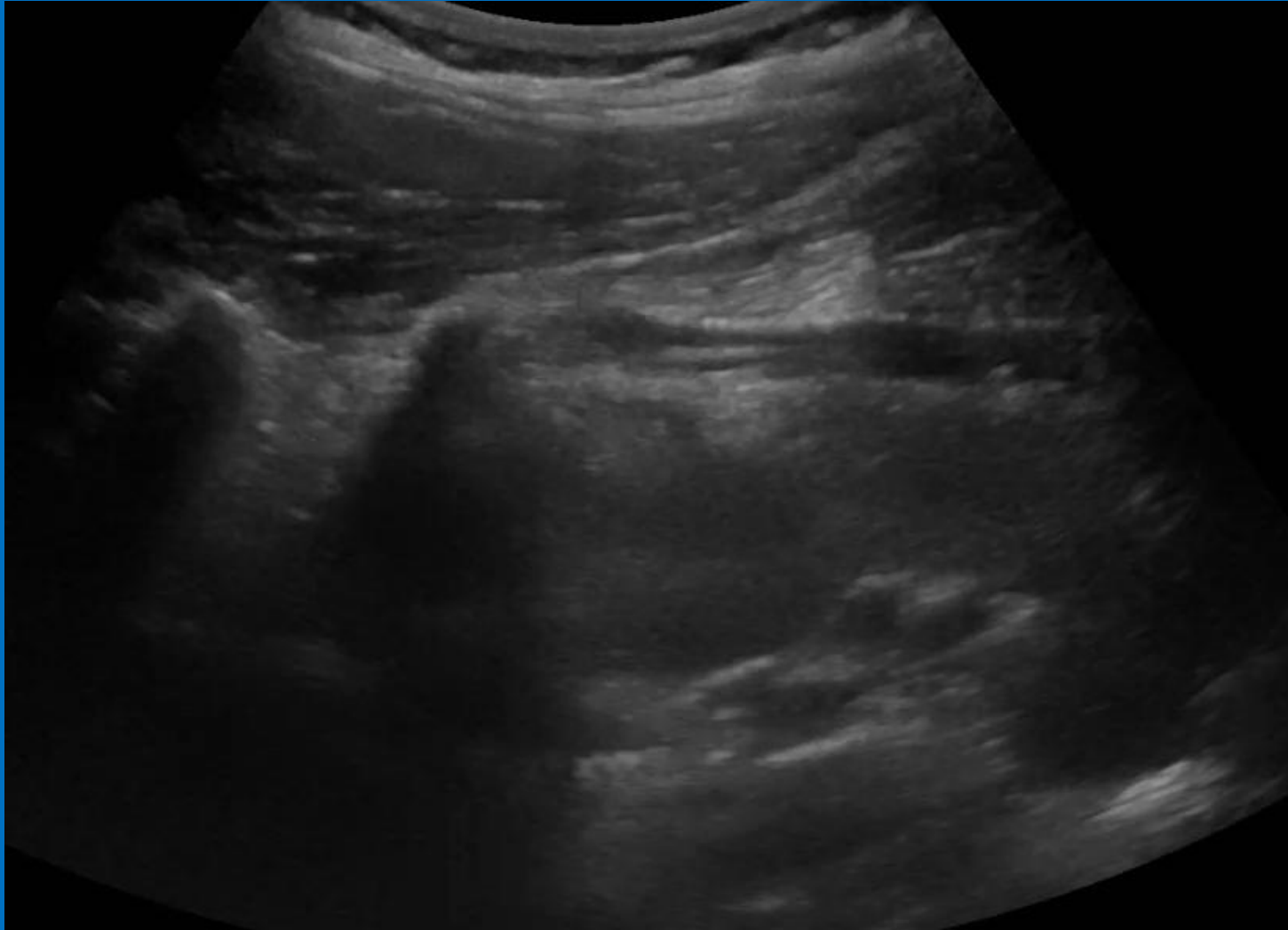
? CAH in 12 yr old boy (international patient)



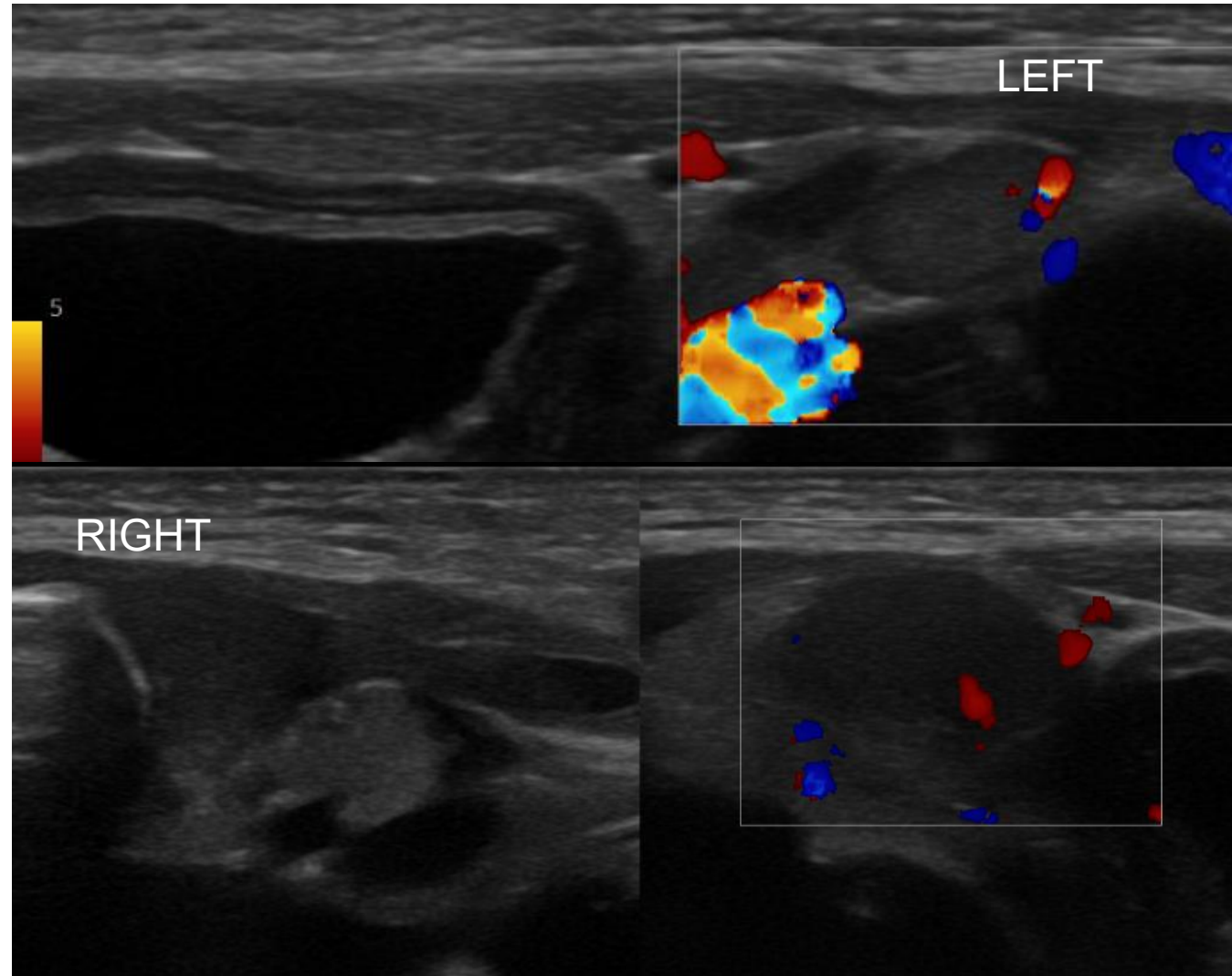
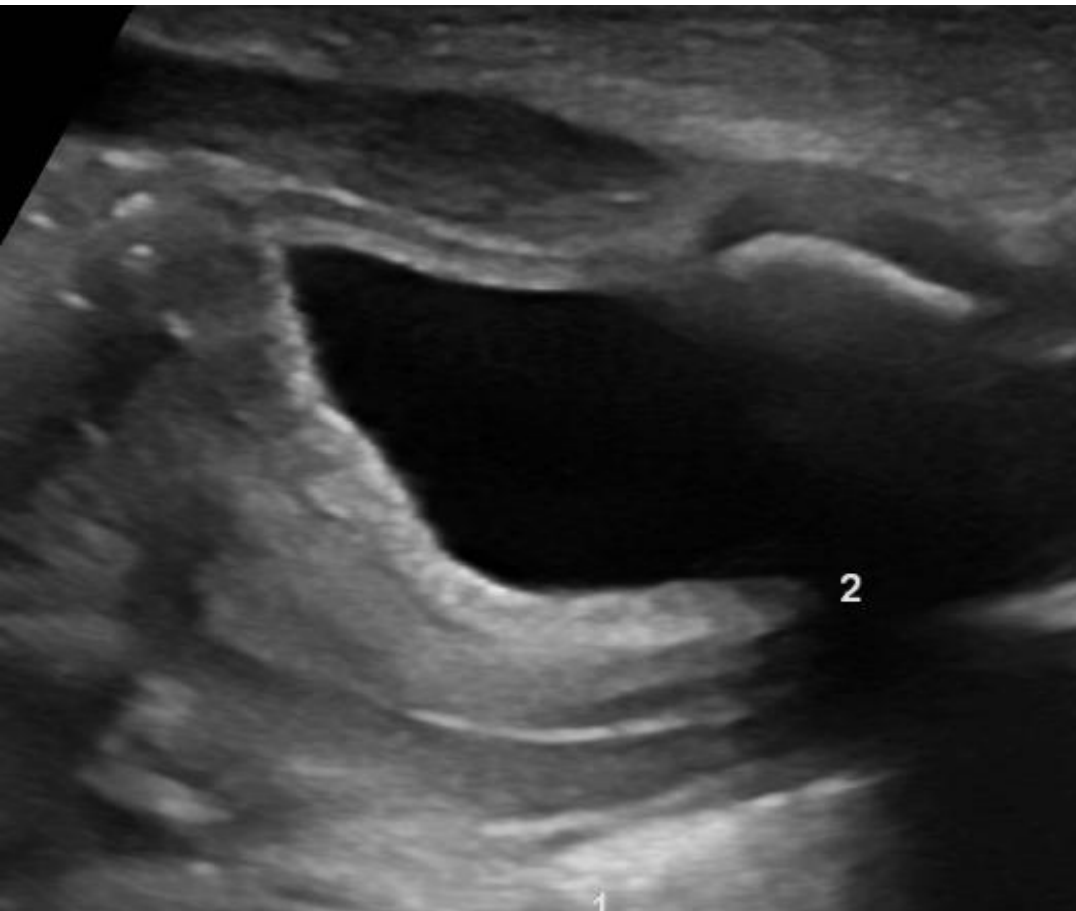
9 yr old girl, CAH and advanced bone age



9 yr old girl with CAH and advanced bone age- (Cine)

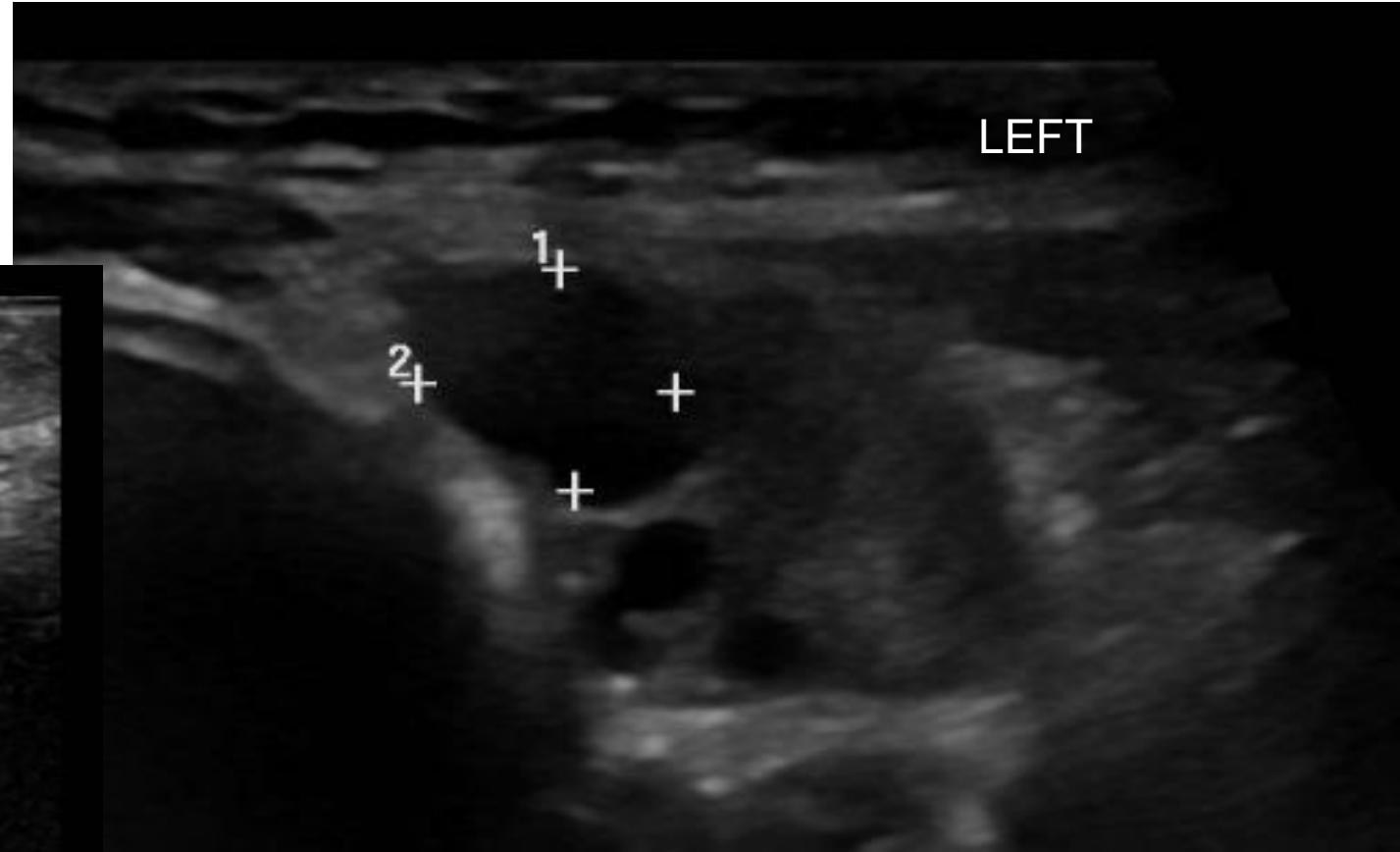
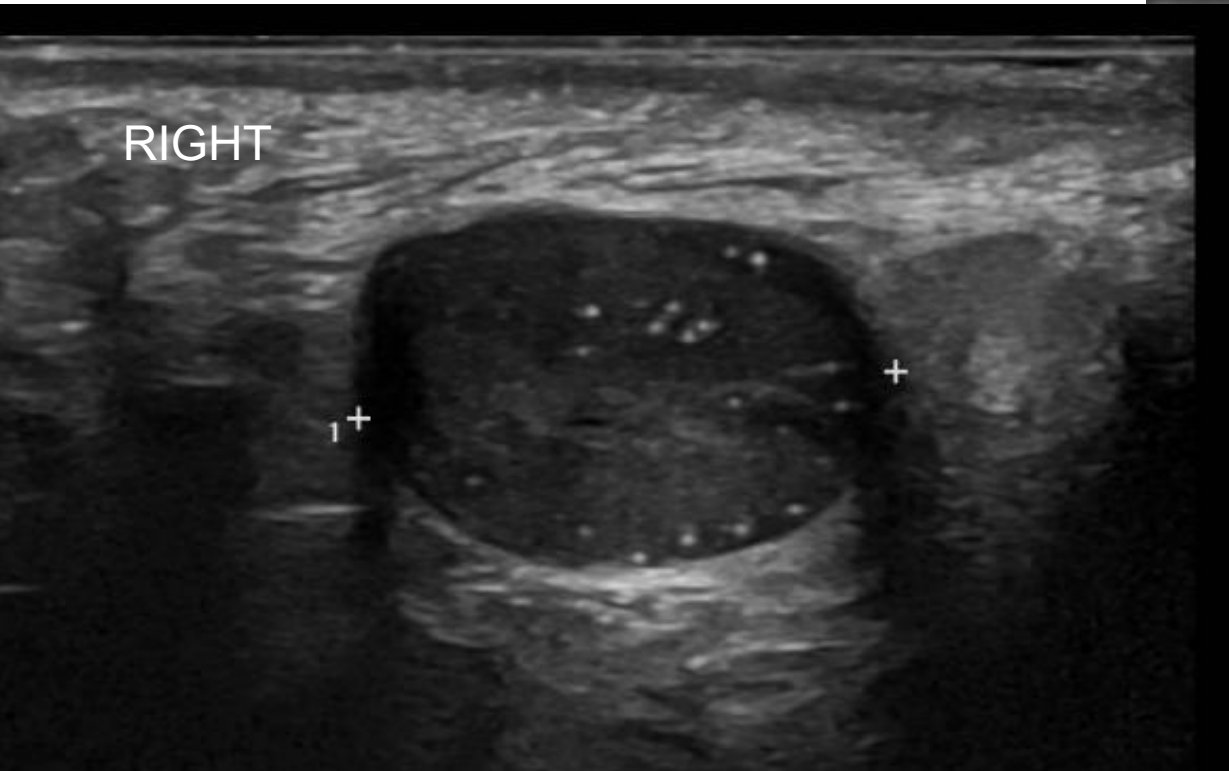


7-day old child with atypical genitalia (large phallus/clitoromegaly), no palpable gonads- looks like a virilised girl. DSD with Turners spectrum, awaiting genetics



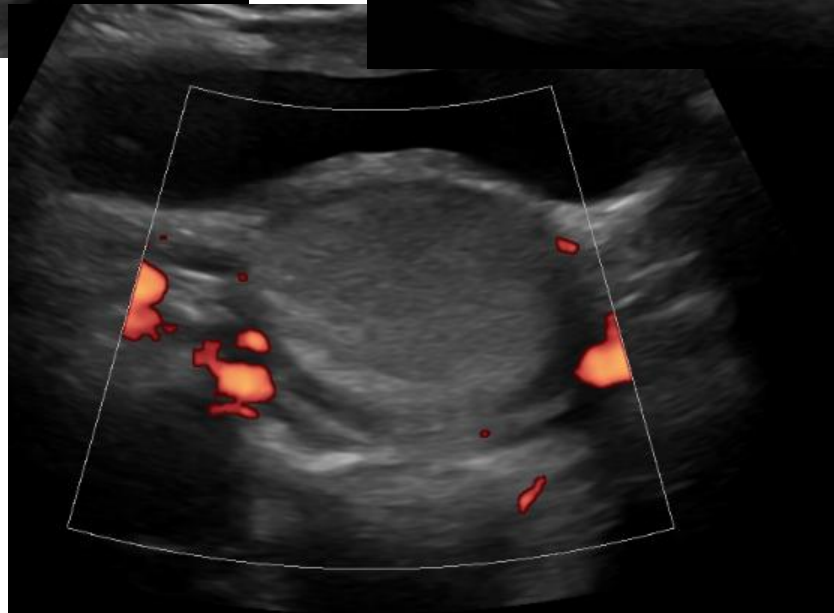
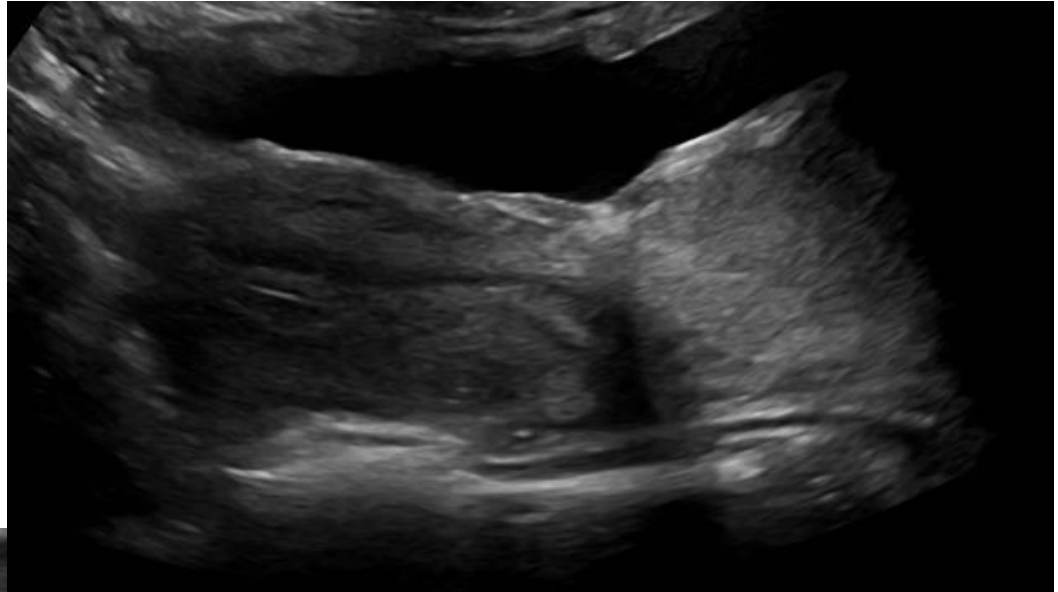
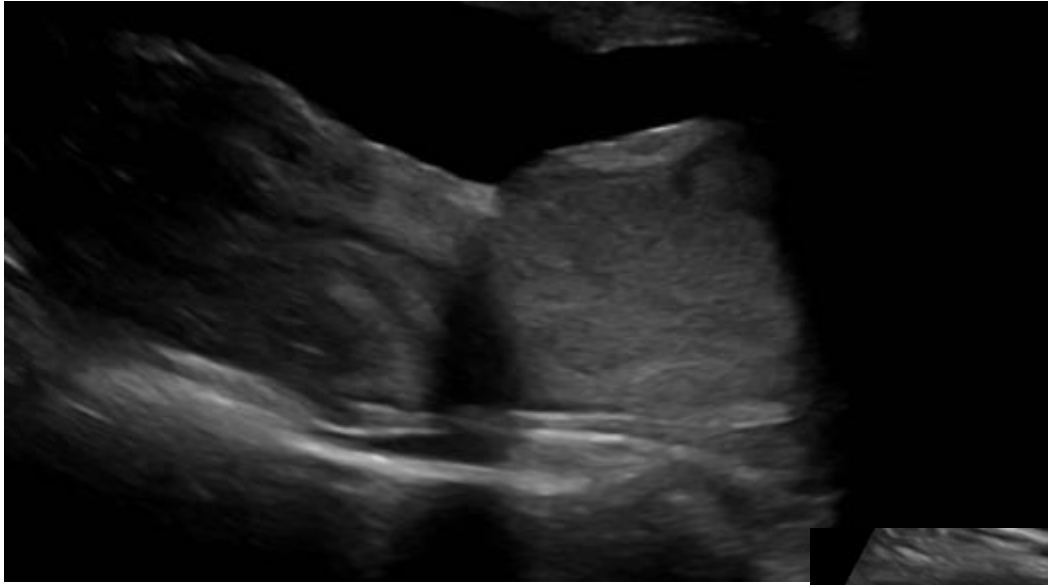
7-day old child with atypical genitalia (large phallus/clitoromegaly), no palpable gonads- looks like a virilised girl. DSD with Turners spectrum, awaiting genetics

***1.5 years later ***



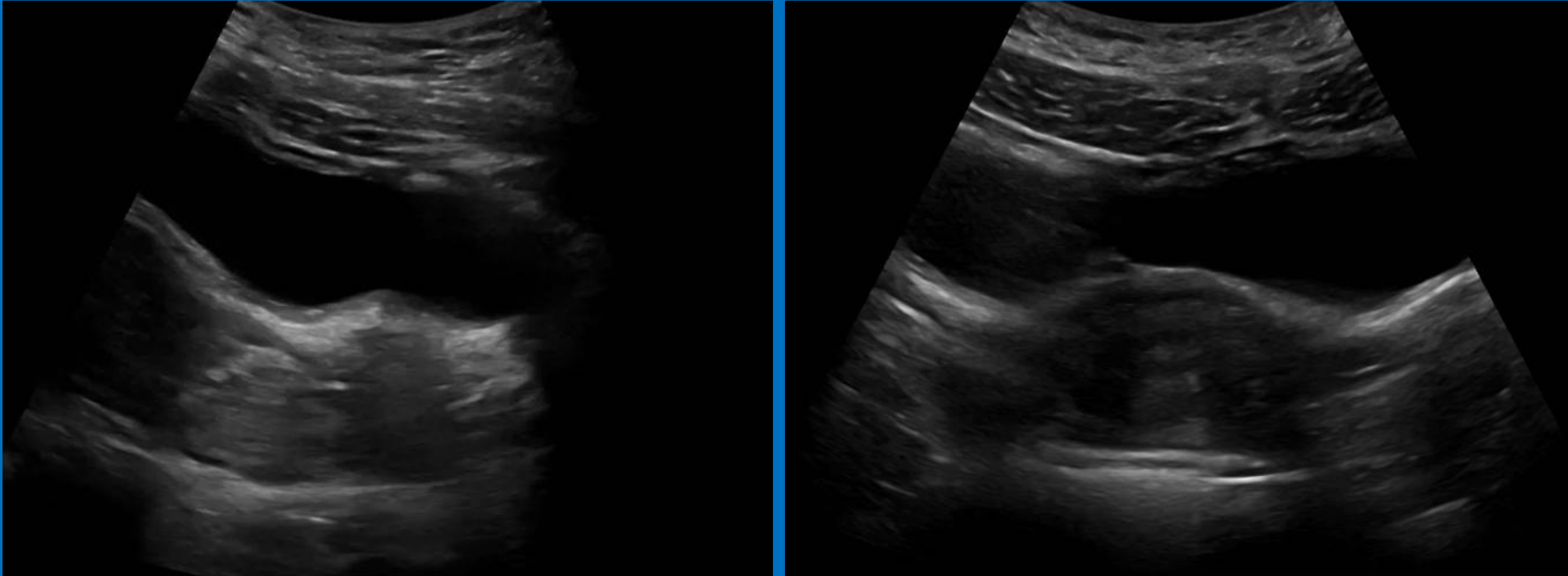
- **TURNERS with MOSAIC KARYOTYPE**

?bladder neck/paravaginal mass

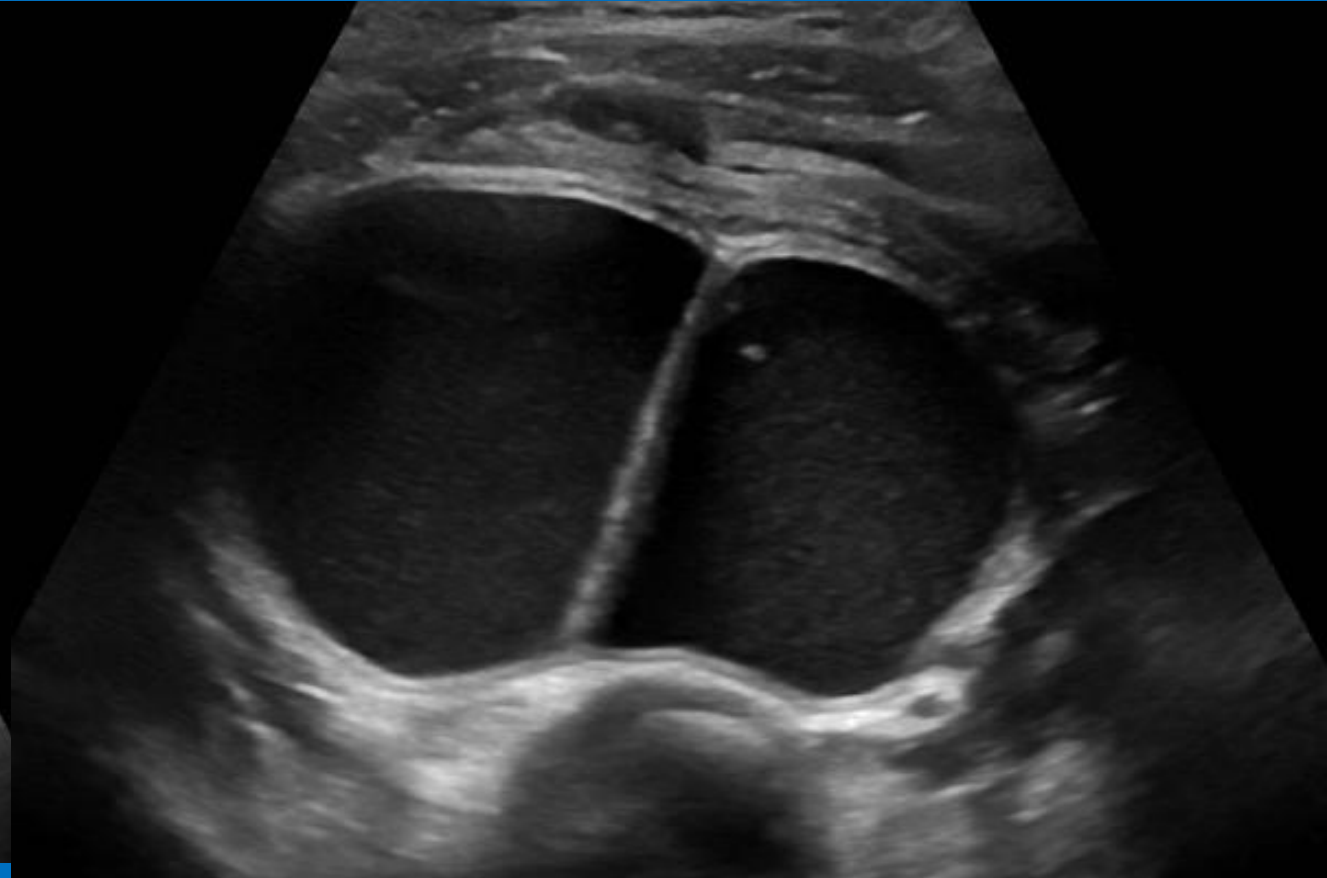
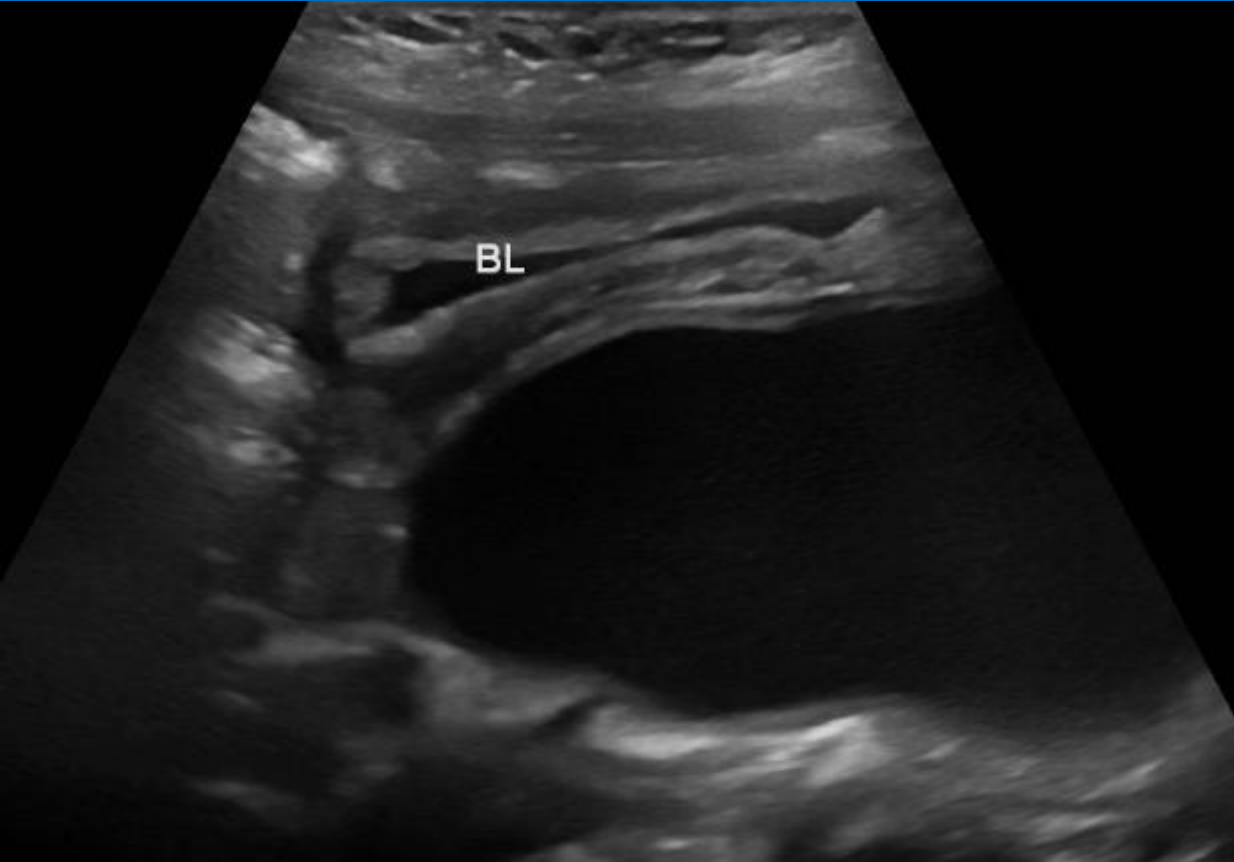


?bladder neck/paravaginal mass- (Cine)

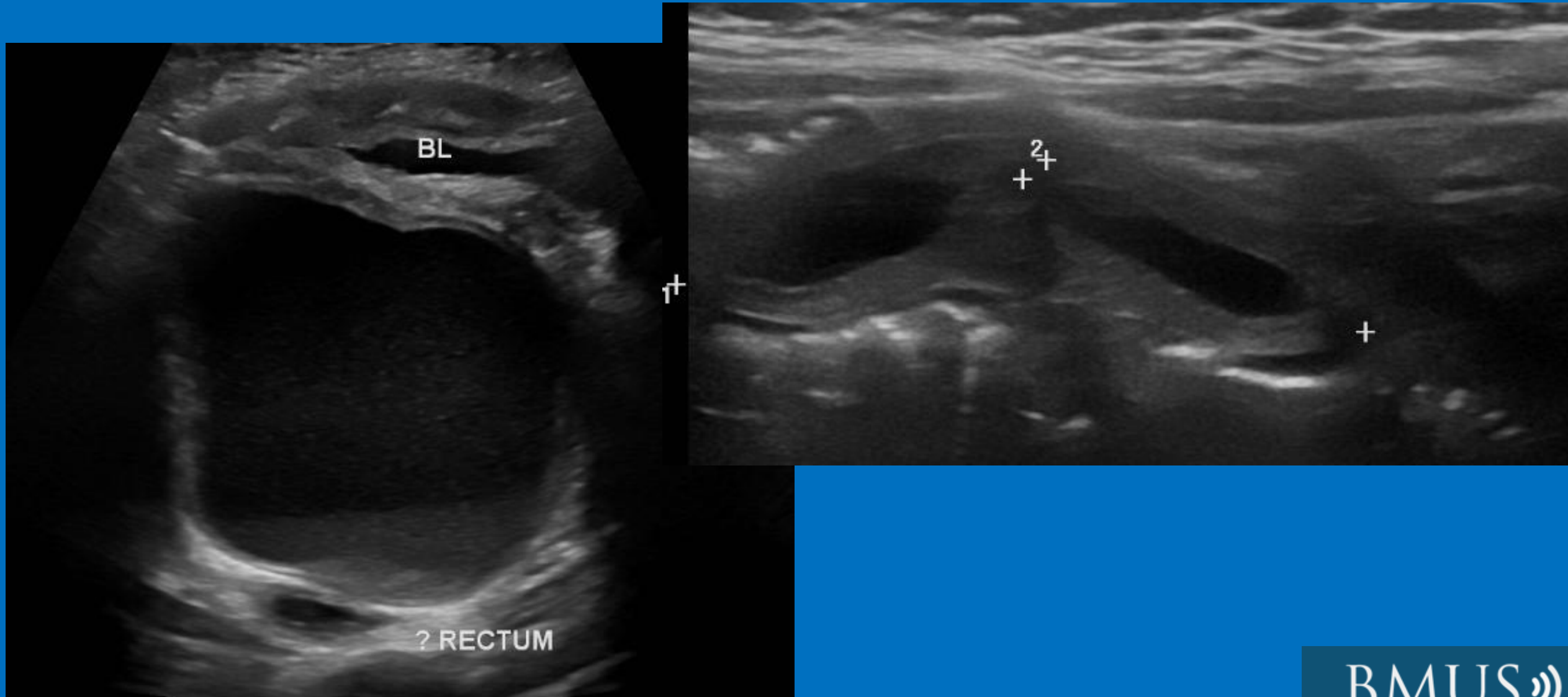
- Bladder neck Deflux



1 yr old girl, Cloaca and Mullerian duplication



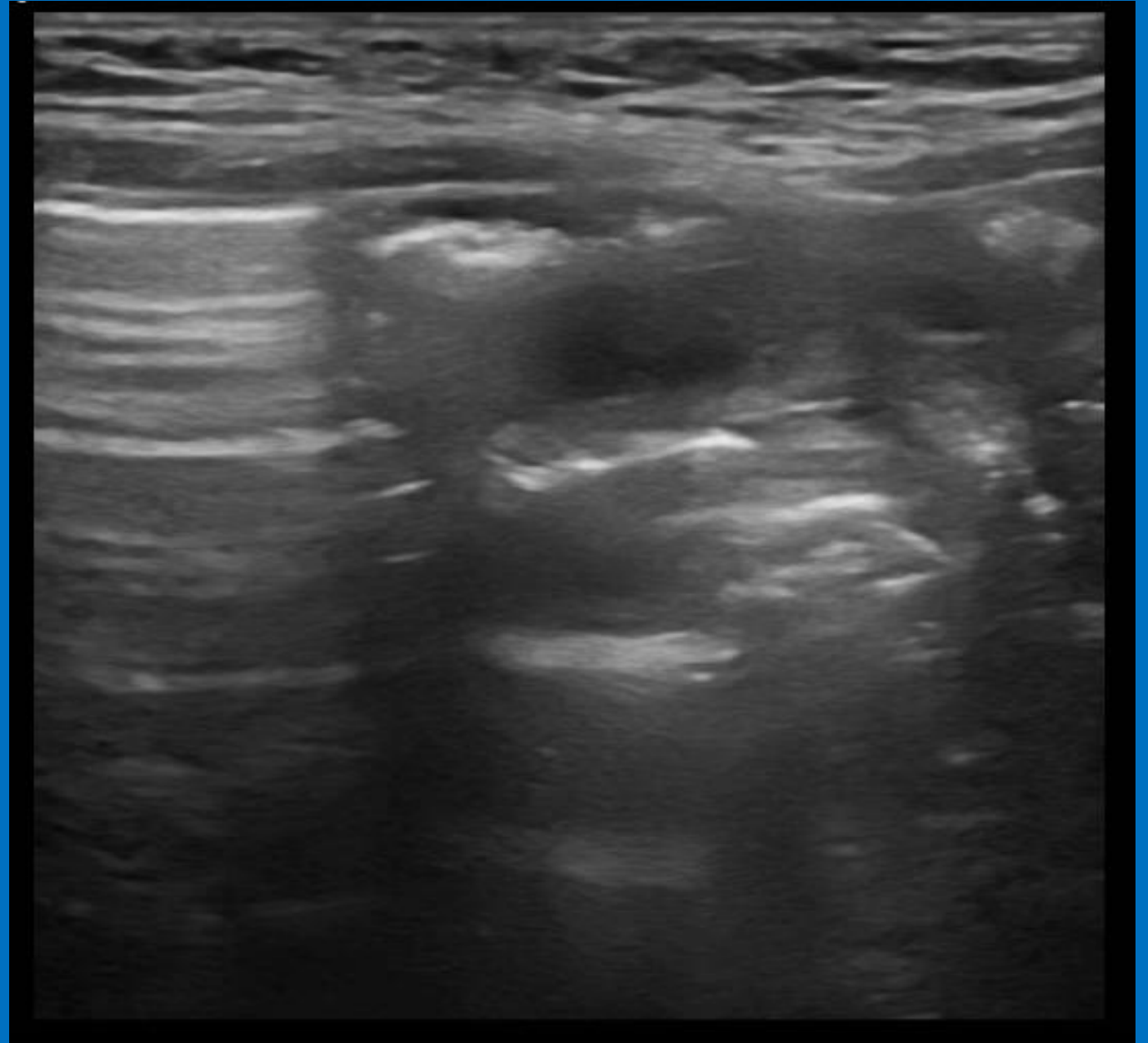
1 yr old girl, Cloaca and Mullerian duplication



1 yr old girl, Cloaca and Mullerian duplication- (Cine)



- Hydrometrocolpos with didelphic uterus and septated Vagina



- Difference in technique/transducers
- Stages of uterine development
- Be methodical. Extend the scan if necessary
- Patience is key (full bladder too)

Thank you for listening!

- Contact us on:
 - Gorseley.Leung@gosh.nhs.uk
 - Stacey.Thomas@gosh.nhs.uk

