



Compression PoCUS for DVT

#POCUSClubInternational

Sponsored by  GE HealthCare

Borsha Sarker

Clinical Specialist Sonographer

DCR. DMU. AVS. MHSc.

gECHO ultrasound solutions ltd.

NIHR Leeds Biomedical Research Centre

borsha@squeeakybird

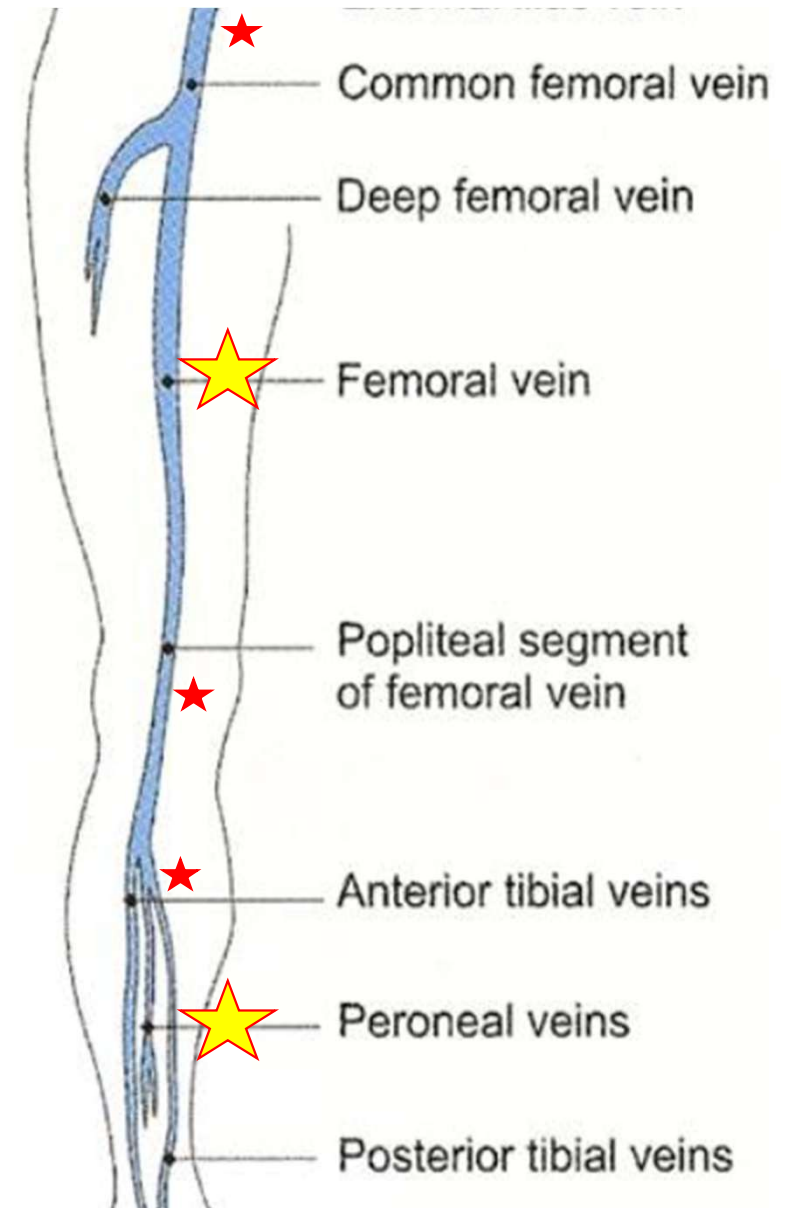
borsha.sarker@nhs.net

Which ultrasound technique?

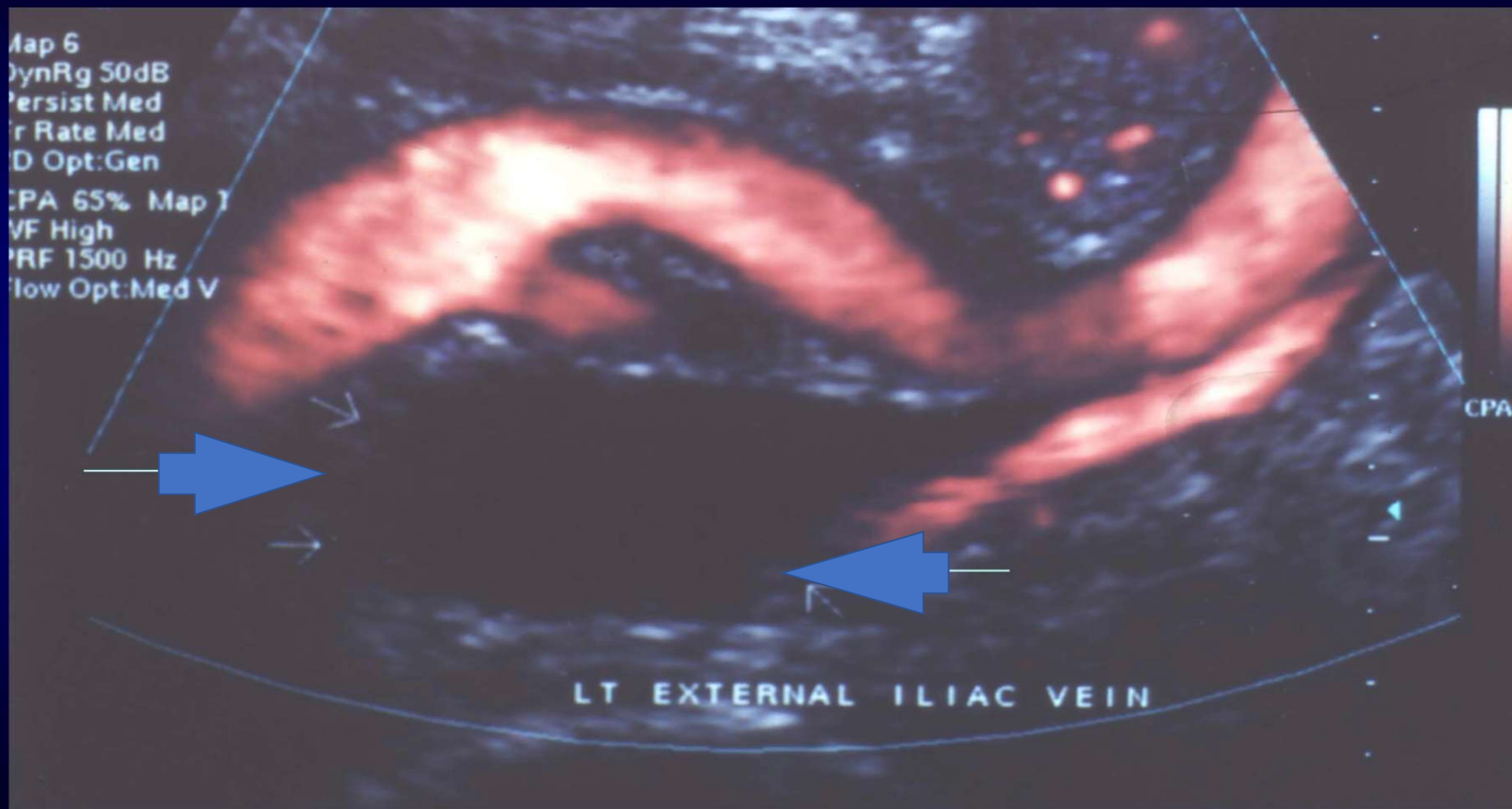
2 point compression }
3 point compression } *

5 point compression ★

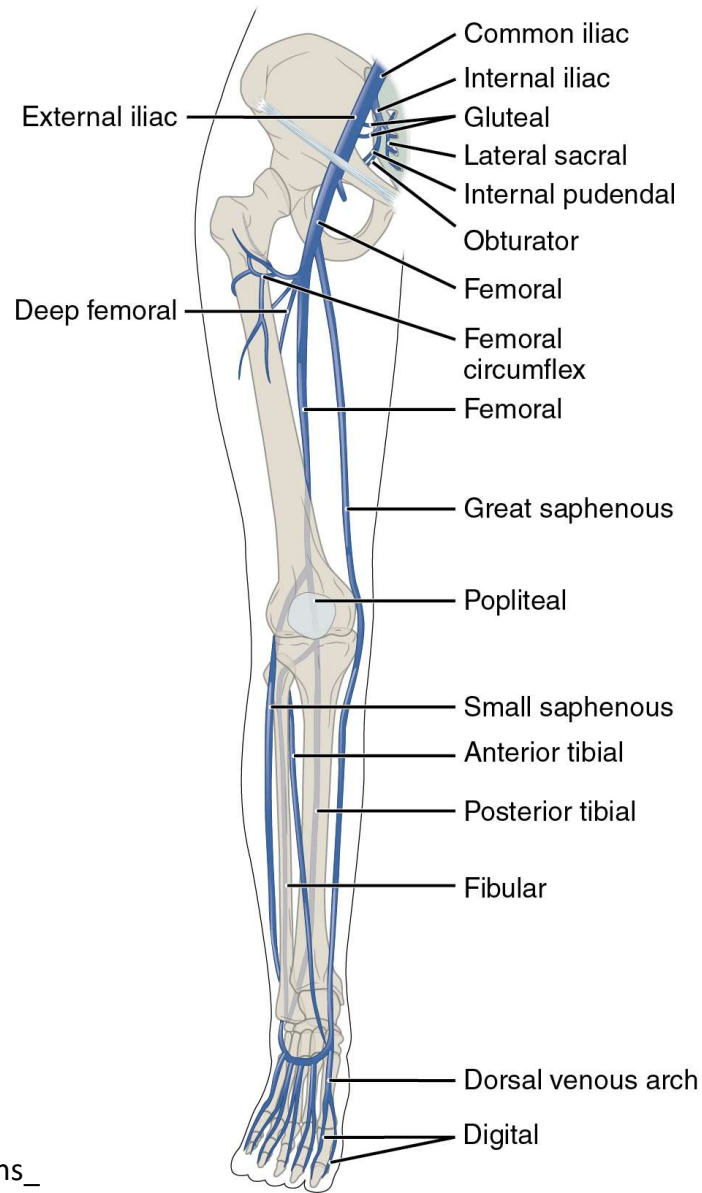
Full leg using Doppler and compression?



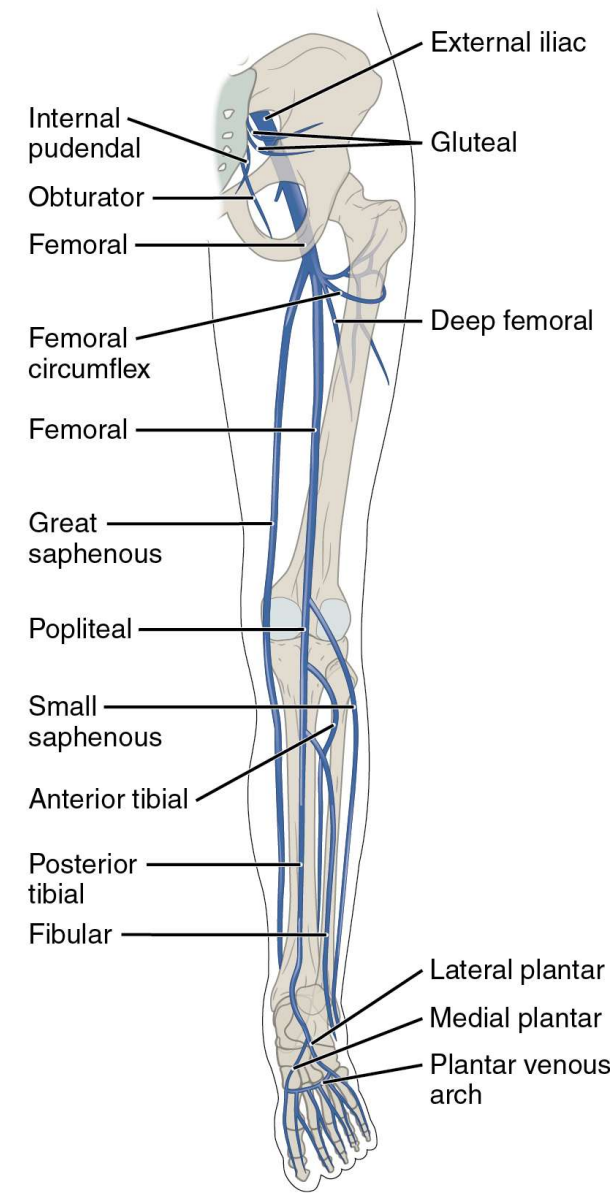
The aim is to prevent fatal pulmonary embolus



Compression PoCUS for DVT

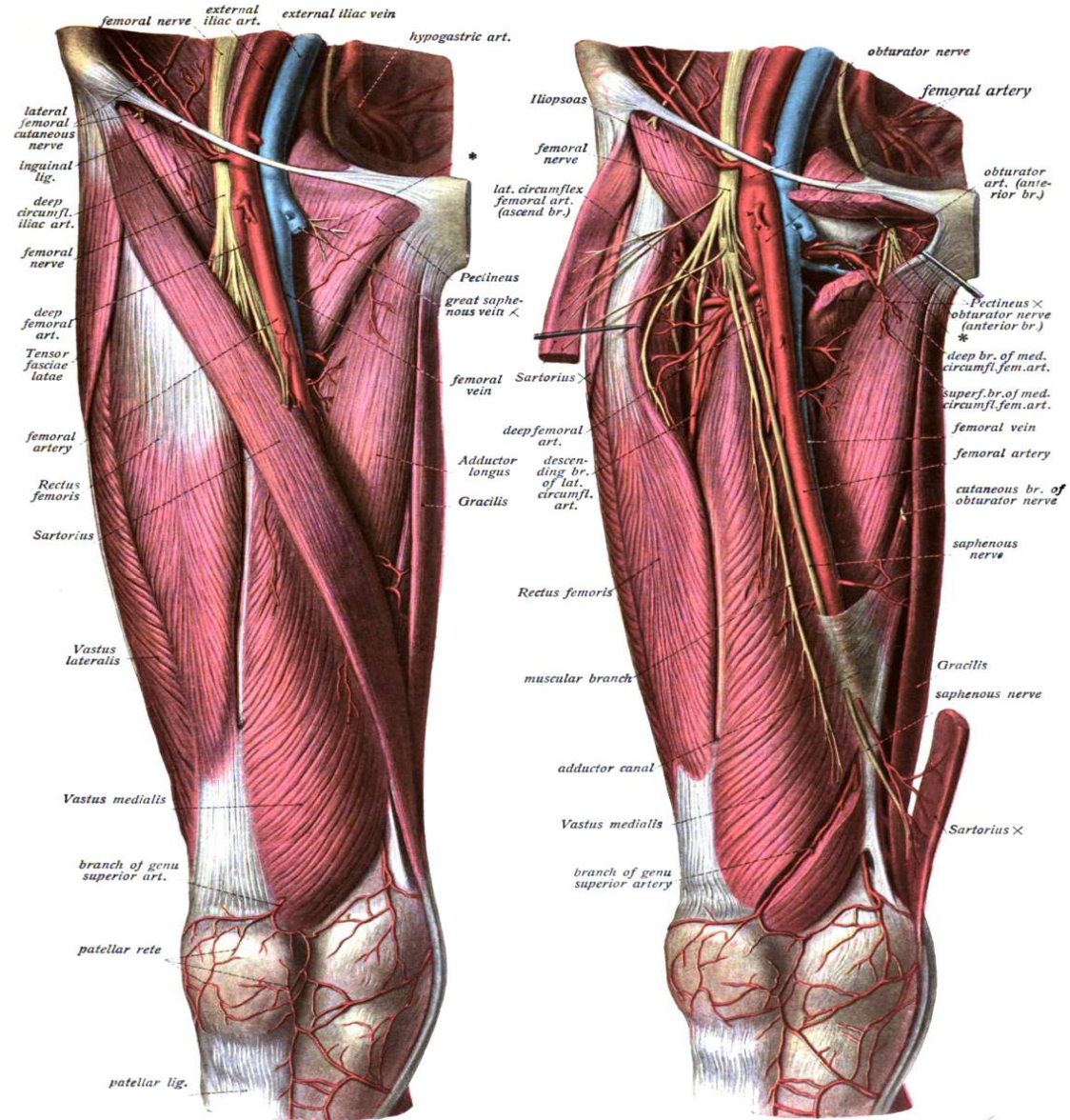
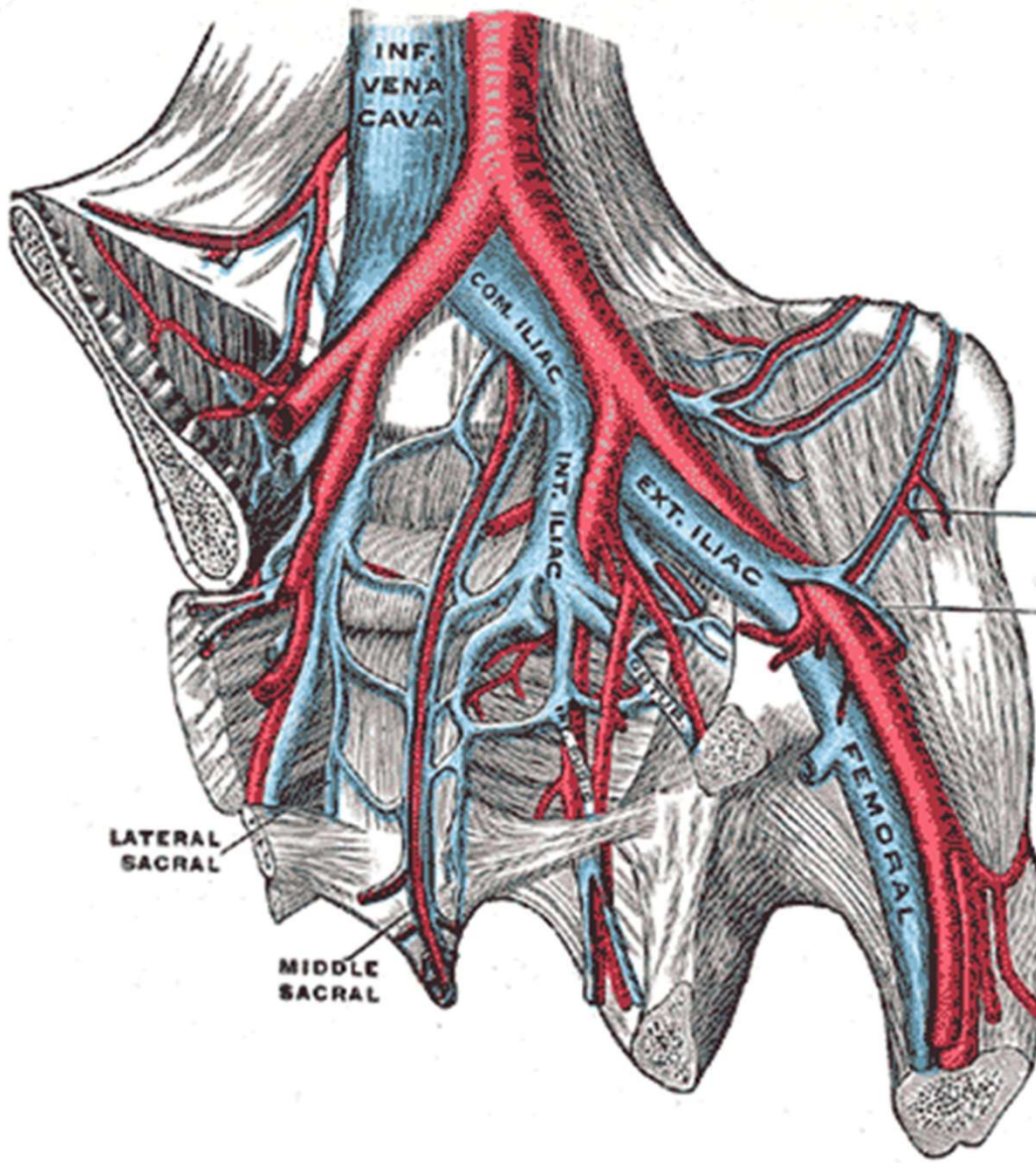


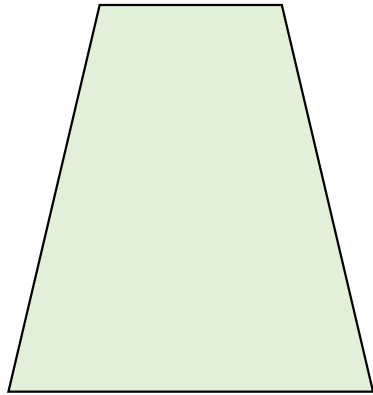
Anterior view



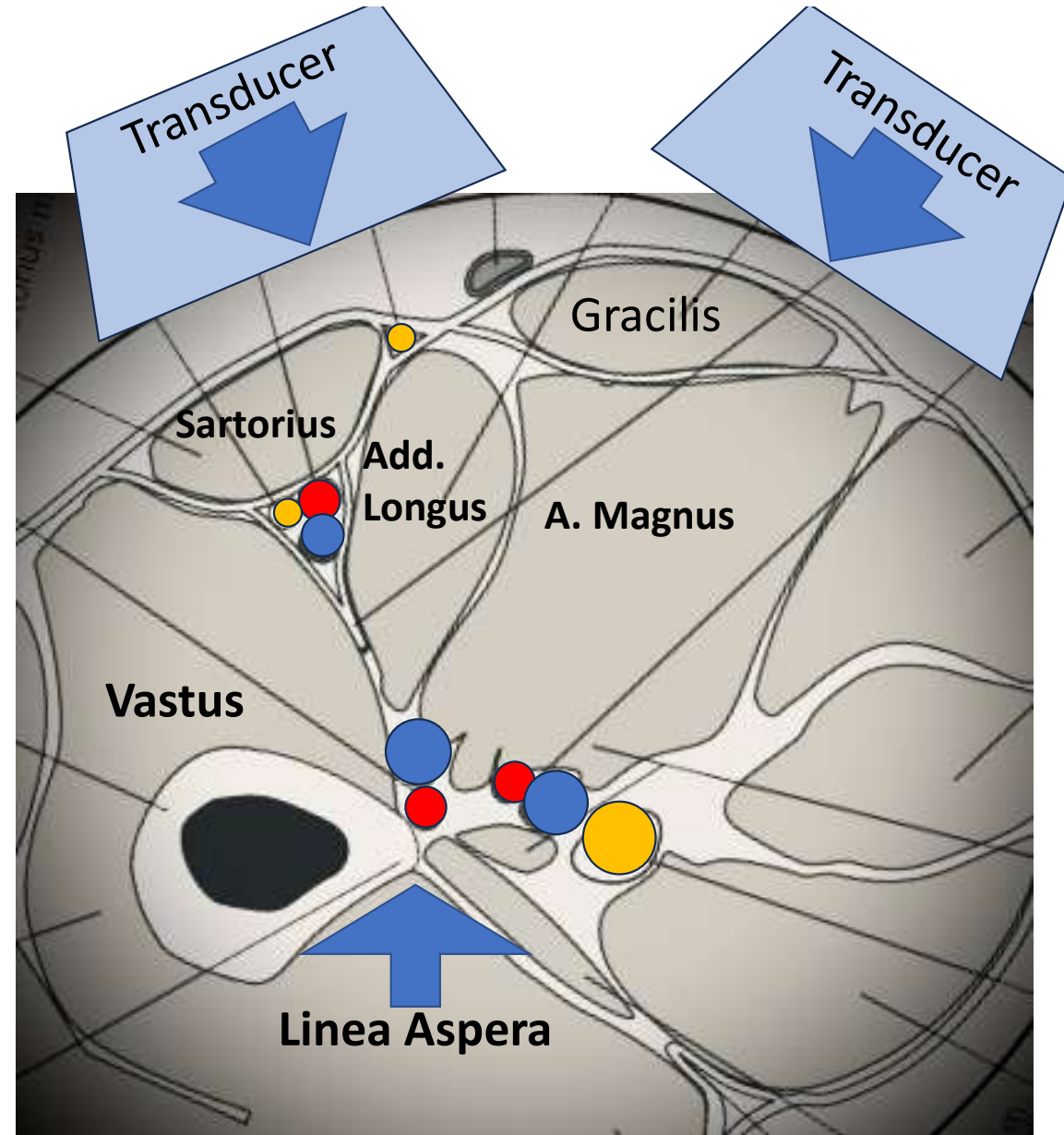
Posterior view

https://en.m.wikipedia.org/wiki/File:2136ab_Lower_Limb_Veins_Anterior_Posterior.jpg



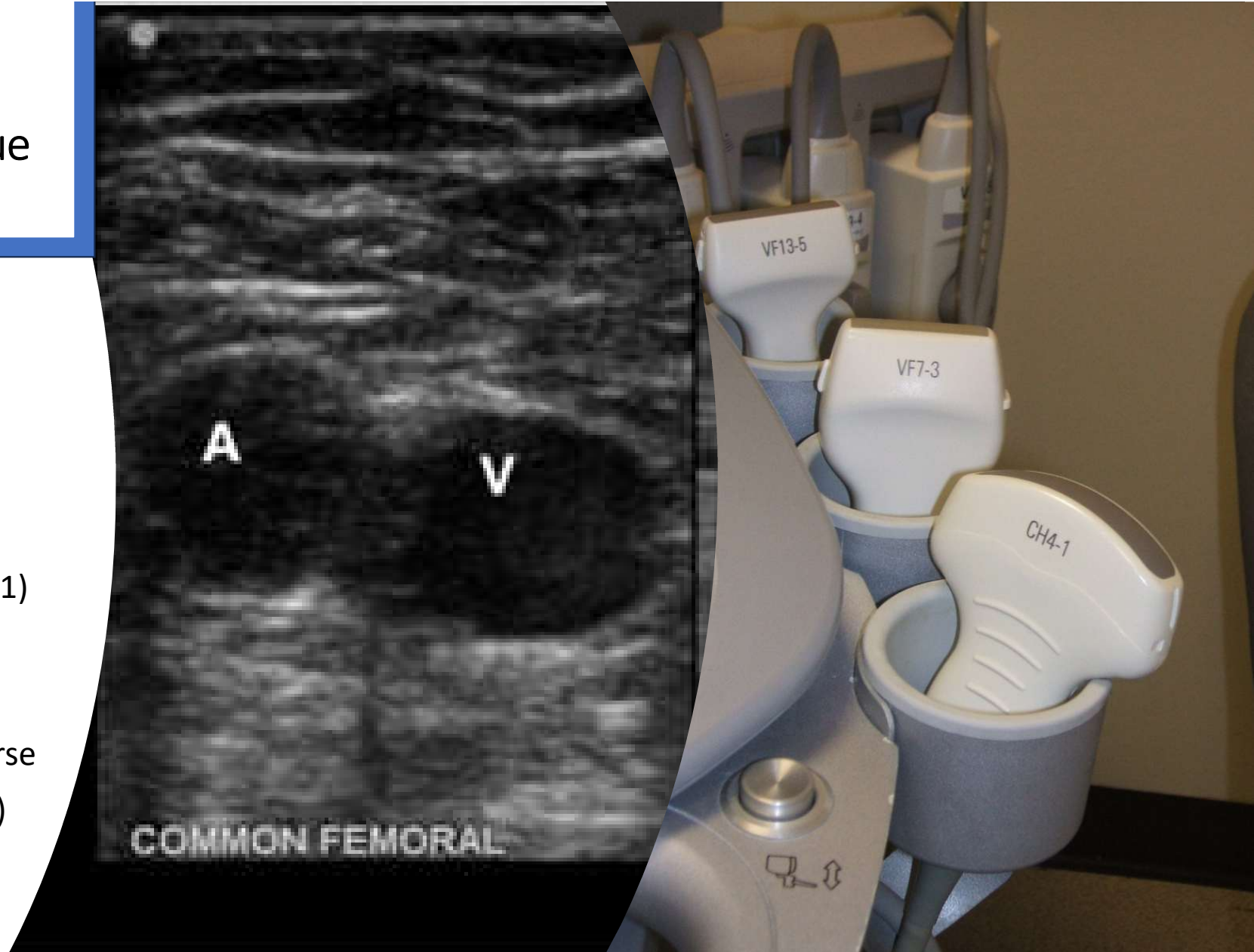


Effective Compression
of the Femoral V

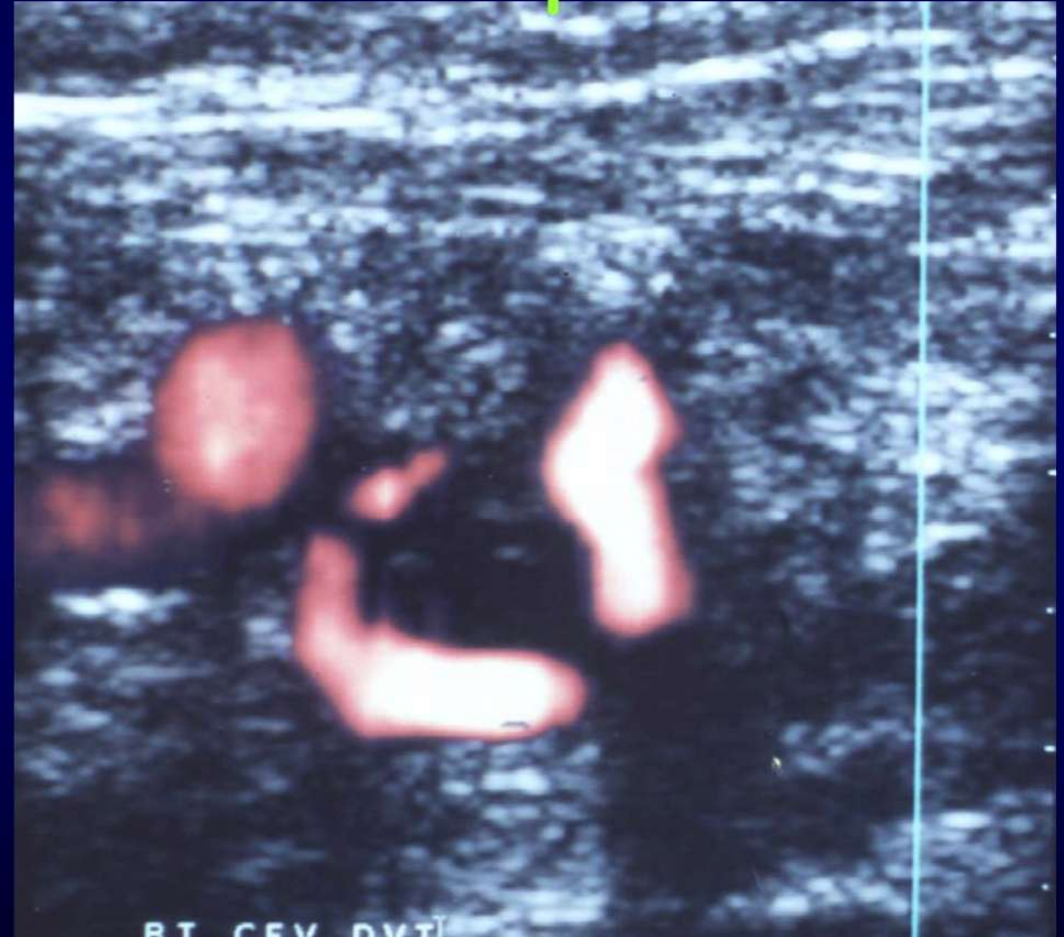
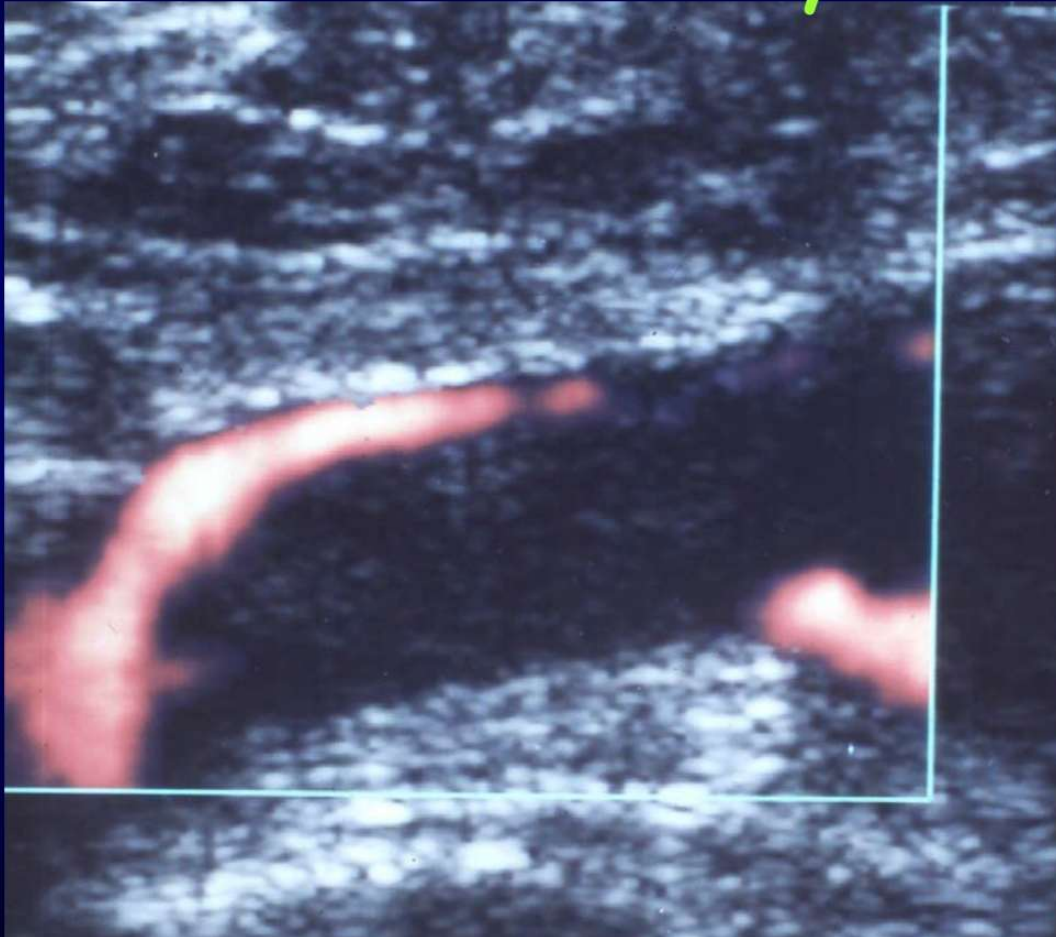


2, 3 or 5 point compression technique

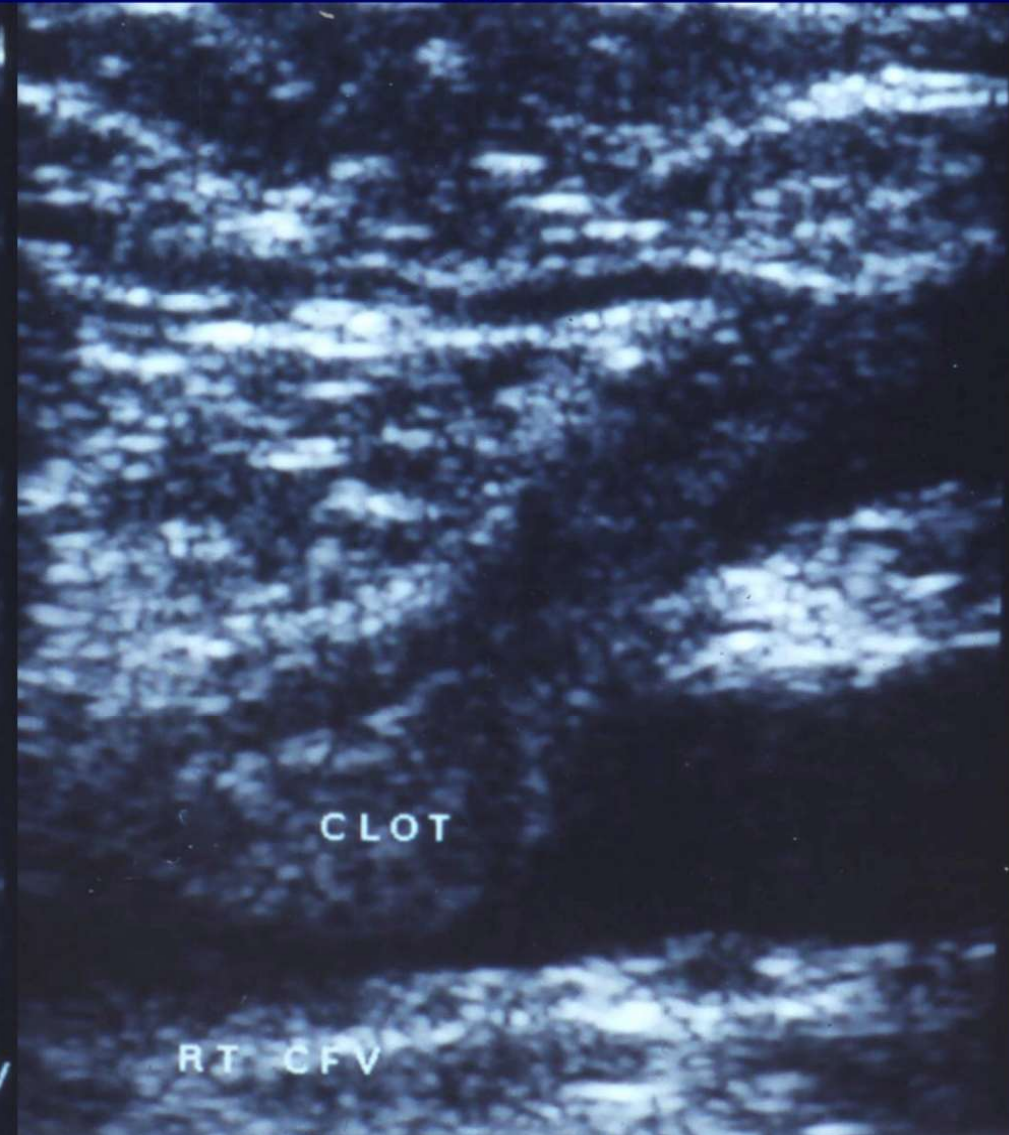
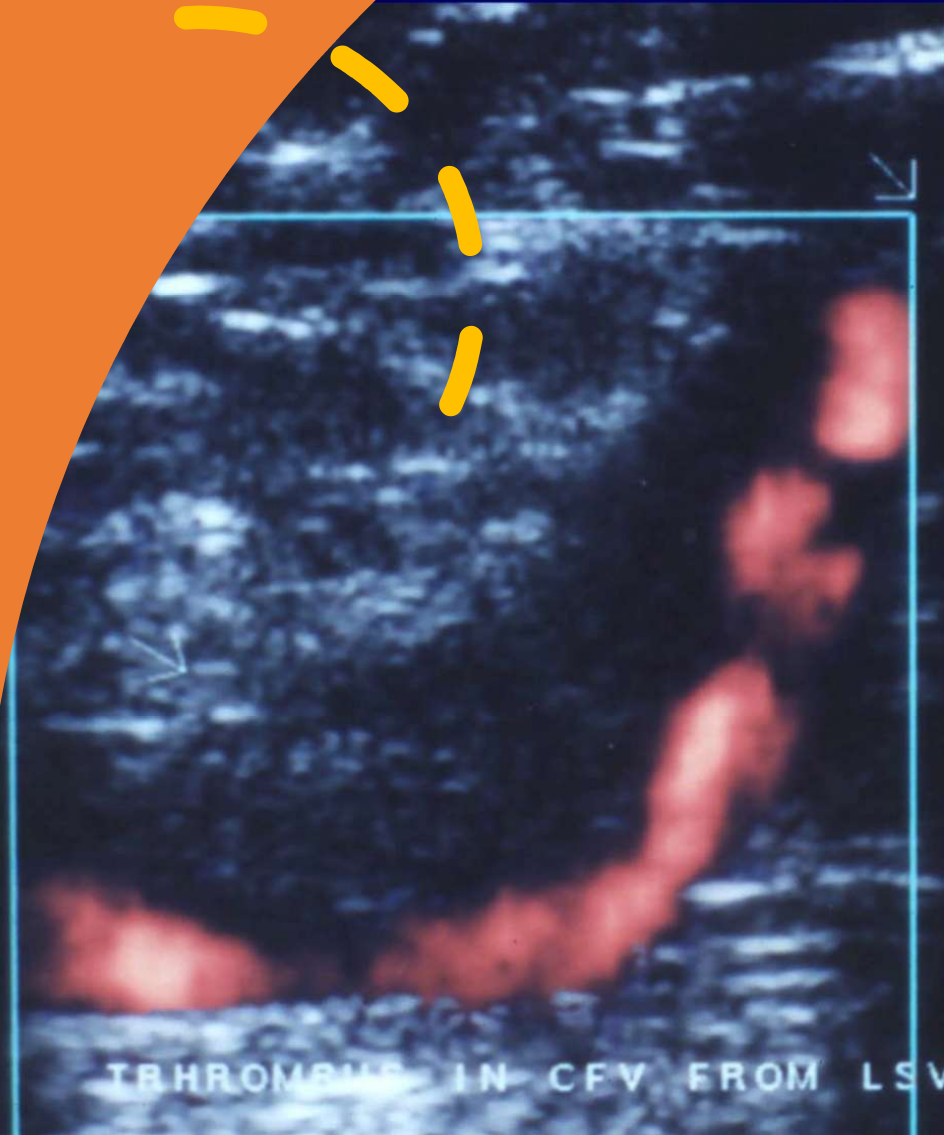
- Linear Transducer
 - low frequency
- Curved Transducer
 - high frequency
- Patient semi-recumbent (1)
- Groin & thigh exposed
- Externally rotated leg
- Compress only in transverse
- Sit patient bolt upright (2)
- Compress towards bone



Acute thrombus is isoechoic and lies centrally within the deep veins



Thrombophlebitis >> Right CFV DVT



QUEEN ELIZABETH HOSPITAL

L7-4 38mm PVasc/DVTS

09:09:54

F# 98 3.8 cm

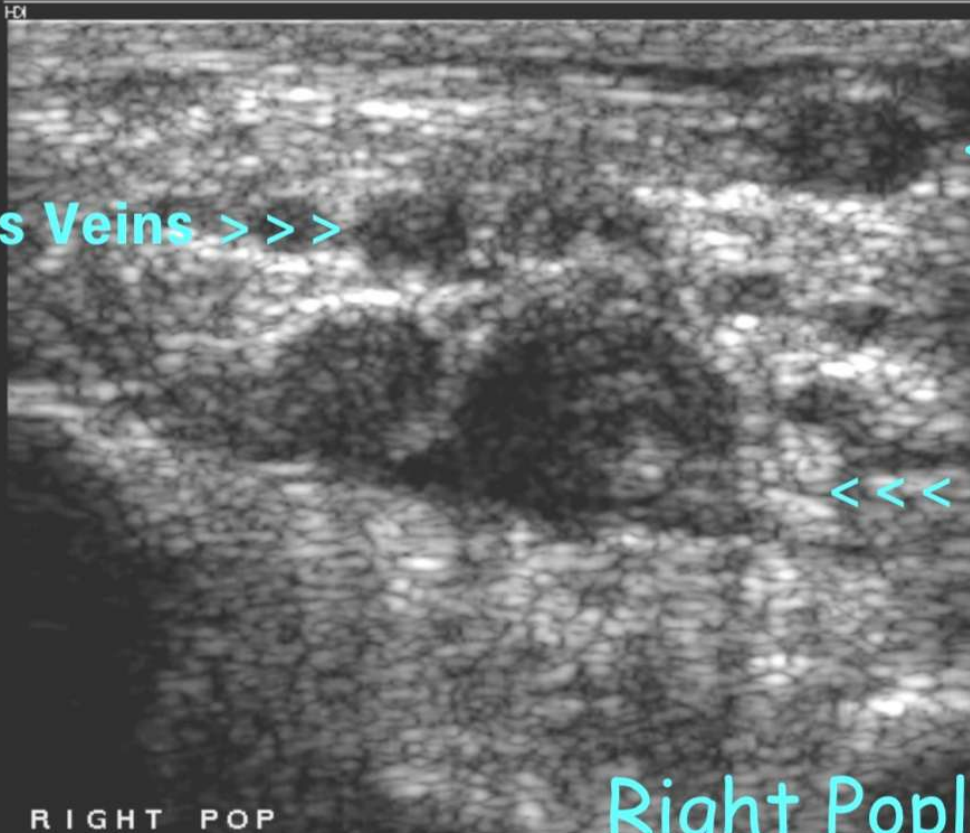
Gastrocnemius Veins >>>

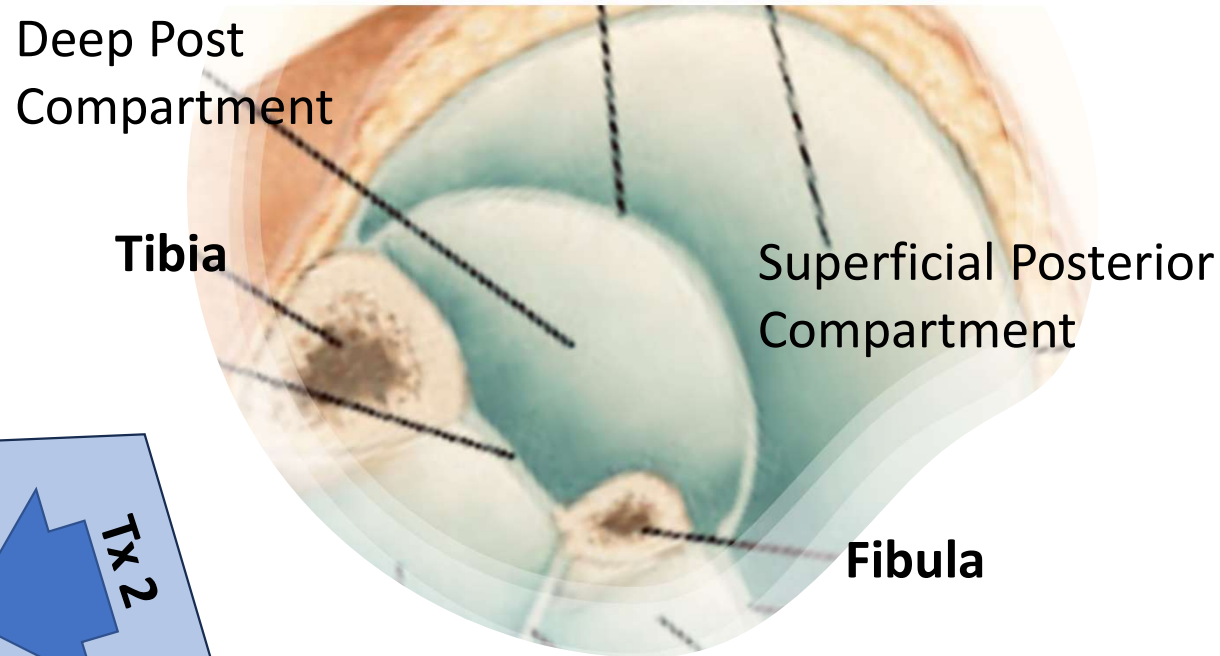
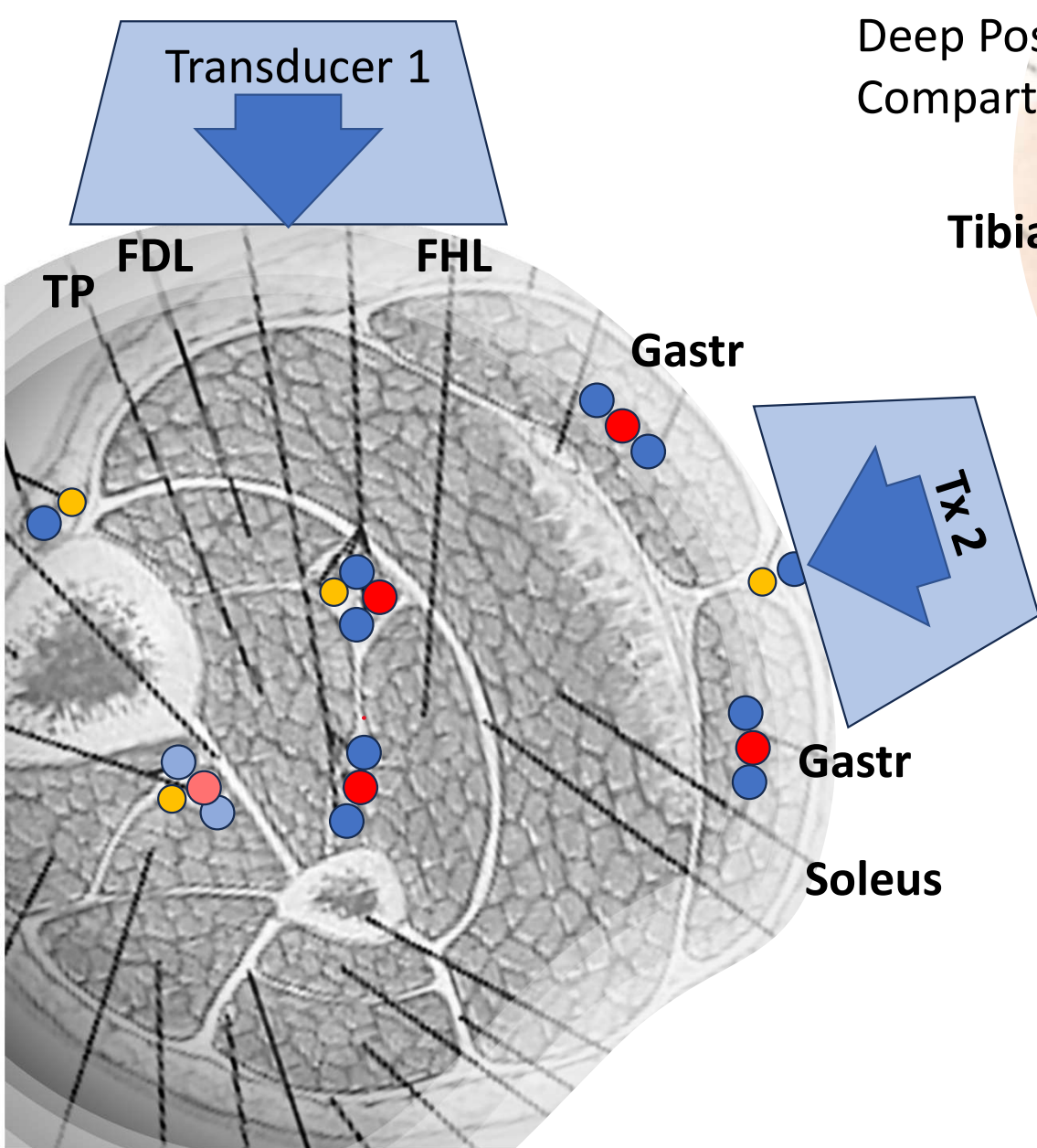
<<< Short Saphenous

<<< Popliteal Veins

RIGHT POP

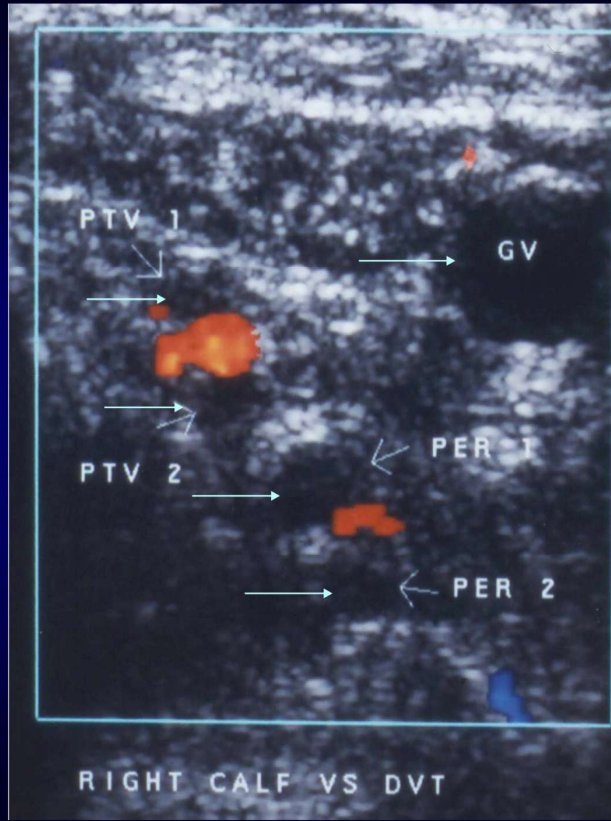
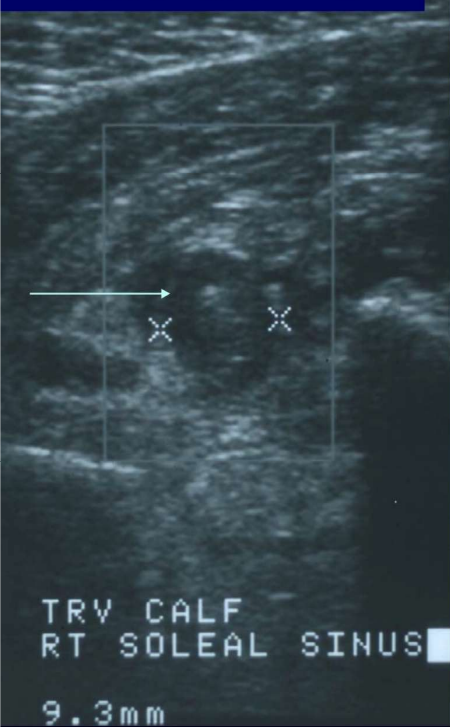
Right Popliteal DVT



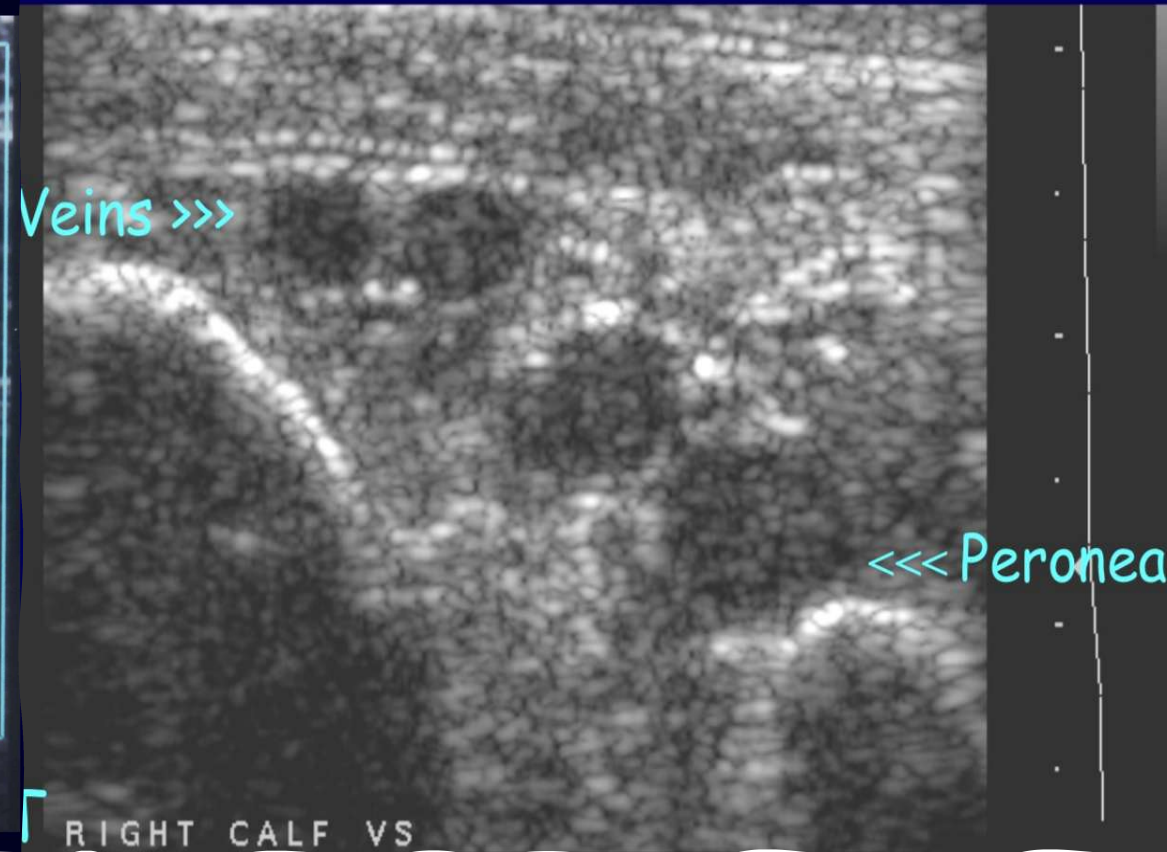


Effective Compression
of the Deep Posterior
Compartment

Calf DVT's



Veins >>>



Alternative Causes of Calf Swelling

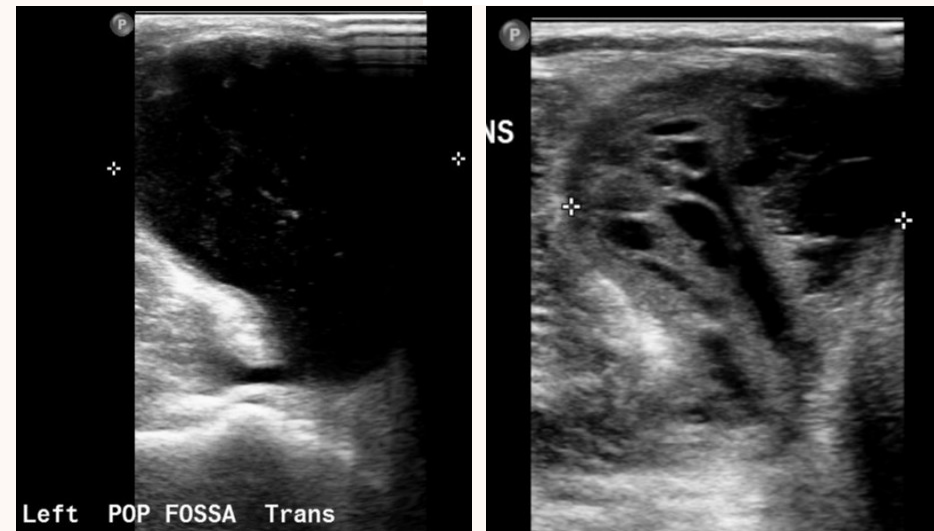
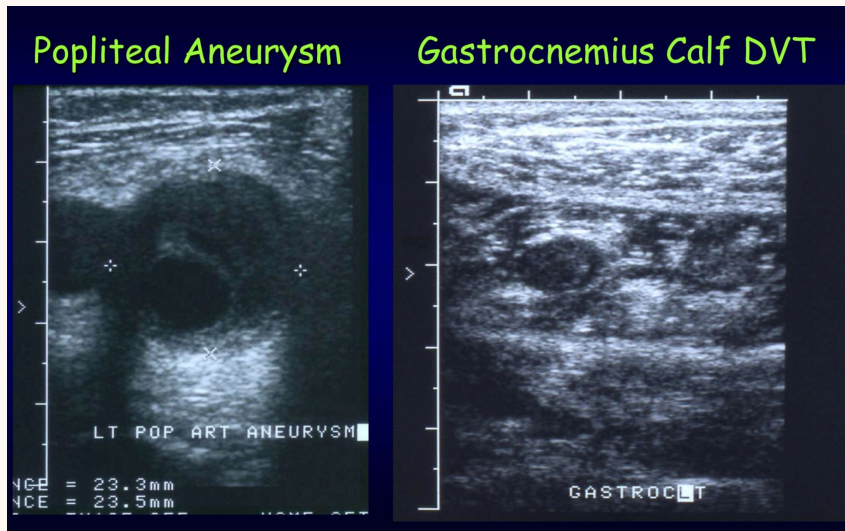
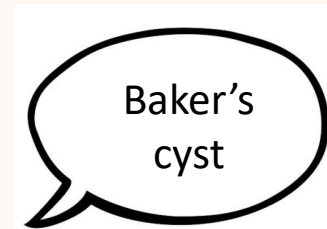
– FIRST think calf DVT !

Alternative Causes of Calf Swelling

Baker's cyst +/- haemorrhage

MSK injuries / Popliteal artery aneurysm

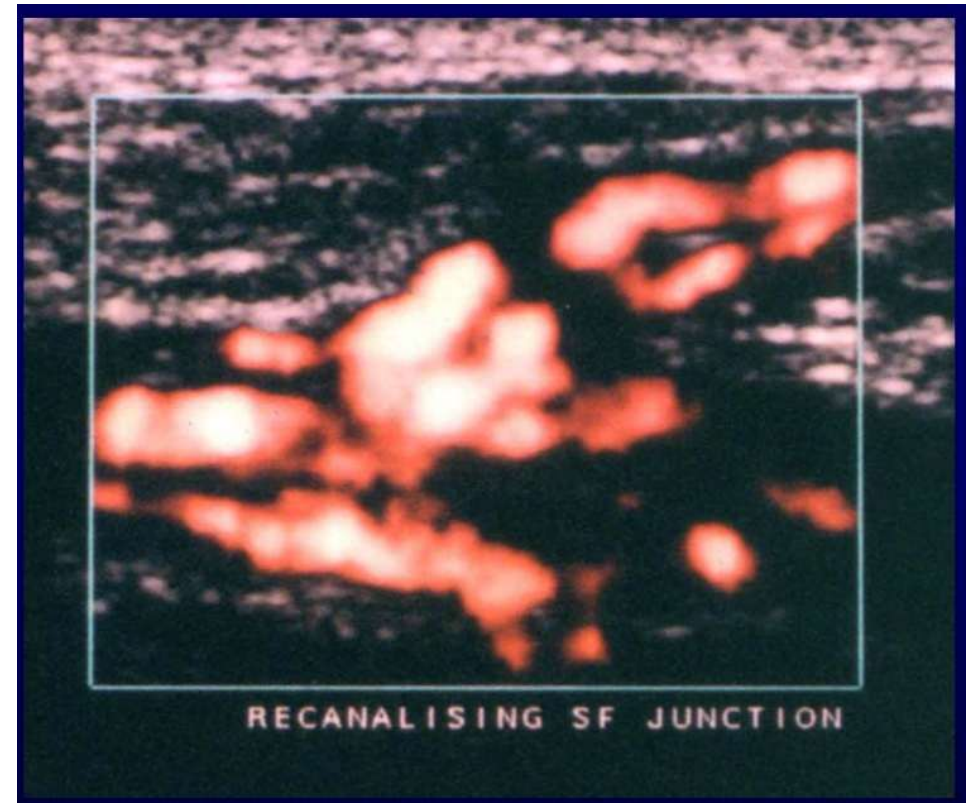
Muscular vein DVT / muscle tears



Pitfalls

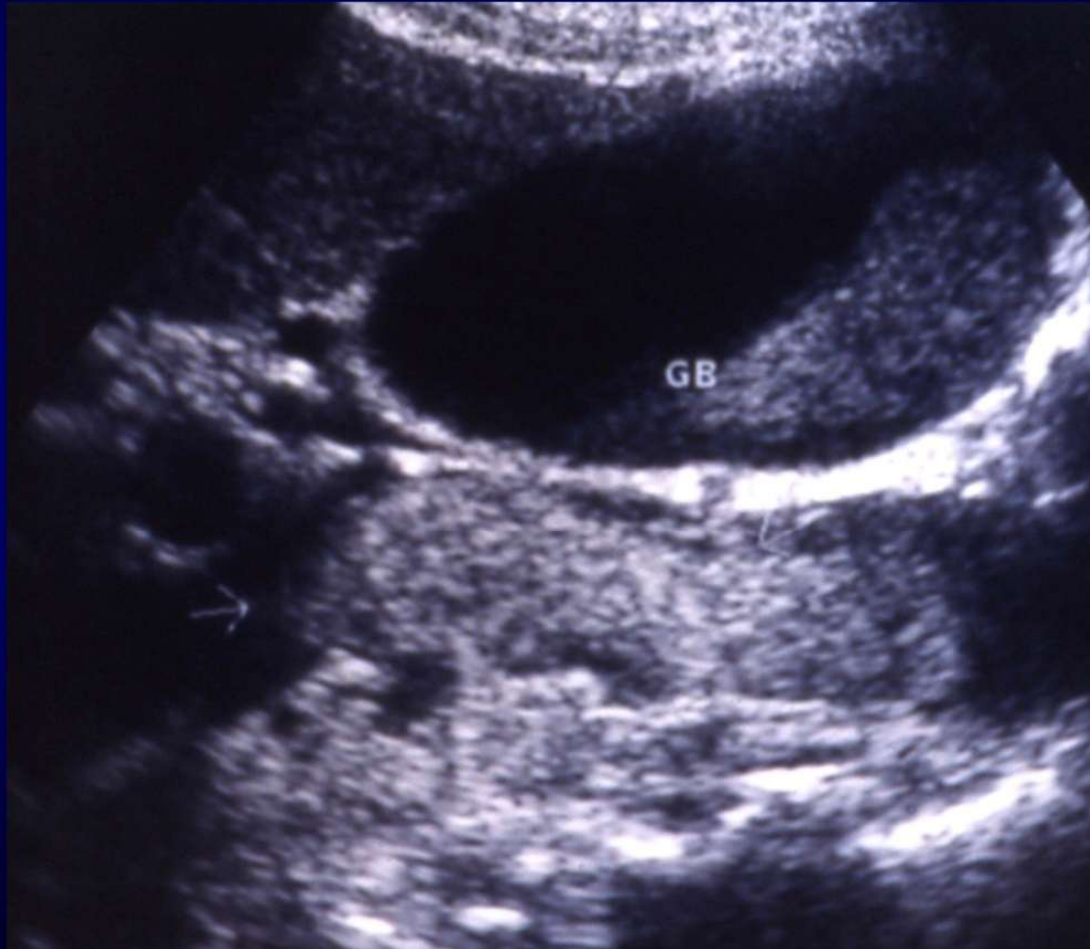
- H/O previous thrombosis
- H/O SFJ ligation (landmarks)
- Abdominal pathology ?
- Already a Pulmonary Embolus ?
- Oedema / Cellulitis
- Isolated thrombus
- Vein duplications
- Confusing Terminology - avoid 'SFV'
instead use FEMORAL vein

IVDU – beware pelvic thrombus

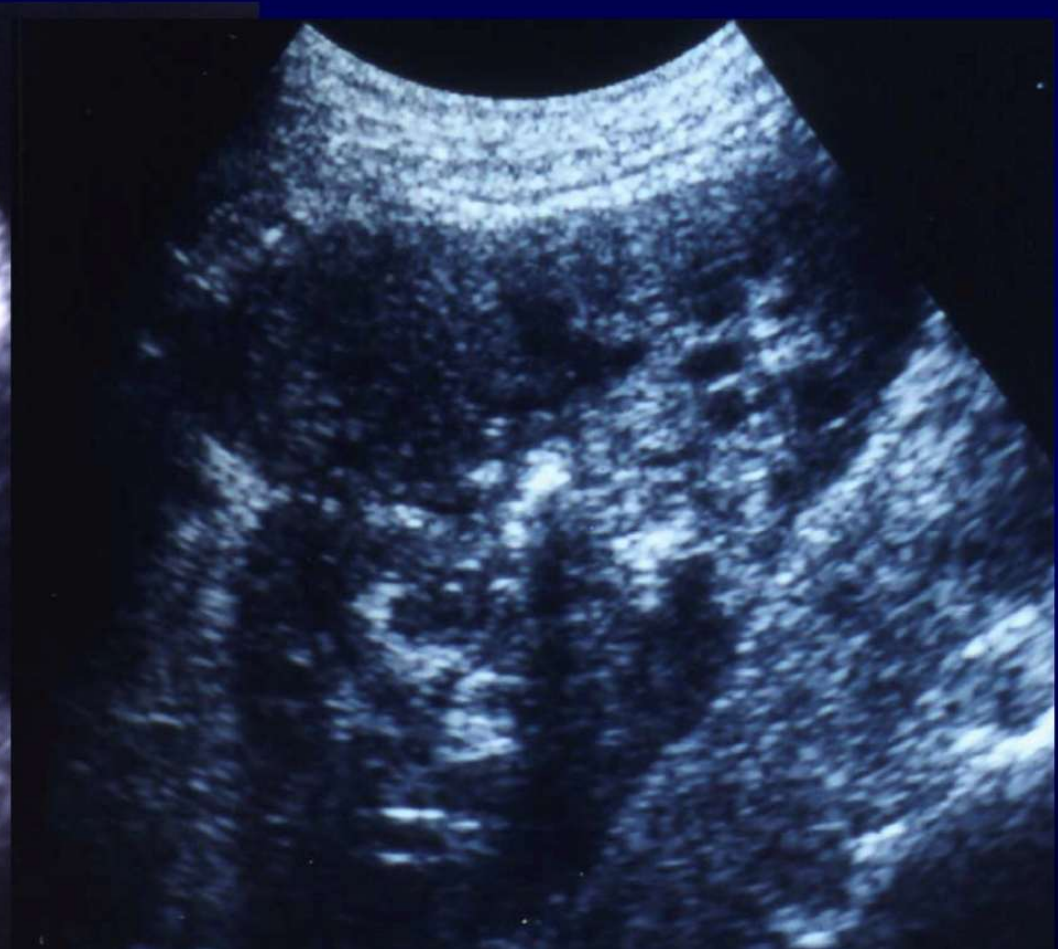

Consider abdominal pathology

Thrombus & Renal Tumour in IVC



Renal Cell Carcinoma



Two colorful parrots, likely Green-winged Macaws, are perched on a car dashboard. The parrot on the left is mostly green with a yellow patch on its neck. The parrot on the right is green with a prominent red patch on its forehead and a yellow patch on its neck. They are both looking towards the camera. The background shows a stone wall and some greenery.

Thank you for listening 😊

Thanks for additional images from Hazel Edwards and Simon Richards

Thank you to Rick Miles



GE HealthCare