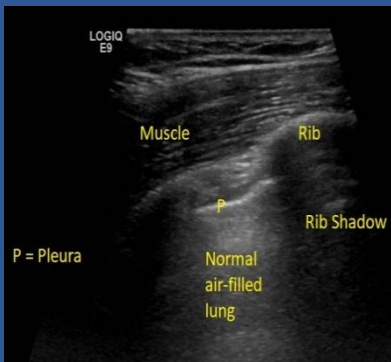

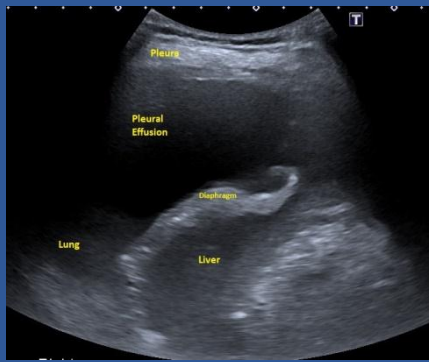
# Thoracic Ultrasound In Pictures

Catherine Payton, Ultrasound Lead  
Maidstone & Tunbridge Wells NHS Trust

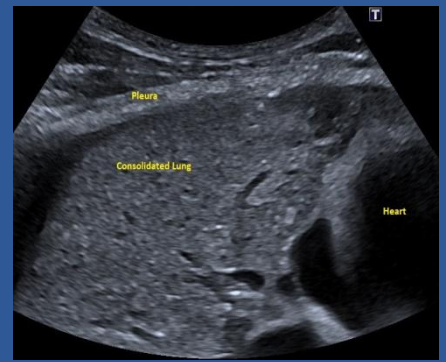
## Normal Pleura



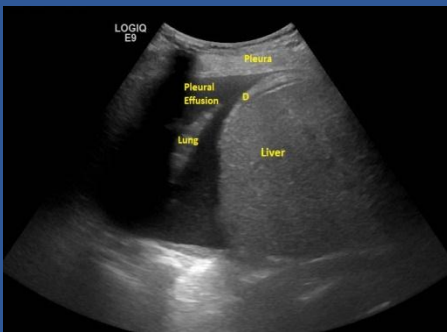## Pleural Thickening



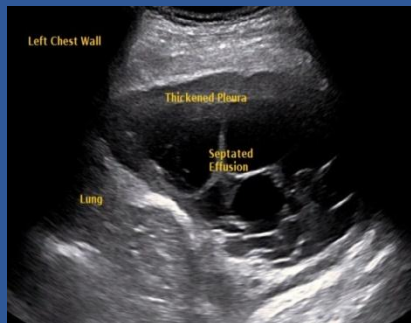
## Lung Consolidation



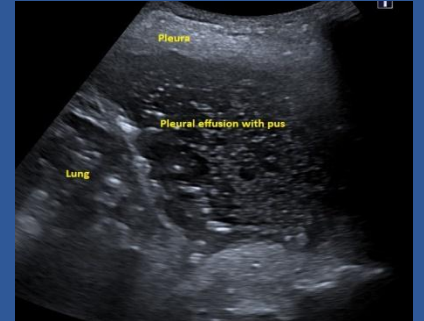
## Pleural effusion



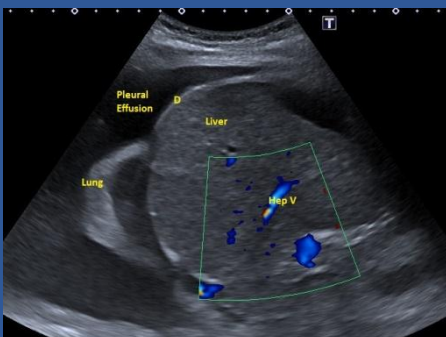## Loculated Effusion



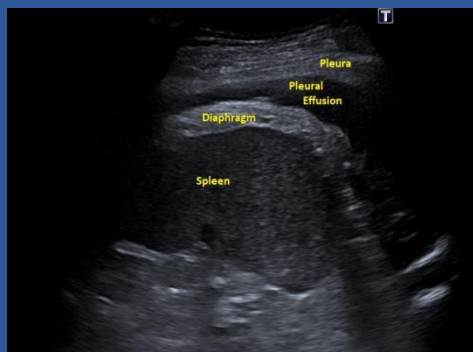## Effusion with Pus



## Normal Diaphragm



## Thick Diaphragm



## Empyema

