

In vivo validation of 3D transperineal ultrasound estimates of prostate motion during radiotherapy

Alex Grimwood¹, Helen McNair², Tuathan O'Shea², Jeffrey Bamber^{1,2}, Alison Tree² and Emma Harris¹

¹Department of Radiotherapy and Imaging, Institute of Cancer Research, Sutton, UK ²Radiotherapy Department, Royal Marsden NHS Foundation Trust, Sutton, UK

Introduction

The Elekta Clarity Autoscan® system (Elekta Ltd., Crawley UK) uses transperineal ultrasound (TPUS) imaging to monitor prostate motion. It is one of the few systems able to monitor motion during therapy. Prostate motion can result in geographical miss, even if patients are set up correctly immediately prior to irradiation [1,2]. Clarity Autoscan is a non-invasive method of potentially reducing geographical misses, improving outcomes in radiotherapy.

This study is the first *in vivo* validation of Autoscan in patients receiving intensity modulated radiotherapy (IMRT) for prostate cancer. The evaluation involved comparing Clarity-measured prostate motion during treatment (intrafraction) with prostate motion determined from clinically routine imaging and implanted fiducial markers.

The Elekta Clarity Autoscan® System

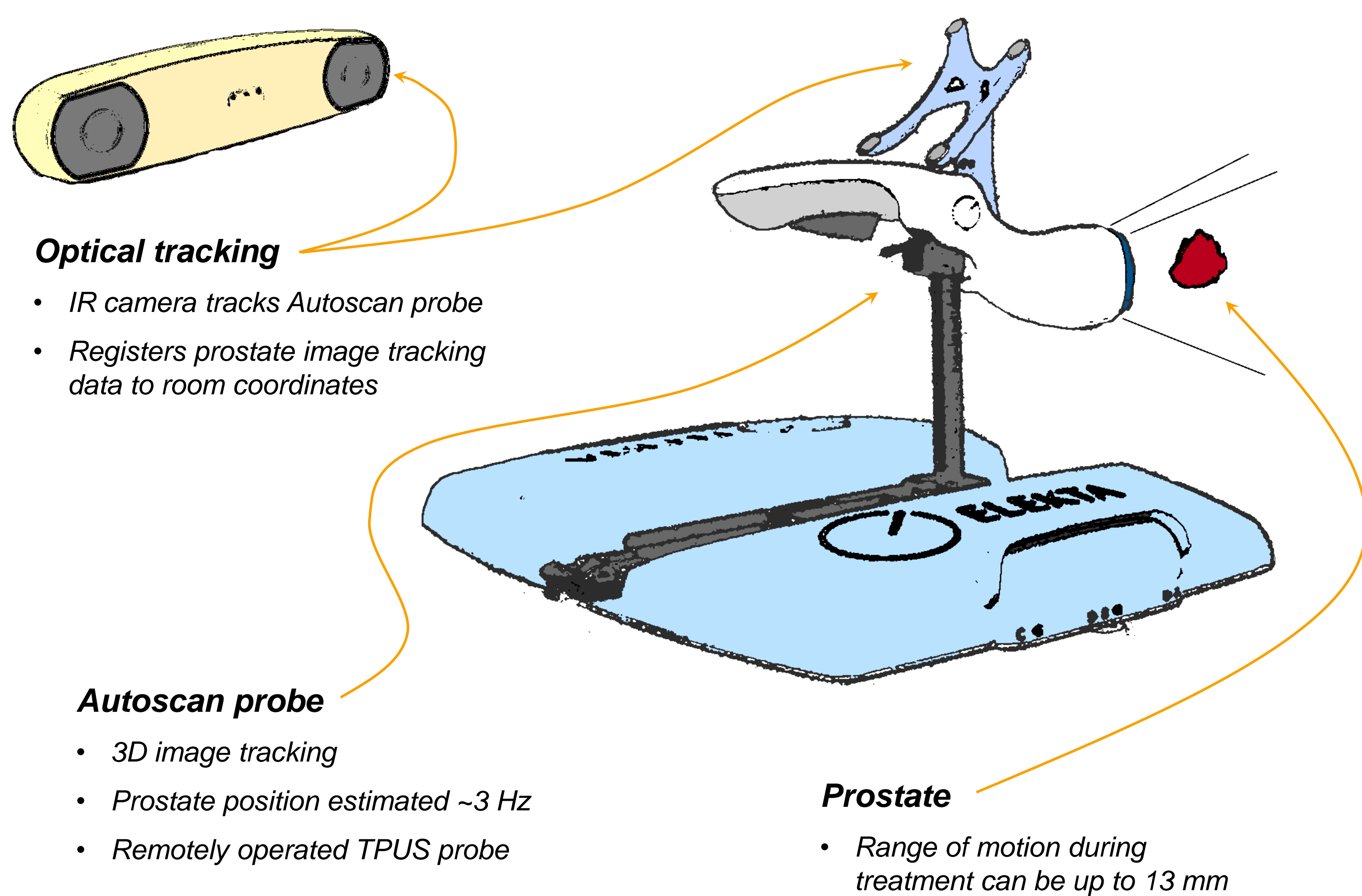


Figure 1. An illustration of the Clarity Autoscan System.

Validation Method

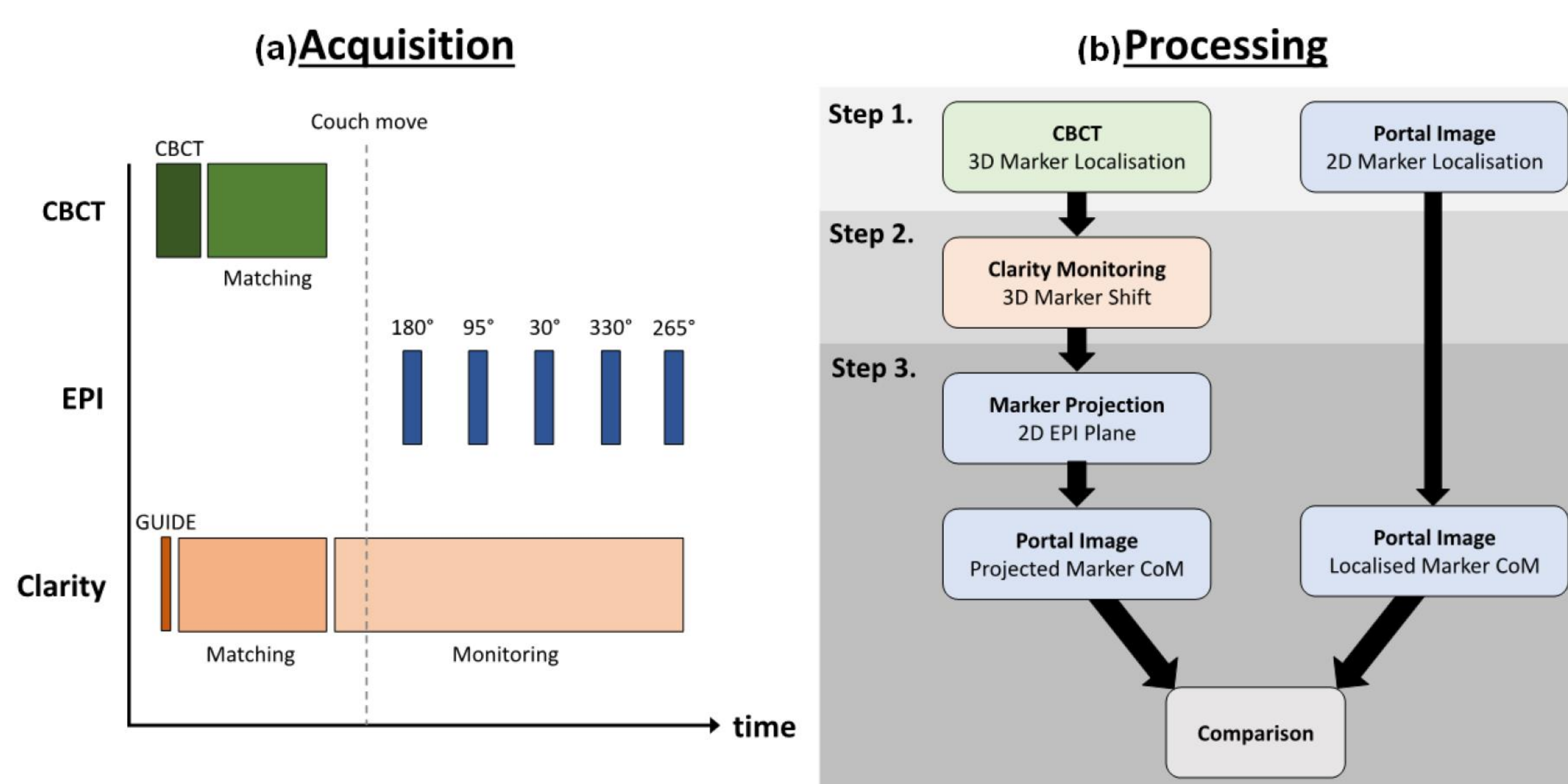


Figure 2. (a) Radiotherapy imaging workflow including Clarity for a 5 field IMRT fraction. (b) Image processing and validation steps: 1. Locate fiducial markers; 2. Estimate 3D marker position during treatment; 3. Project 3D position onto 2D EPI image plane and compare with actual position of imaged markers – difference between marker centres of mass (CoM).

Autoscan prostate motion estimation is validated against intraprostatic marker positions localised in electronic portal images (EPI) acquired during treatment (figure 2).

Initial 3D marker position is found in pre-treatment cone beam computed tomography scan (CBCT). Data is used to position patient before treatment (figure 2a).

Autoscan prostate monitoring is combined with CBCT marker localisations to estimate 3D position during treatment (figure 2b).

Estimated marker positions are projected onto 2D EPI images acquired during treatment.

For the validation, these estimates are compared to actual marker positions in EPIs (figure 3). Error, E , is the difference between Autoscan estimates and EPI localisations.

The Autoscan motion estimation algorithm also records a confidence factor, C .

The effect of ultrasound image quality and number of resolvable features within the prostate on C and E was studied (figure 4).

Results

Bland Altman plots in figure 3 show the error distributions. Median horizontal u -axis error (95% LOA) was 0.0 (-2.0 to 2.1) mm. Median v -axis error (95% LOA) was 0.1 (-2.5 to 1.9) mm. For both the u - and v -axes, median absolute error was 0.6 mm. The median 2D error vector magnitude was 1.0 (2.6) mm. The table accompanying figure 3 shows 25%, 50%, 75% and 95% limits of agreement (LOA).

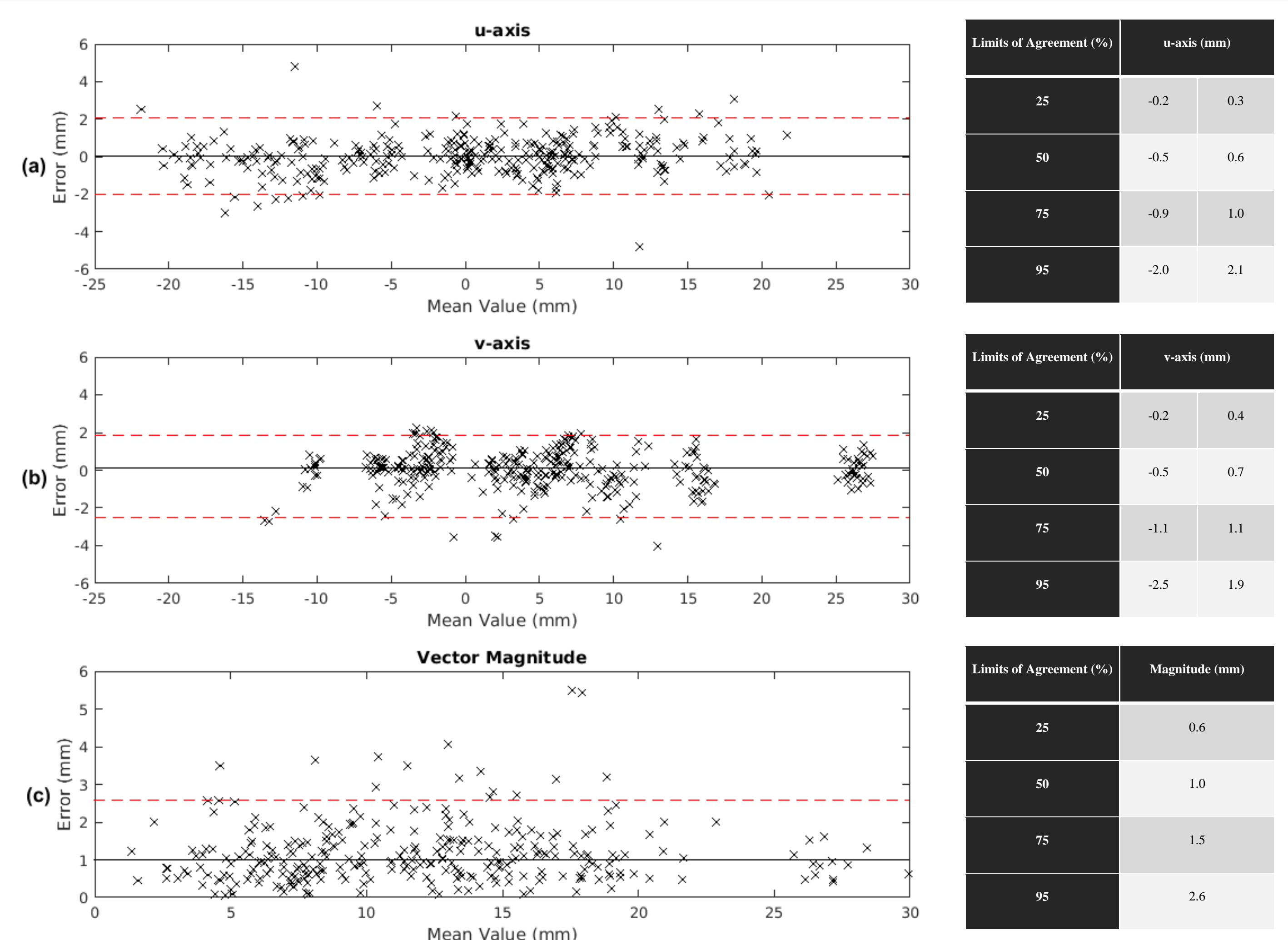


Figure 3. Bland Altman plots of difference between monitoring and EPI estimates of prostate position (Error), with accompanying tables of LOA: (a) in the portal image horizontal u -axis, with median (95% LOA) of 0 (-2.0 to 2.1) mm and (b) vertical v -axis, median 0.1 (-2.5 to 1.9) mm. (c) Bland Altman of the 2D error vector magnitude, median 1.0 (2.6) mm.

ANOVA tests of Autoscan performance across different categories indicated no statistically significant variation. The distributions of mean confidence factor, C_p , and Autoscan errors, E_p , by radiotherapy fraction are shown in figure 4.

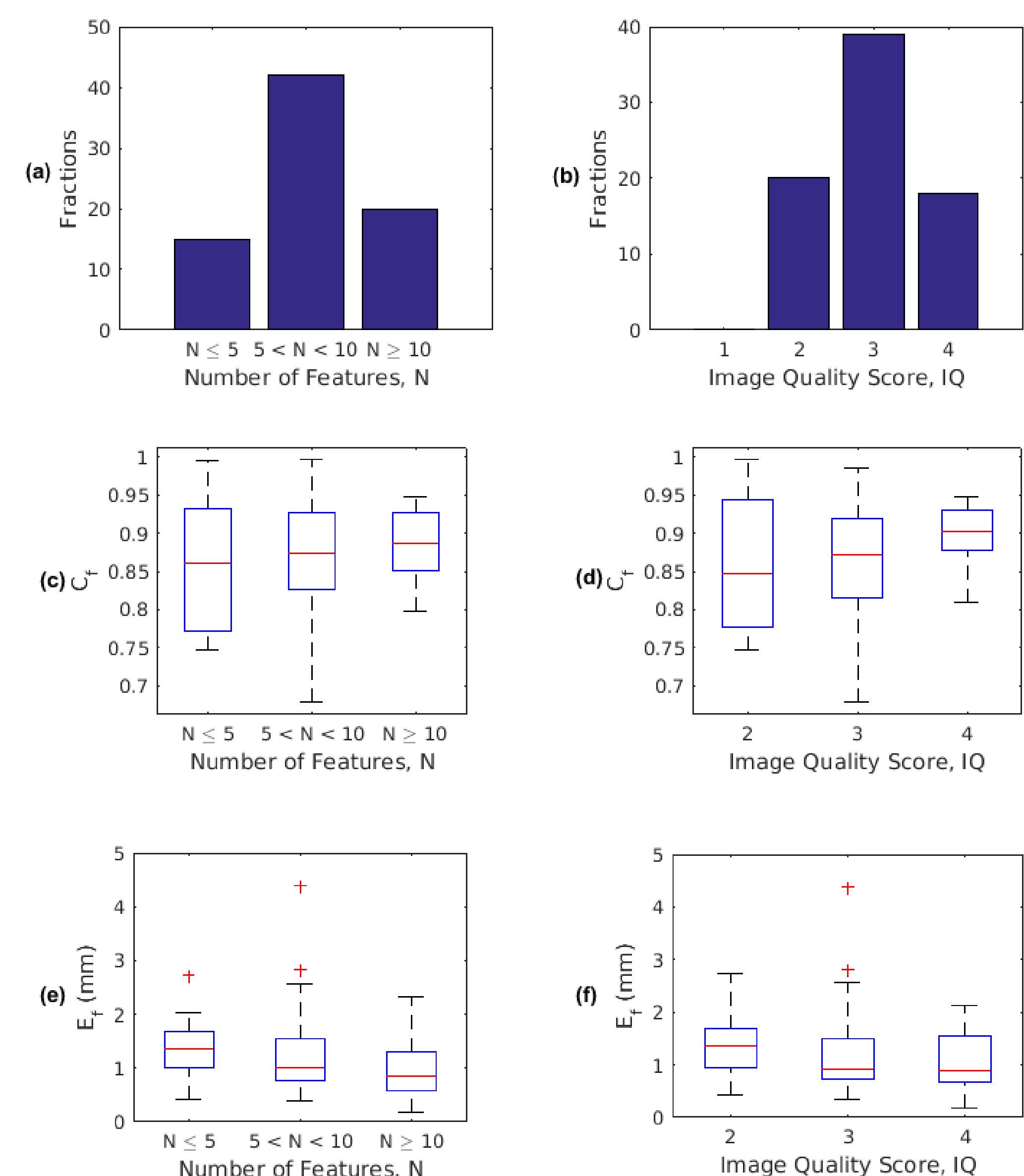


Figure 4. Histograms of fractions by feature frequency, N (a) and image quality, IQ as scored by 3 observers (b). Boxplots of mean Confidence factor, C_p , by N (c) and IQ (d). And mean difference, E_p , by N (e) and IQ (f).

Conclusions

Clarity is an accurate method of in-treatment prostate motion monitoring. Its performance is comparable to other motion monitoring systems [3-5]. No significant relationship between motion estimation confidence and image quality was observed.