

Sonographer Led One-Stop Neck Lump Clinic – 3 Year review

Nicki Davidson, Lead Sonographer.
Worcestershire Acute NHS Trust
nicola.davidson5@nhs.net



In 2018, a sonographer led one-stop neck lump was introduced in conjunction with the ENT team to improve the patient 2 week- wait pathway and provide quicker access to ultrasound and fine needle aspiration (FNA). A sonographer led ultrasound approach was developed due to lack of radiologist capacity and to ensure best use of resources. The clinic also incorporated histopathology support with an advanced biomedical scientist attending to review all samples and provide information to the sonographer on sample adequacy. The clinic has been embraced by the ENT team and has received positive feedback from patients who have seen the benefits of a 'one-stop' approach with consultations, imaging and tests all done in one appointment.

The objective of the audit was to provide an overview of the service and to identify any further areas of development

Methods:

A retrospective review was performed, of all patients who attended the one-stop neck lump clinic within the 3 year period. CRIS and ICE records were used to obtain details of the scan type, any pathology identified, who performed the scan and whether FNA was performed. Histology of all FNAs was reviewed to form part of the final diagnosis and provide results on adequacy. Each 12 month period was reviewed and compared, special consideration was made to see if the service had been affected by COVID-19 pandemic.

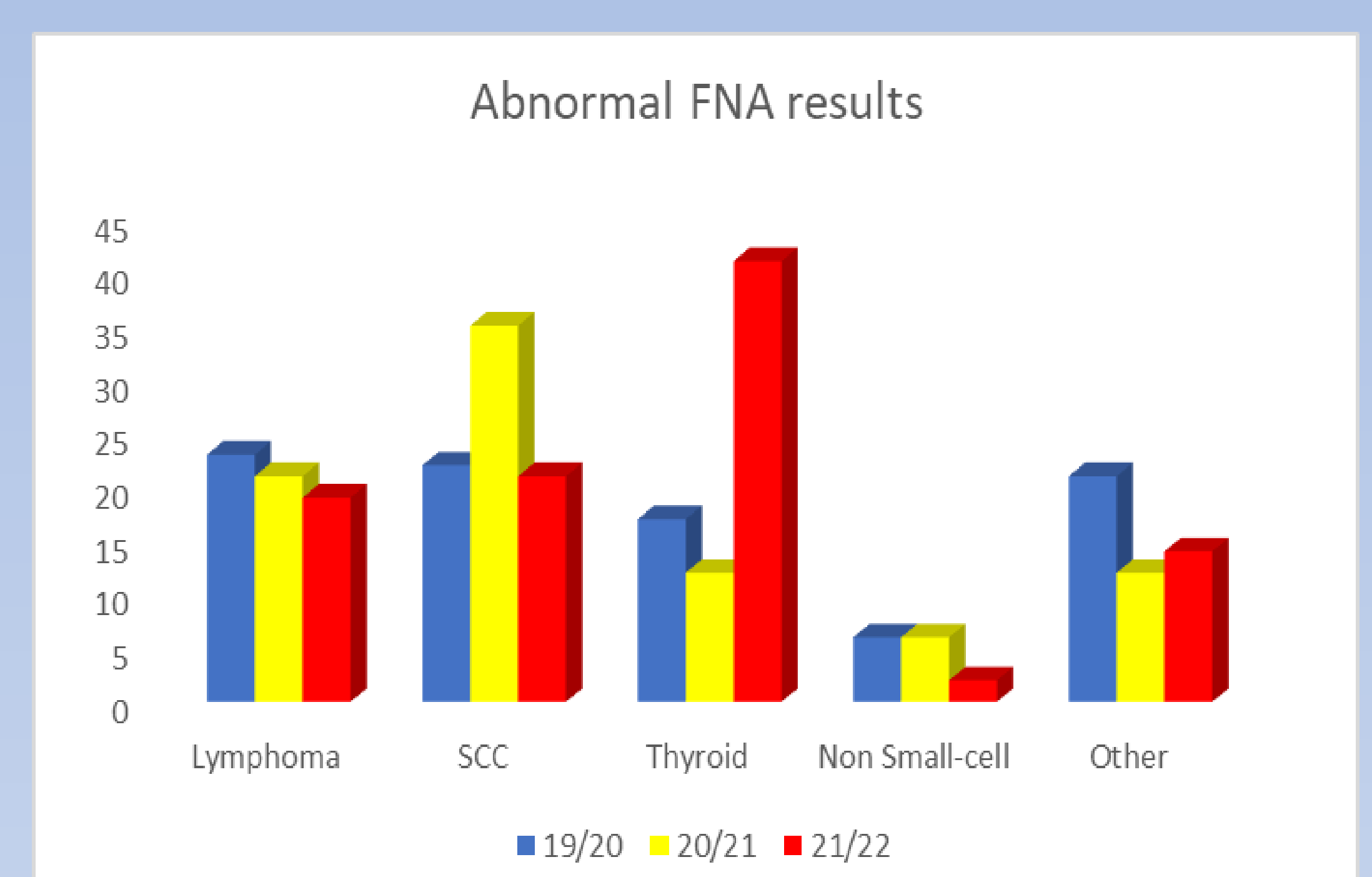
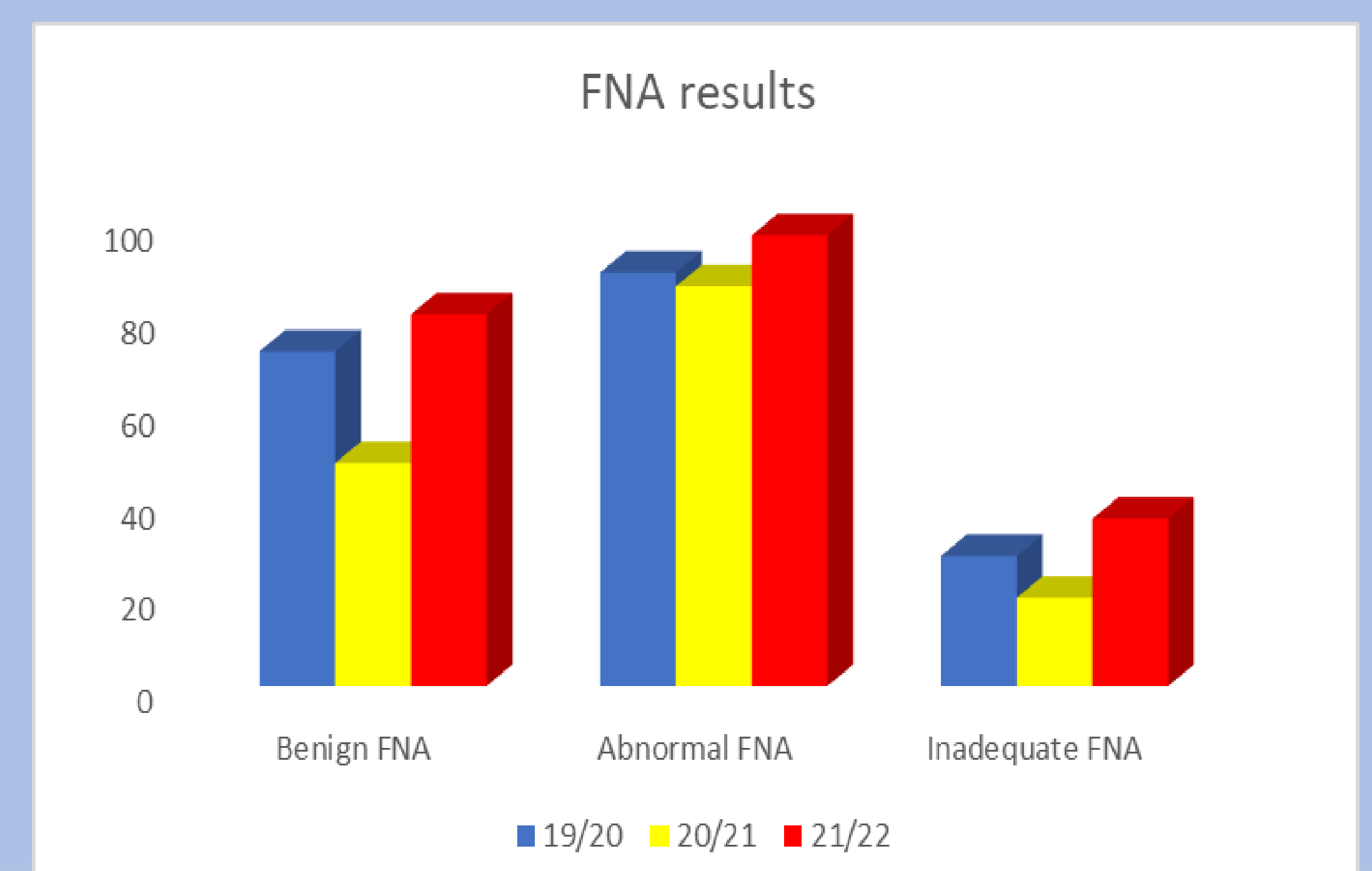
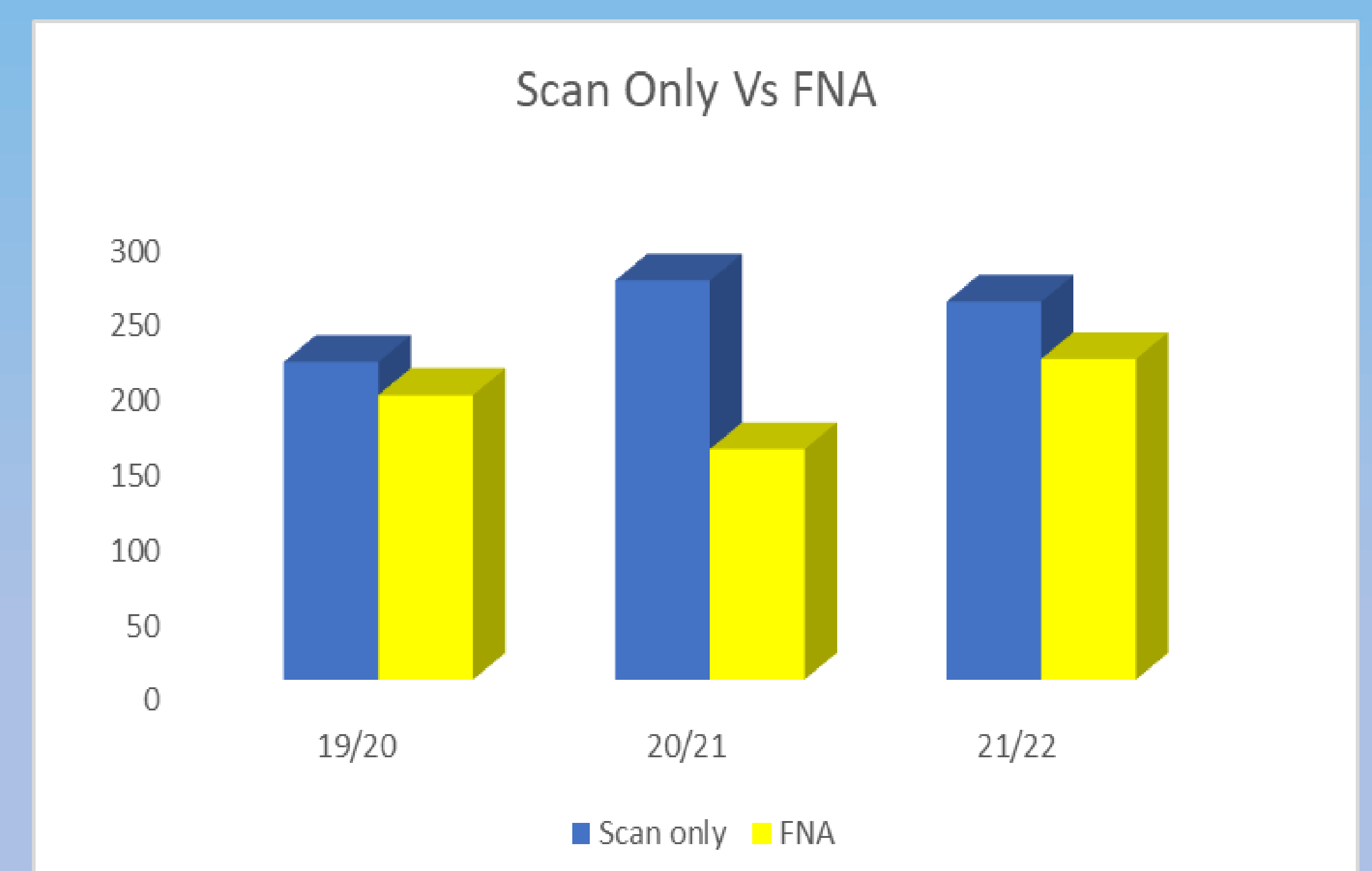
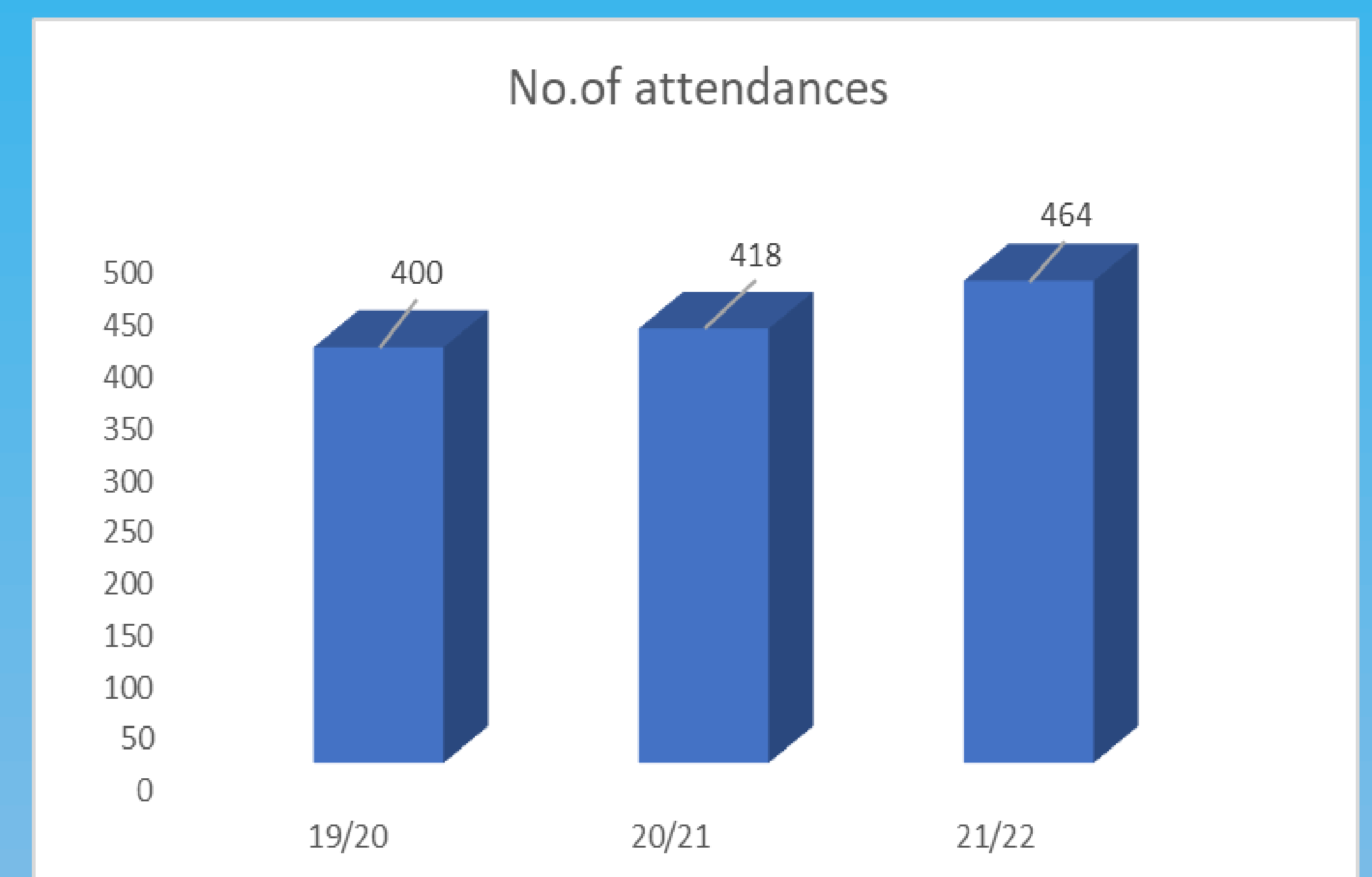
Results:

Numbers attending the clinic over the 3 year period have increased showing no impact during covid lockdown – numbers actually increased gradually although on detailed breakdown there was an initial reduction during the first 2 weeks of lockdown before numbers increased to normal levels. Clinics averaged at just over 8 patients per session with a minimum of 2 and maximum of 13 seen.

Consistently there has been a larger proportion of patients with benign ultrasound appearances than those requiring FNA, this enables immediate discharge and releases future ENT appointments.

The number of patients attending who have abnormal FNA results represents around 20% of all patient seen in the clinic each year, which shows the clinic is being booked appropriately and the referral pathway is well established.

Inadequate / insufficient FNA's has remained between 12 and 18% which meets the adequacy criteria set by the Royal College of Radiologists requiring 70% of all specimens to be considered adequate on cytology assessment.



FNA –BENIGN RESULTS
(Reactive nodes, Thyroid - Thy2, Sialadenitis, Warthins, Pleomorphic Adenoma, Branchial Cyst)

FNA – ABNORMAL
(Thyroid Thy3+, Metastasis, Lymphoma, Carcinoma)

Conclusions :

There has been consistent and appropriate use of the clinic, with no obvious impact during the COVID-19 pandemic. Although there has been a variation in the types of abnormalities identified on FNA – the number of patients with abnormal findings has been constant at around 20% of all patients attending the clinic. The one-stop neck lump clinic has proved to be an appropriate setting for a sonographer- led service and is showing continued support from both radiology managers and the ENT team.