

# Ultrasound Appearances of Breast Implants for Cosmetic and Reconstructed Breasts.

L. R. Magilton Griffin (Clinical Specialist Advanced Practitioner in Breast Imaging) NHS University Hospitals of Liverpool Group

## History and Background

Since 1800 women have been trying to create their 'perfect' breast with the introduction of breast augmentation. There have been many types of breast enlargement recorded throughout history, including paraffin and Vaseline injections, or wool and glass ball insertions as some of the earliest materials used. Due to their less-than-desirable appearances and side effects, the development of the more commonly known silicone and saline implants were introduced, which are mainly what are still in use today.

Today implants are not only just for cosmetic enlargement but also to create symmetry and for post-surgical reconstruction. Within any breast unit, the assessment of patients containing breast implants is routine in daily workloads.

### Saline water filled

Filled with sterile saline water in a silicone shell, which can be inserted empty for a more discrete incision. These are more likely to fold and wrinkle with a higher risk of rupture compared to silicone.

If rupture the saline will be absorbed into the body without complication.



### Types of implants used today.



www.drbottinger.com

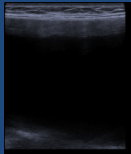
### Silicone gel filled

Most common form of breast implant used in the UK. Silicone filled in a silicone shell which leads to a more natural feeling and look with less wrinkles compared to the saline filled. If ruptured the silicone has the risk of causing lumps within the breast tissue and infiltrates the lymph nodes causing siliconomas.



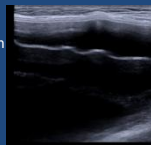
## Ultrasound Appearance of Intact Implants

### Standard single lumen implant



Smooth uninterrupted double contours of the implant capsule. Reverberations lines at the anterior aspect of the implant. Anechoic centre.

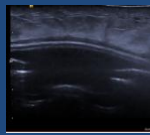
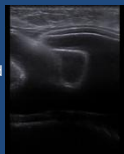
### Double lumen implant



Outer compartment of the double lumen implant (silicone filled). With double linear hyperechoic line of the anterior aspect of the implant (Implant capsule).

### Tissue expander with port

Partially expanded or not expanded expander contains lots of deep folds which can be missed interpreted as implant rupture or peri-implant fluid.

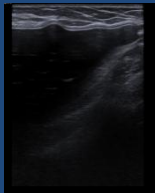



The expander port appears as a dip in the implant with multiple horizontal linear hyperechoic line starting at the implant capsule. The port is the entry site for which saline can be injected through to expand the implant and thus tissue to the desired size.

### Normal Variations

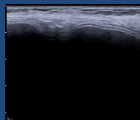
#### Previous Extracapsular Ruptures

Silicone seen within the tissue and well-defined hypoechoic lesion adjacent to the fibrous capsule. Contains snow-storm shadowing which can obscure implant capsule. The appearance can be confused with a rupture. Attaining previous history of rupture is vital in these situations.



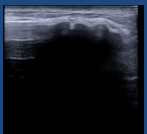
#### Reverberation Artefact Throughout

Multiple linear hyperechoic linear lines seen throughout this implant. In absent of any other rupture appearance can be normal. This can be mistaken as step-ladder sign.



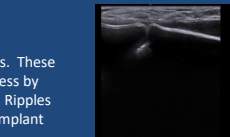
#### Capsular Calcifications

Hyperechoic edge to the capsule. Demonstrates posterior acoustic shadowing what can obscure the capsule. Can be multiple or singular.



#### Deep folds (radial folds) and ripples

Both occur in sub-glandular implants. These can mimic the step ladder sign. Assess by follow the fold through the implant. Ripples appear as bulges or bubbles in the implant capsule.



#### Post surgical seroma or effusion (Peri-implant fluid)

Layer of anechoic or hypoechoic fluid surrounding the anterior aspect of the implant. Seen between the implant capsule and the fibrous capsule. Can contain hyperechoic linear lines which indicates a septated seroma.

## Ruptured Implant Appearance

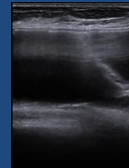
### Clinical signs

Change in shape, change in size, increase in pain, tenderness, firmness and swelling. The breast may also become softer or appear deflated.

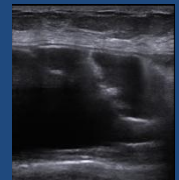
### Types of implant ruptures

Intra-capsular rupture which is where the implant shell ruptures but the rupture remains within the fibrous capsule.

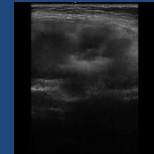
### Step-ladder sign



Series of horizontal hyperechoic lines.  
Straight linear of curvilinear.  
Parallel to the implant.  
Indicates intracapsular rupture.

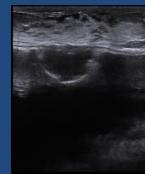


### Hyperechoic areas and snowstorm shadowing within the implant



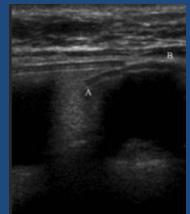
Occurs as a result of the tissue fluid mixing with the silicone gel within the implant.

### Breaks or separation of the implant capsule layers

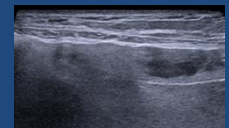
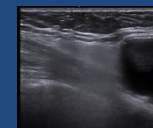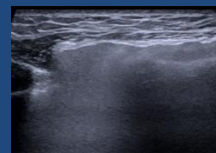


Complete break in the capsule.

The implant capsule layer becomes separated. Can appear as a bulge between the layers.



Extra-capsular rupture which is the rupture of both the implant shell and the fibrous capsule. The silicone gel escapes into the surrounding breast tissue.



Hyperechoic areas with snowstorm shadowing outside the implant capsule. Can appear oval in shape or diffuse.

## References

- Abbato, O. (2020) Meta-analysis of prepectoral implant-based breast reconstruction: guide to patient selection and current outcomes. *Breast cancer Res treat.* 213(5):543-554. Berg, W, Birdwell, R. (2006) *Diagnostic Imaging – Breast.* Amirsys. Birdwell, R. (2003) *Pocket Radiologist – Breast Top 100 Diagnosis.* Amirsys. Cardenas, G. (2017) *Breast Imaging Companion (4th ed.)* Wolters Kluwer. Dixon, A. (2008) *Breast Ultrasound – How, Why and Where.* Churchill Livingstone Elsevier. Dixon, M. (2006) *ABC of Breast Disease (3rd ed.)* Blackwell Publishing. Fisher, U., Baum, F., Luftner-Nagel, S. (2018) *Breast cancer: Diagnostic Imaging and Therapeutic Guidance.* Thieme. Jauwale, S., Schreer, L., Dershaw, D. (1997) *Diagnostic Breast Imaging – Mammography, Sonography, Magnetic Resonance Imaging and Interventional Procedures.* Thieme. Jaunpre, S., Perez, E., Huc, O., Motos, N., Pont, J., Pedraza, S. (2011) Imaging of breast implants – a pictorial review. *Insight Imaging* 2(6):653-670. Kim, J. (2022) *Atlas of Breast Implant – Ultrasound.* Springer. Kopans, D. (2007) *Breast Imaging (3rd ed.)* Lippincott Williams and Wilkins. Lake, E., Ahmed, S., Dobarshian, R. (2013) The Sonographic Appearances of Breast Implant Rupture. *Clinical Radiology* 26(6) 581-588. Santanelli di Pompeo, F., Padini, G., Firmani, G., Sacoto, M. (2022) History of breast implants: back to the future. *Sciencedirect* 3(2022) 166-177. Sencha, A. (2015) *Imaging of Male breast Cancer.* Springer. Stavros, T. (2004) *Breast Ultrasound* Lippincott Williams and Wilkins. Van Keulen, E., Fuchs, S., Hegeman, M., Smithuis, R. (2022) Breast Implants – Normal imaging and complications. *Radiology Assistant.* 2022.