

MEDICO LEGAL CASES

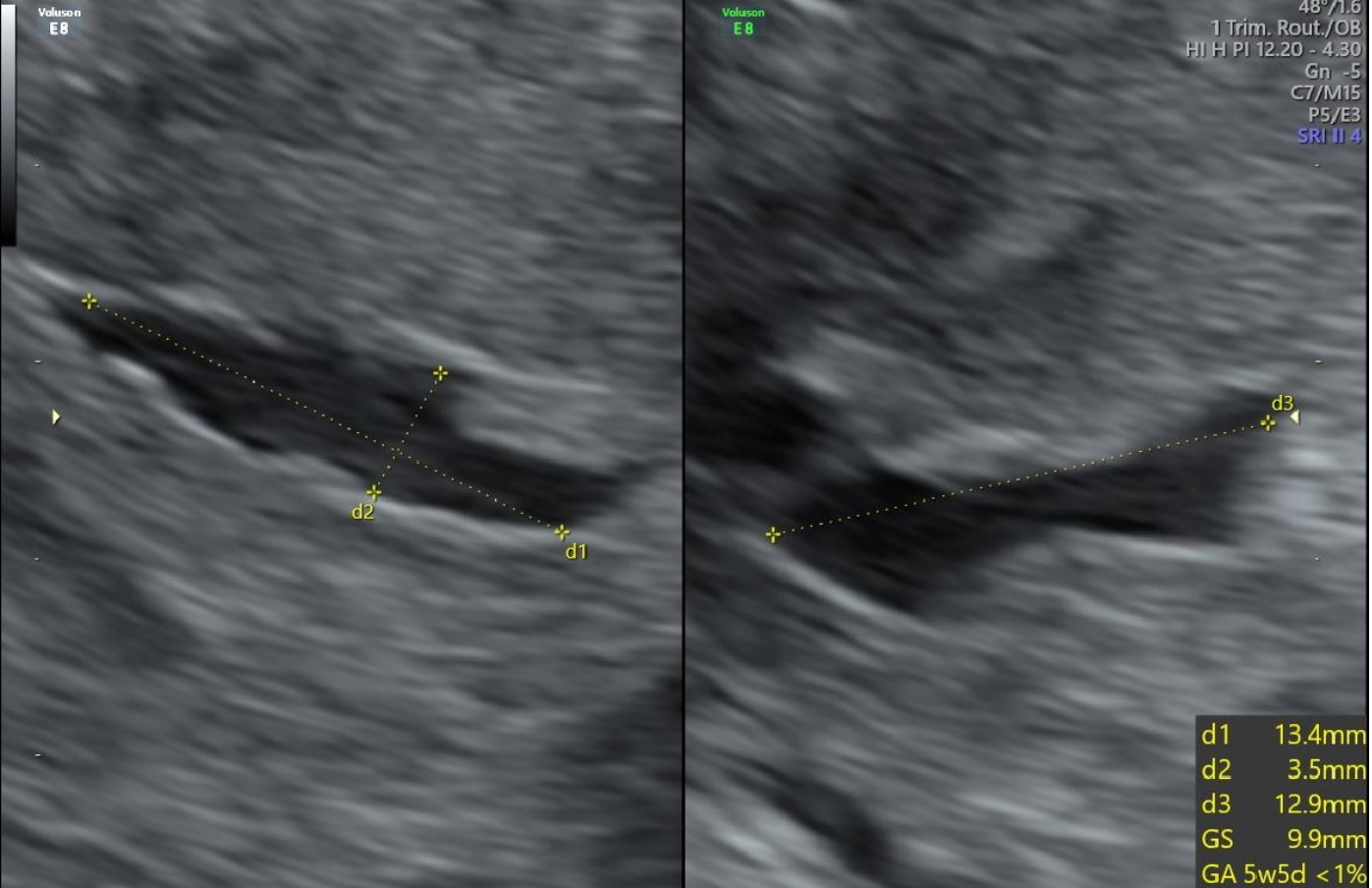
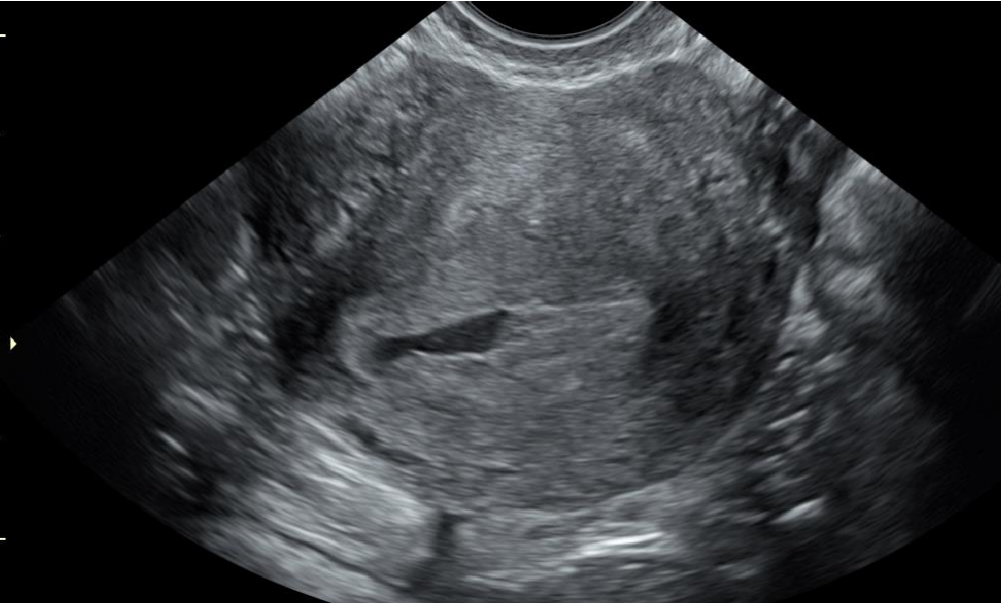EARLY PREGNANCY & GYNAECOLOGY

Helen French



Negligence is defined as the breach of duty caused by the omission to do something, which a professional with reasonable knowledge would do.

Early Pregnancy Referral



Private Scan Report

TA TV scan performed

LMP = 8w 1d

Anteverted uterus with and irregular gestation sac diameter of 9.9mm.

No fetal pole or yolk sac seen.

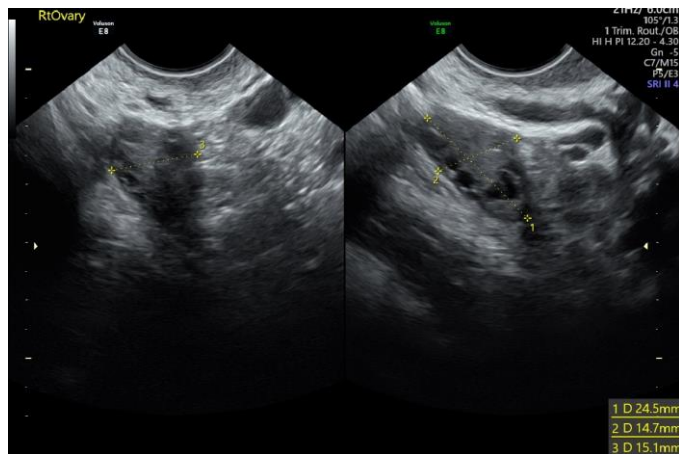
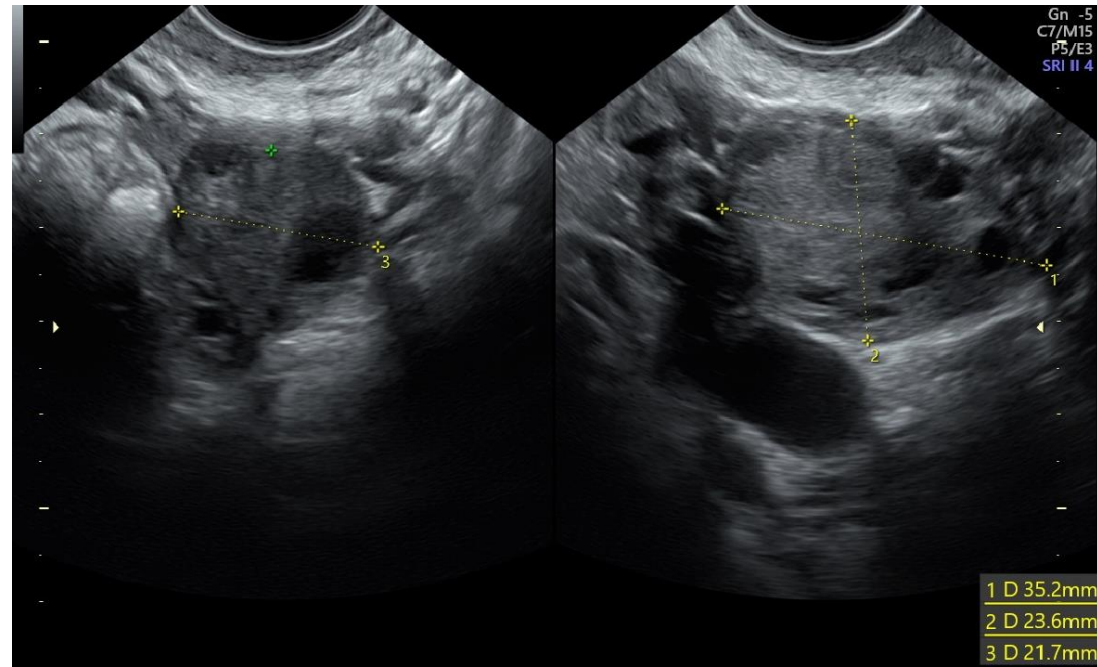
Due to the irregularities of the sac appearance are consistent with a missed miscarriage.

Suggest referral to EPAU.

Both ovaries appear normal in size and shape.

No free fluid in the POD.

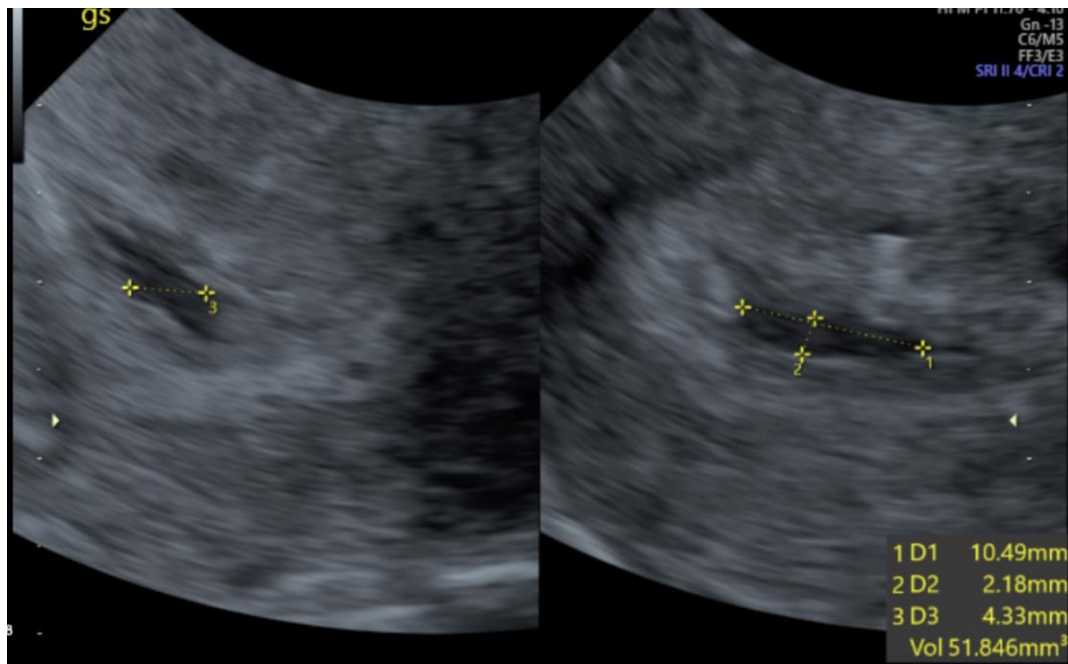
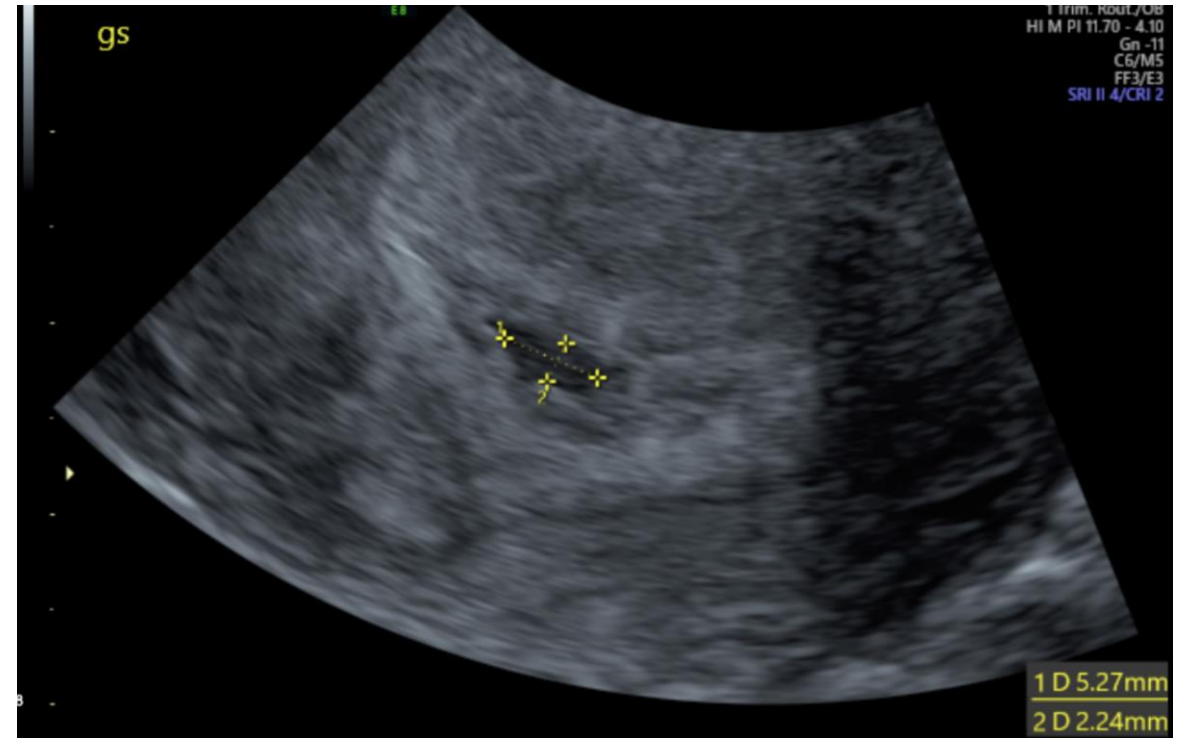
Which ovary?

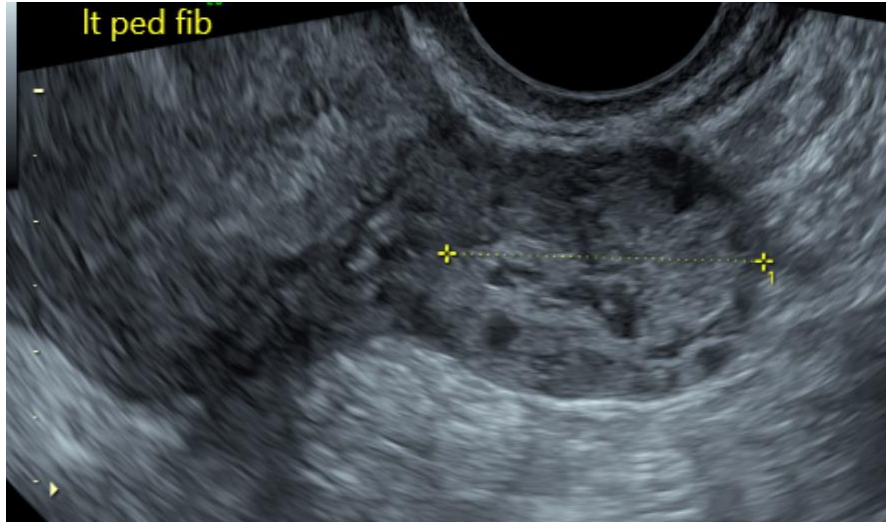
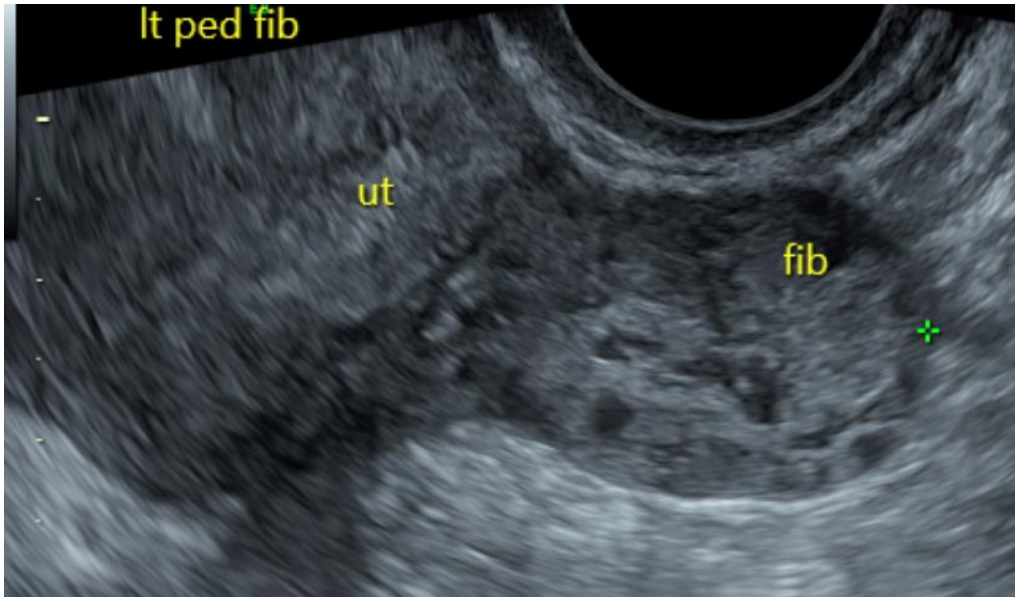
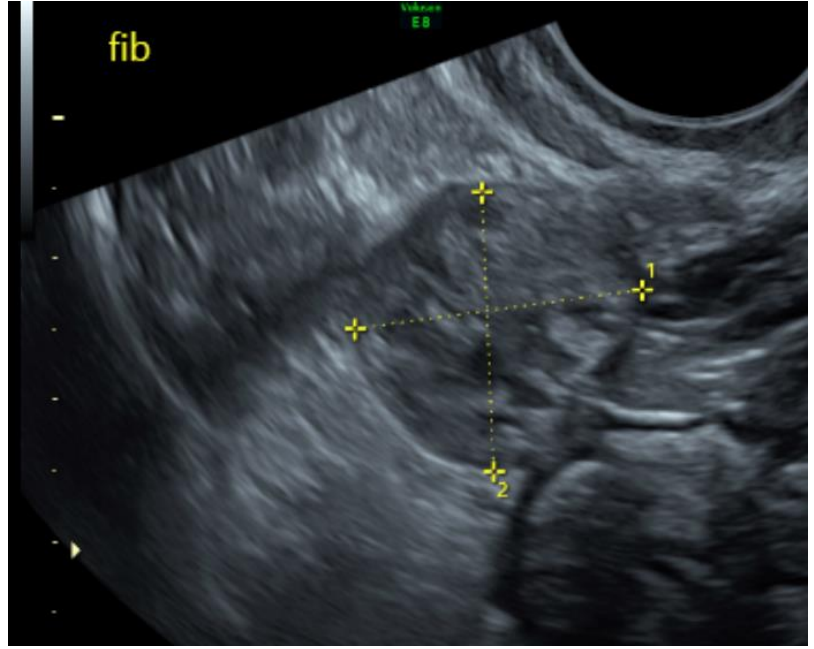
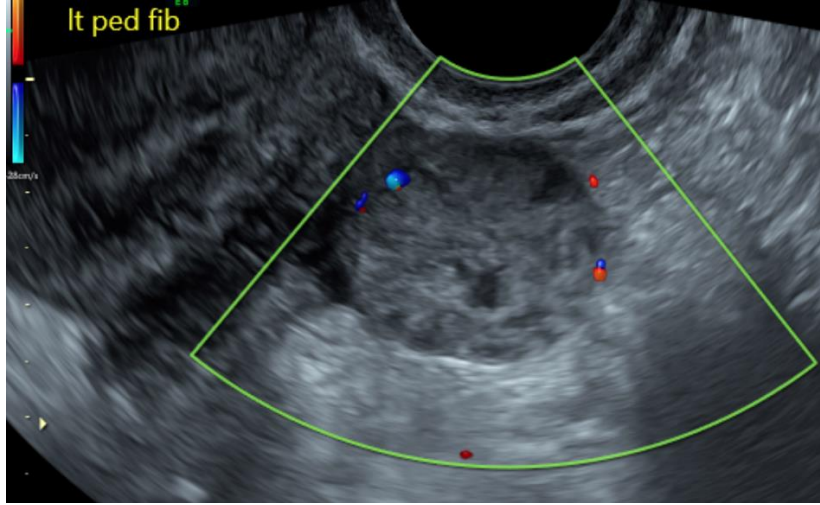


The right ovary

NHS scan

Clinical History: patient 8+1/40 according to LMP had scan privately due to some bleeding 2 weeks ago found to have abnormal looking gestation sac about 5+3/40 told need referral to EPU.






NHS Scan Report

- LMP 9+weeks
- Private scan reported as irregular gestation sac, no yolk sac or fetal pole seen
- Normal anteverted uterus. Posterior wall intramural fibroid seen measuring 10 x 7mm. There is a 25 x 30 x 20mm well defined heterogenous area adjacent and left lateral wall of the uterus. Appearances suggestive of left lateral pedunculated fibroid given the echotexture.
- Non tender on examination and no free fluid seen to suggest an ectopic. No vascularity seen. Of note: there was no mention of this on the private scan therefore unable to correlate.
- Irregular cystic area within the endometrial cavity measuring 17.2 x 4.7 x 17.3mm possible decidual reaction seen. Small echogenic focus seen within this measuring 3.5mm.

NHS Scan Report

Take home message
with Early Pregnancy.

**ASK THE PATIENT QUESTIONS
AND ASK FOR CORRELATION**



Reporting

Defending any case requires an accurate and thorough report to support the examination.

- Date of scan
- Consent
- Chaperone ?
- LMP
- +VE TEST
- Clinical Presentation / Reason for Scan
- Scans performed TA/TV

What to include in your report

Clinical indications

LMP

+VE TEST?

Scans performed TA/TV

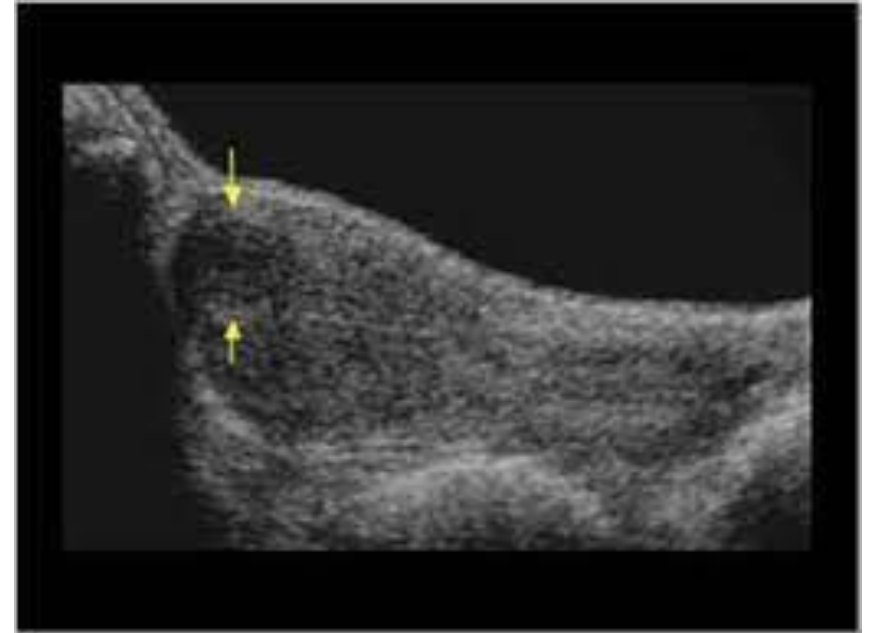
Considerations

- History of ectopic ?
- History of pain?
- IVF ?
- GS SAC ? Size & Appearance
- Is there a yolk sac
- Is there a fetal pole /cardiac activity
- Is LMP – reliably accurate for clinical correlation.
- BHCG?
- Consider heterotopic pregnancy

Gynaecology

37yr old Caucasian
MRI scan incidental finding
2cm lesion in the fundal uterus
for further evaluation with
Ultrasound.

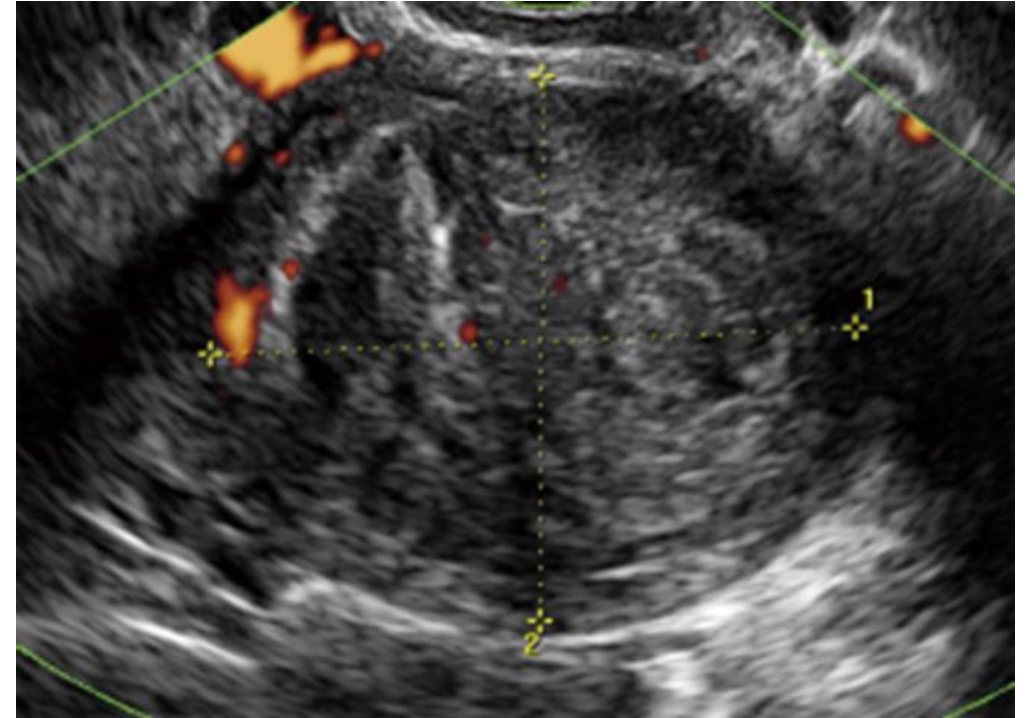
Conclusion:
Anterior, fundal intramural
fibroid.



Gynaecology

2yrs later
A&E attendance
sudden onset of
radiating dull pelvic
pain.

CT requested,
report: Uterus
distended and
findings were most
consistent with
degeneration of
known posterior
fibroid.



NHS Scan Report

Ultrasound
arranged...

Conclusion:
Degenerating
fibroid

