

Everything You Need To Know About Ectopic Pregnancy And Early Pregnancy

Dr Bill Smith
Consultant Ultrasound Specialist
Clinical Diagnostic Services, London



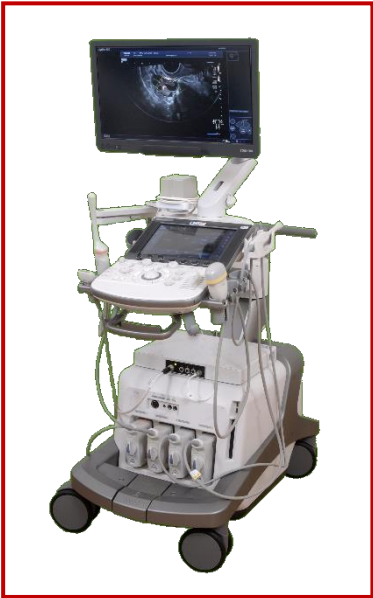Introduction To Ultrasound Scanning In Early Pregnancy. Investigation of Ectopic Pregnancy.

Bill Smith
Consultant Ultrasound Specialist
Clinical Diagnostic Services, London



Ultrasound Imaging In Early Pregnancy

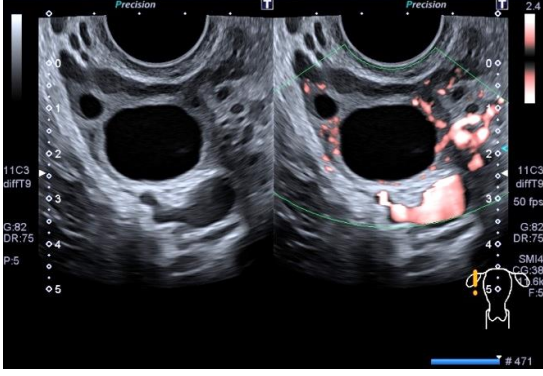
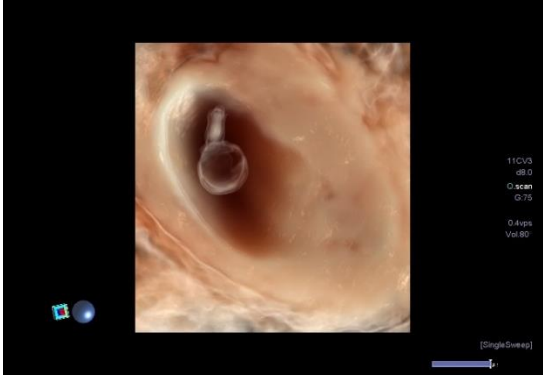
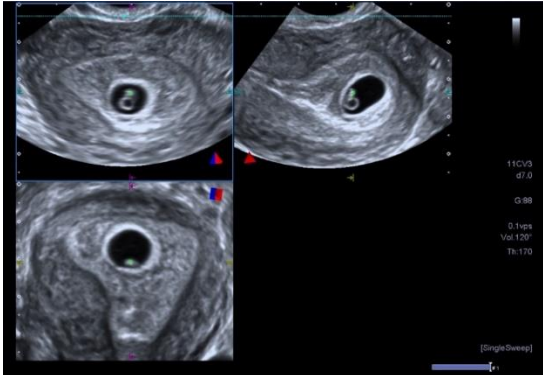
Impact of Advanced Technology




High Resolution
2D TVS Grey Scale

Advanced 3D
Technology

Colour Doppler Imaging
SMI

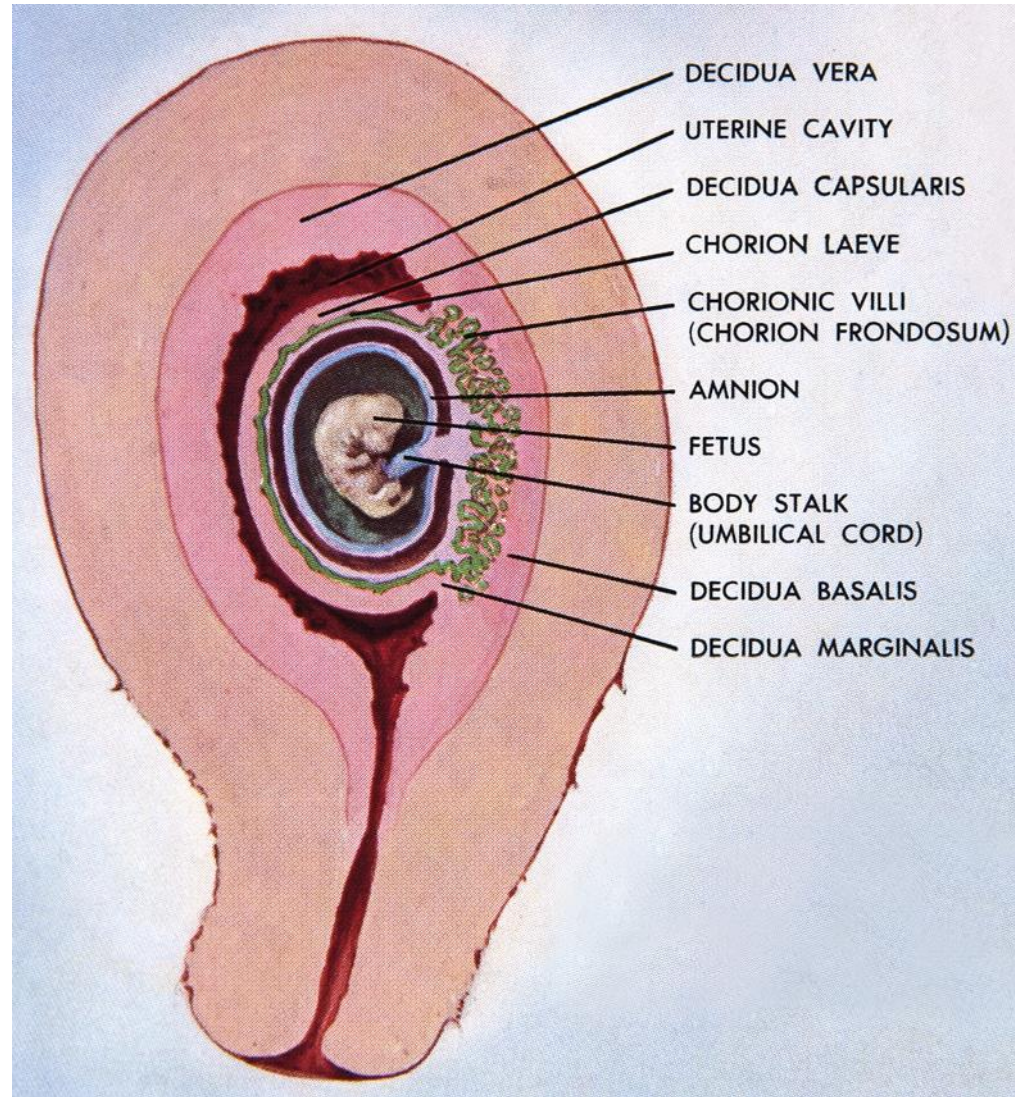


Ultrasound Imaging In Early Pregnancy



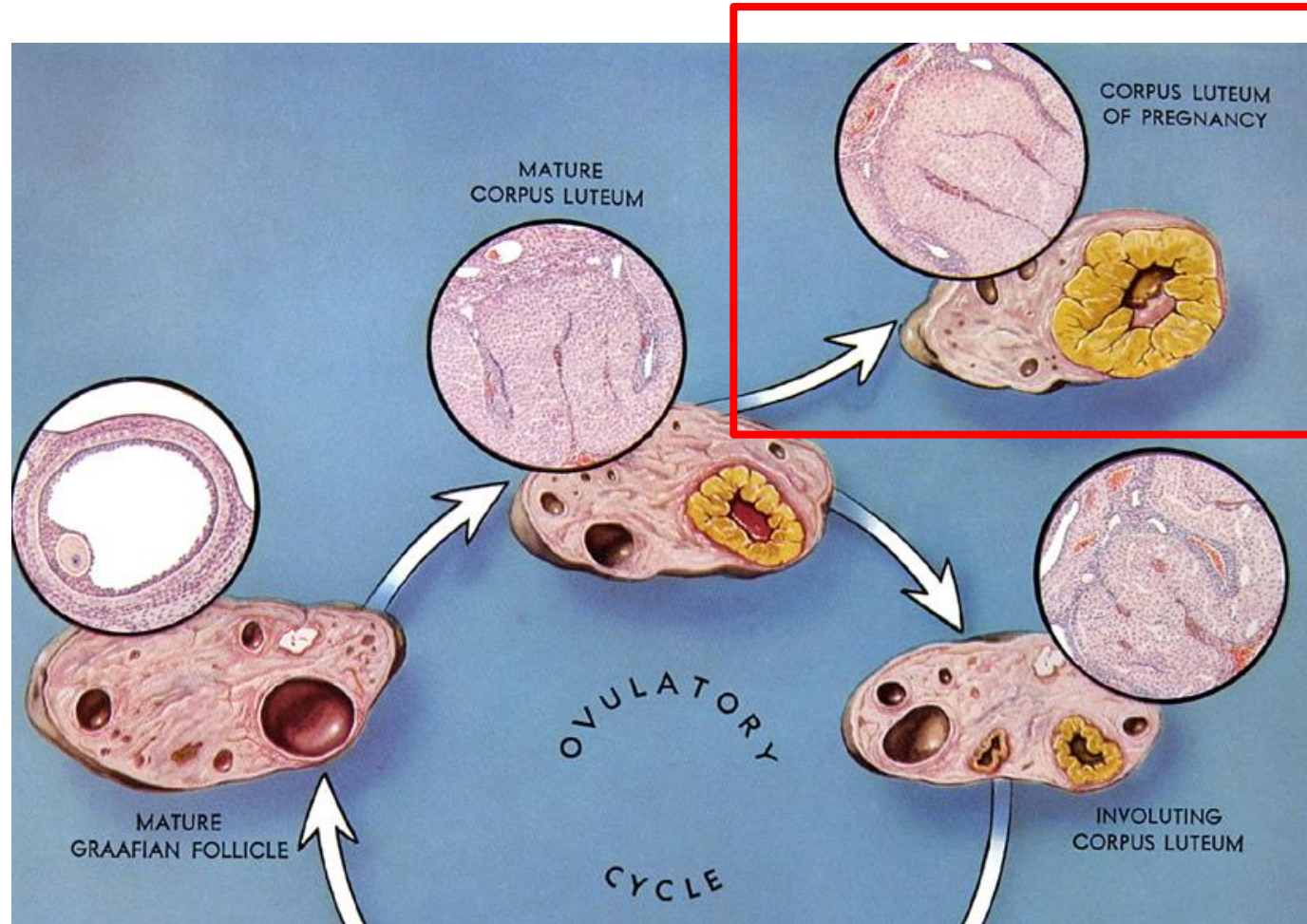
- Reduce scanning time
- Reduced exposure time
- Accurate assessment of pregnancy sac size, contents and implantation site
- Detailed assessment of trophoblastic and decidual responses
- More efficient storage of data
- Convenient playback facility

Ultrasound Assessment Of Early Pregnancy



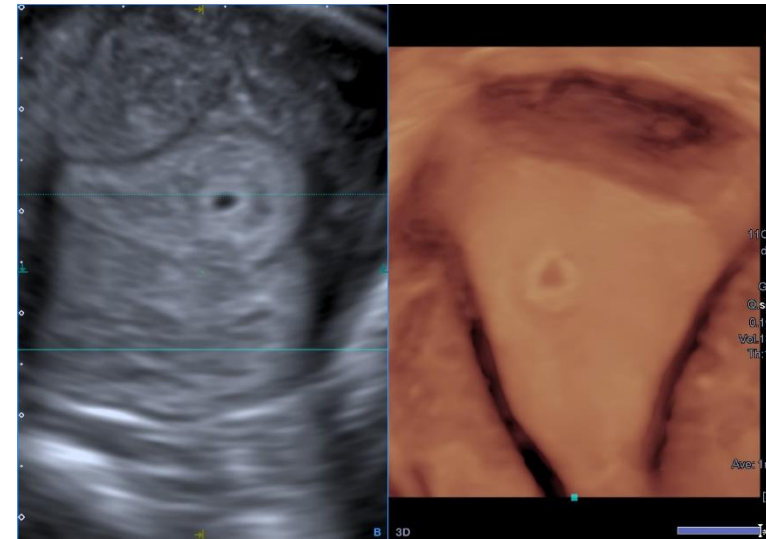
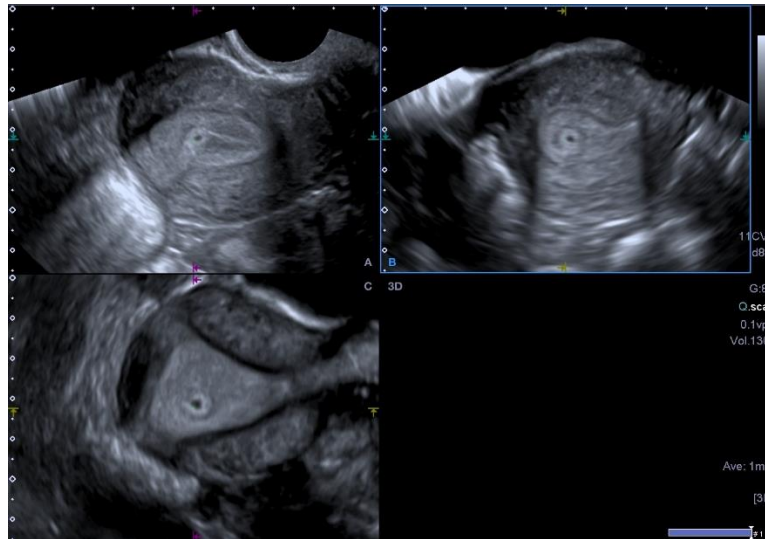
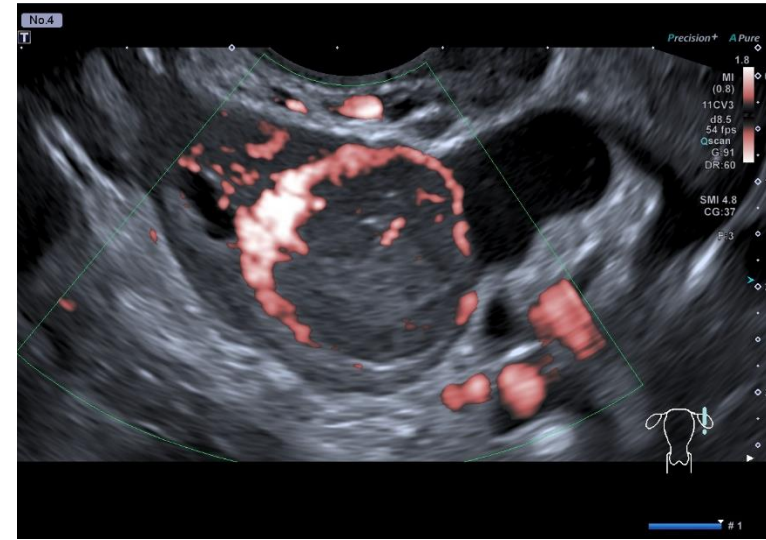
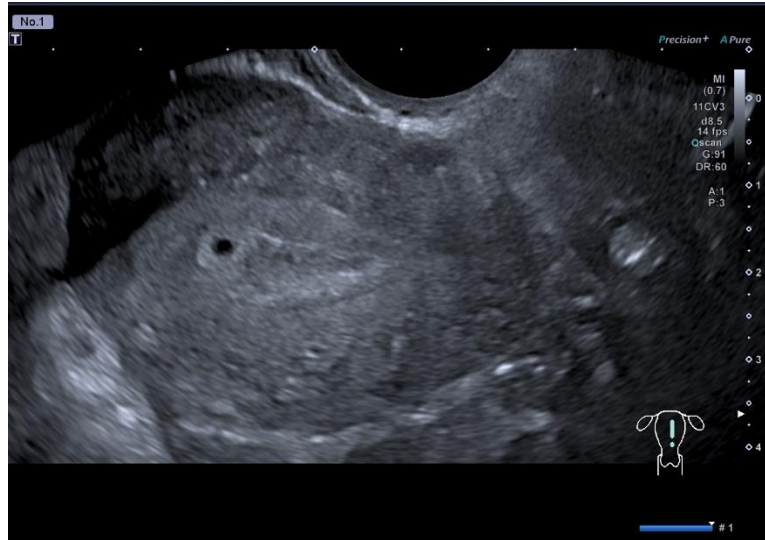
Prognostic Evaluation

Ultrasound Assessment Of Early Pregnancy



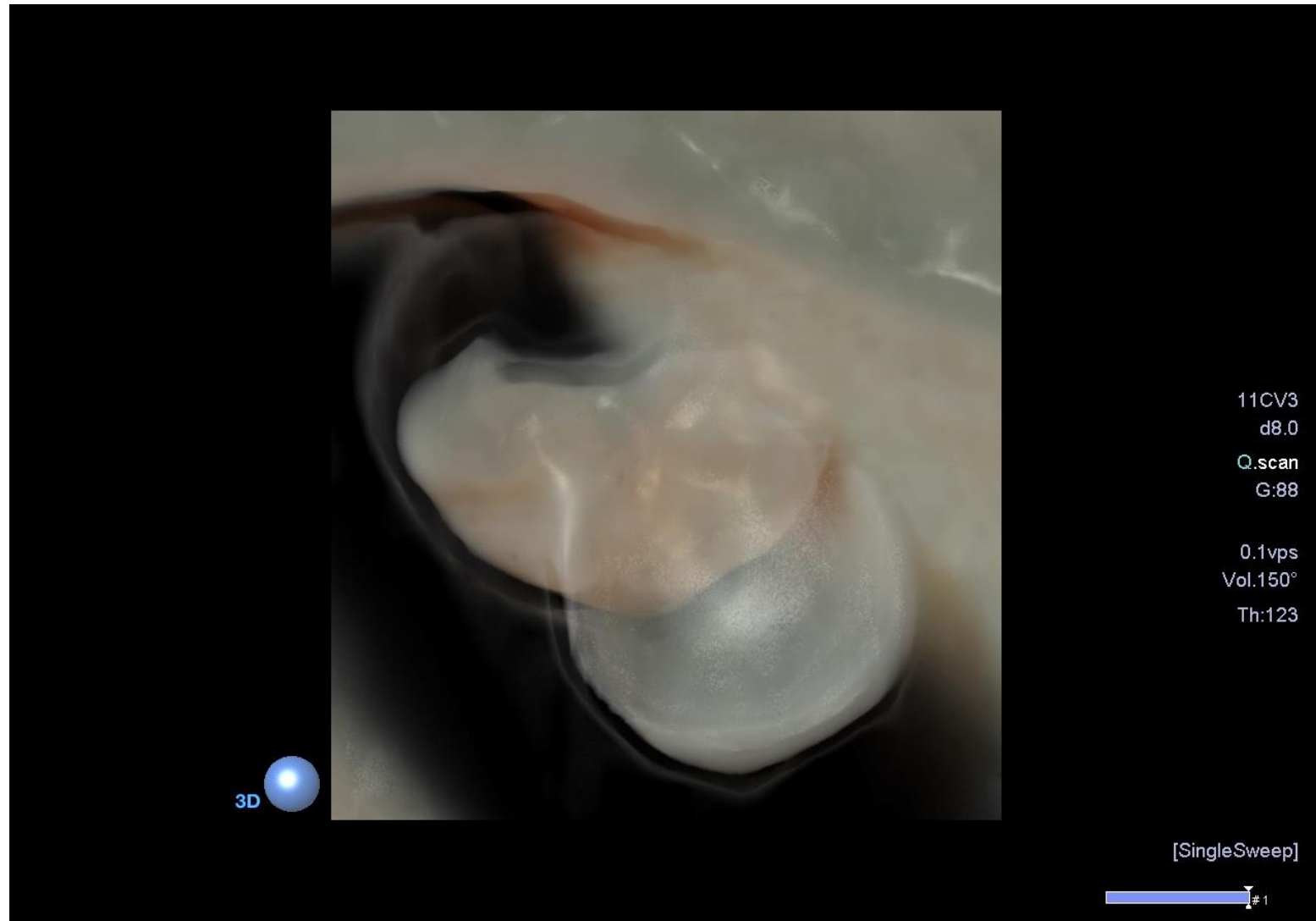
Prognostic Evaluation

Ultrasound Assessment Of Early Pregnancy



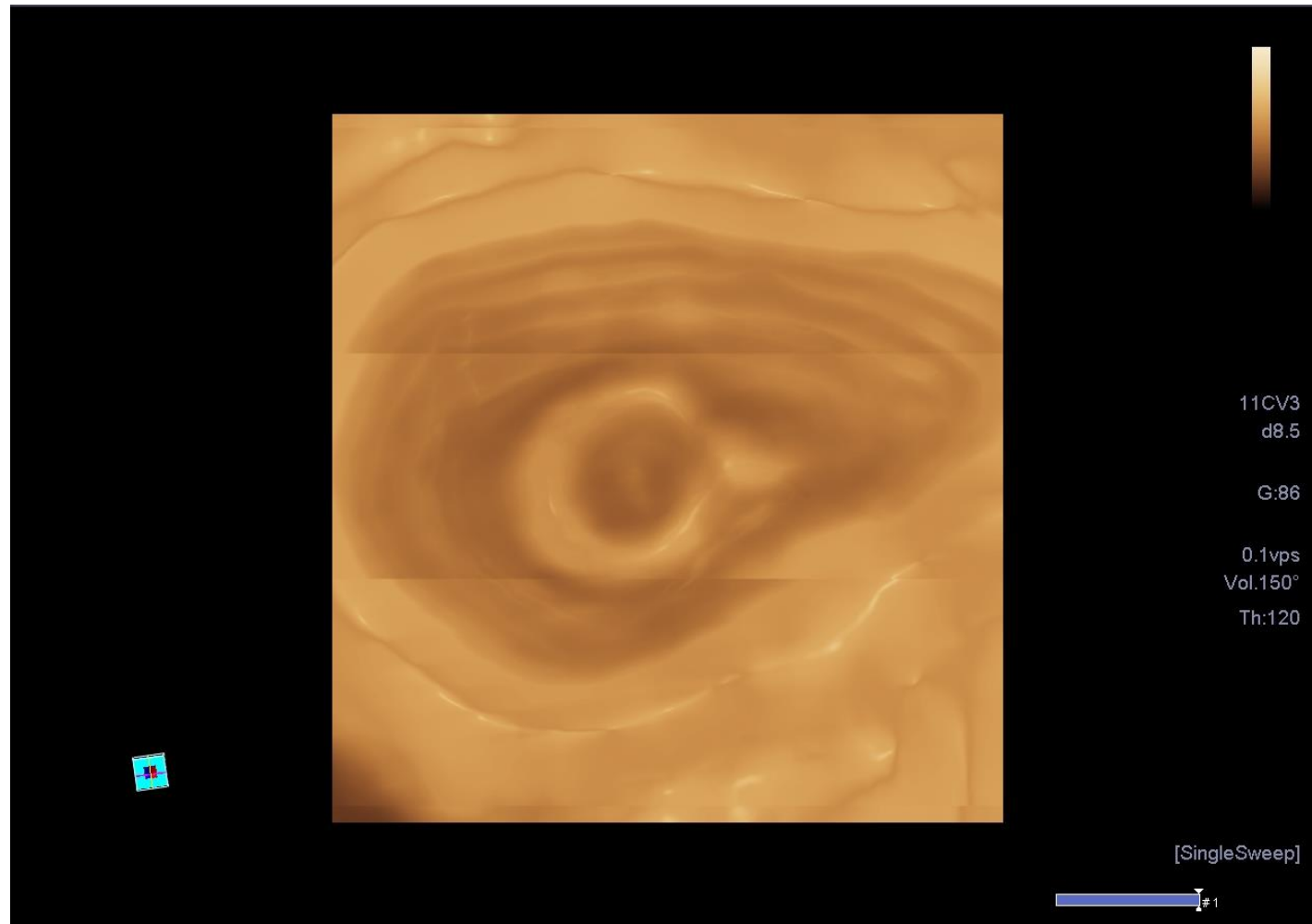
Ovulation + 18 days

Ultrasound Assessment Of Early Pregnancy



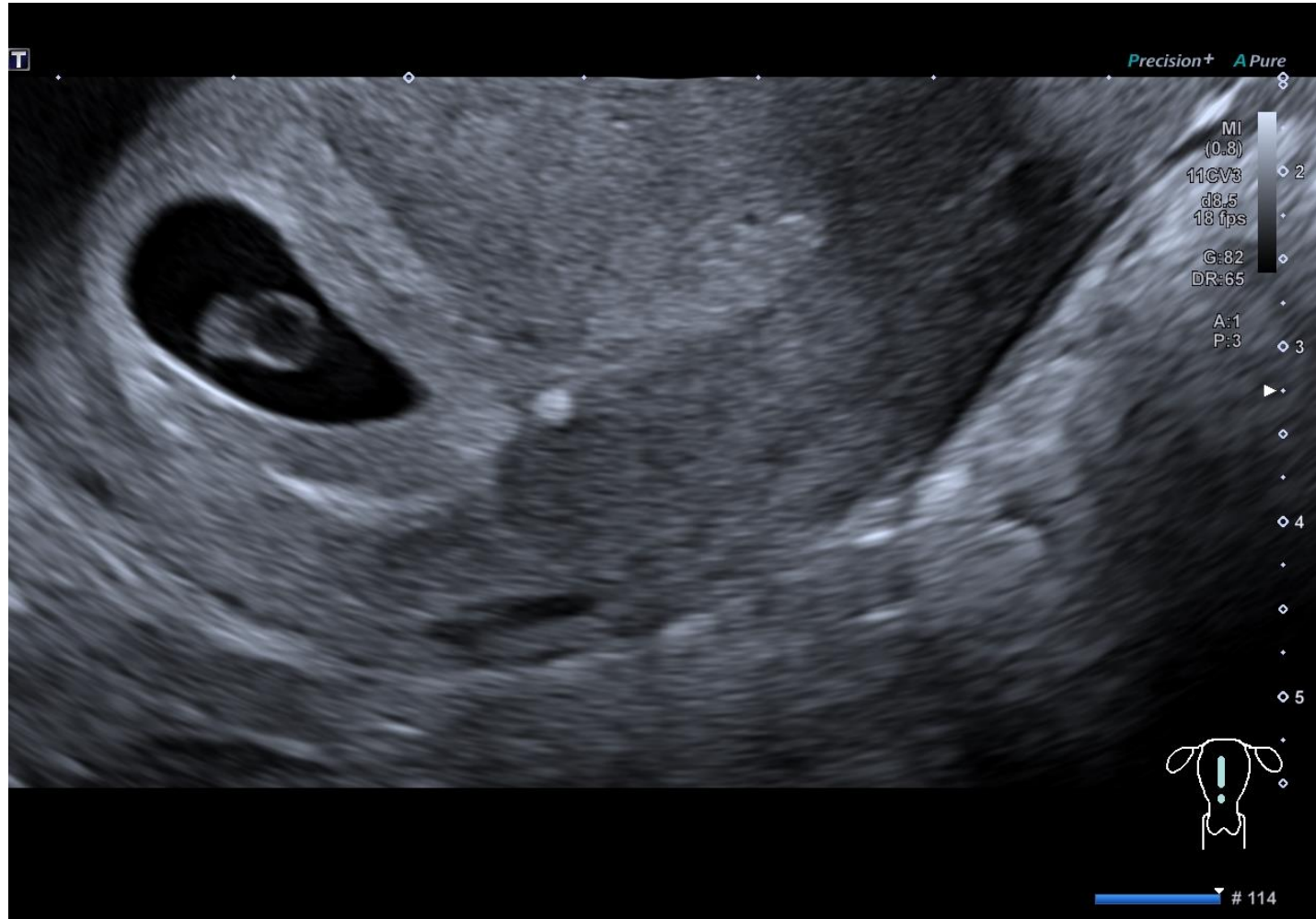
Ovulation + 29 days

Ultrasound Assessment Of Early Pregnancy



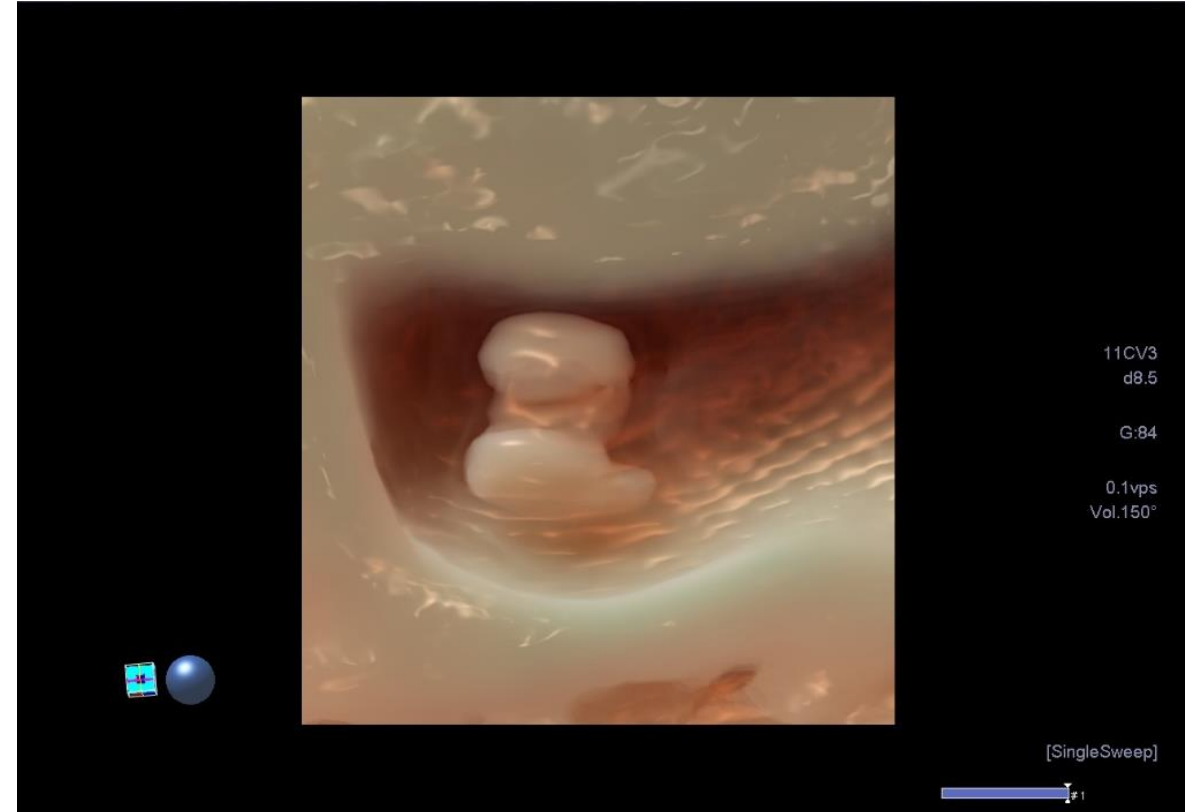
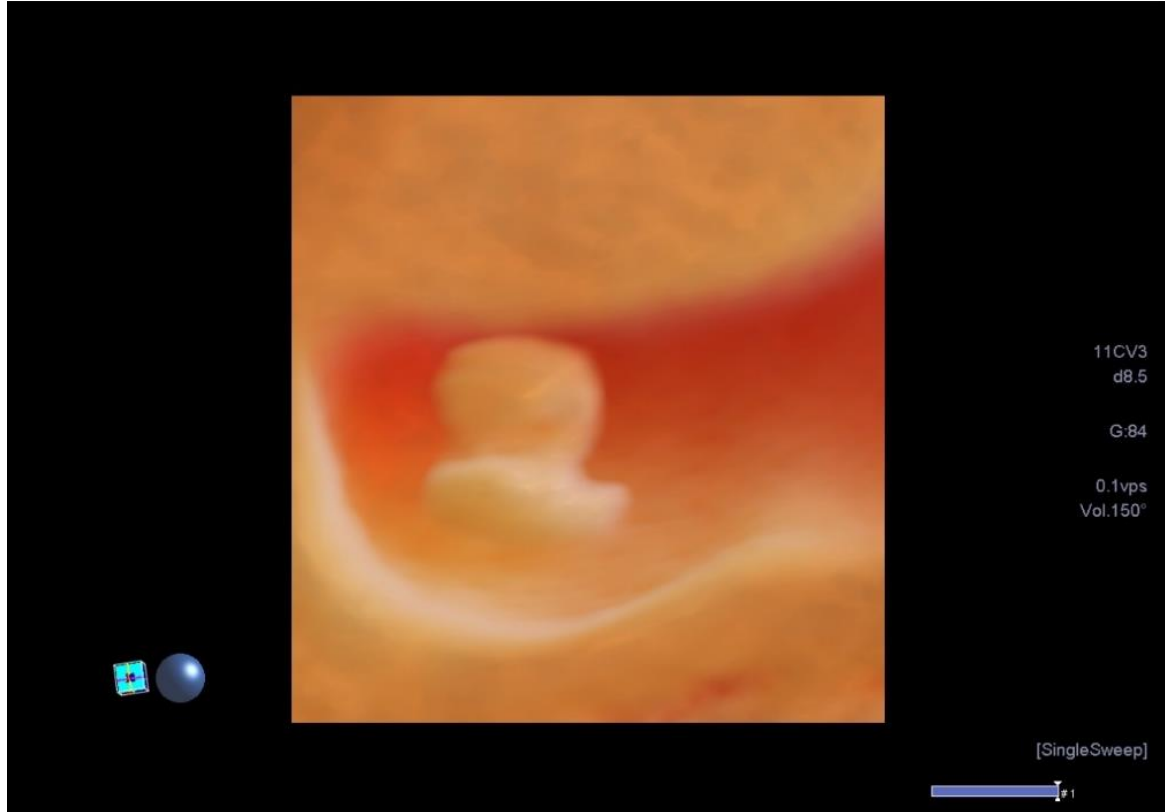
Ovulation + 22 days

Ultrasound Assessment Of Early Pregnancy



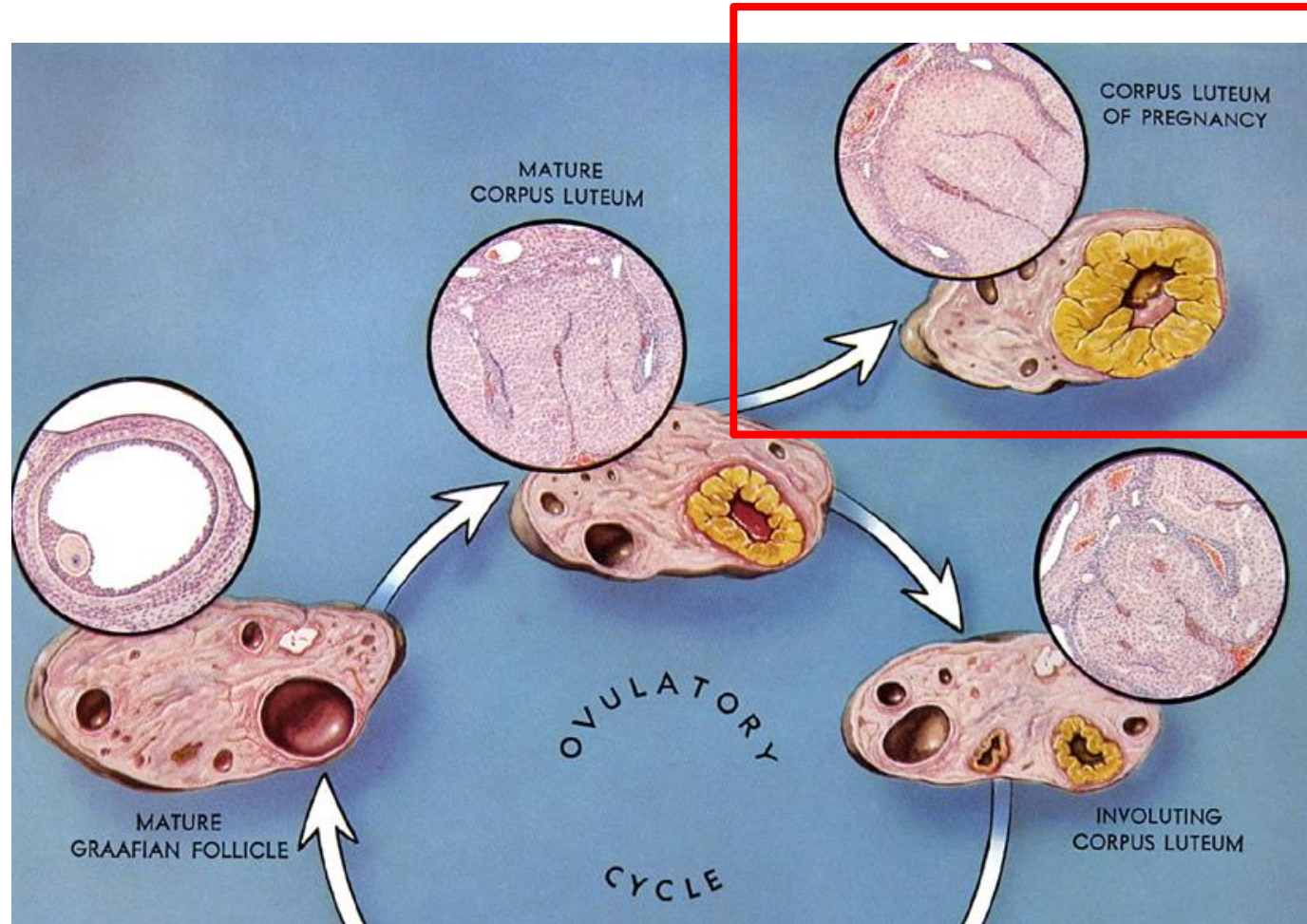
Ovulation + 31 days

Ultrasound Assessment Of Early Pregnancy



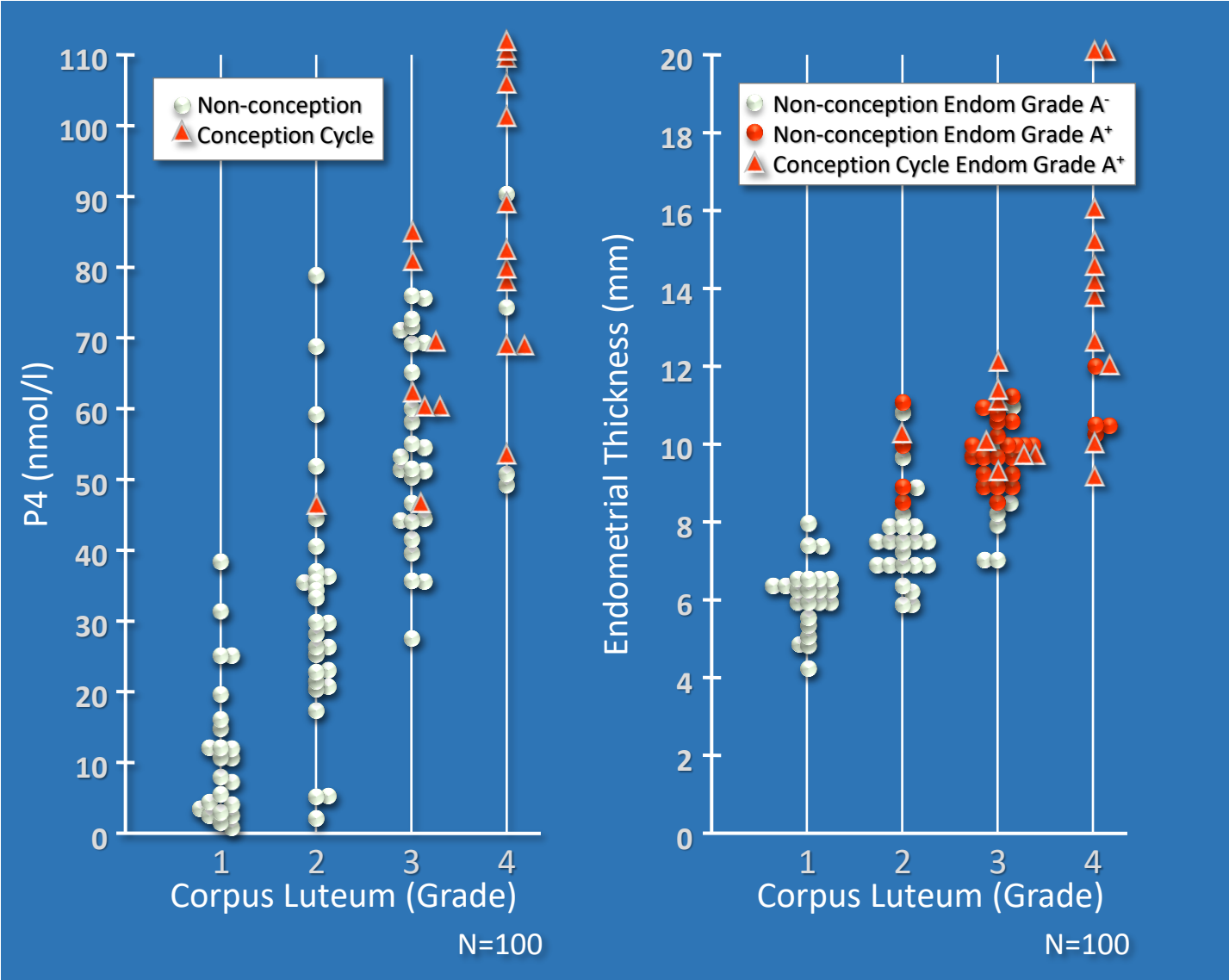
Ovulation + 31 days

Ultrasound Assessment Of Early Pregnancy



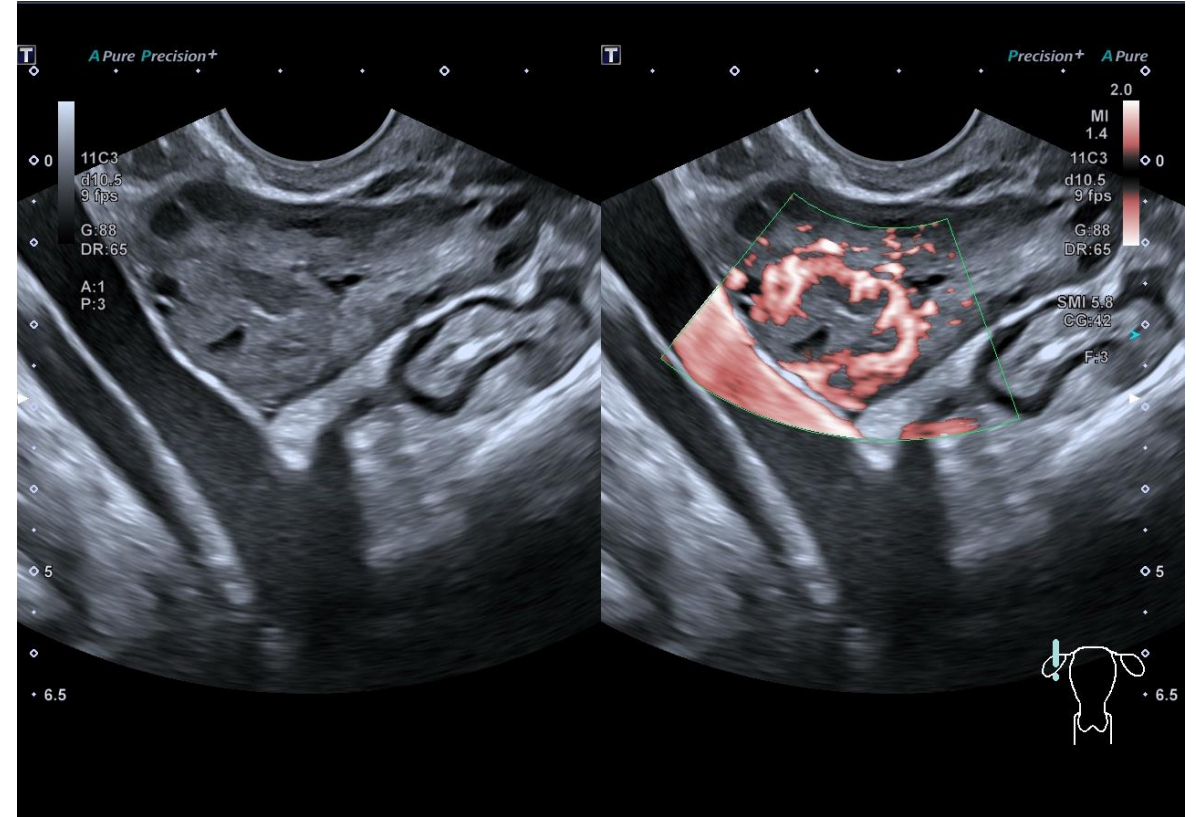
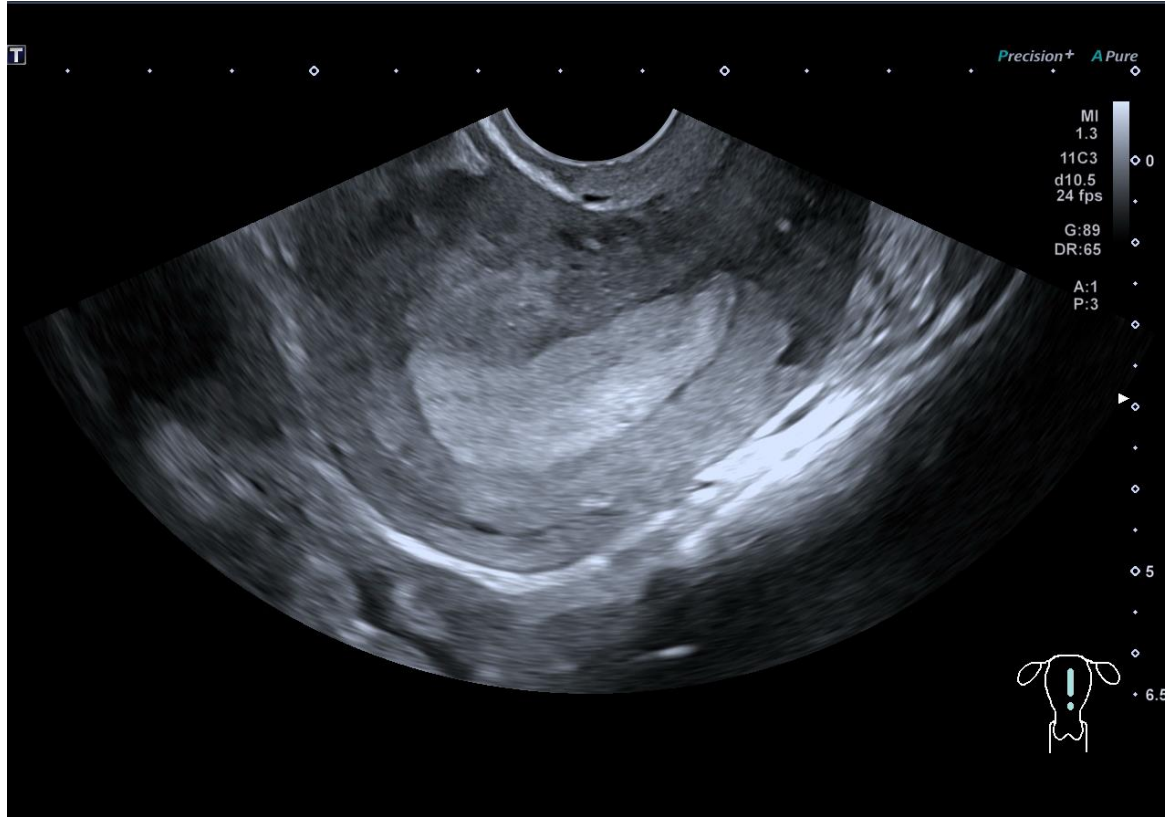
Prognostic Evaluation

Comprehensive Cycle Monitoring



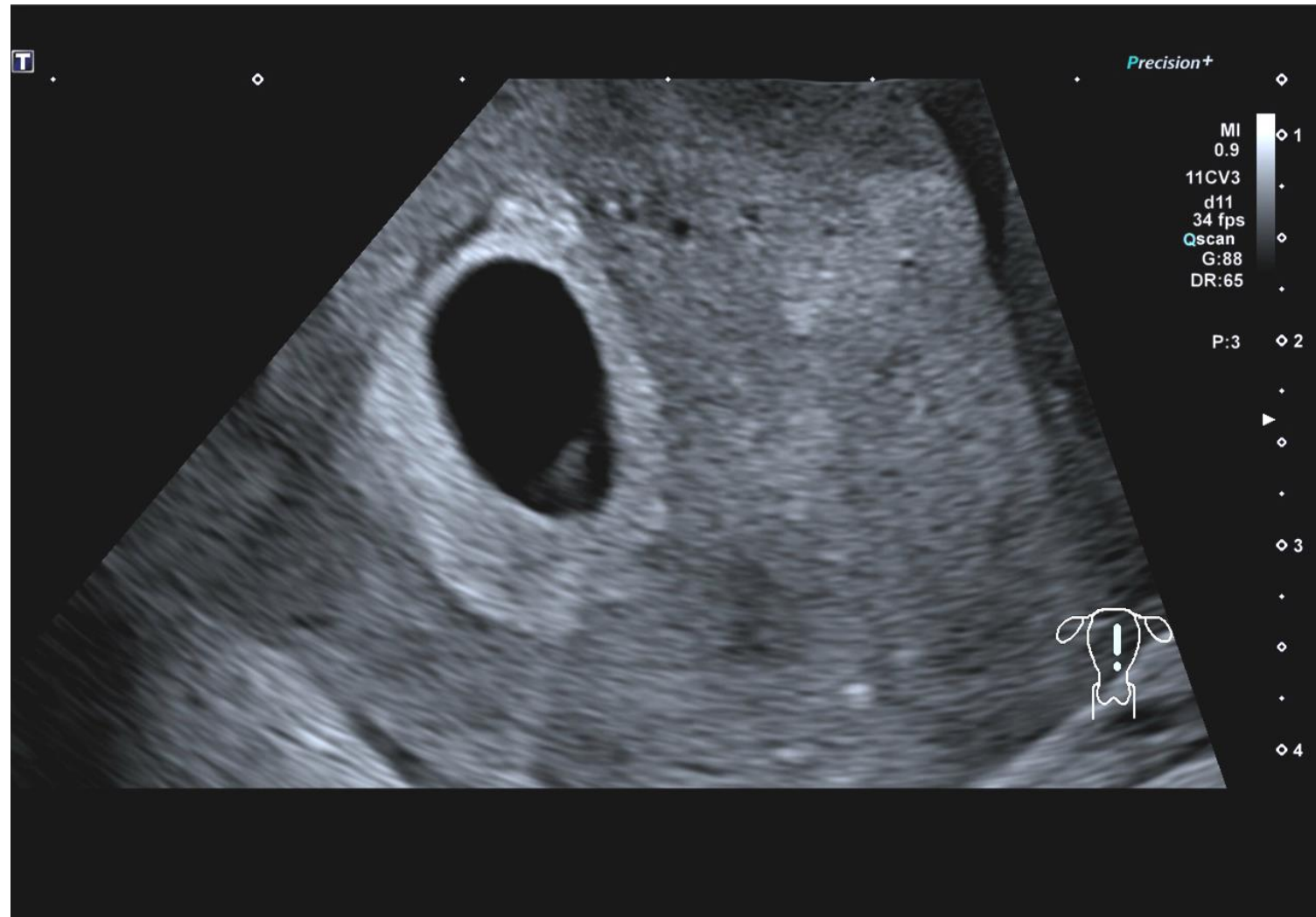
Luteal Phase Study

Comprehensive Cycle Monitoring



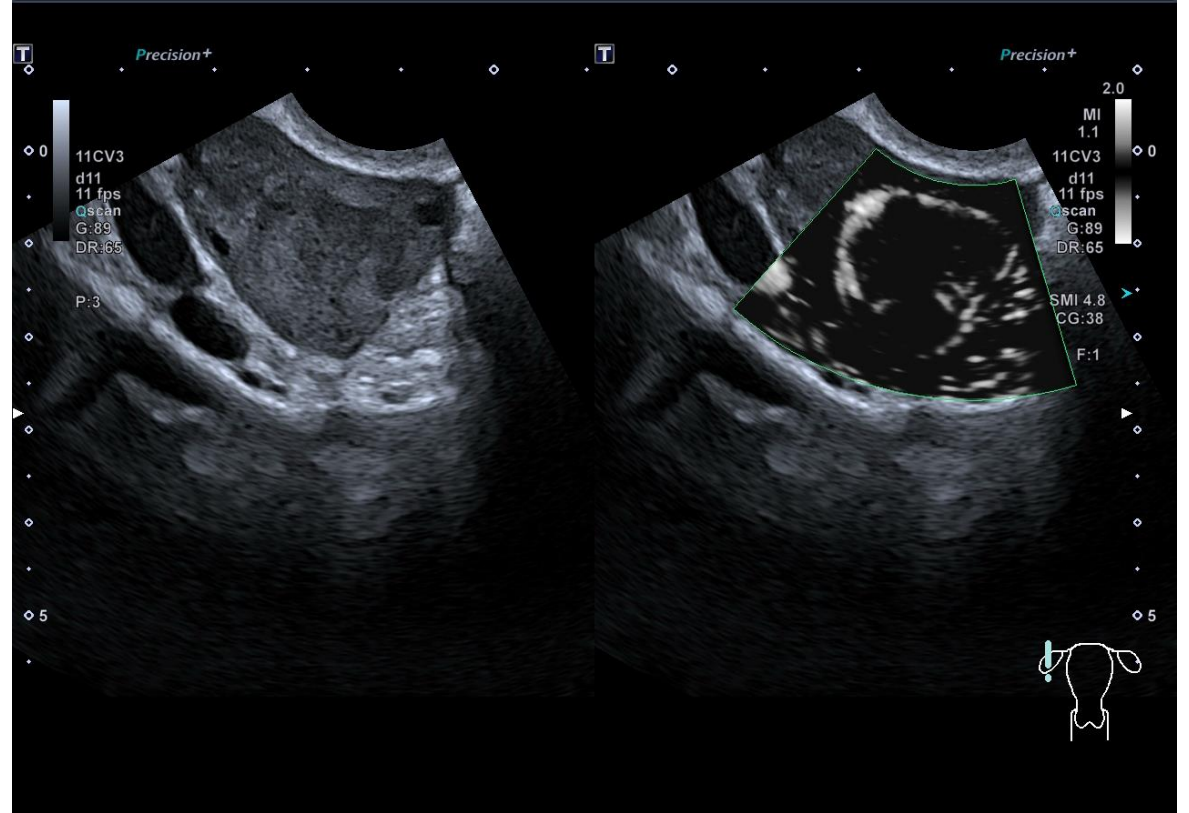
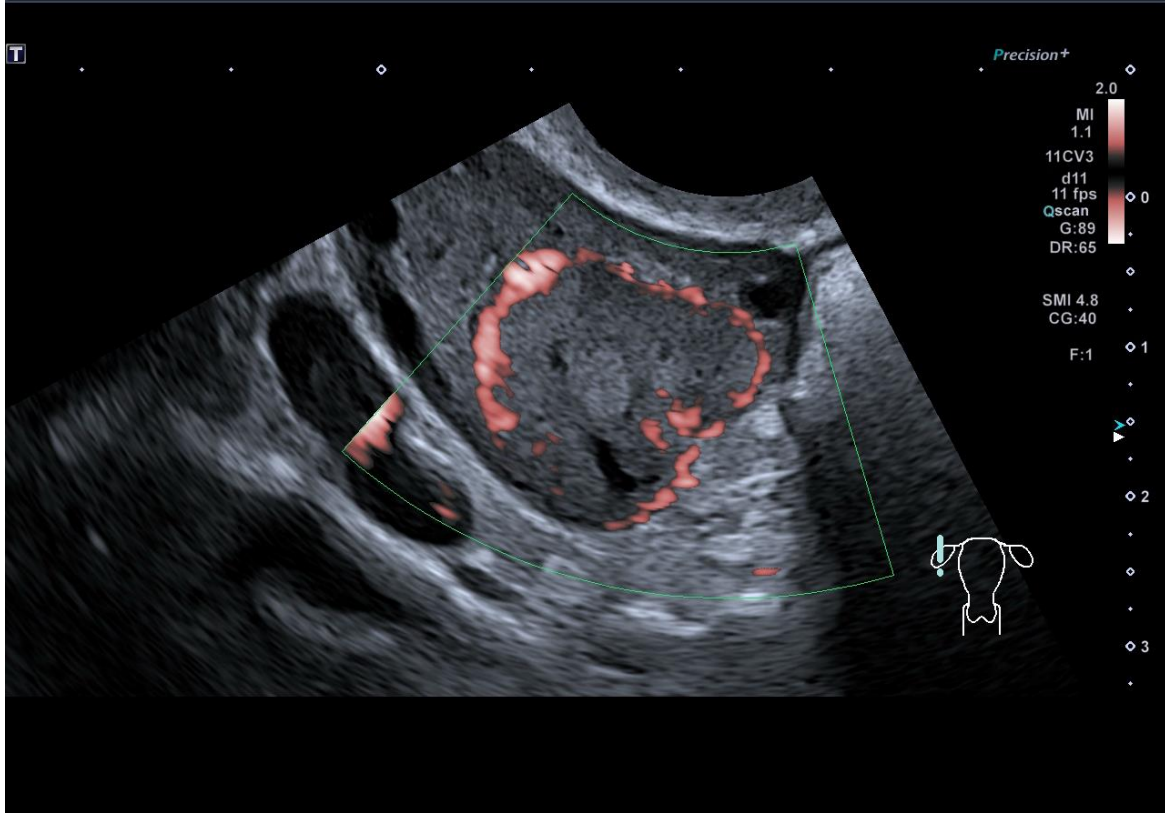
Positive Pregnancy Test – Ovulation + 13 days

Early Pregnancy Assessment

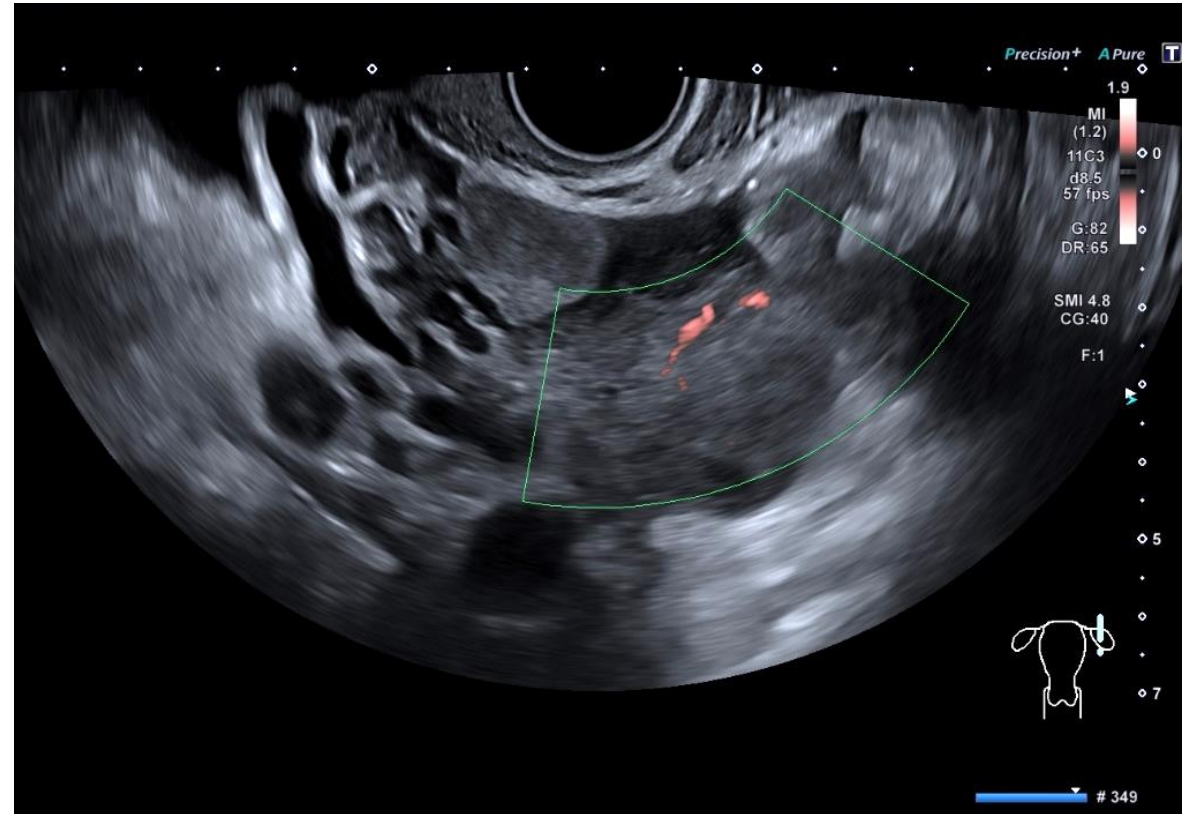
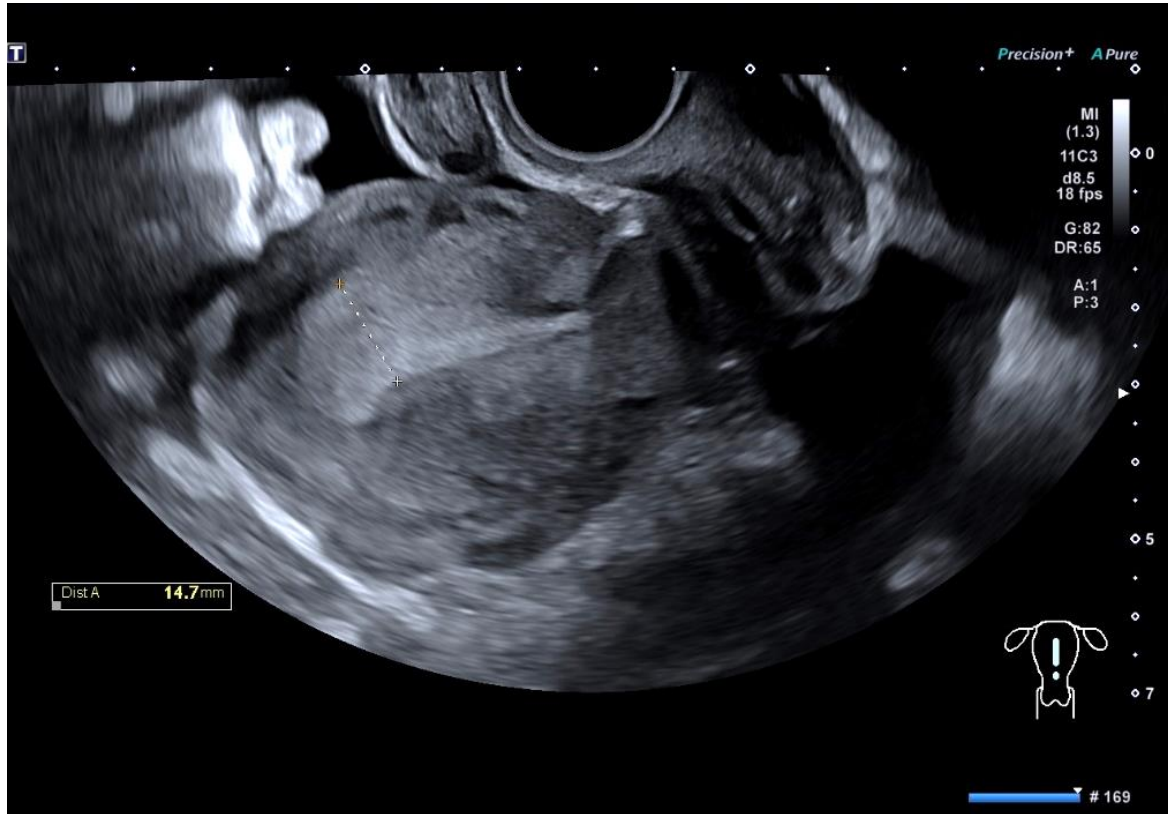

Ovulation + 26 Days

Early Pregnancy Assessment

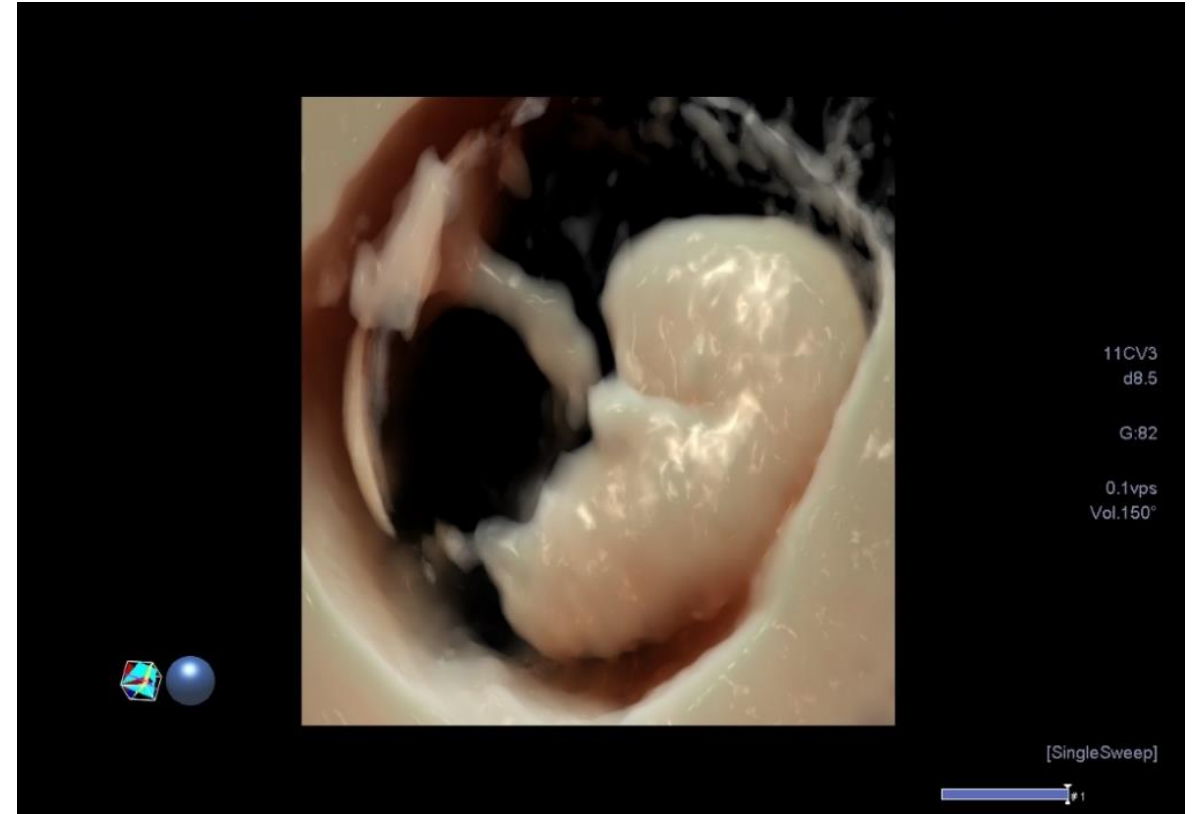
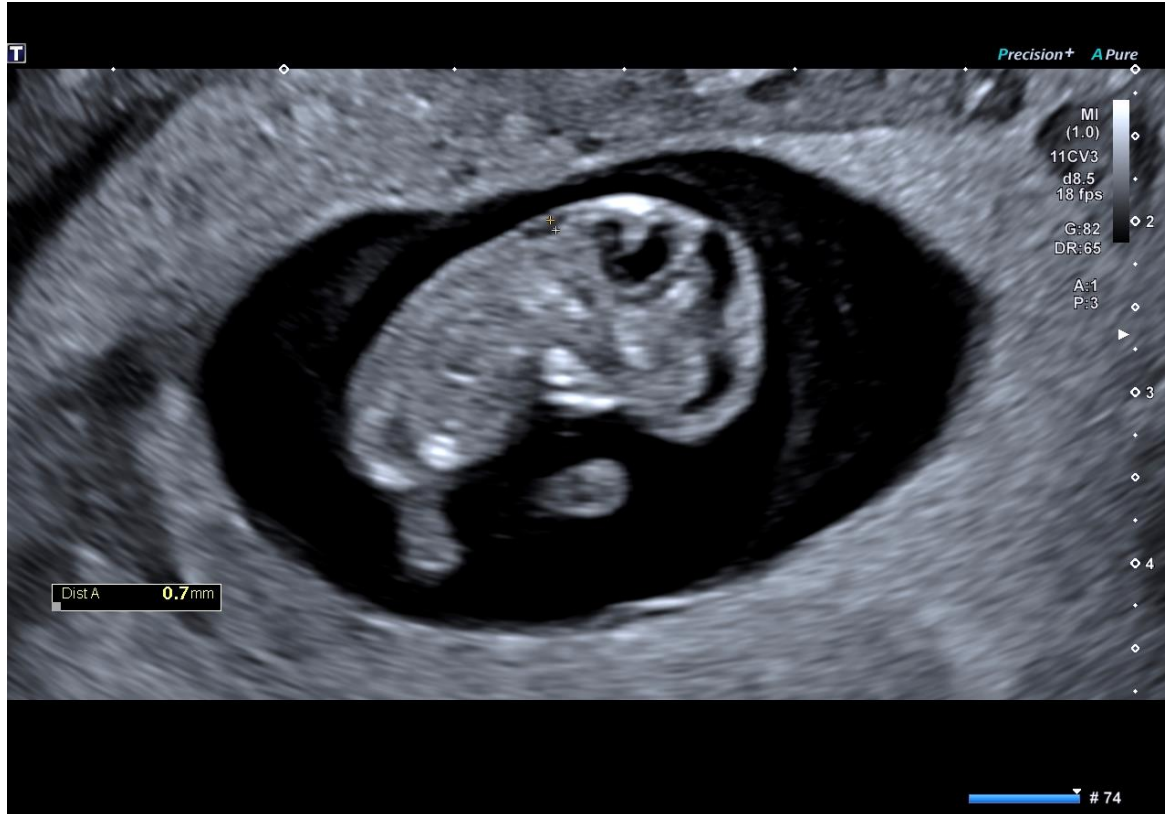

Early Pregnancy Assessment



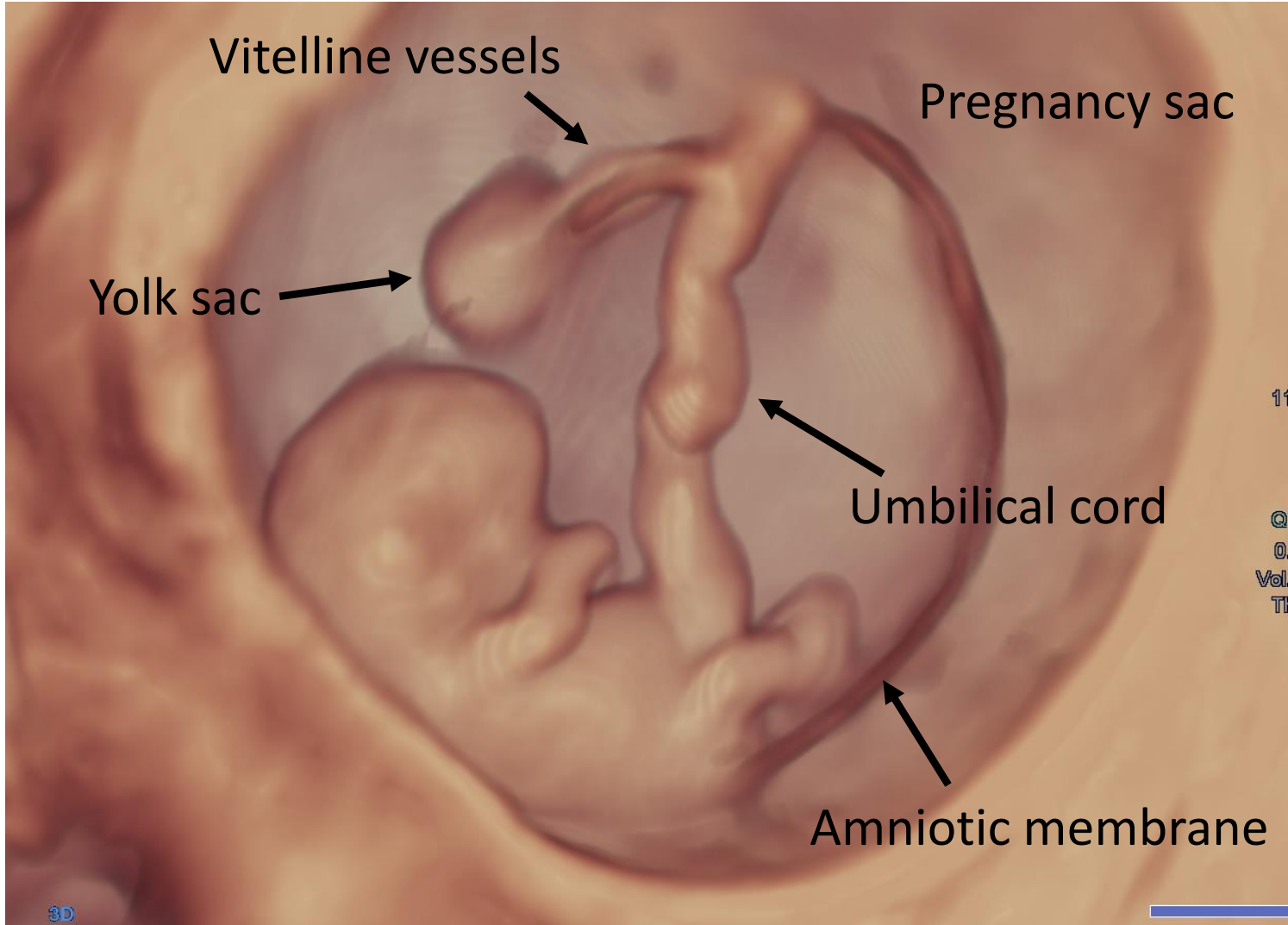
Ovulation + 13 Days

Early Pregnancy Assessment

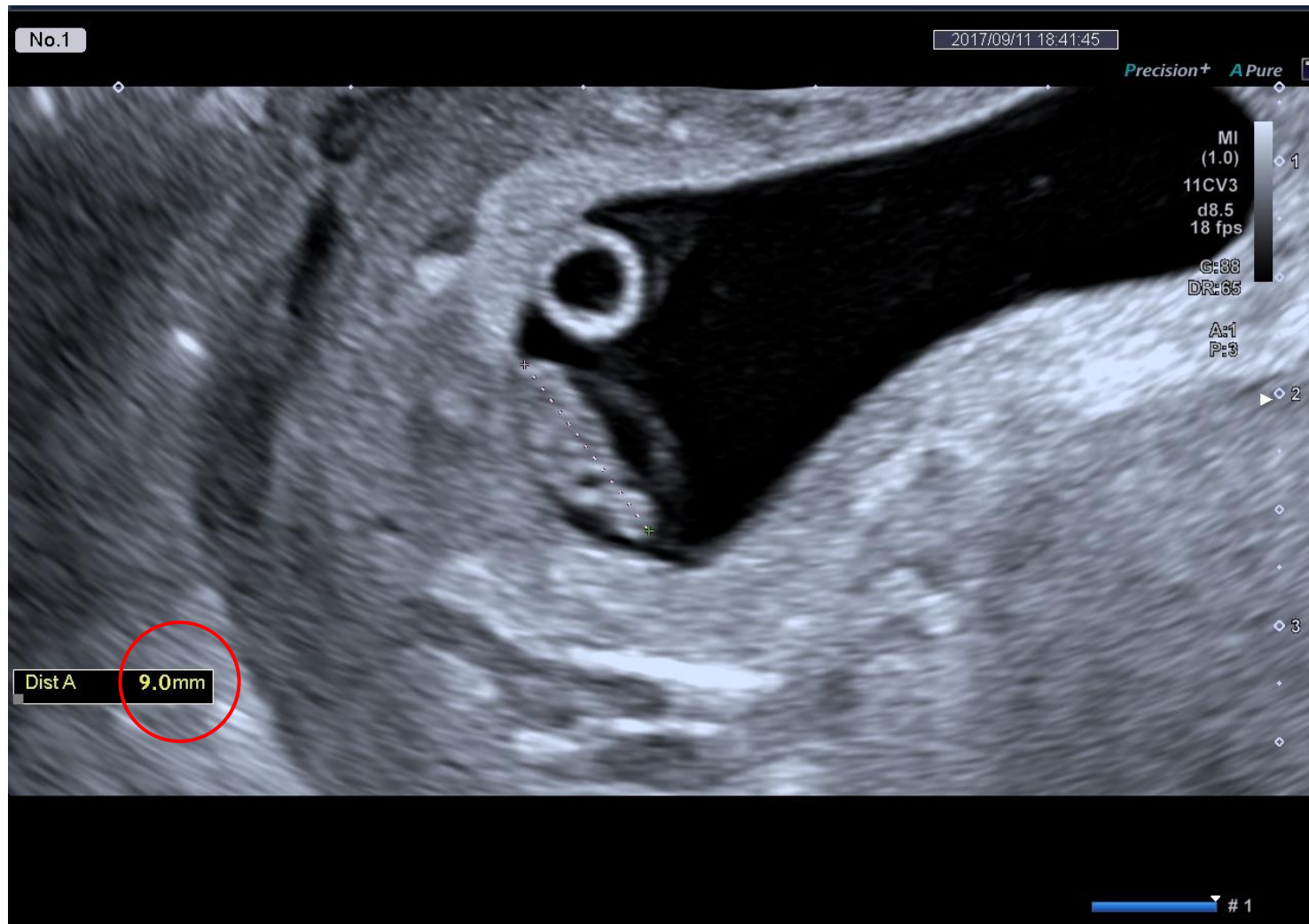


Ovulation + 46 Days Cyclogest Rx

Early Fetal Assessment

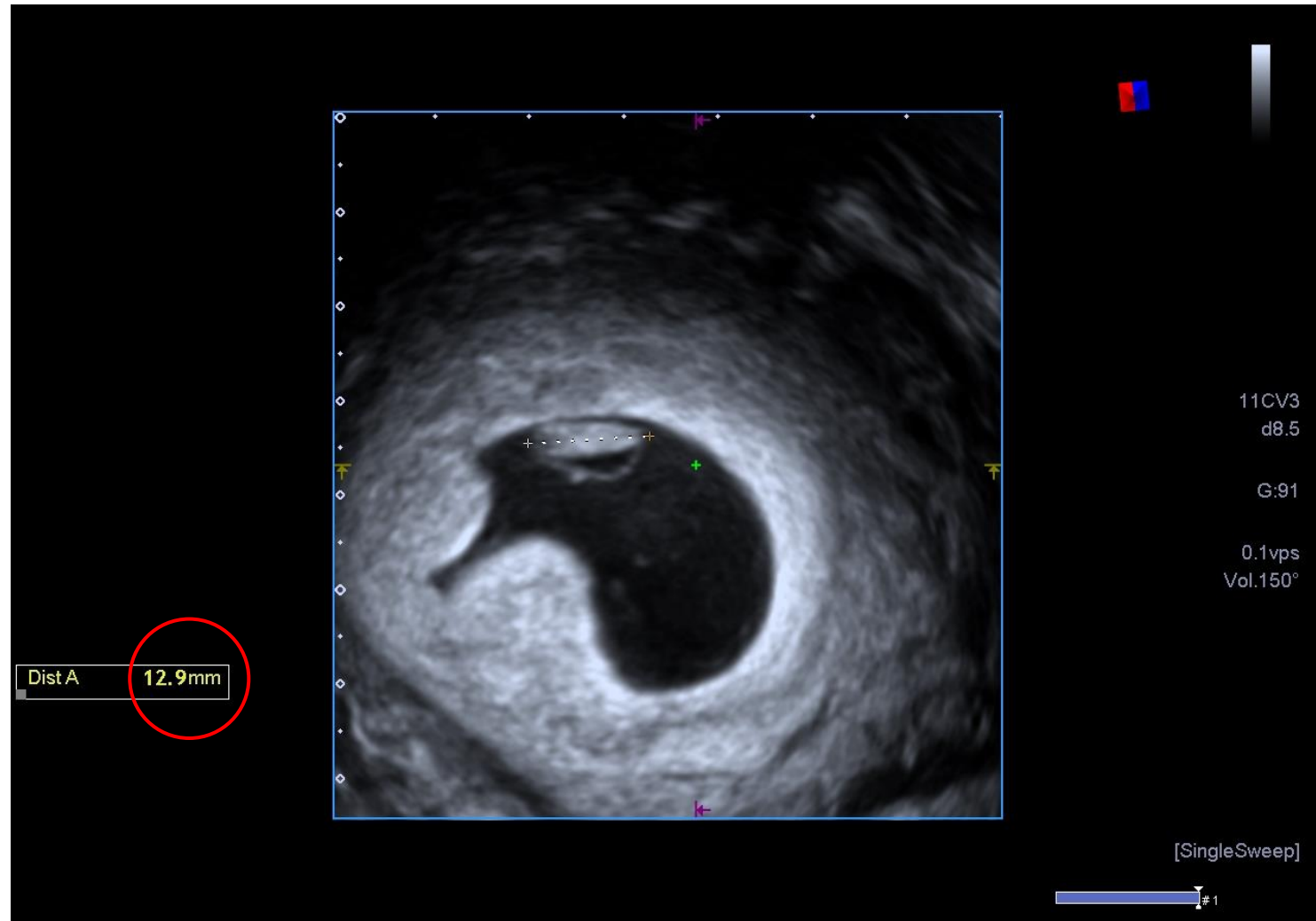


Early Fetal Measurement



CRL 2D TVS

Early Fetal Assessment



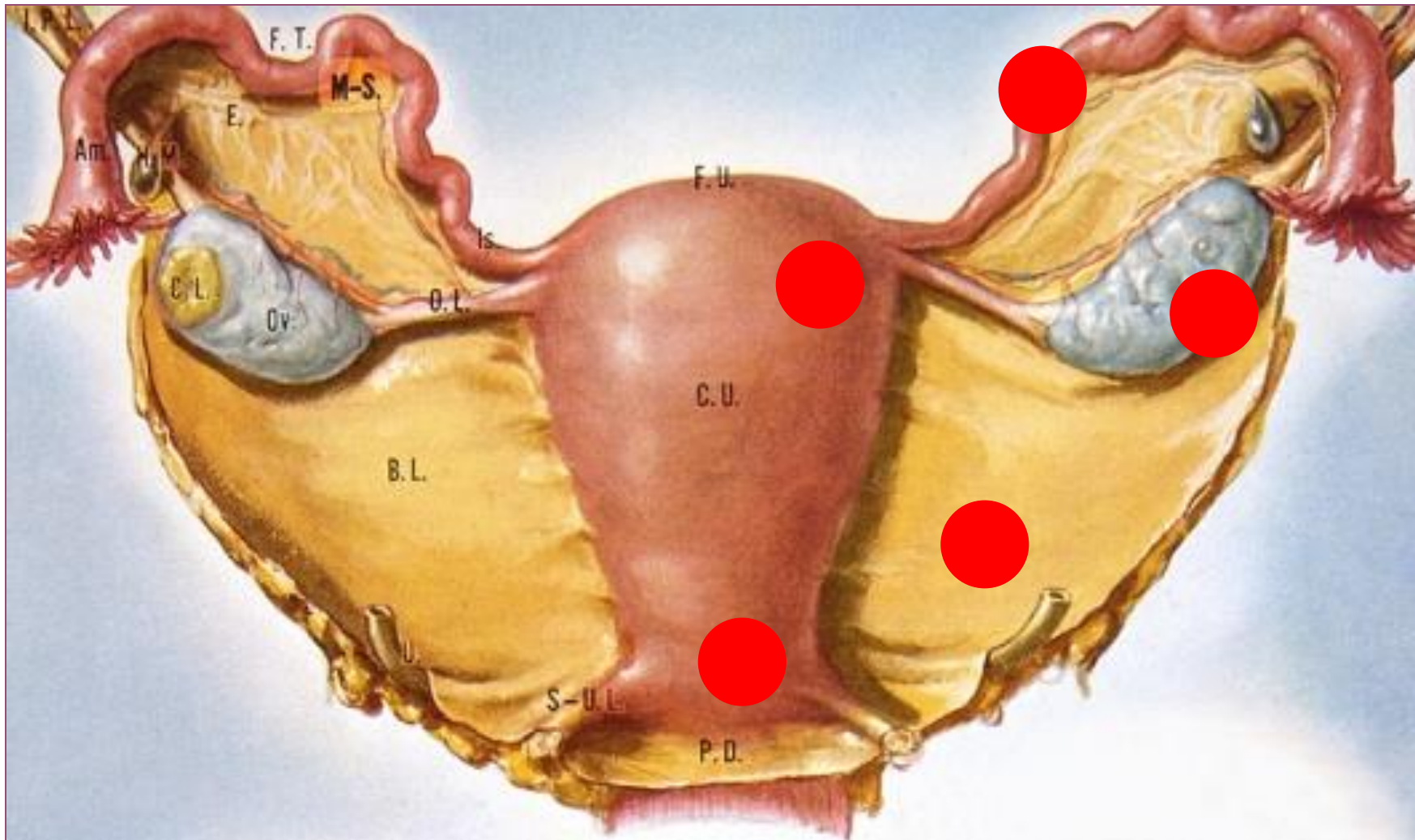
CRL 3D TVS (“reconstructed”)

Early Fetal Measurement

Experience suggest significant discrepancy regarding correlation between CRL measurements and clinical dates :

- 100 normal pregnancies 6-10 wks gest. (known conception dates)
- 80-90% CRL < Clinical Dates
- Ongoing study promotes the utilisation of 3D TVS for increased accuracy of CRL measurement and its clinical relevance

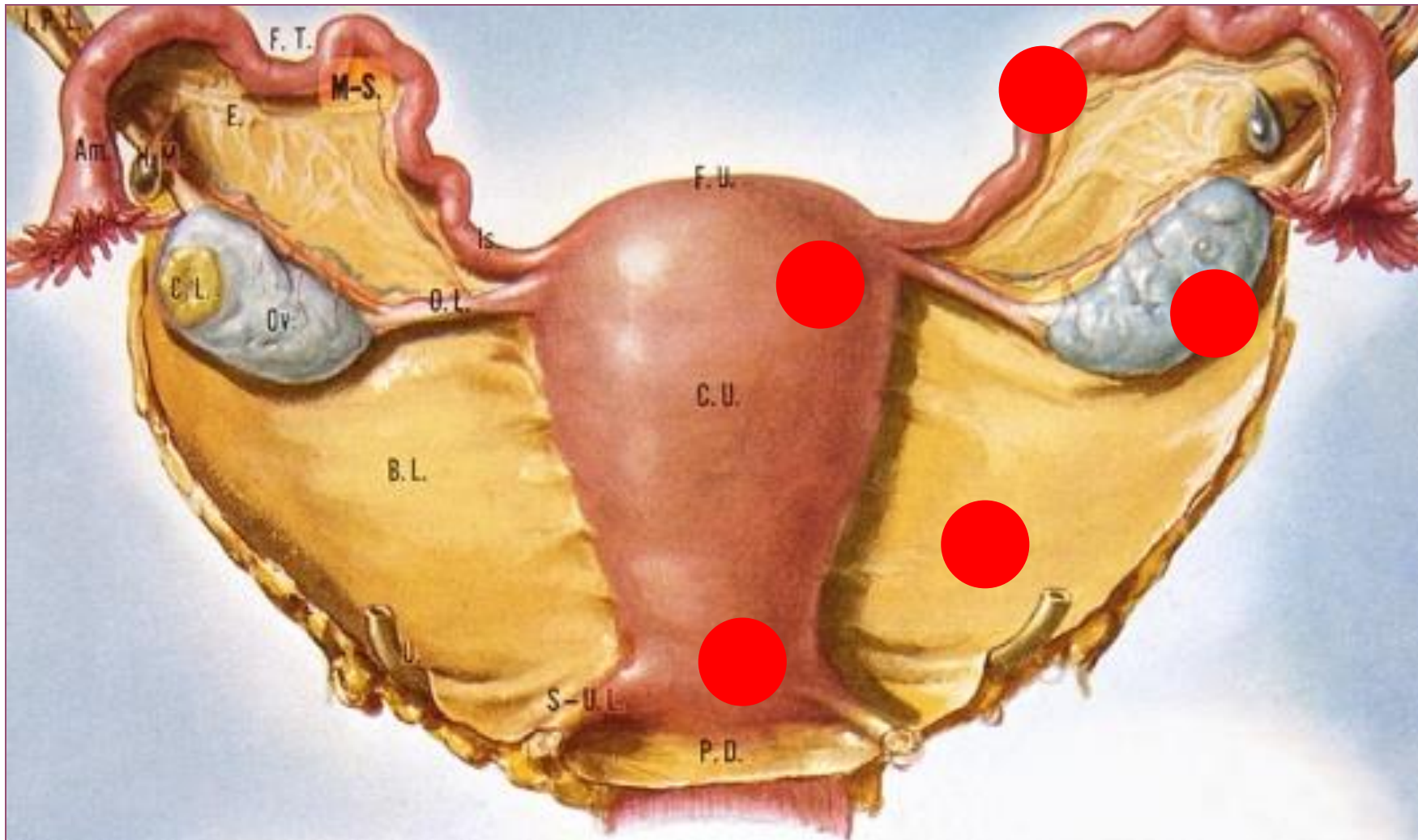
Ectopic Pregnancy



- Tubal
- Cornual
- Ovarian
- Cervical
- Abdominal

Locations

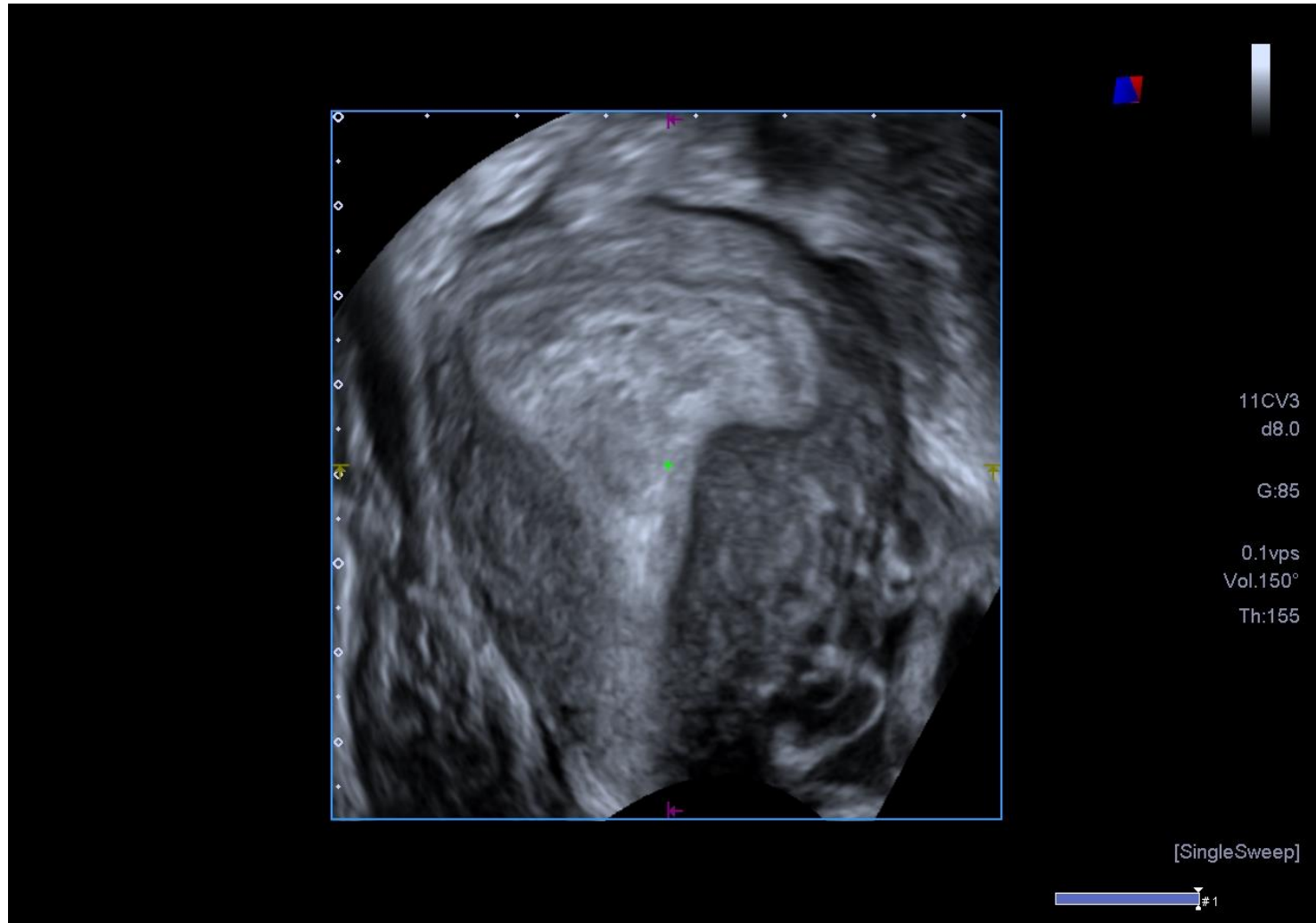
Ectopic Pregnancy



- Live
- Miscarried
- Molar development
- Compound
- Multiple
- CS scar

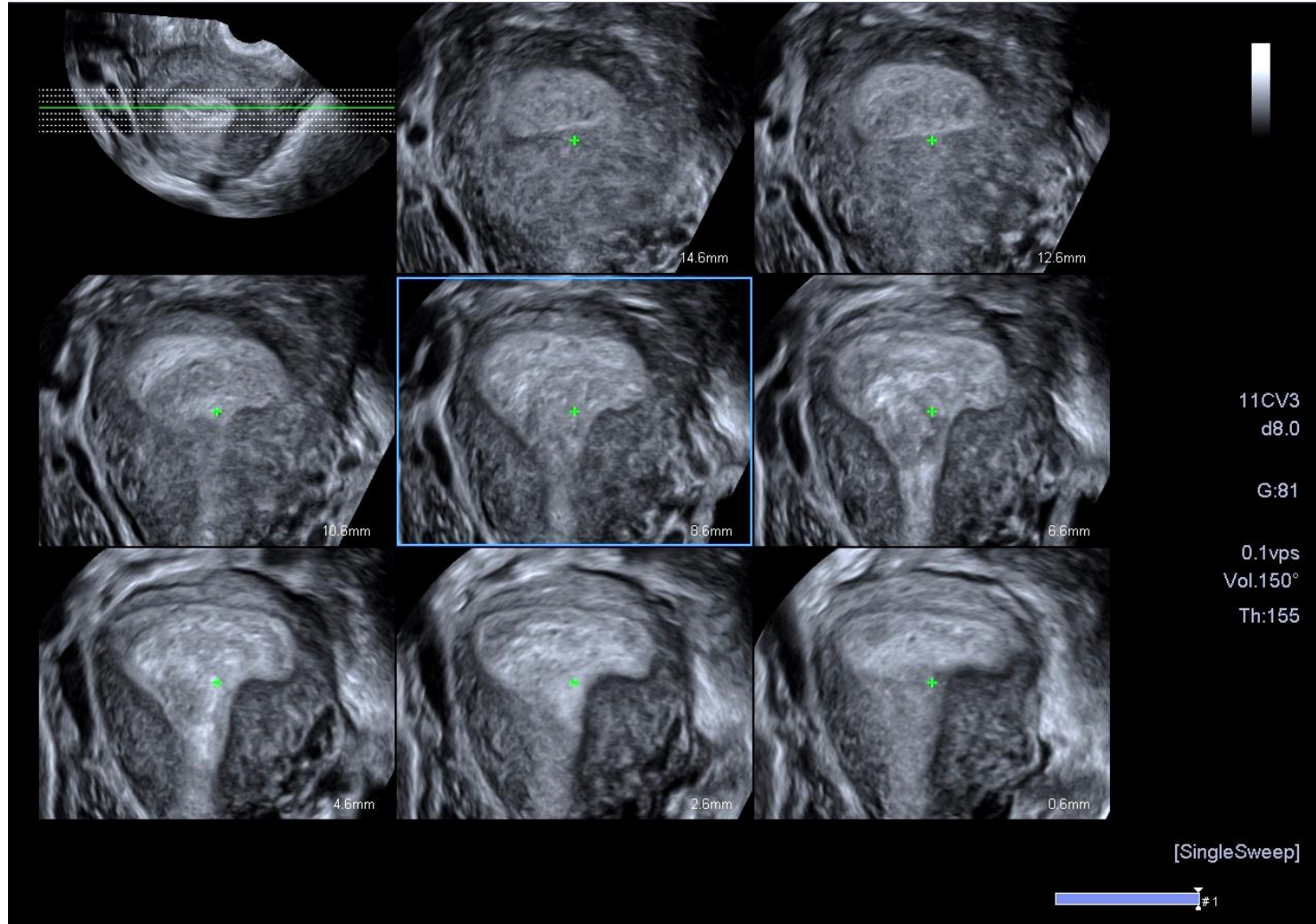
Status

Ectopic Pregnancy



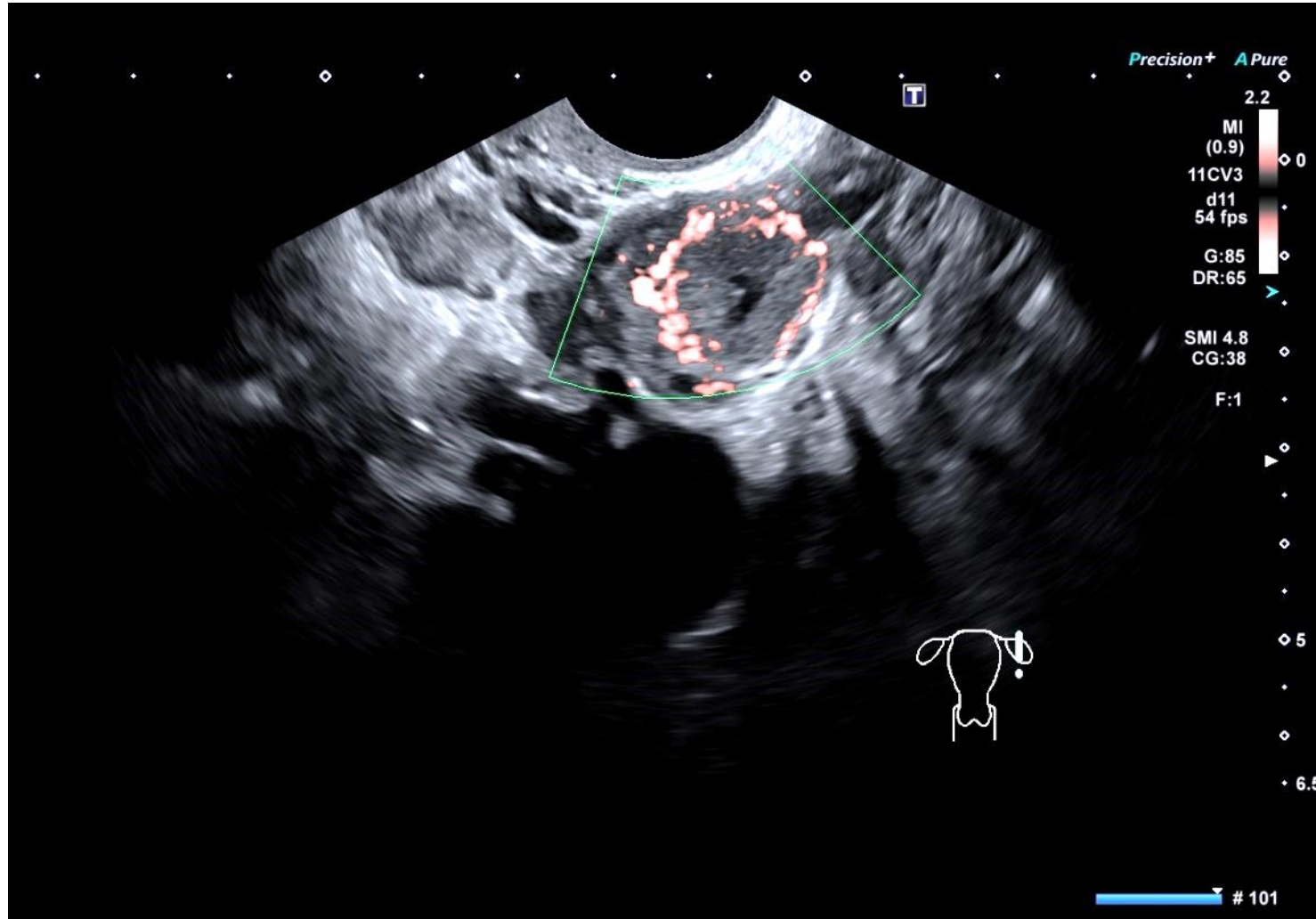
Status / Location : Live Tubal

Ectopic Pregnancy



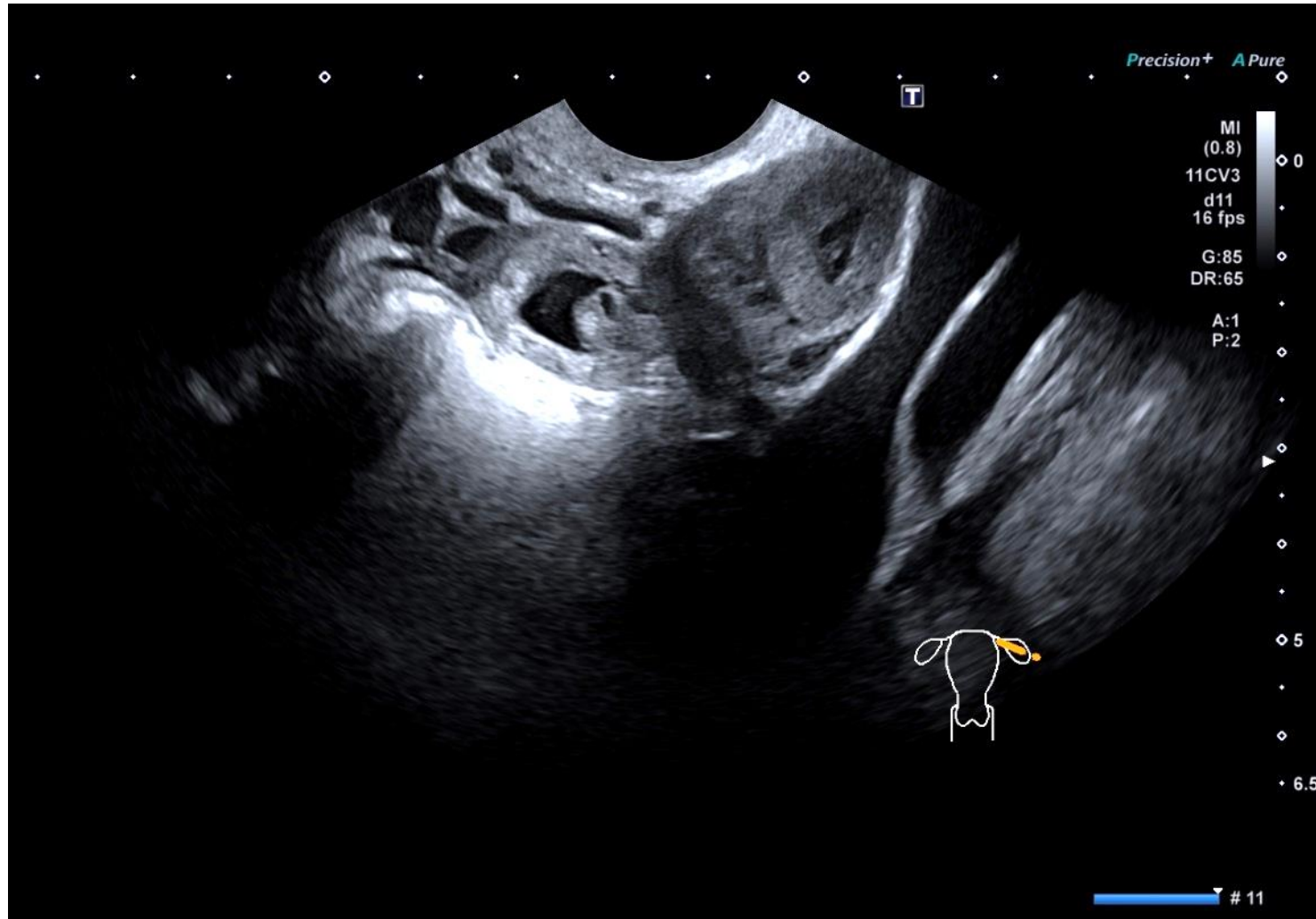
Status / Location : Live Tubal

Ectopic Pregnancy



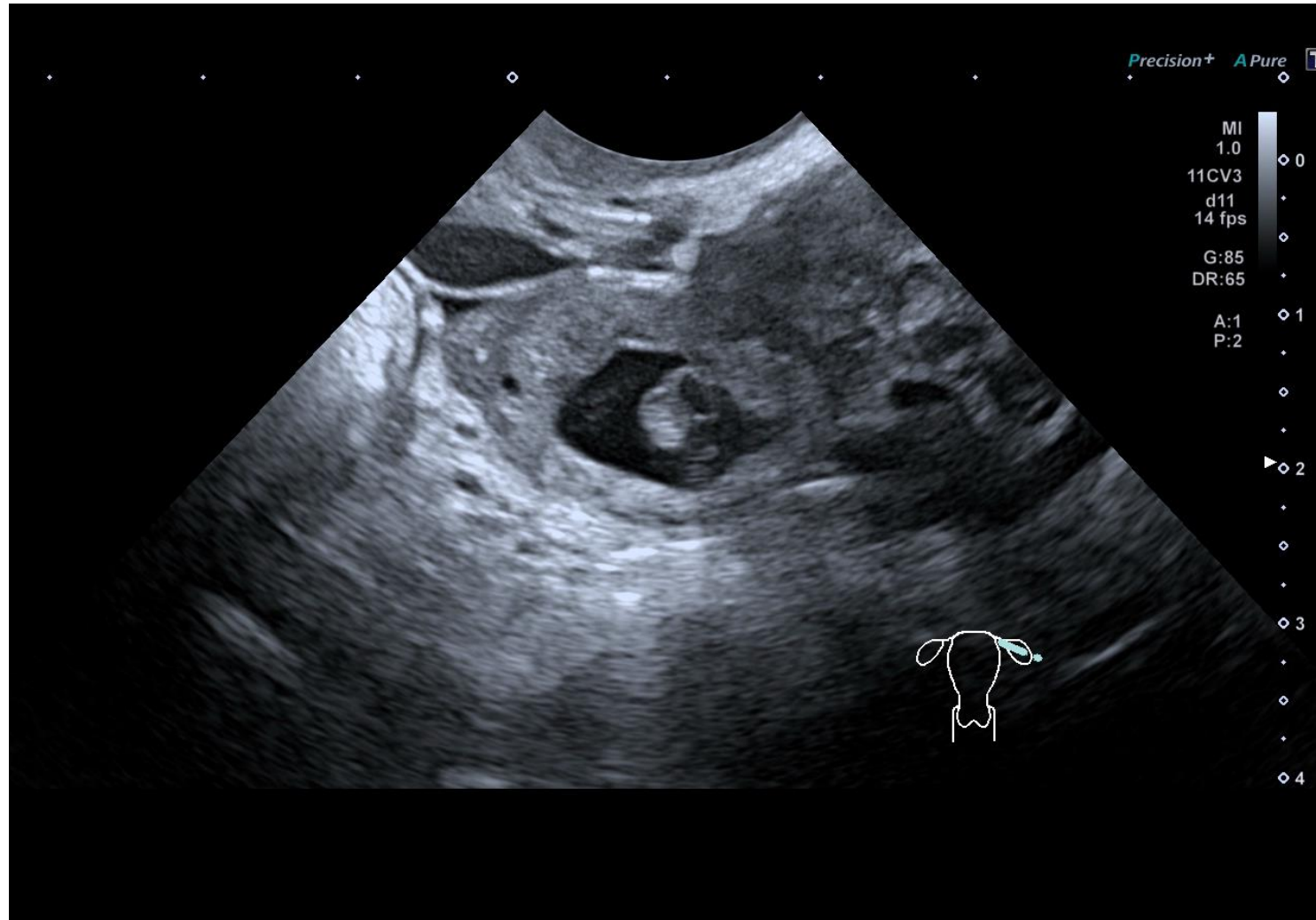
Status / Location : Live Tubal

Ectopic Pregnancy



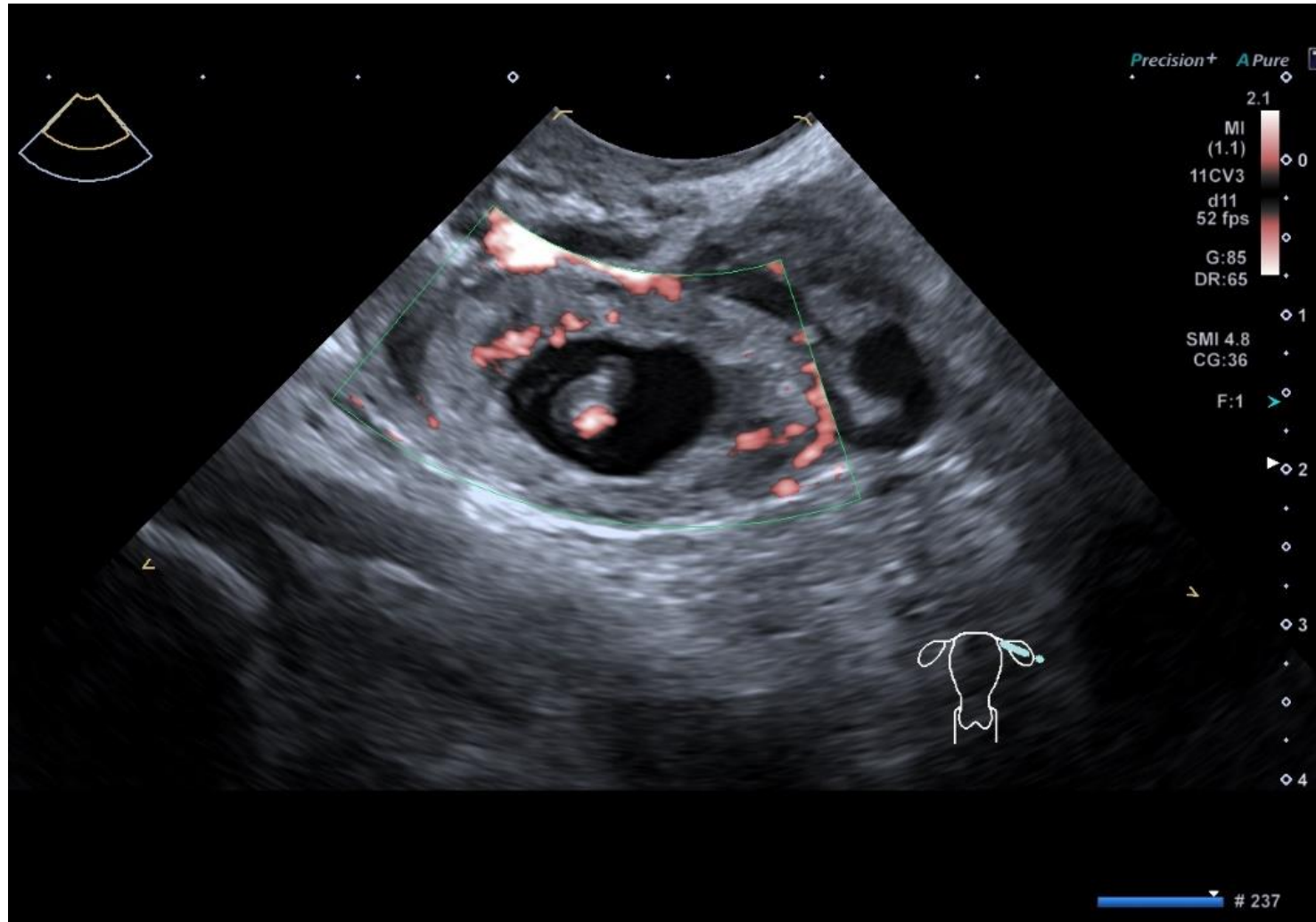
Status

Ectopic Pregnancy



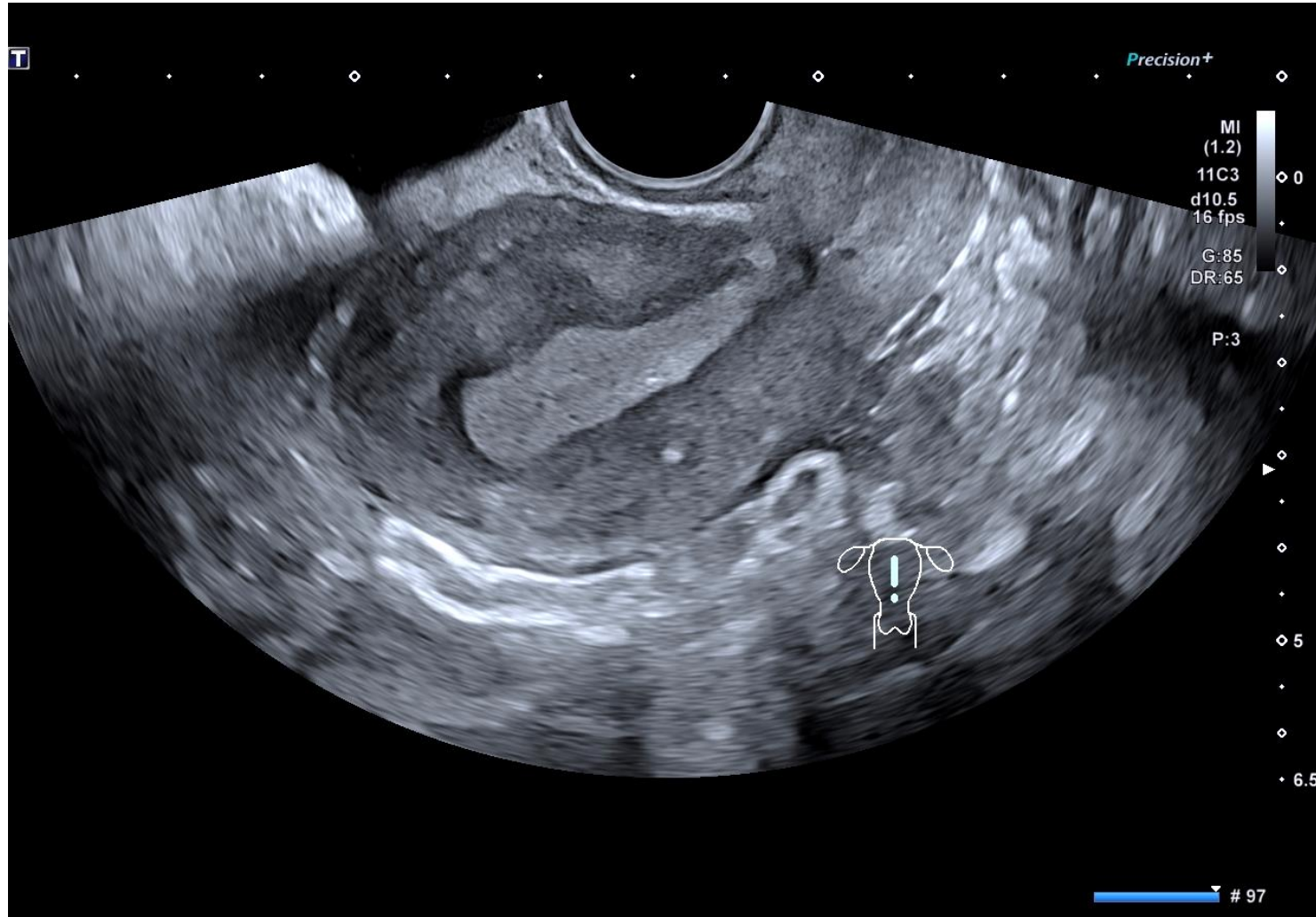
Status / Location : Live Tubal

Ectopic Pregnancy



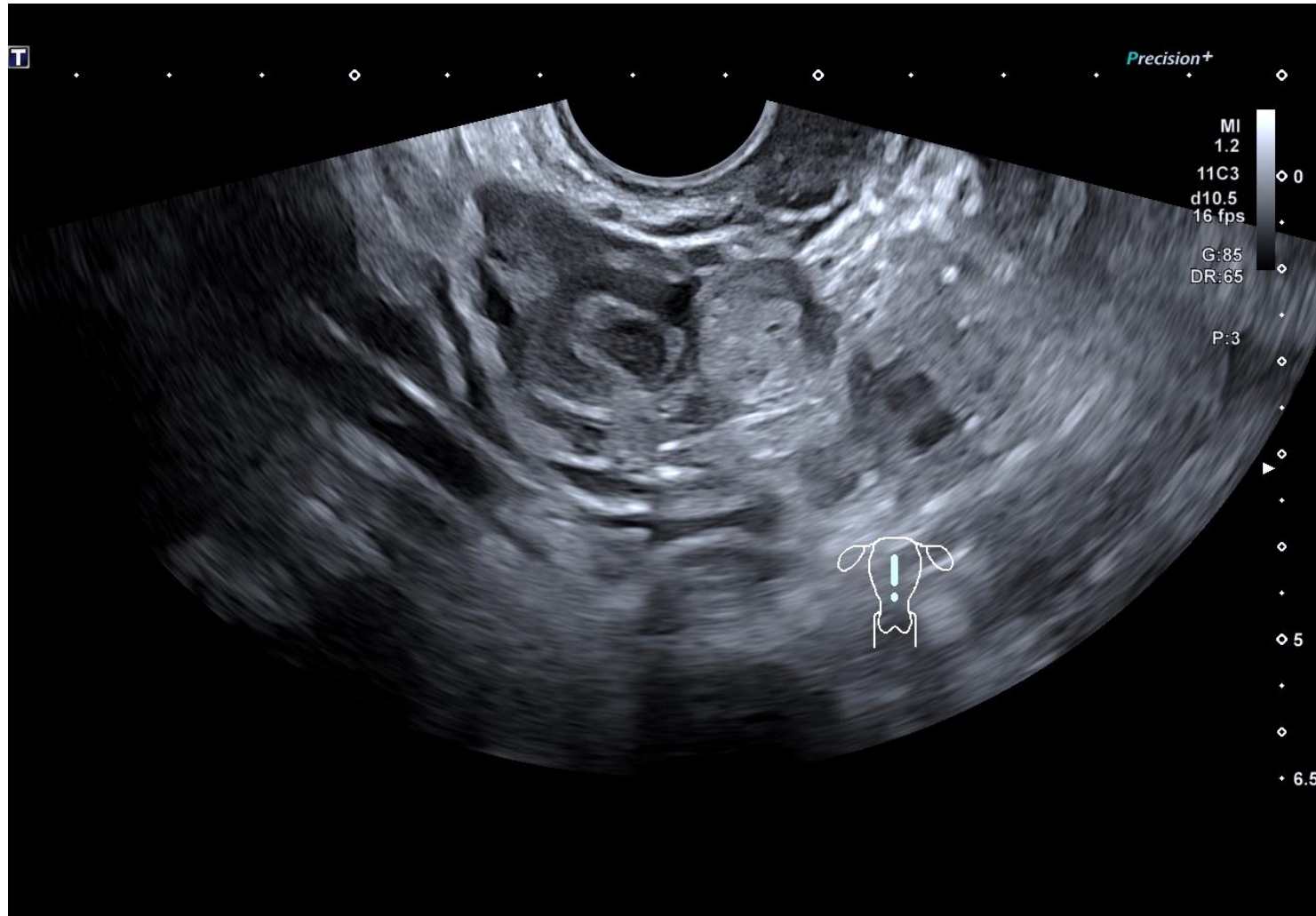
Status / Location : Live Tubal

Ectopic Pregnancy



Location / Status : Tubal Miscarriage

Ectopic Pregnancy

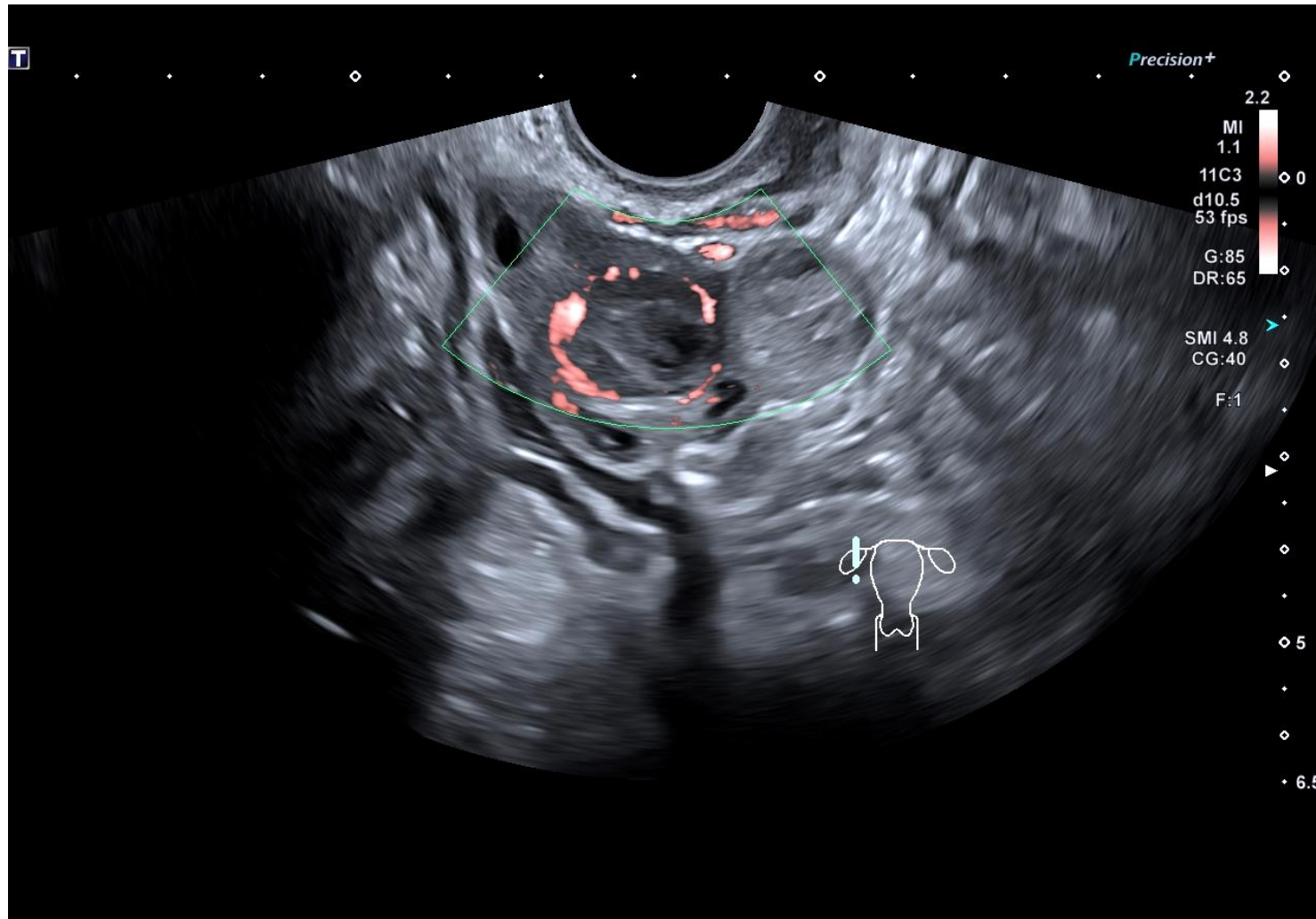


β hCG 13u

Location / Status : Tubal Miscarriage

Case 1B

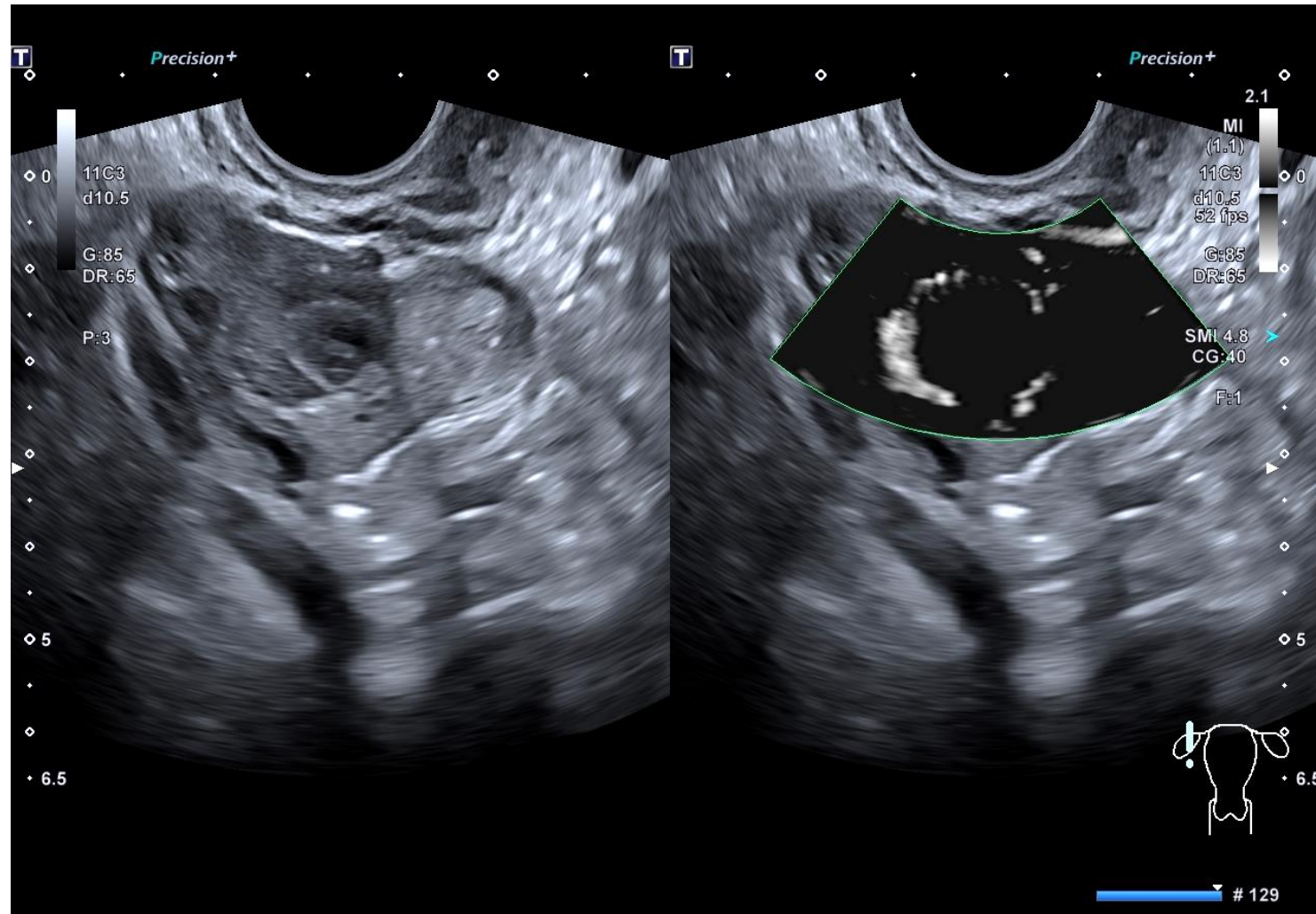
Ectopic Pregnancy



β hCG 13u

Location / Status : Tubal Miscarriage

Ectopic Pregnancy

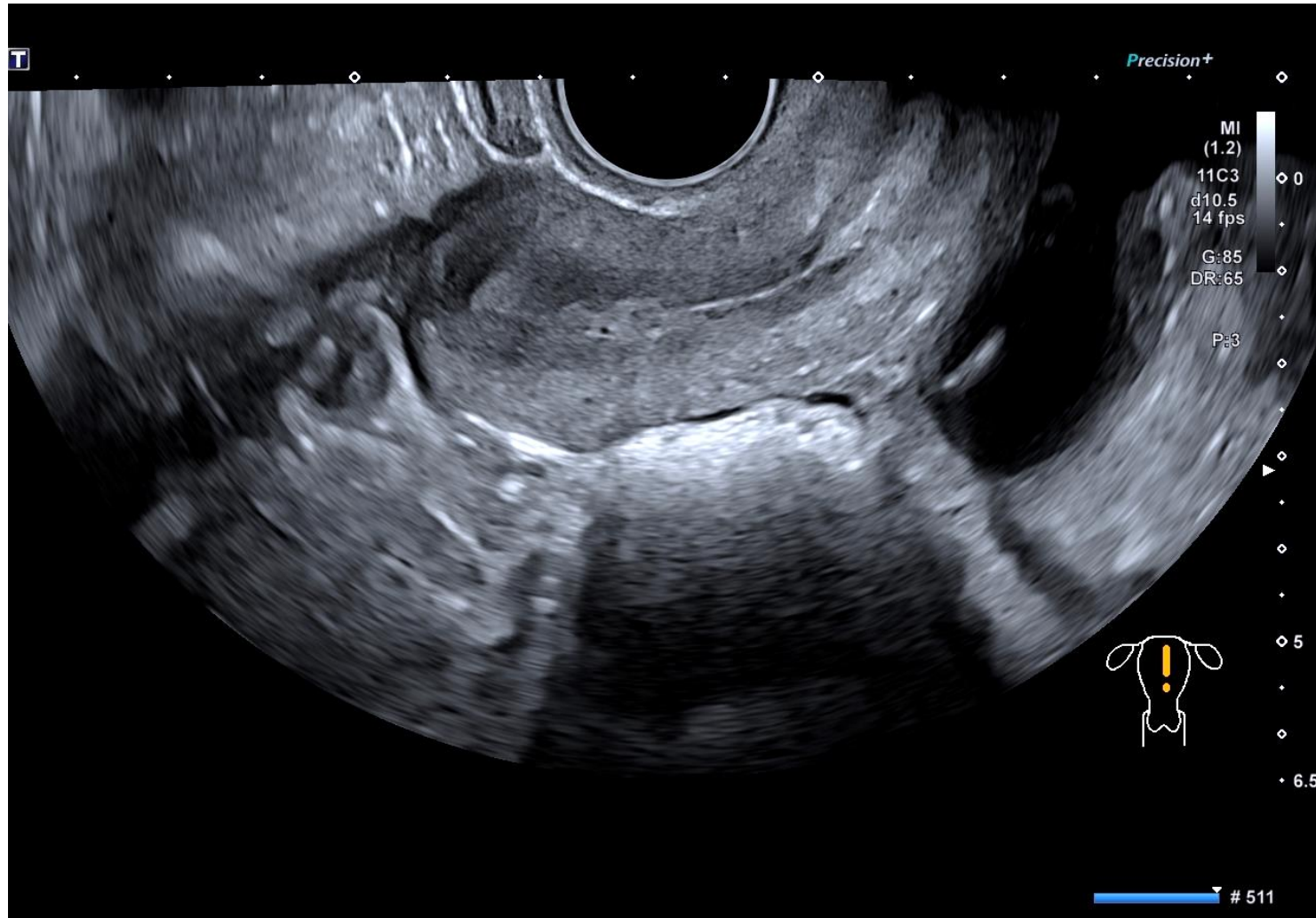


β hCG 13u

Location / Status : Tubal Miscarriage

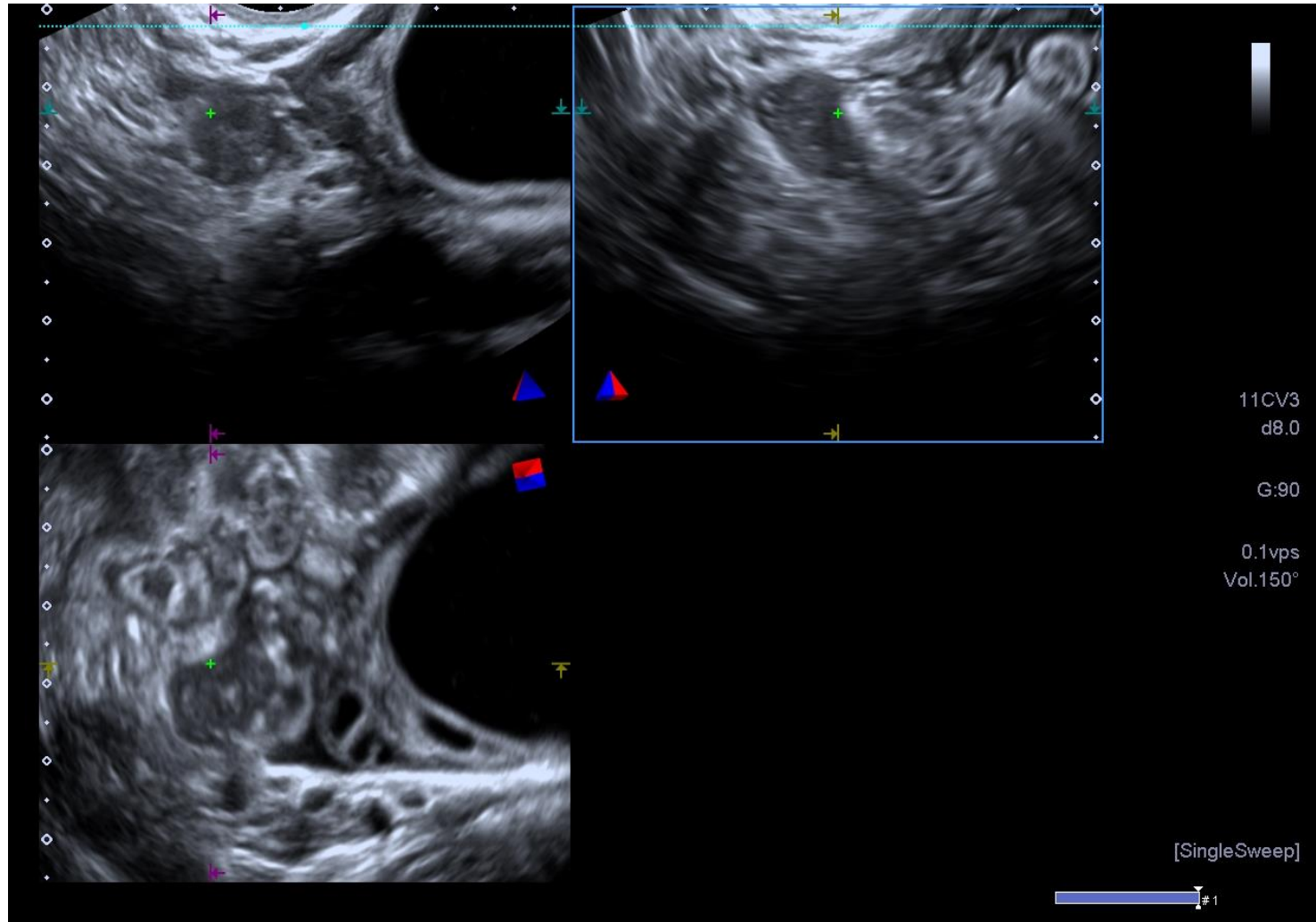
Case 1D

Ectopic Pregnancy



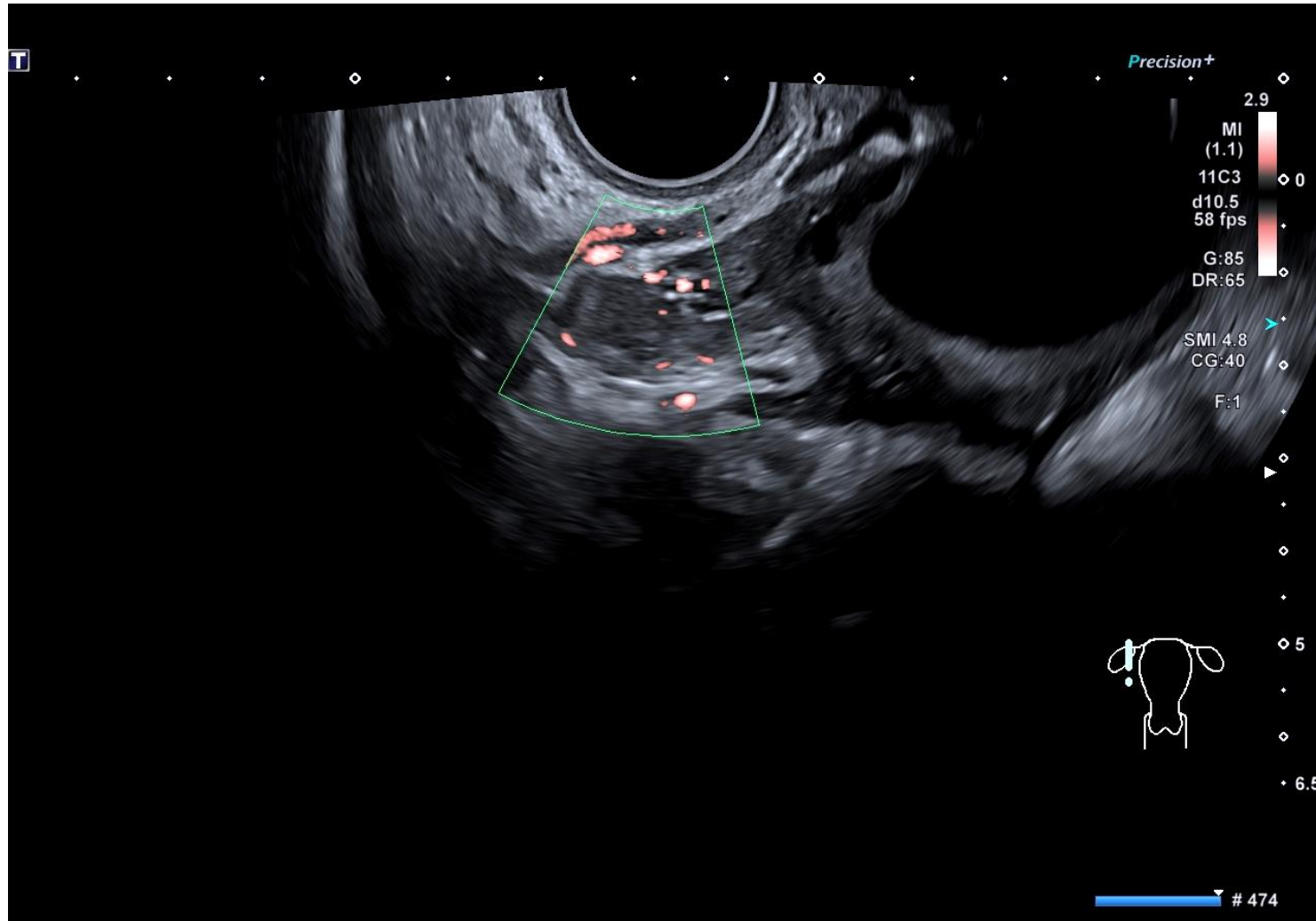
Location / Status : Tubal Miscarriage

Ectopic Pregnancy



Location / Status : Tubal Miscarriage

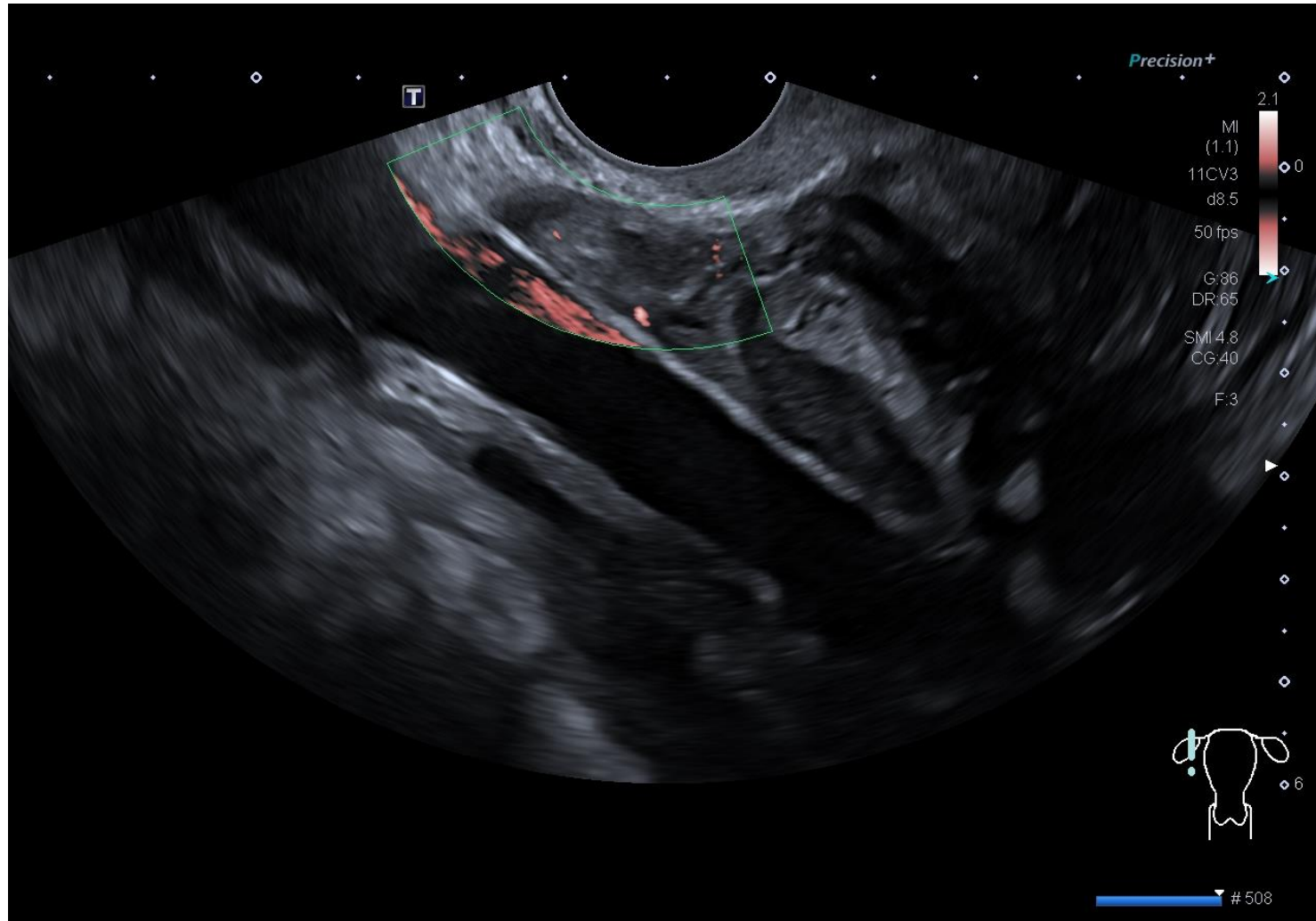
Ectopic Pregnancy



β hCG 43u

Location / Status : Tubal Miscarriage

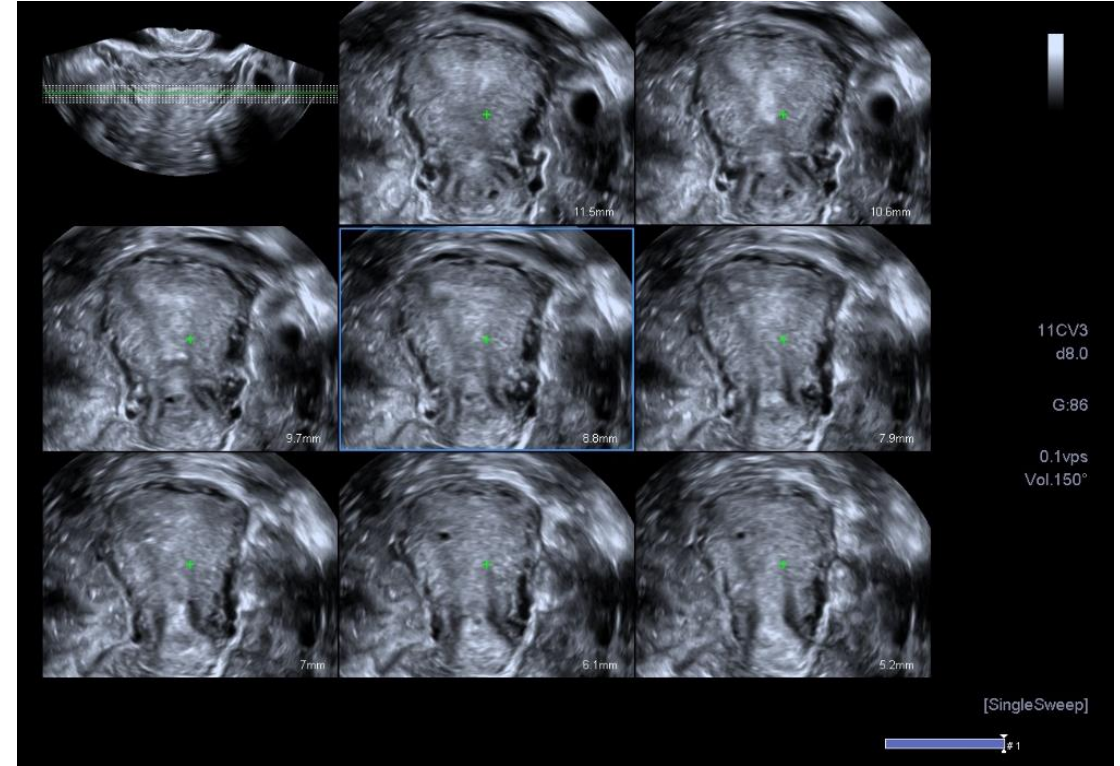
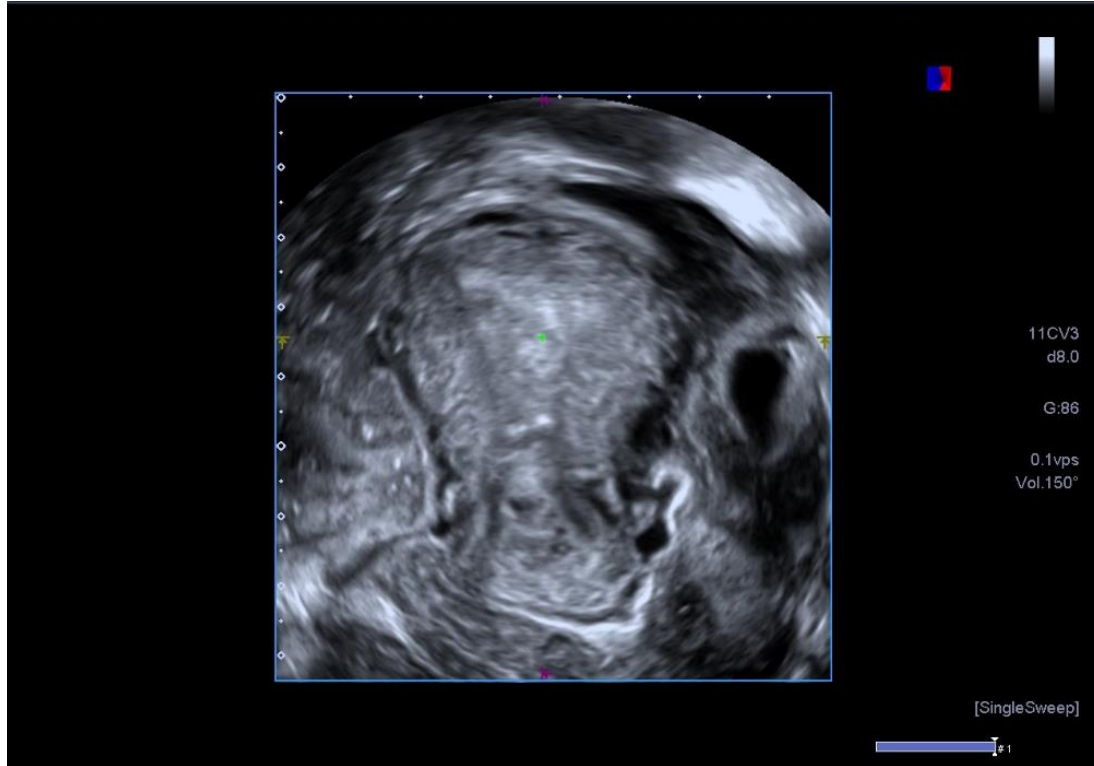
Ectopic Pregnancy



β hCG 45u

Location / Status : Tubal Miscarriage

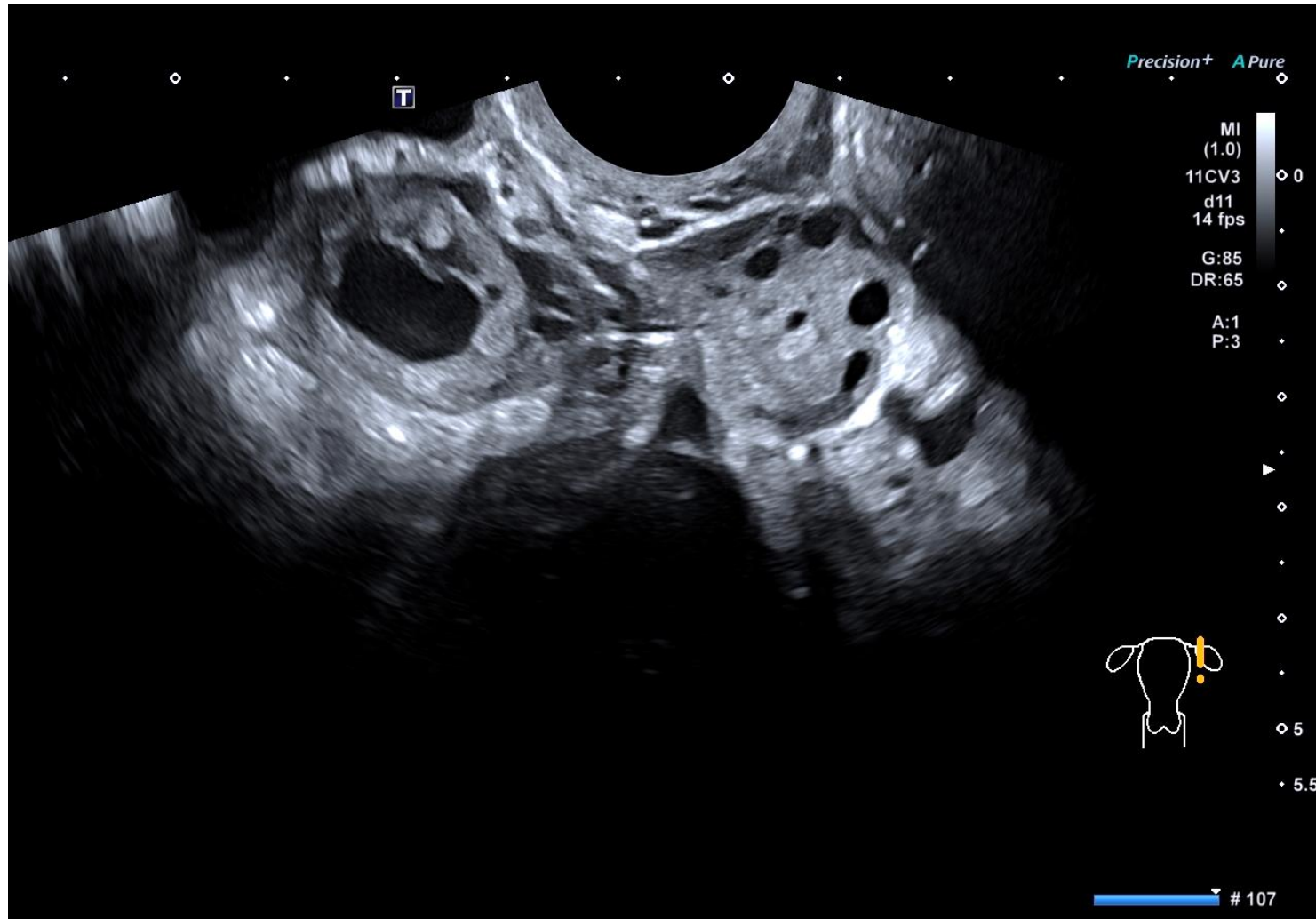
Ectopic Pregnancy



Location / Status : Tubal Miscarriage

Case 4A

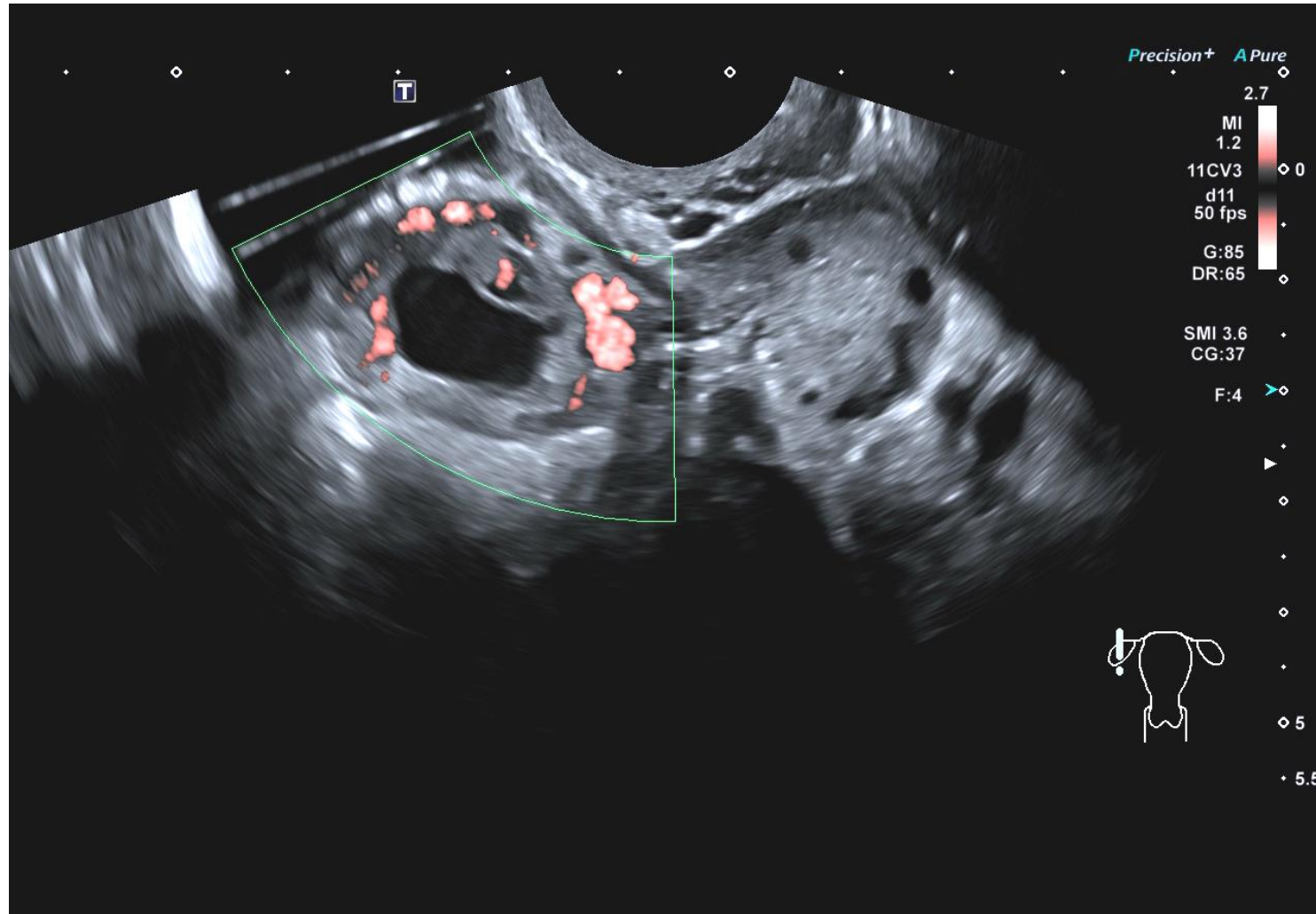
Ectopic Pregnancy



β hCG 11,845u

Location / Status : Tubal Miscarriage

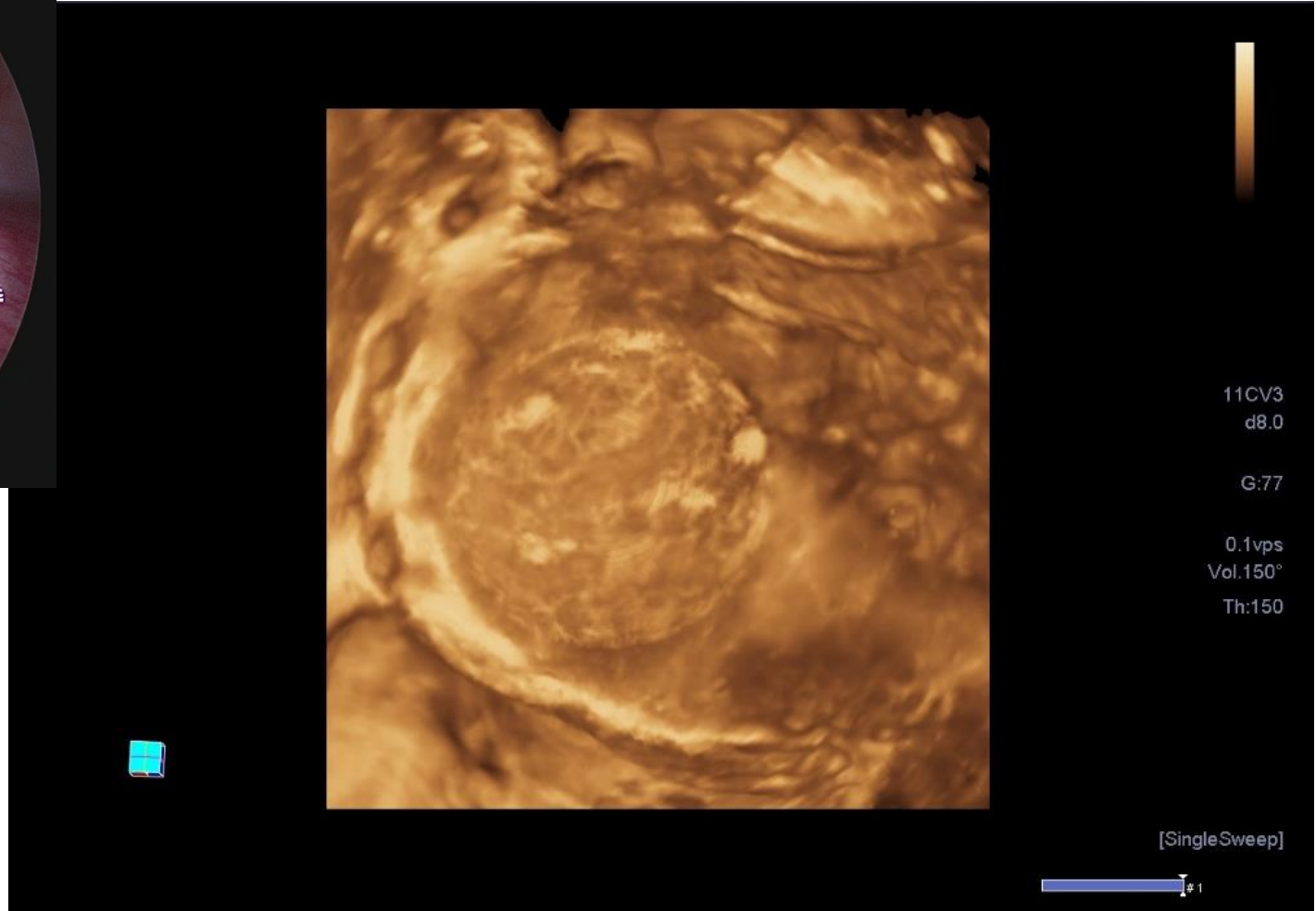
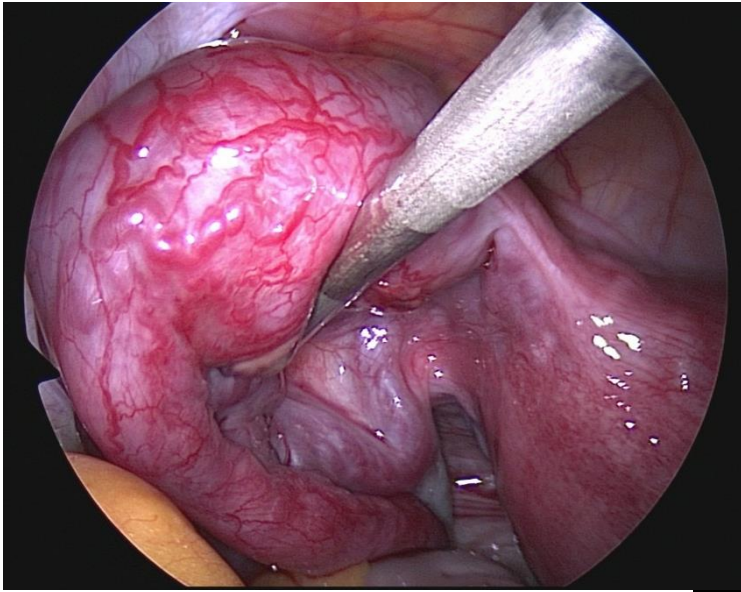
Ectopic Pregnancy



β hCG 11,845u

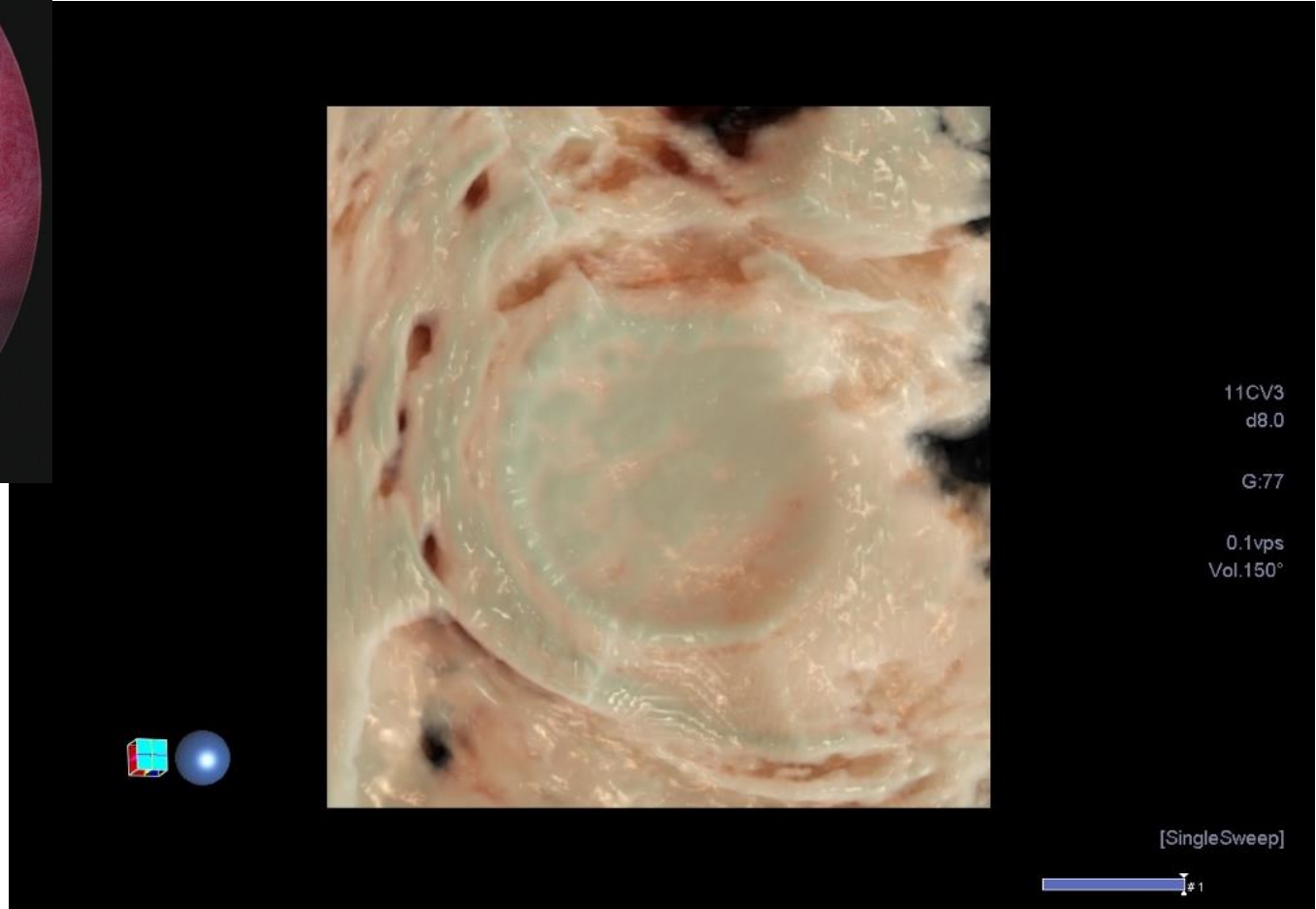
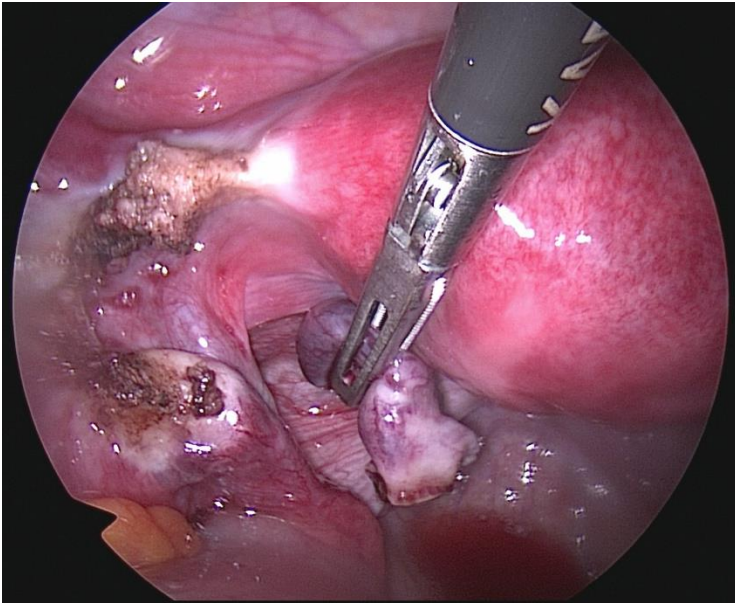
Location / Status : Tubal Miscarriage

Ectopic Pregnancy



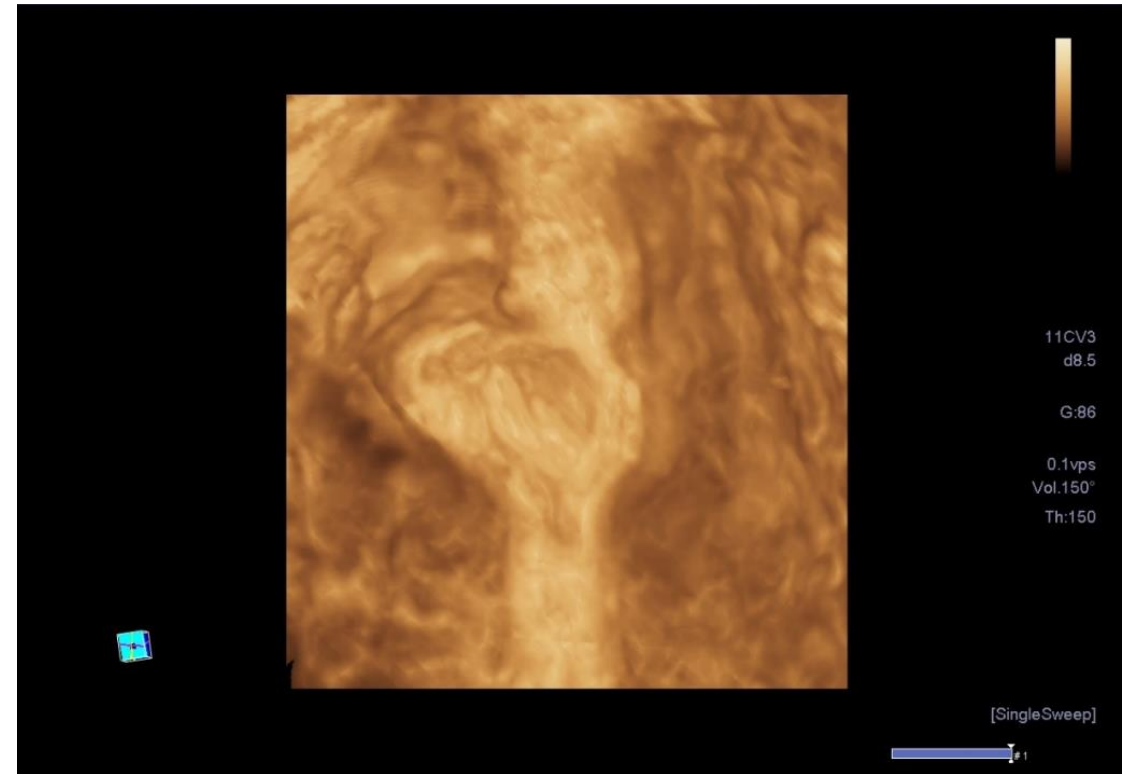
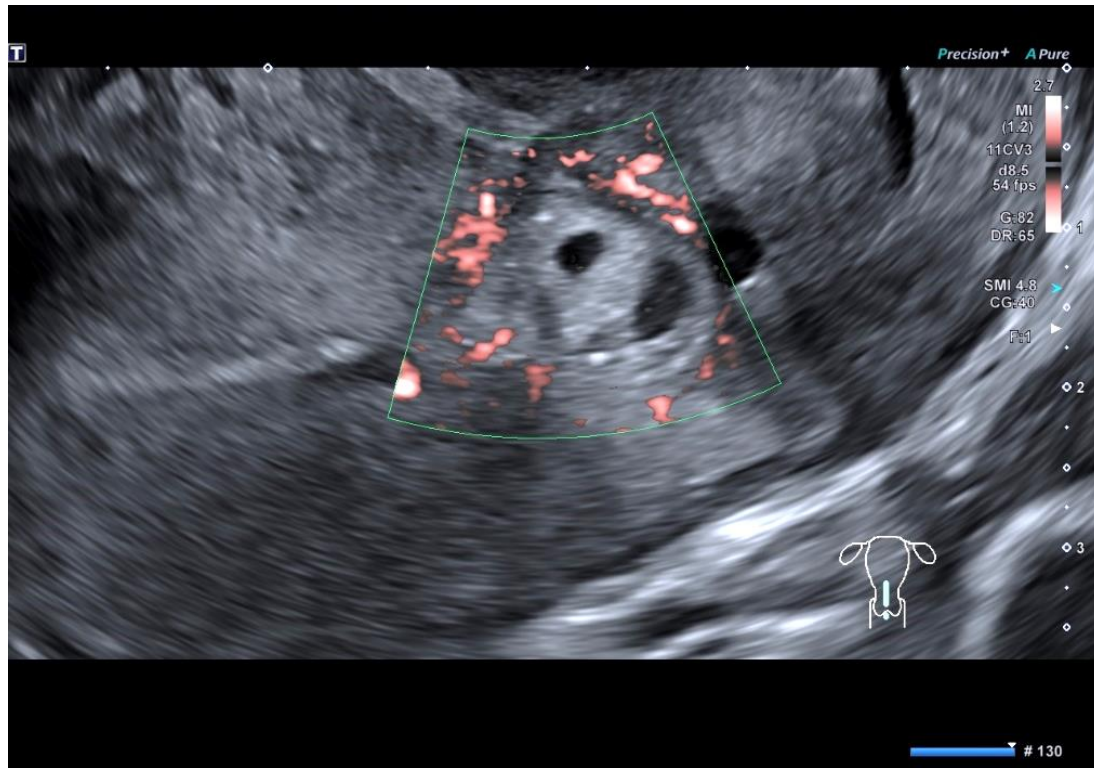
Location / Status : Tubal Miscarriage

Ectopic Pregnancy



Location / Status : Tubal Miscarriage

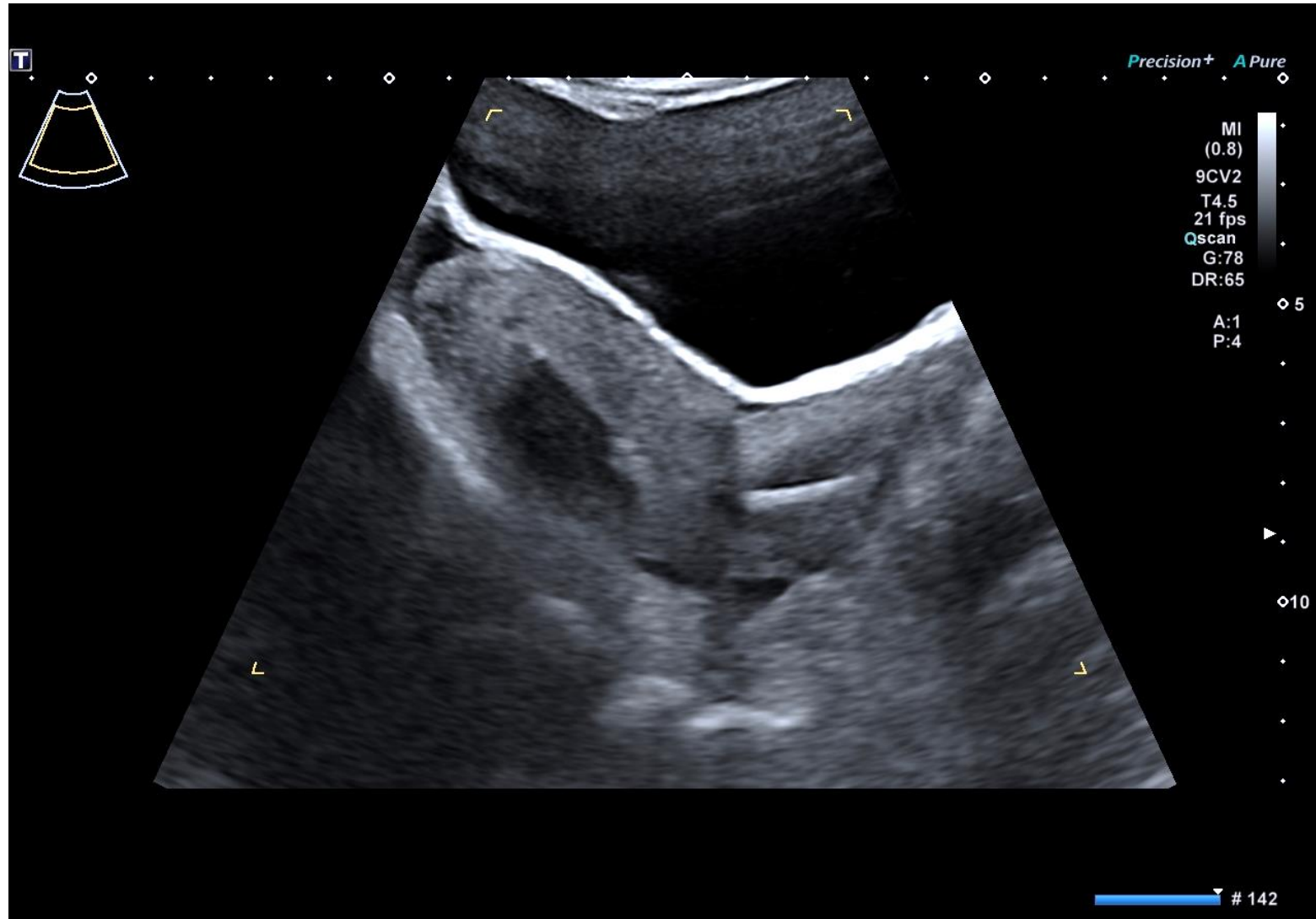
Ectopic Pregnancy



Location : CS Scar

TVS vs TAS Ultraound

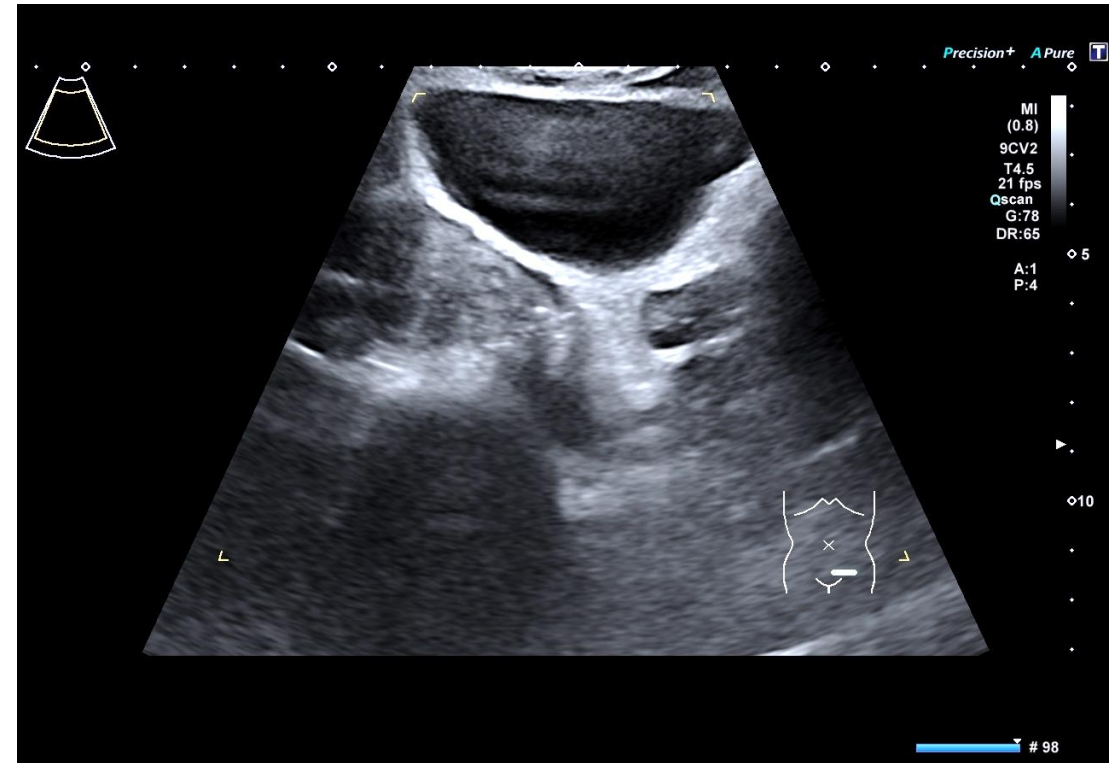
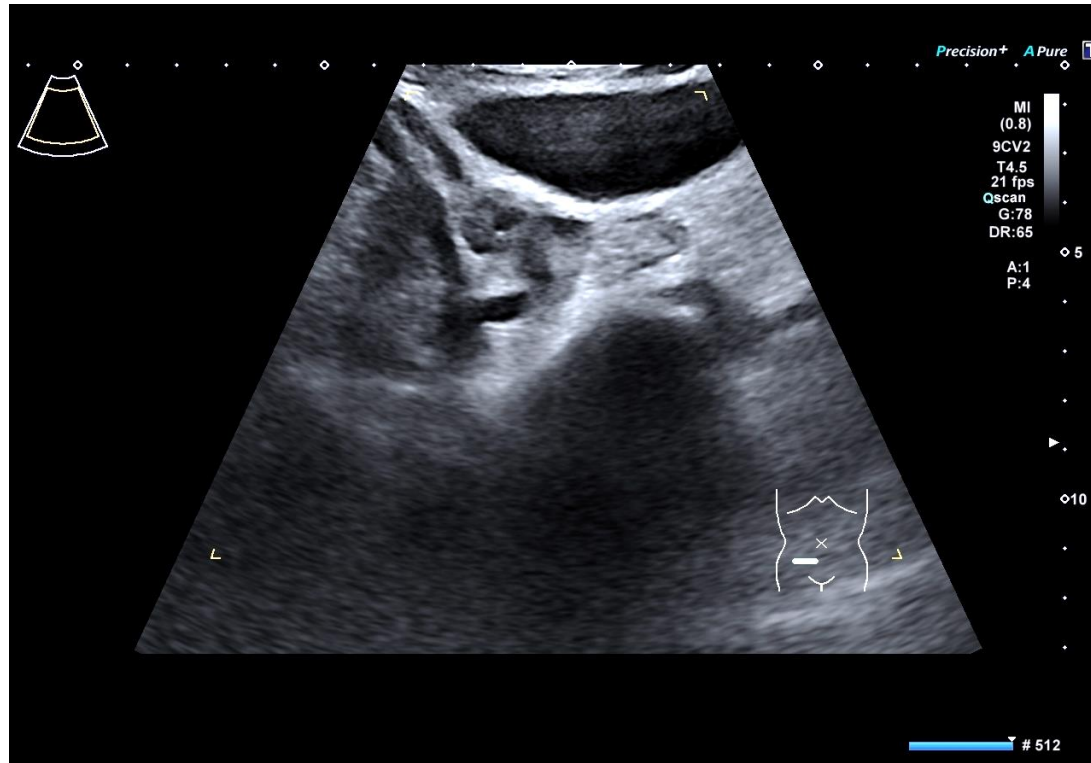
TAS



Abnormal pv bleeding - IUS

TVS vs TAS Ultraound

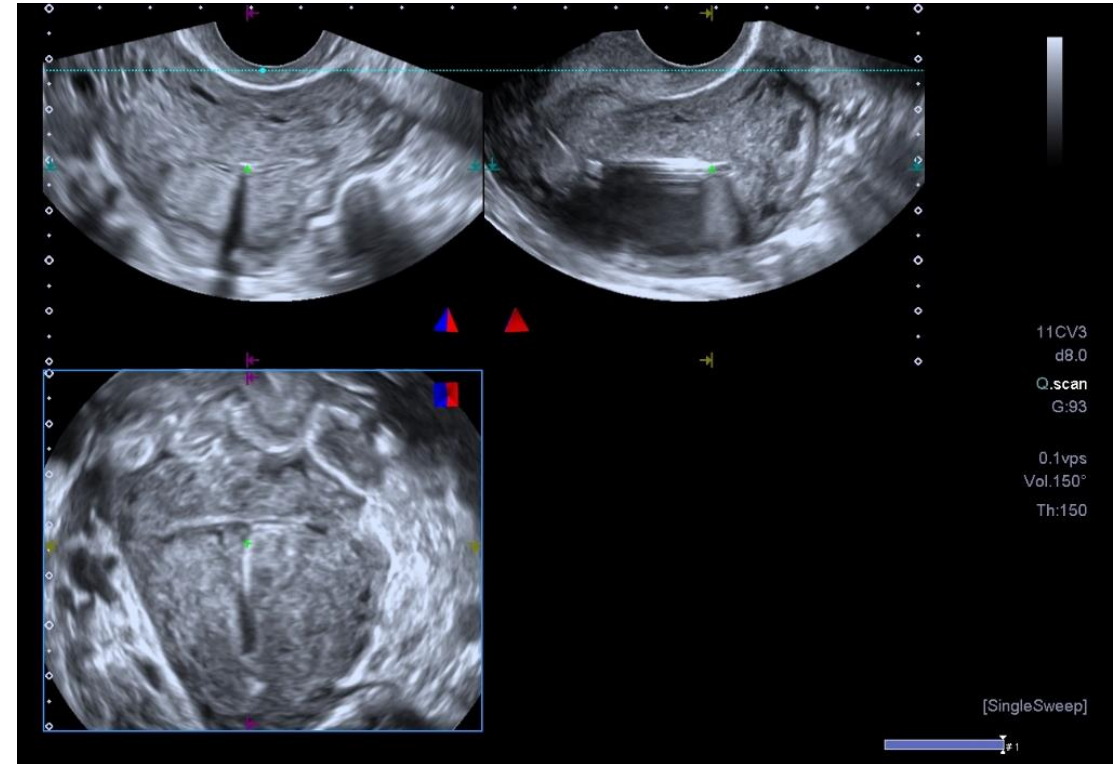
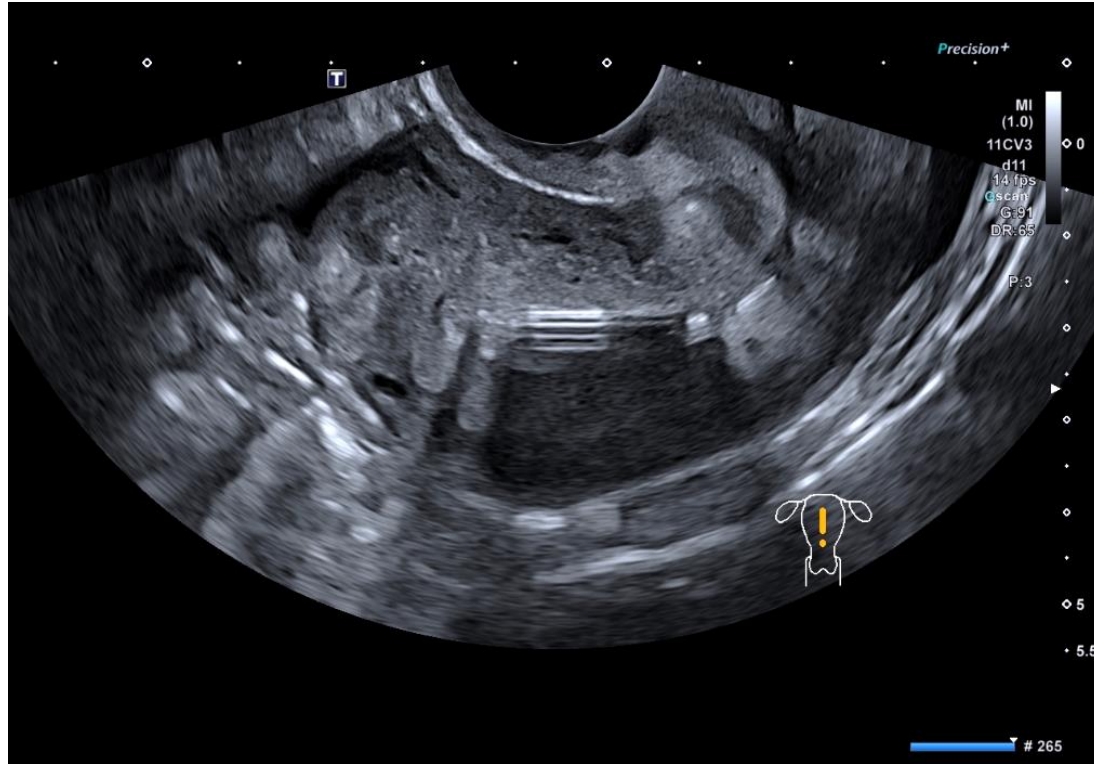
TAS



Abnormal pv bleeding - IUS

TVS vs TAS Ultraound

TVS

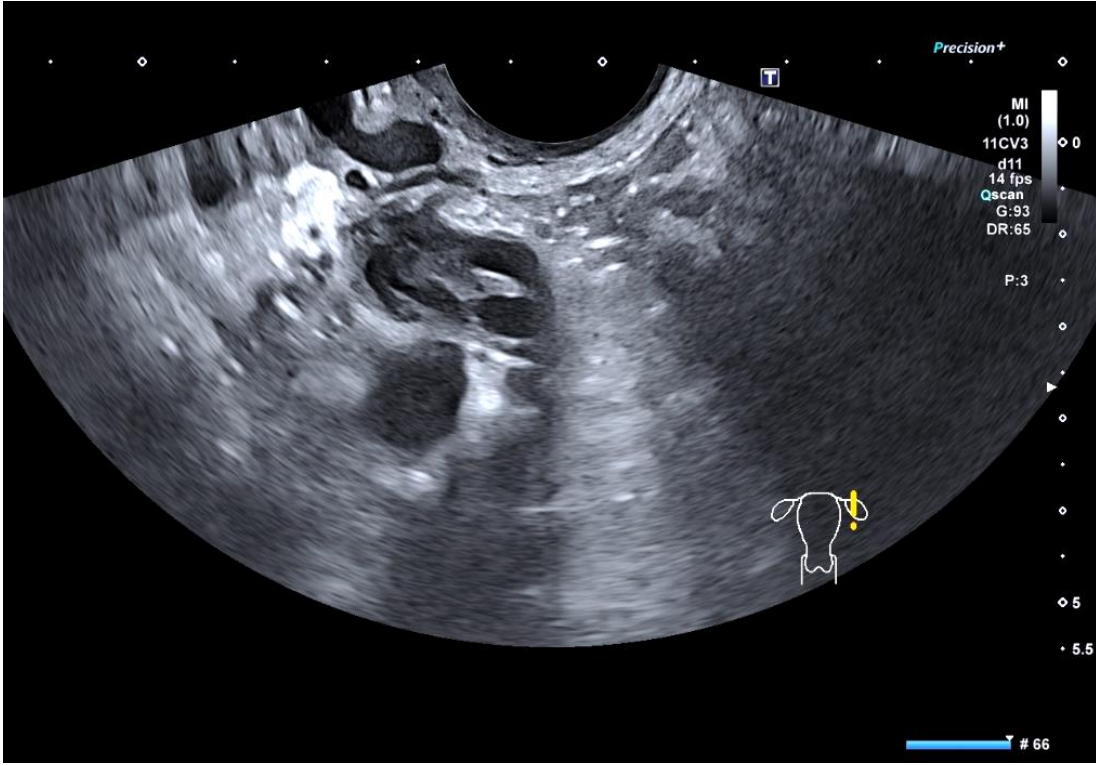
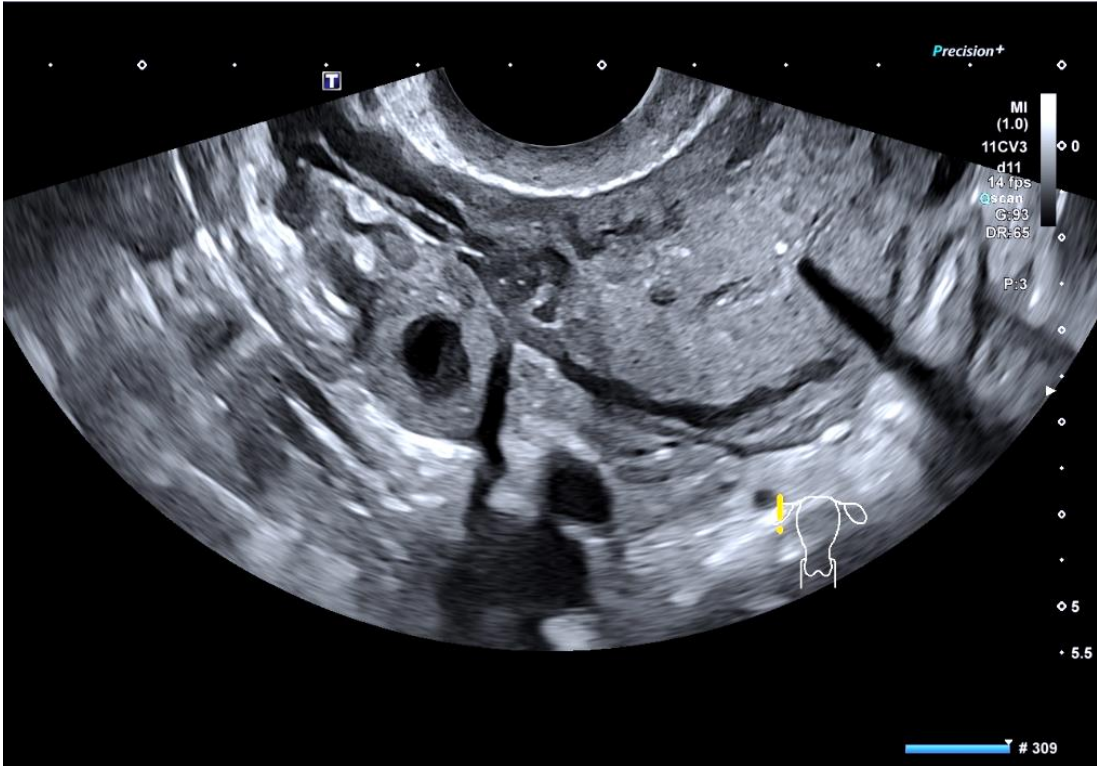


Abnormal pv bleeding - IUS

TVS vs TAS Ultraound



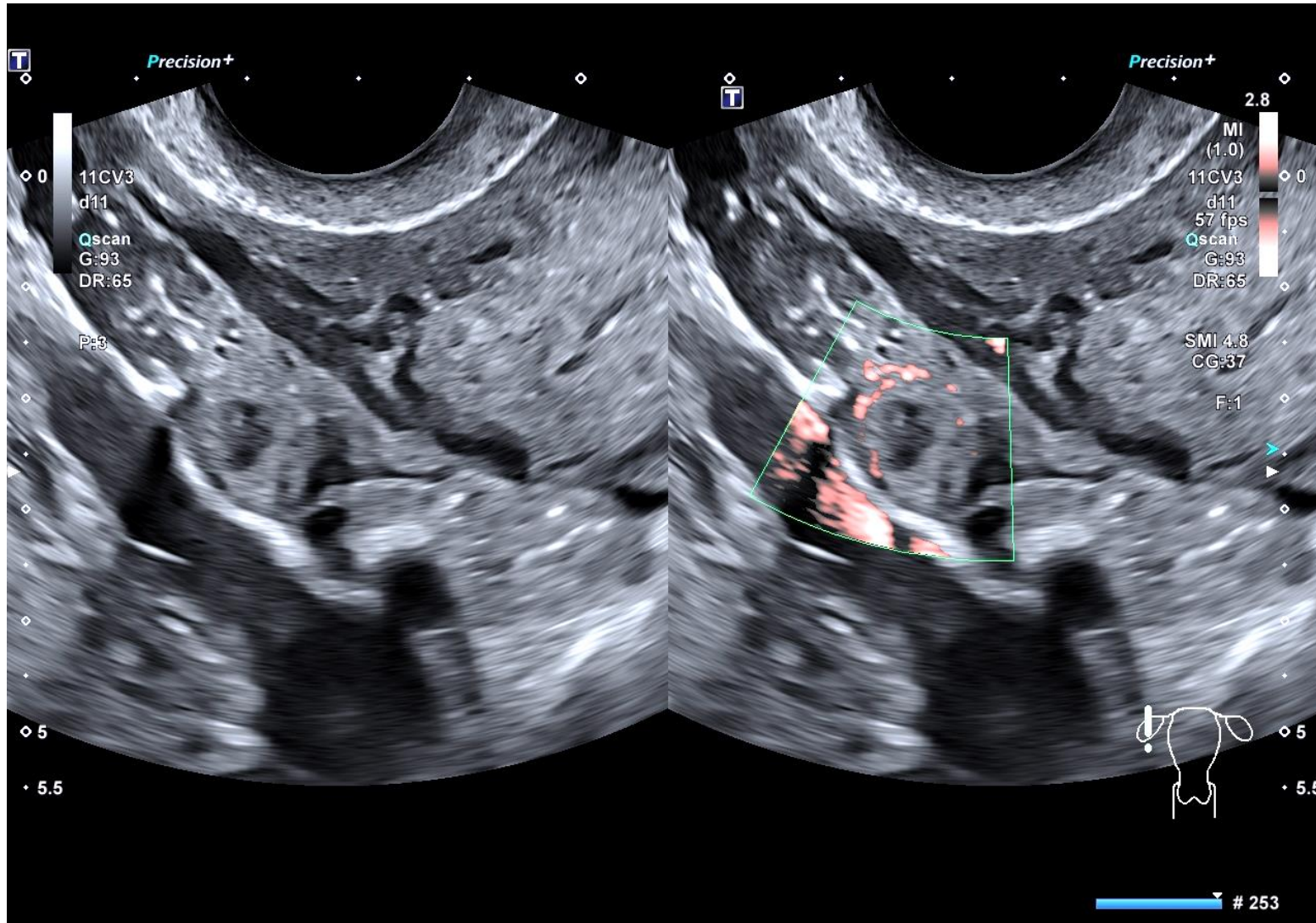
TVS



TVS vs TAS Ultraound



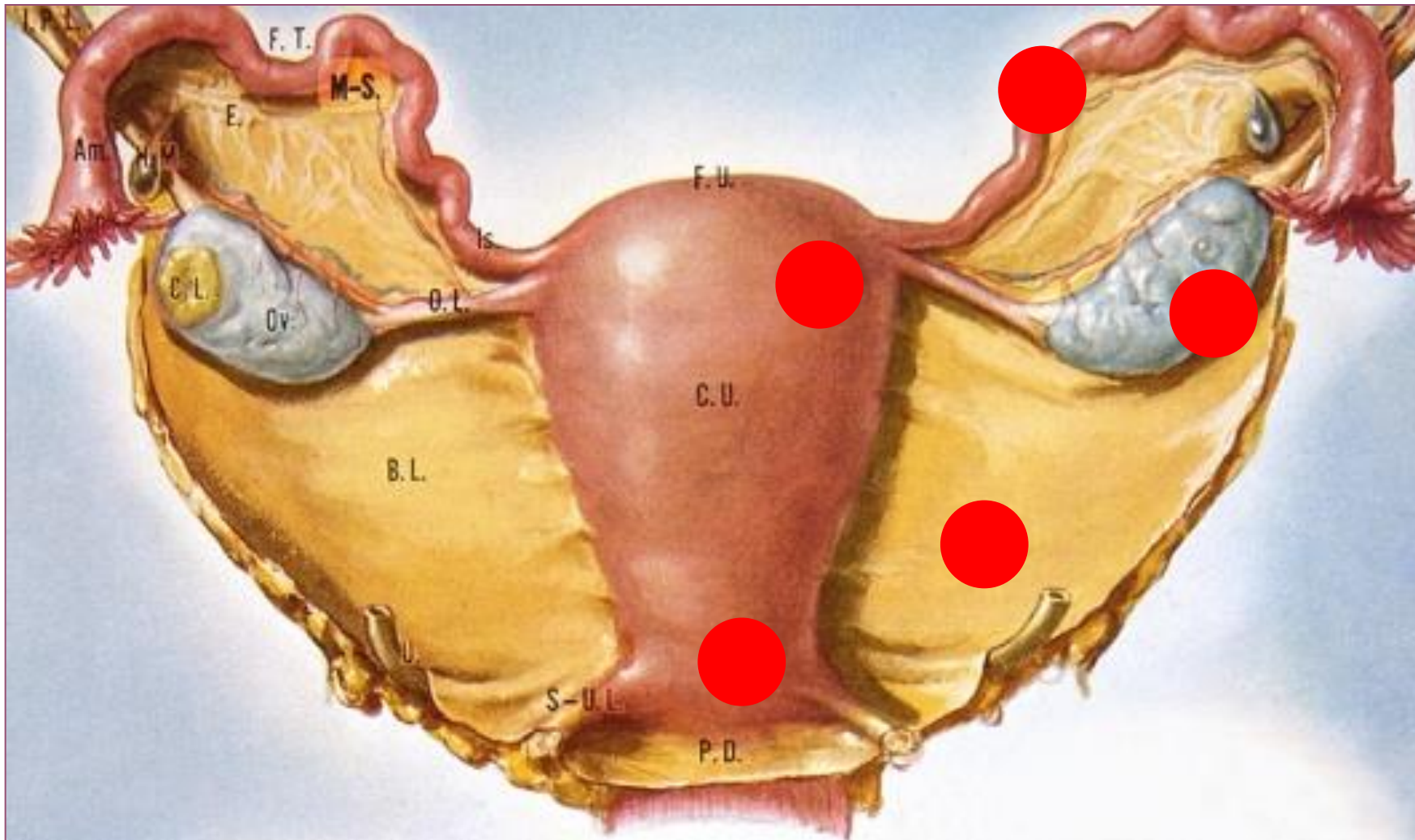
TVS



Tubal Miscarriage
 β hCG 257iu

Abnormal pv bleeding - IUS

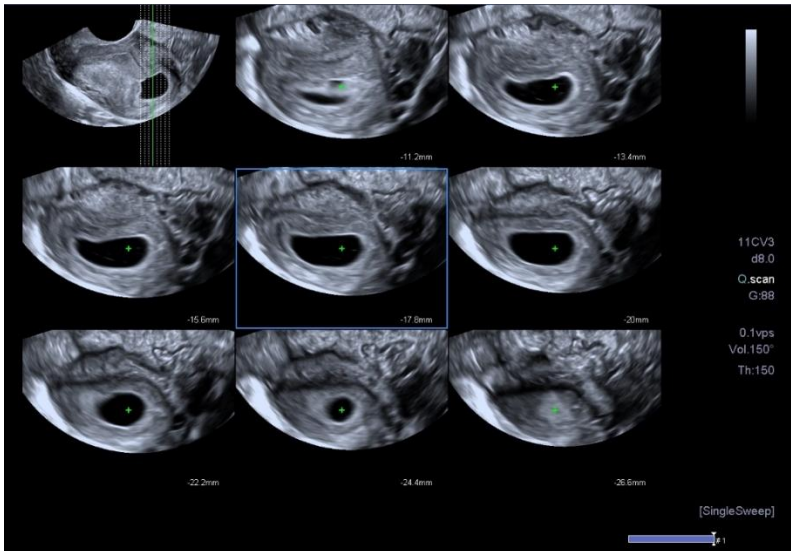
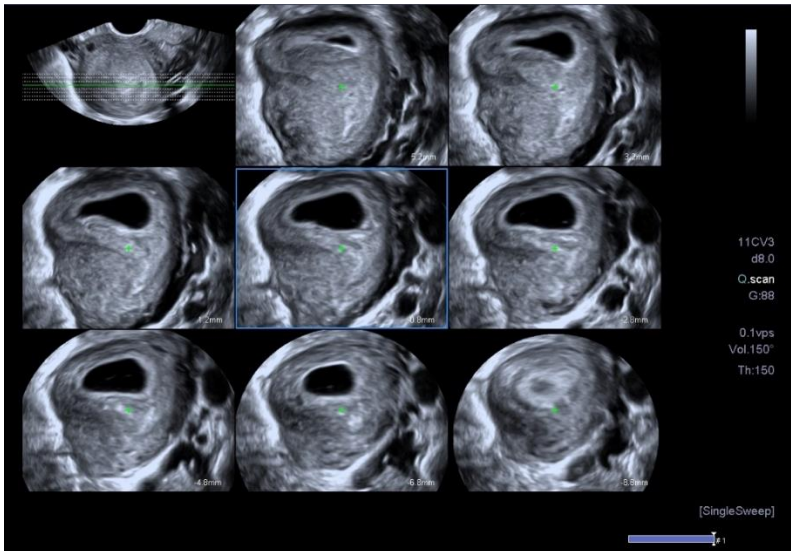
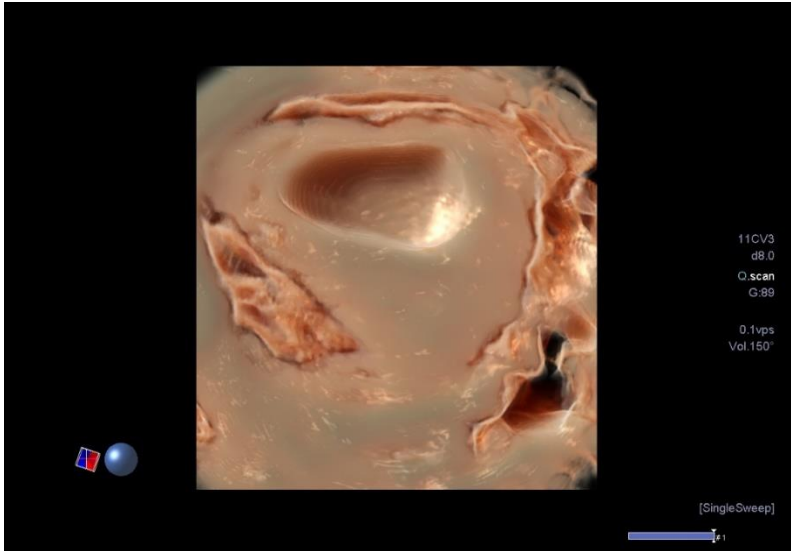
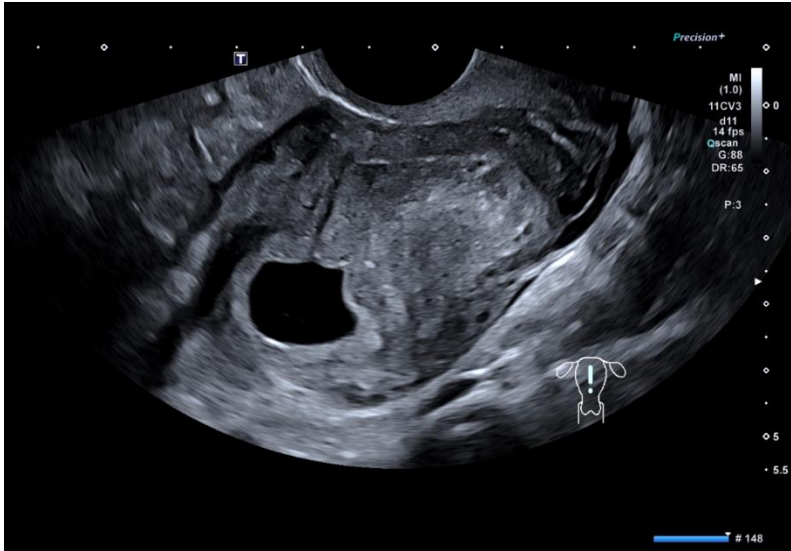
Ectopic Pregnancy



- 2D / 3D TVS
- CDI
- Exclude CL
- Strict protocols PUL
- Clinical alert
- Serial β -hCG + TVS

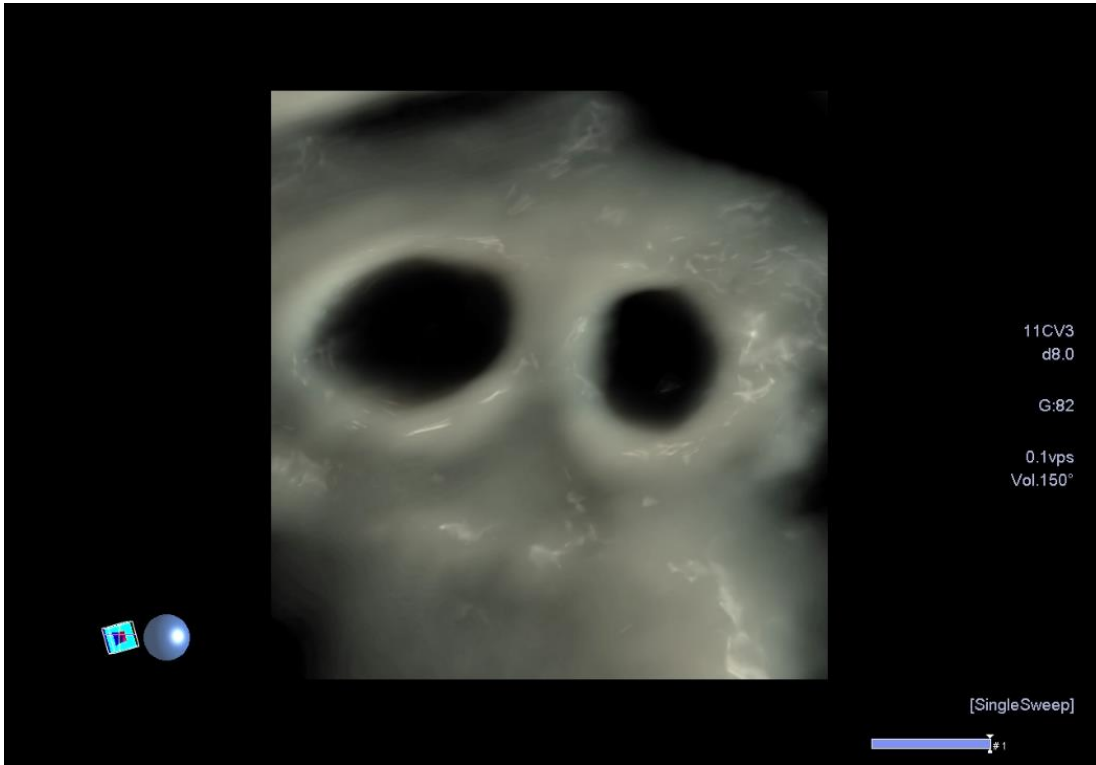
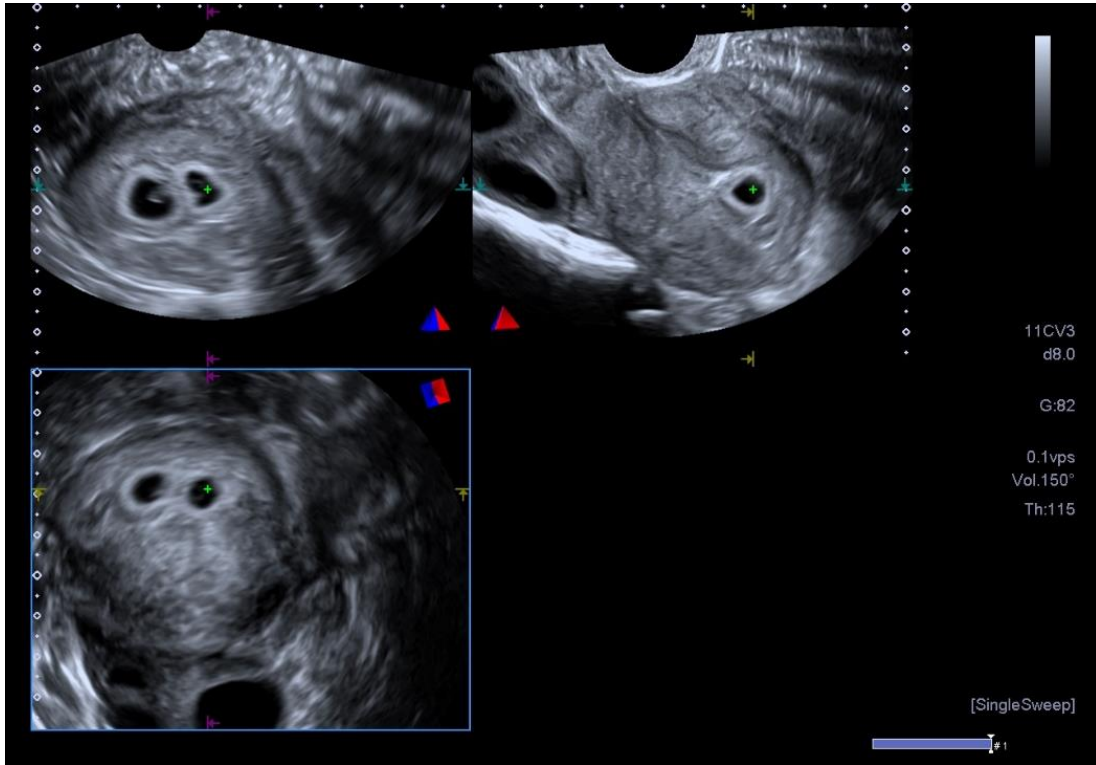
“Vigilance” Location / Status

Multiple Pregnancy



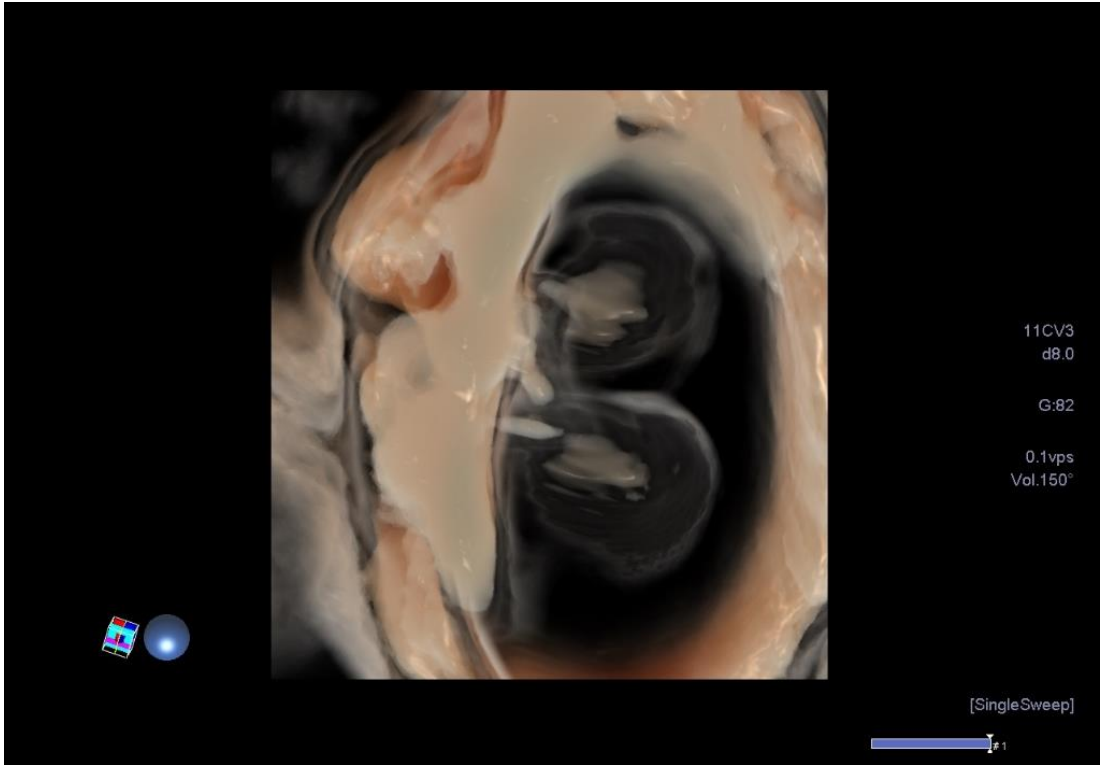
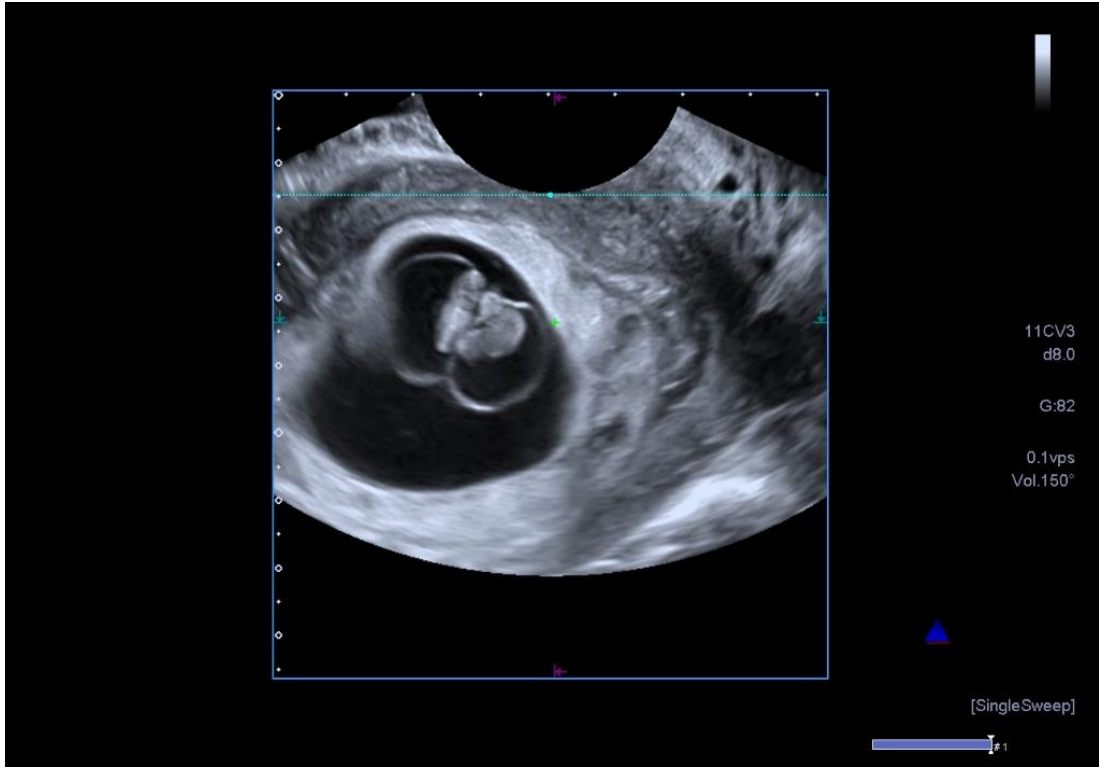
Clinical Gestation
7+ weeks

Multiple Pregnancy



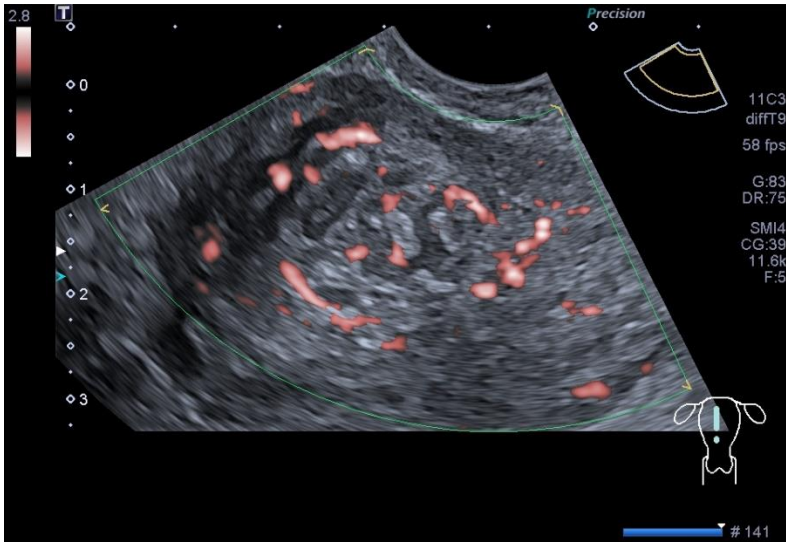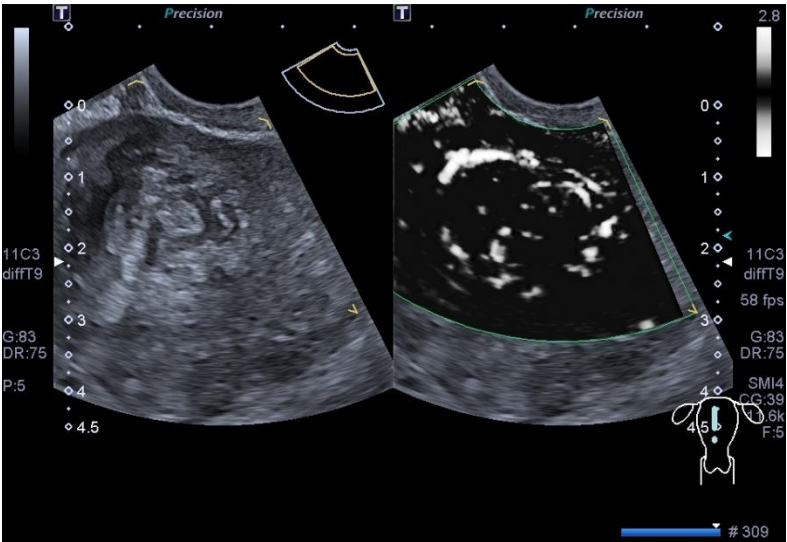
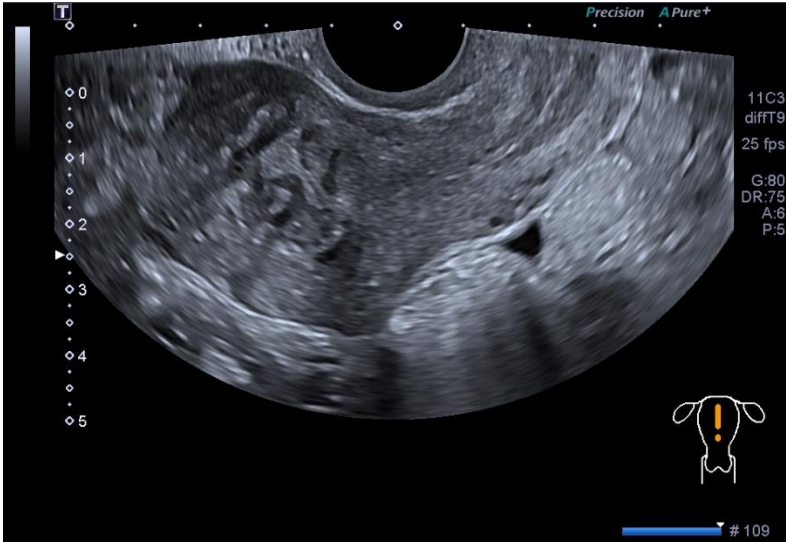
Dichorionic Diamniotic Pregnancy – Clinical Gestation 5 weeks

Multiple Pregnancy

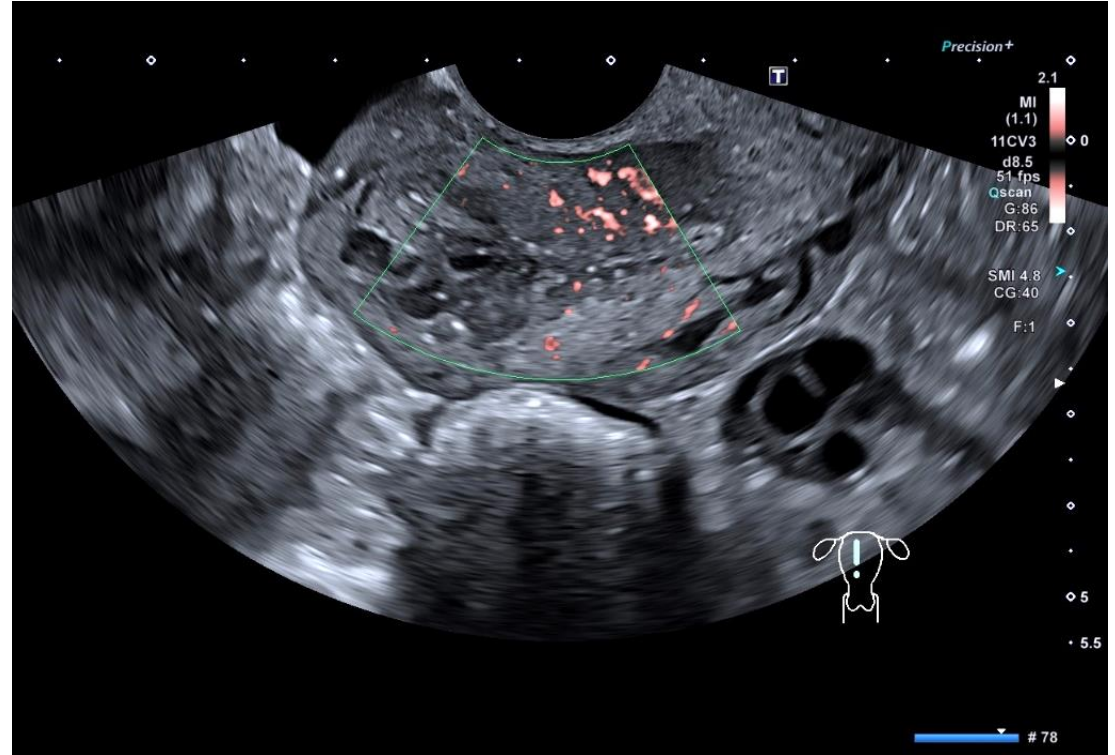
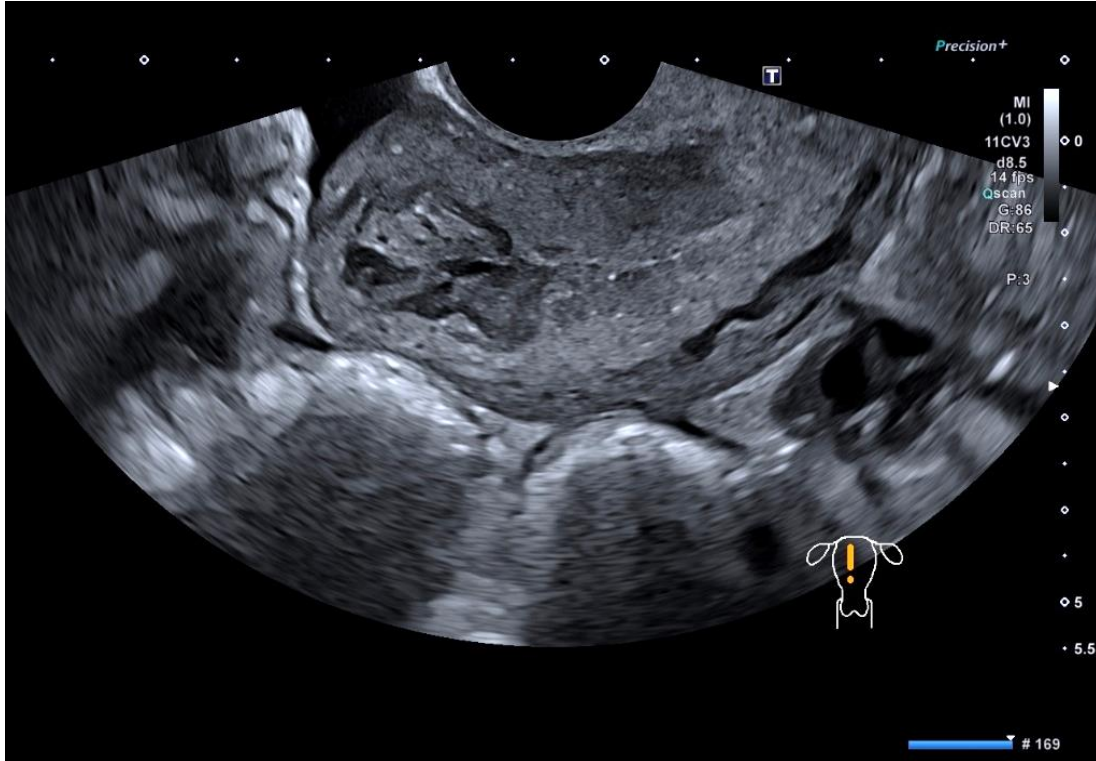


Monochorionic Diamniotic Pregnancy – Clinical Gestation 5+ weeks

RPOC – Post Partum

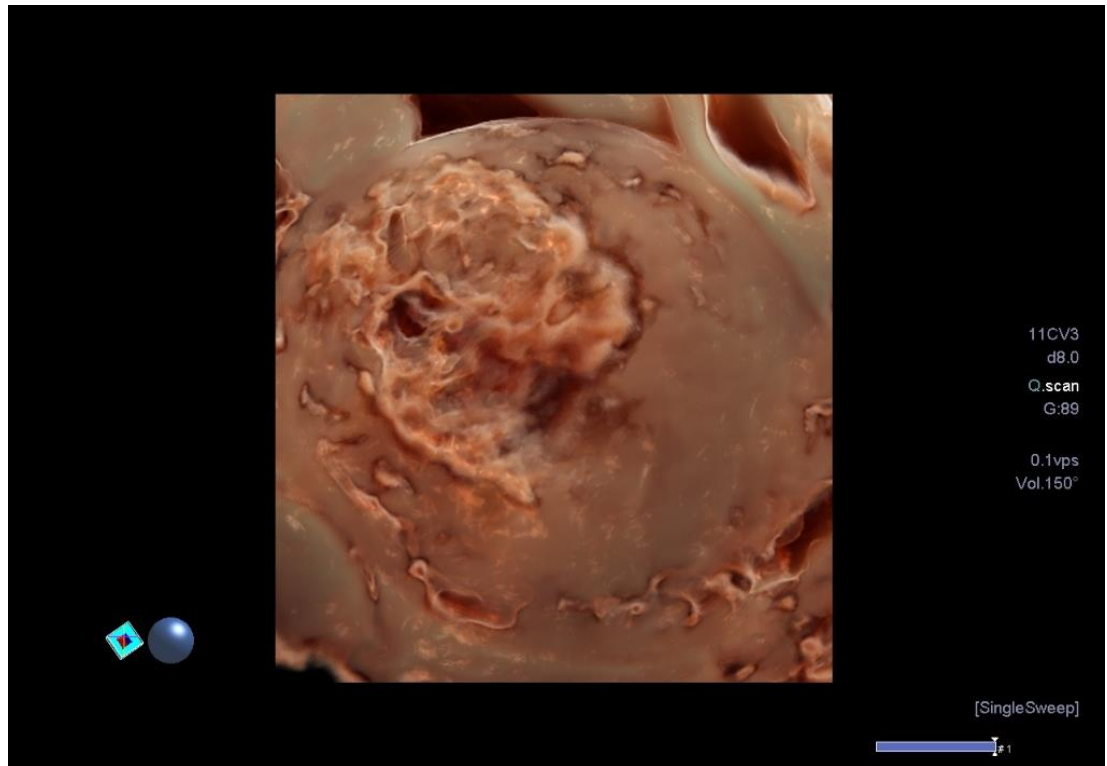
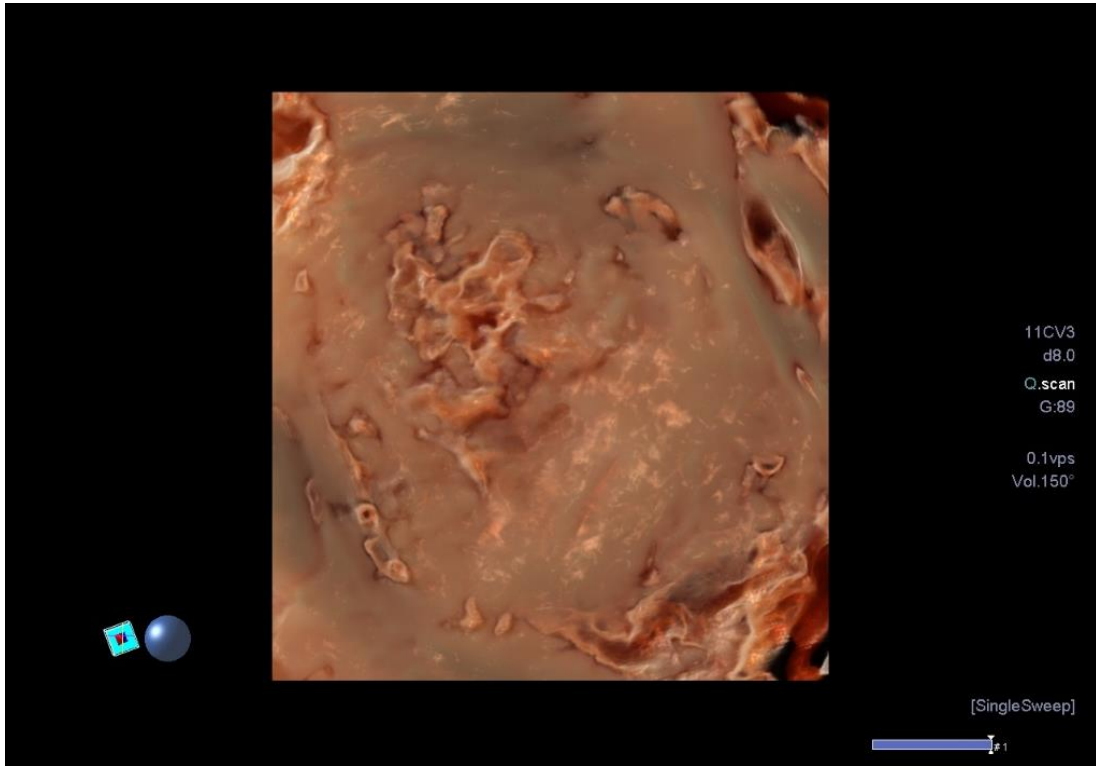


RPOC – Post Partum

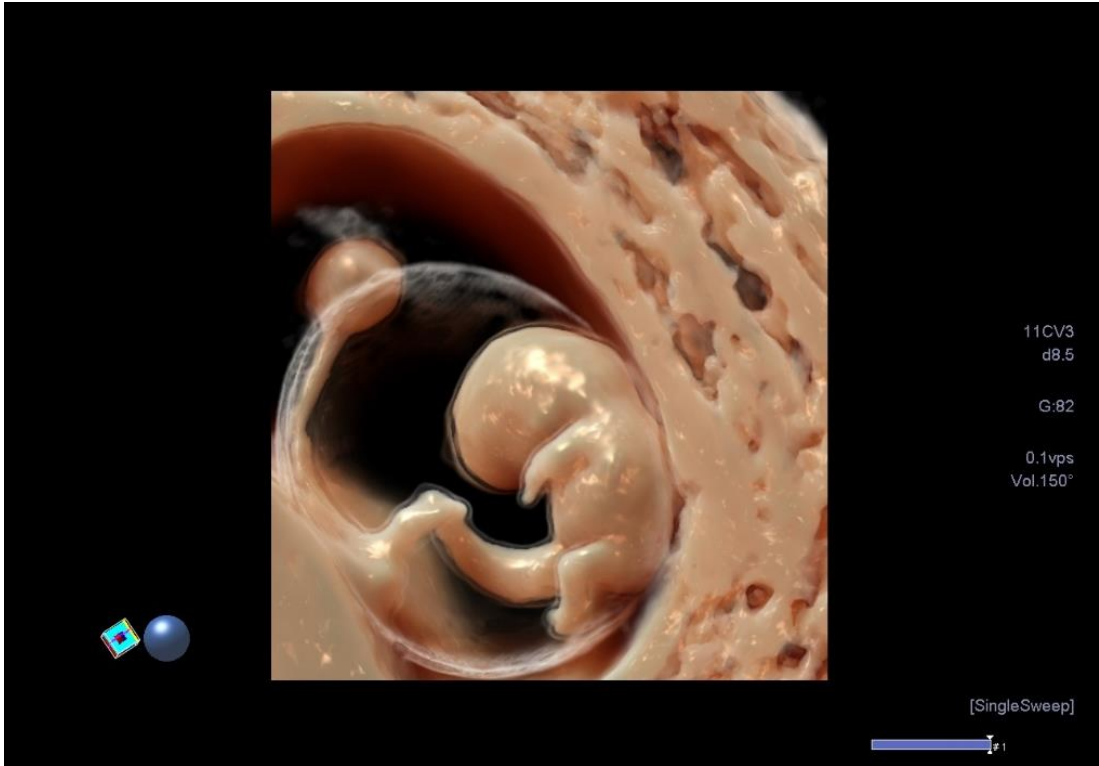
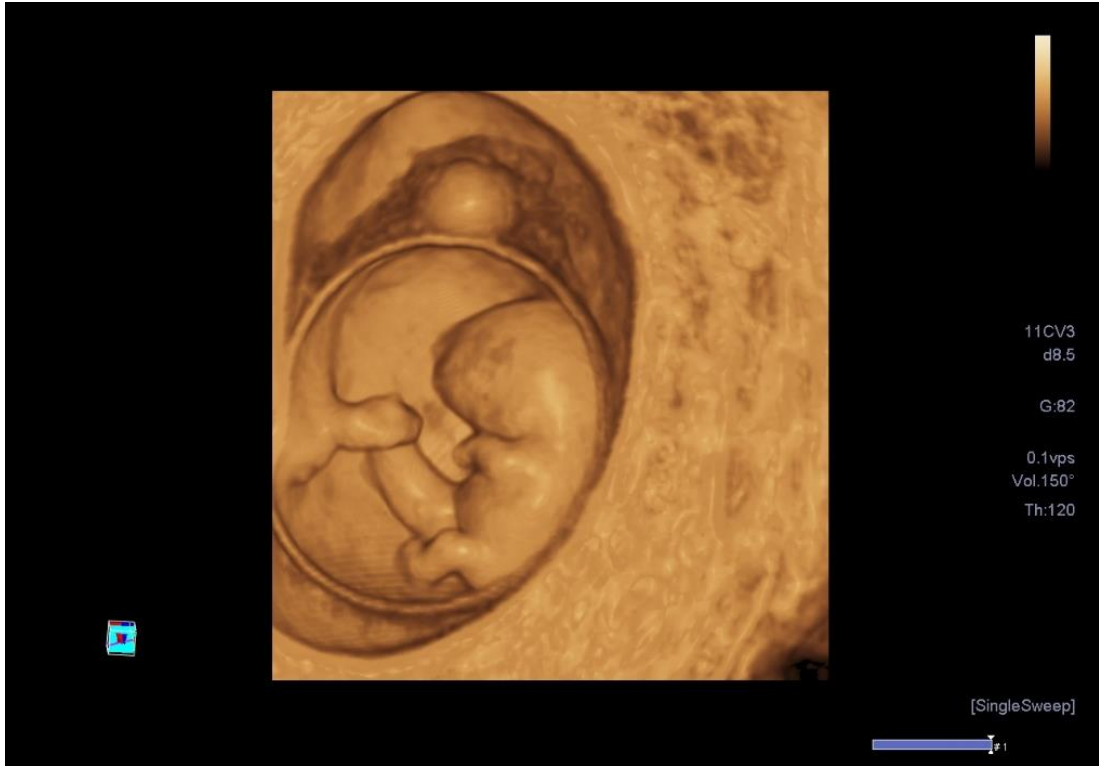


Complications of Early Pregnancy

RPOC – Post Partum

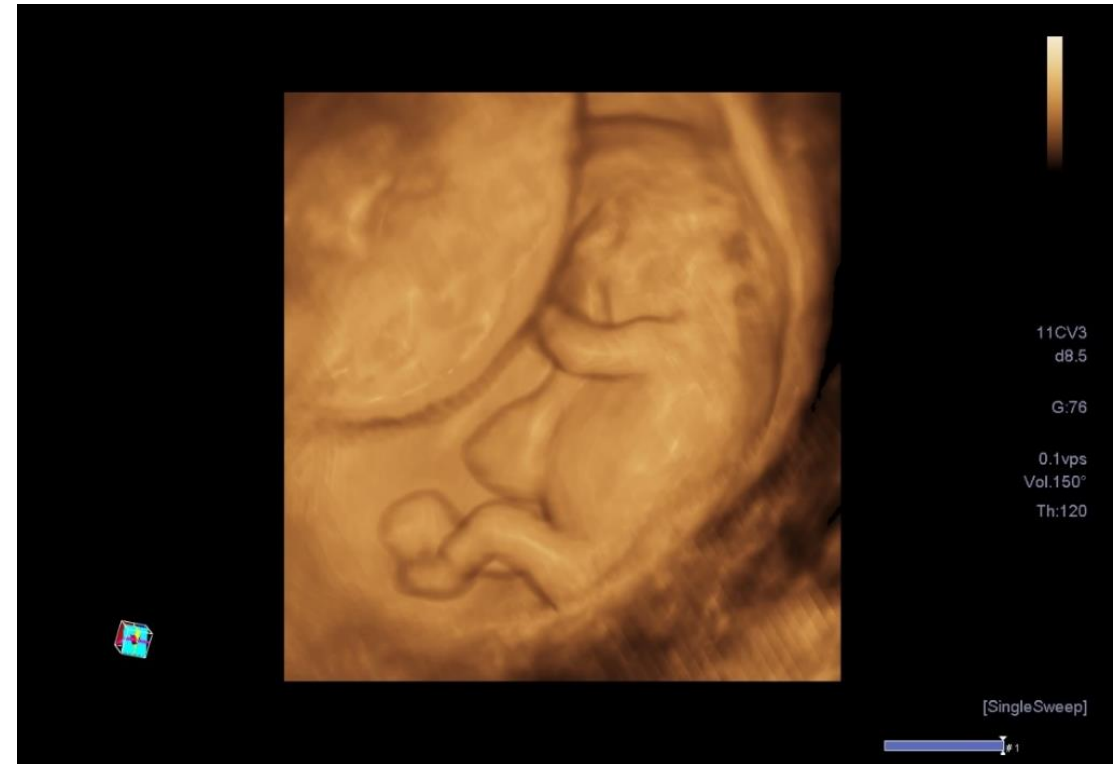
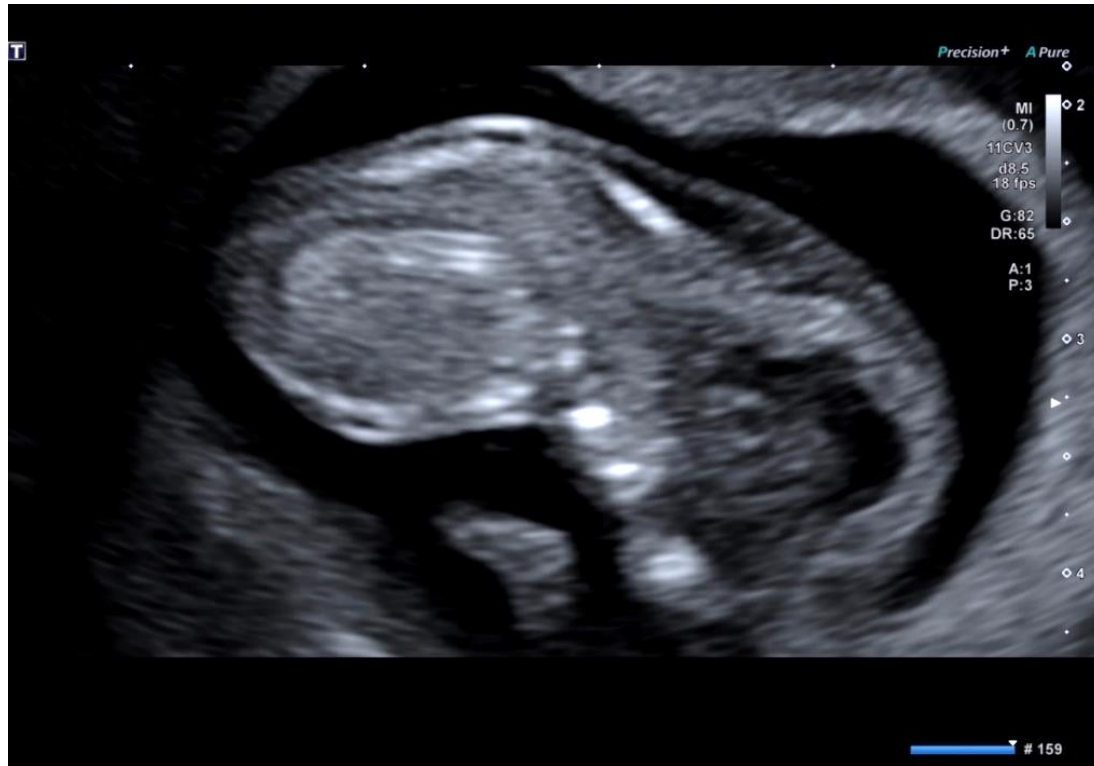

First Trimester Fetal Assessment <10 wks gest.



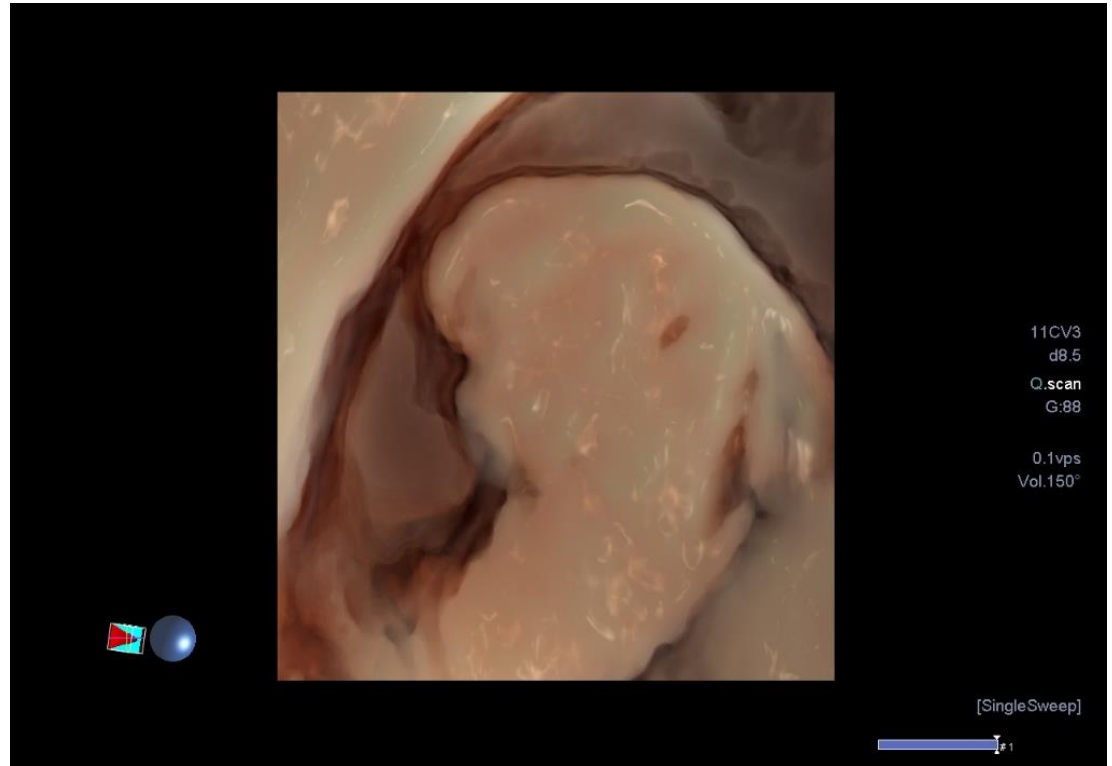
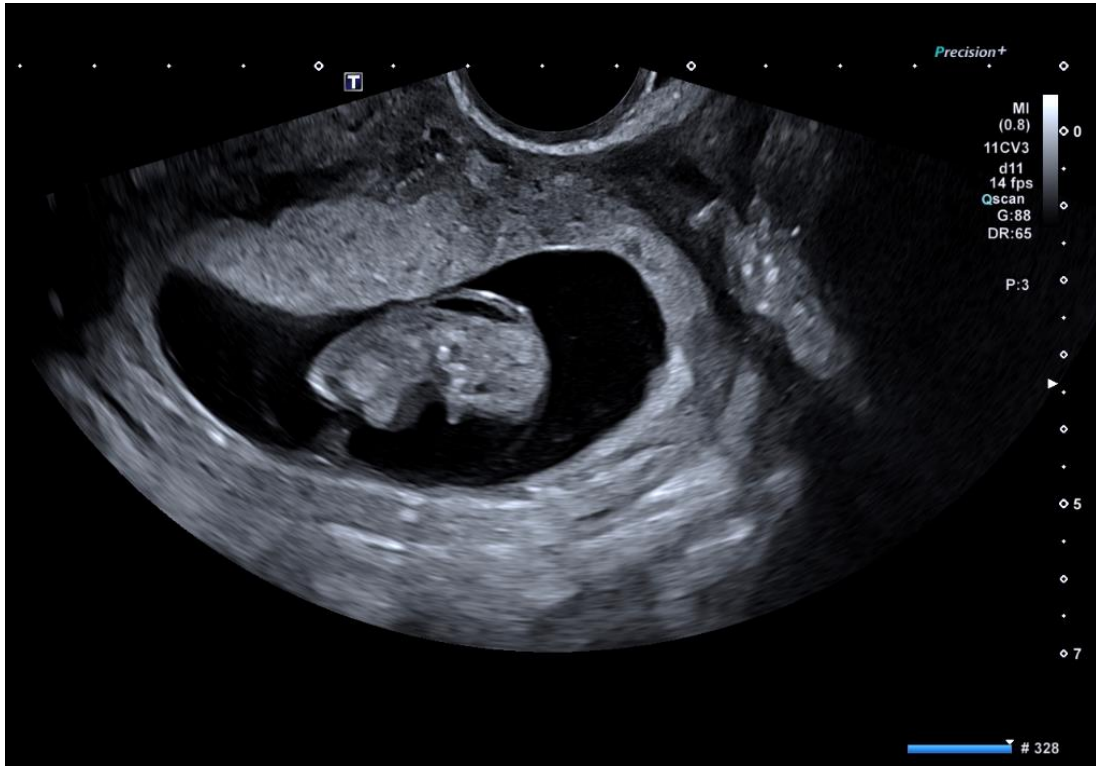
Normal – Clinical Gestation 9+ weeks

First Trimester Fetal Assessment <10 wks gest.

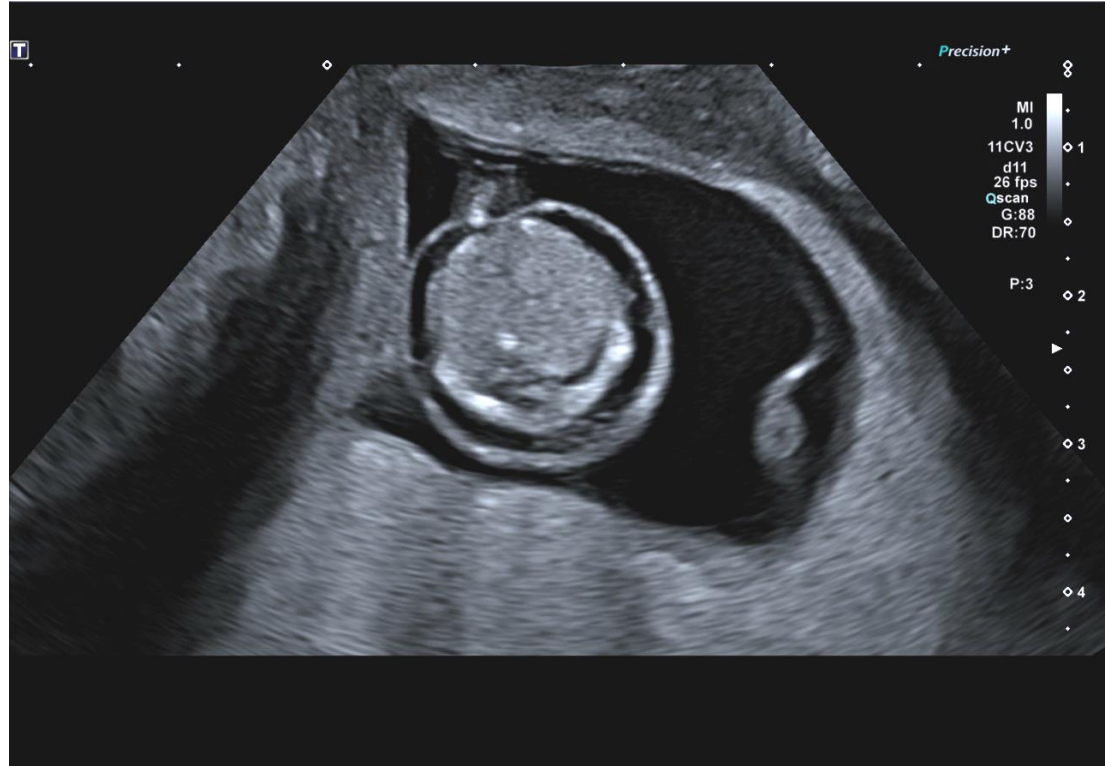
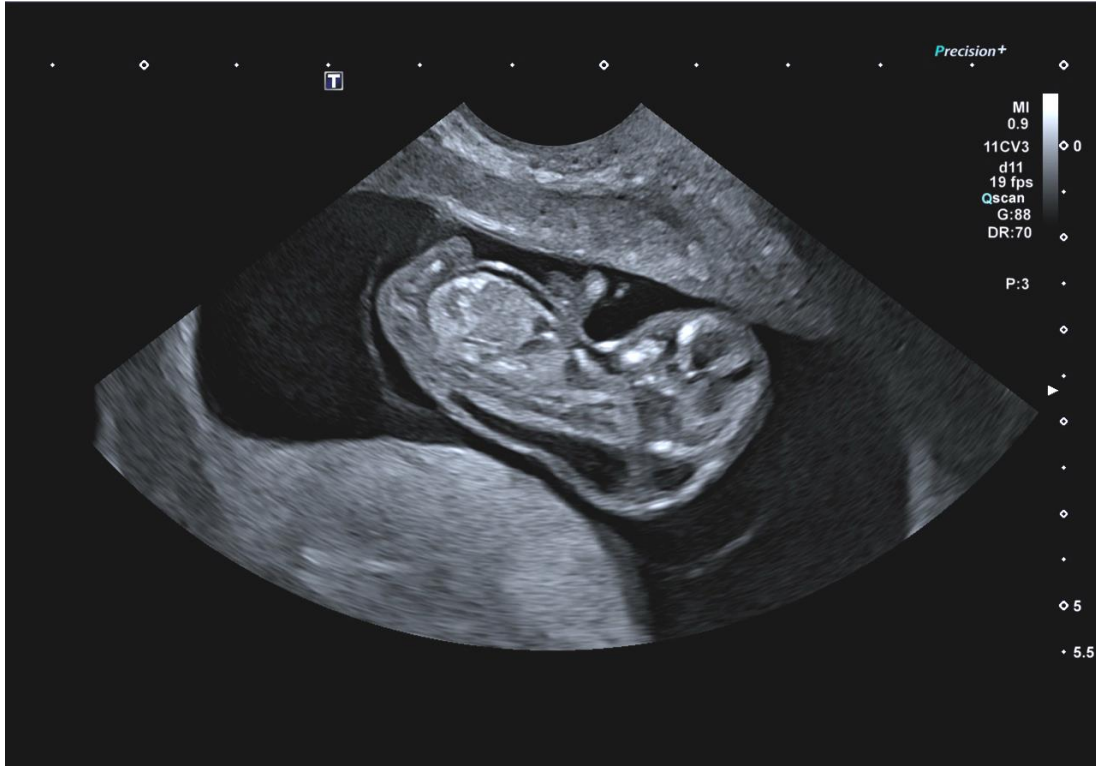

Trisomy 18 – Clinical Gestation 9+ weeks

First Trimester Fetal Assessment <10 wks gest.

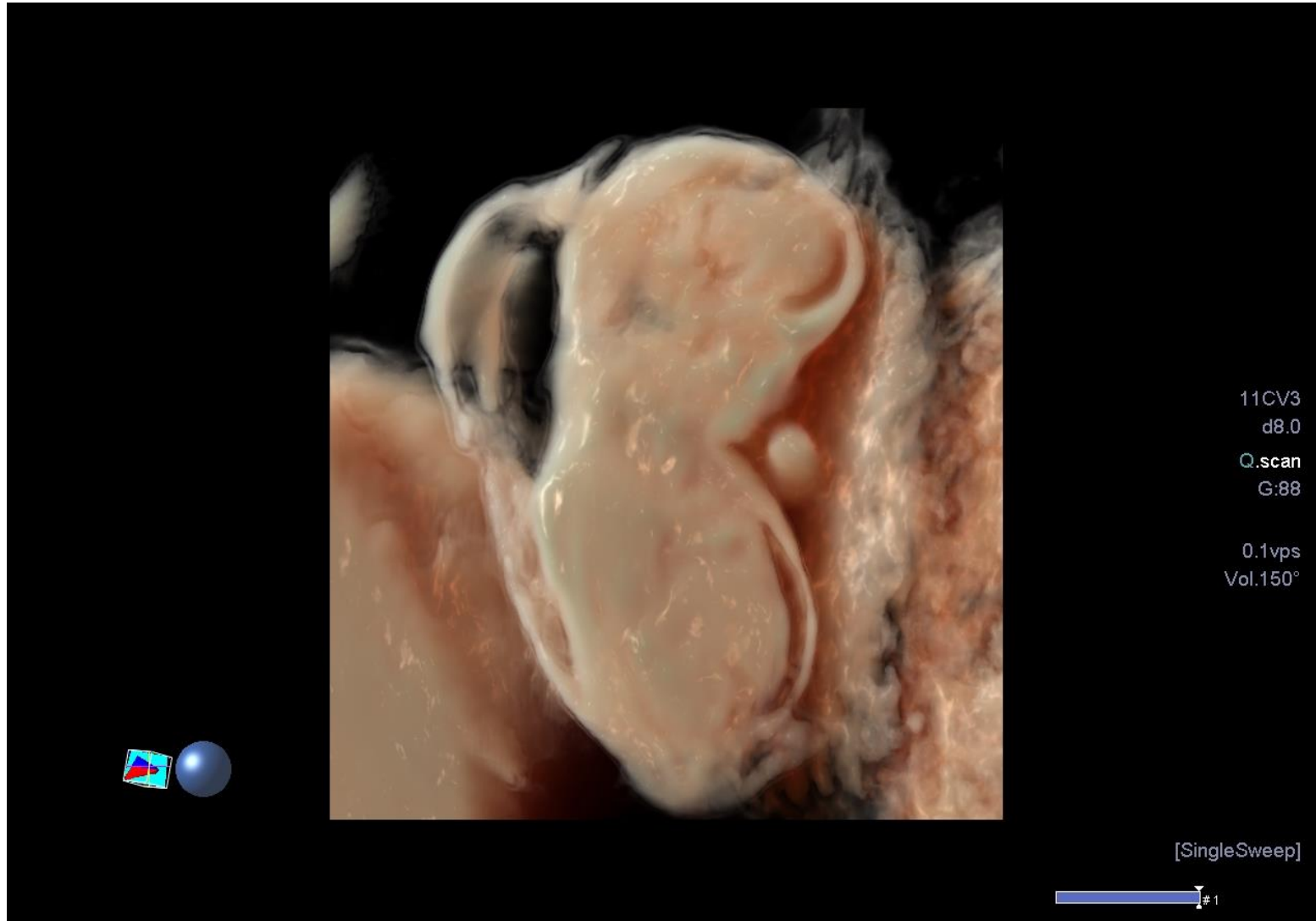


First Trimester Fetal Assessment <10 wks gest.



Trisomy 18 – Clinical Gestation 9+ weeks

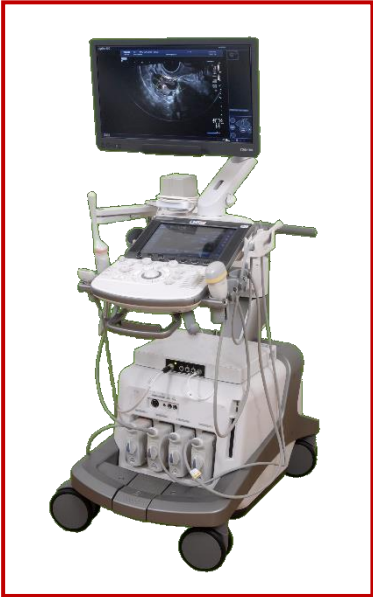First Trimester Fetal Assessment <10 wks gest.



Trisomy 18 – Clinical Gestation 9+ weeks

Ultrasound Imaging In Early Pregnancy

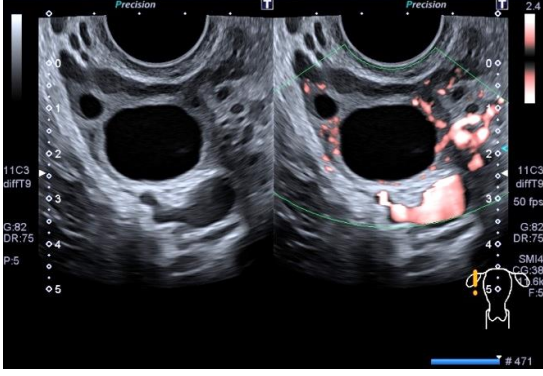
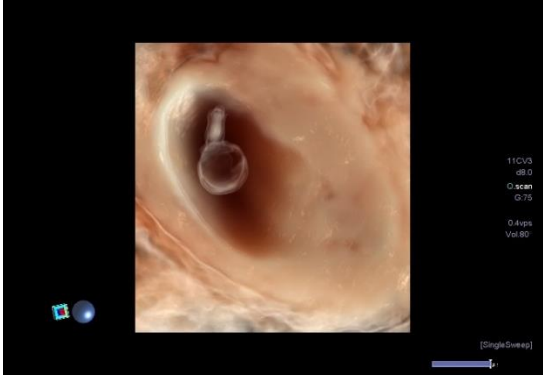
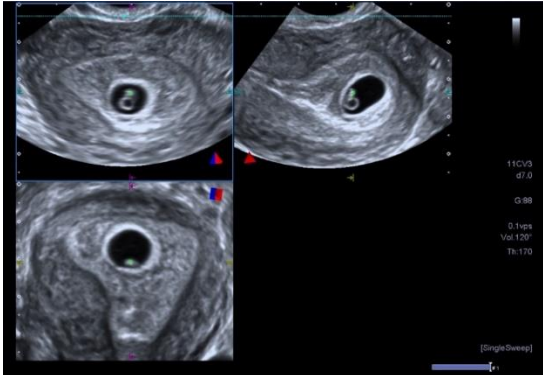
Impact of Advanced Technology



High Resolution
2D TVS Grey Scale

Advanced 3D
Technology

Colour Doppler Imaging
SMI



BMUS Educational



Thank you for your attention.
I hope the lecture was of value to you all.

