Ben Stenberg PhD
Consultant Sonographer
Newcastle upon Tyne

Ultrasound update–

Current concepts and principles including new techniques in US imaging

Standard model

- An ultrasound transducer is a straightforward concept but can be made perform amazing feats
- Crystal – matching layer – lens- tissue- reflection

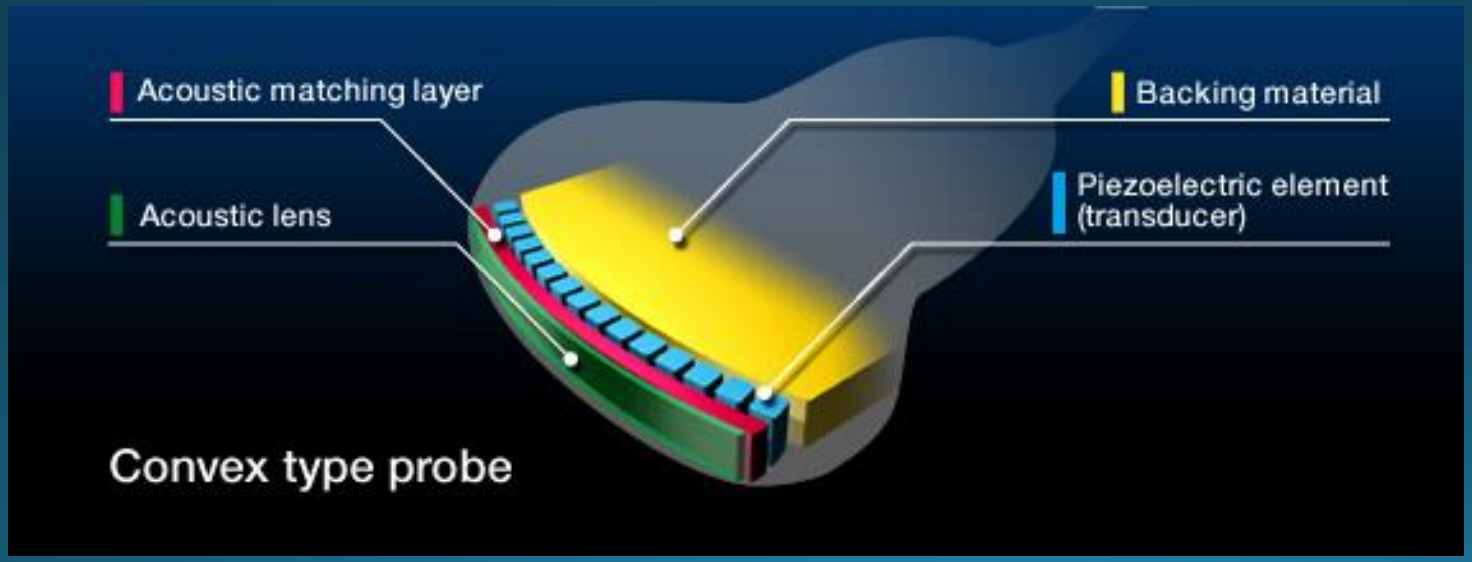

A-mode to B-mode

- One crystal
- A-mode
  - The start of medical ultrasound
  - Lancet, 1958,
    - Donald, MacVicar, Brown,
  - Obstetrics/ Gynae use

- Ovarian cyst

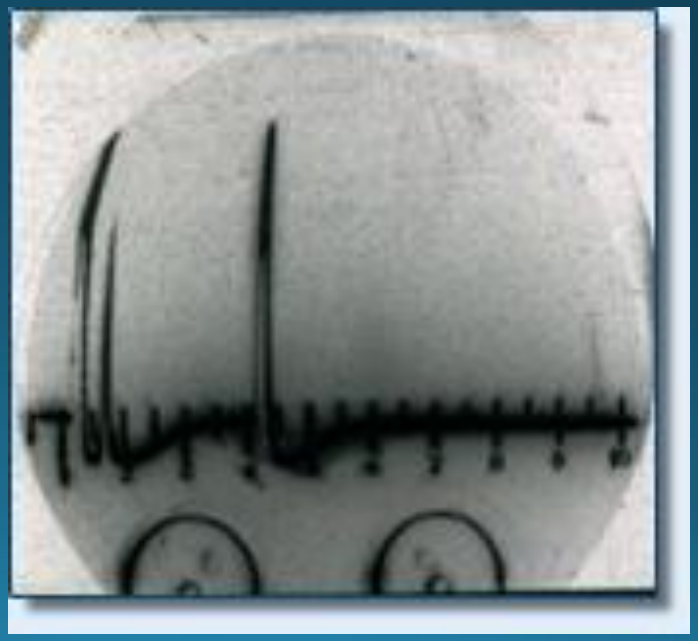

Real time B-mode

- Real time came in 1963. Vidoson, Siemens.

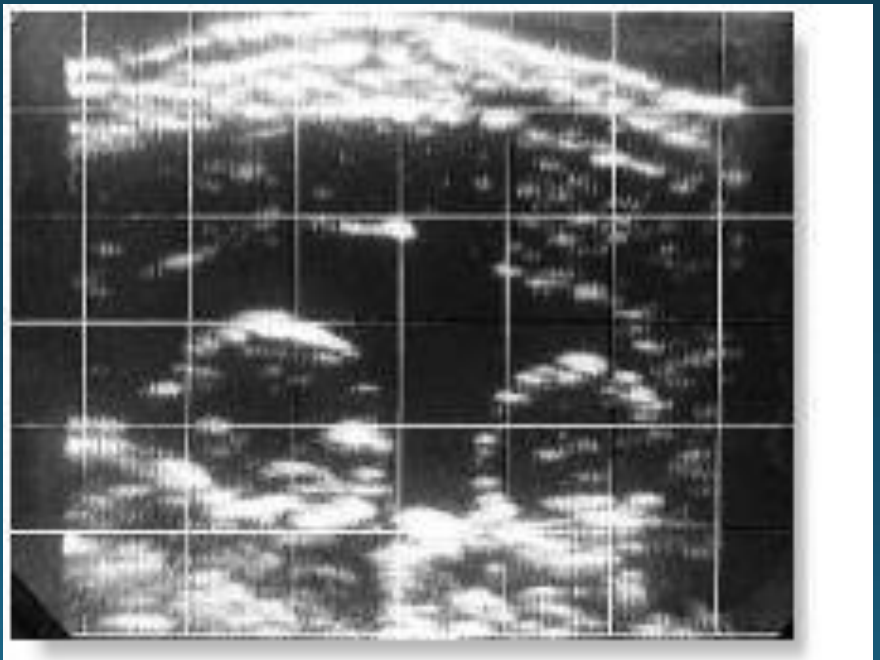

Twin pregnancy depicted on the Vidoson, 1965

Real real-time

Manual elastography- frame rate

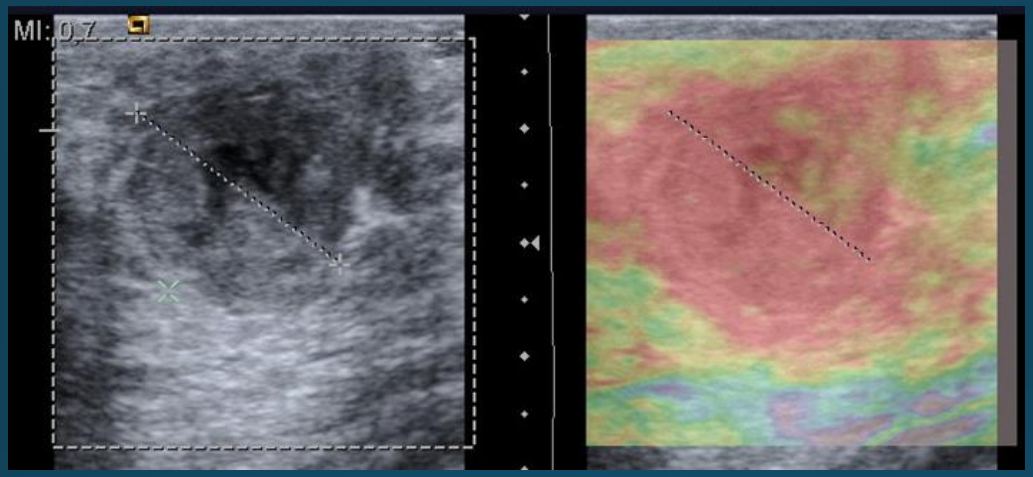

- Pictorial representation (pseudo-quantative) of the compressibility of tissue using registration.
- Bounce the probe on the area of interest and see how much it squashes.
- Latest versions use respiration or arterial thump to generate strain.

Pixel tracking- frame rate

- Real time tracking of thousands of pixels
- Non-angle dependent
- Non-speed dependant

- Requires high frame rate in order to track pixel change
- Movement must be in plane.



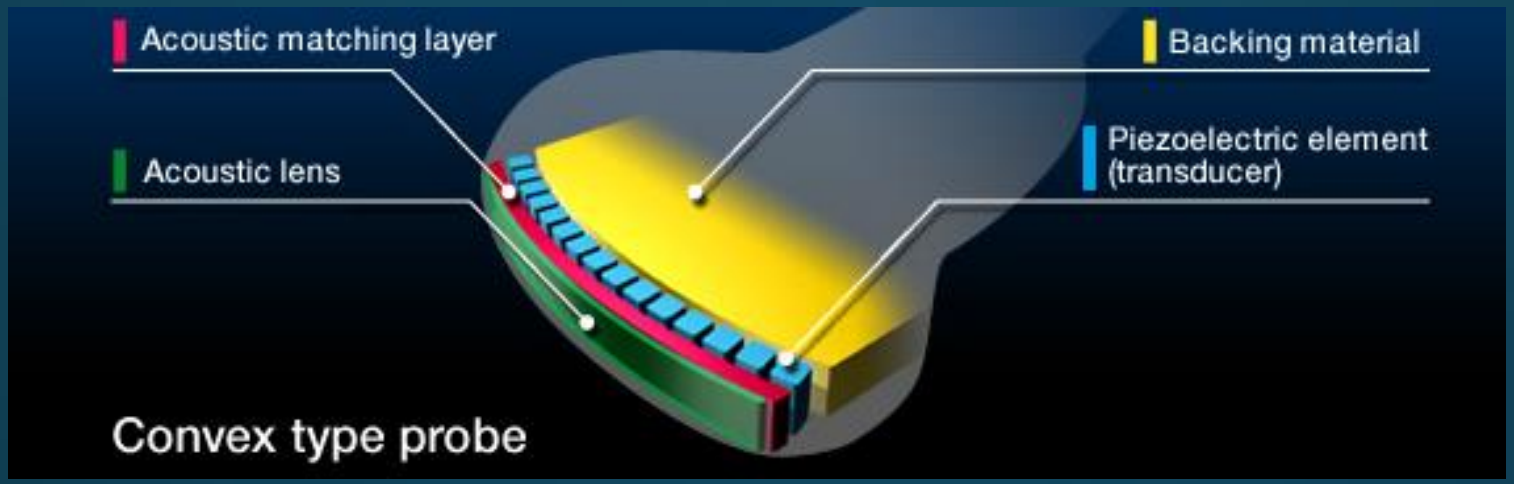

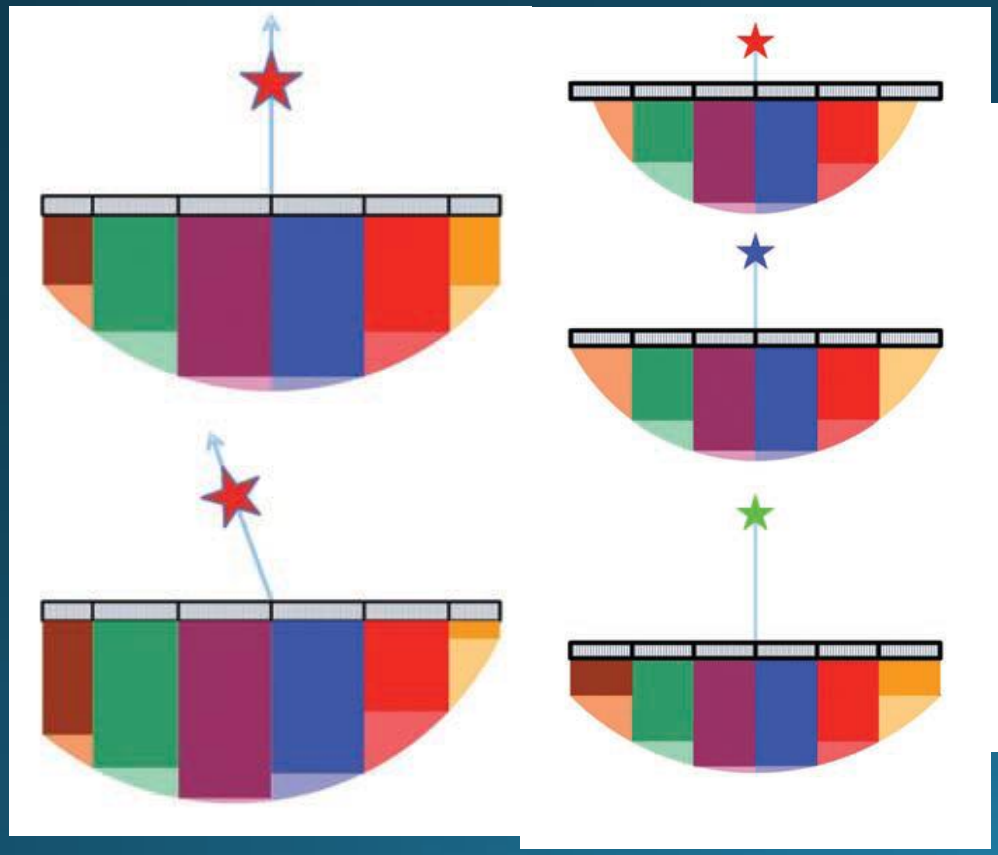

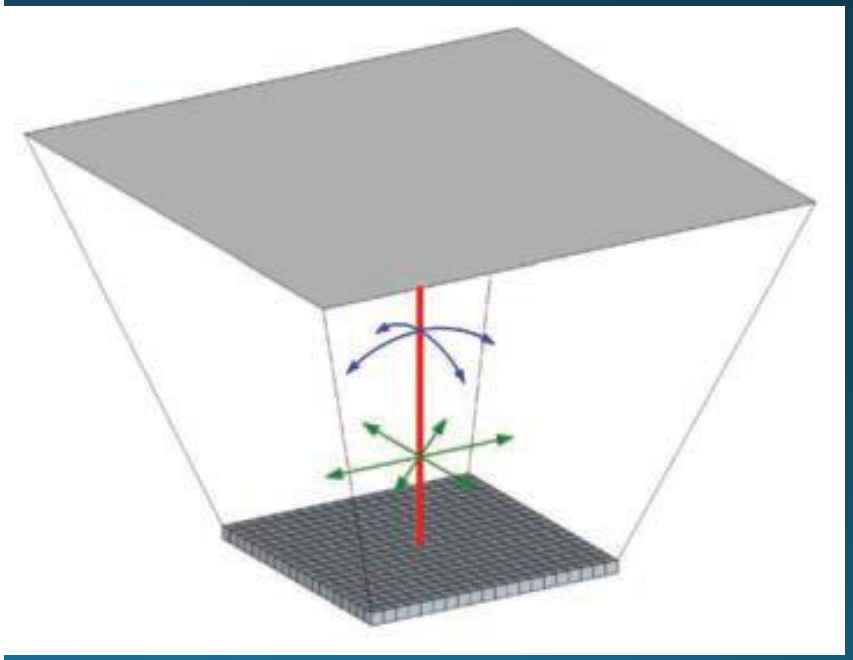

Images courtesy of Philips Healthcare

Beam control

- Offset delay profile and you get beam steering
- Seeing "round corners"
- Compound imaging
- Focusing in the b-plane

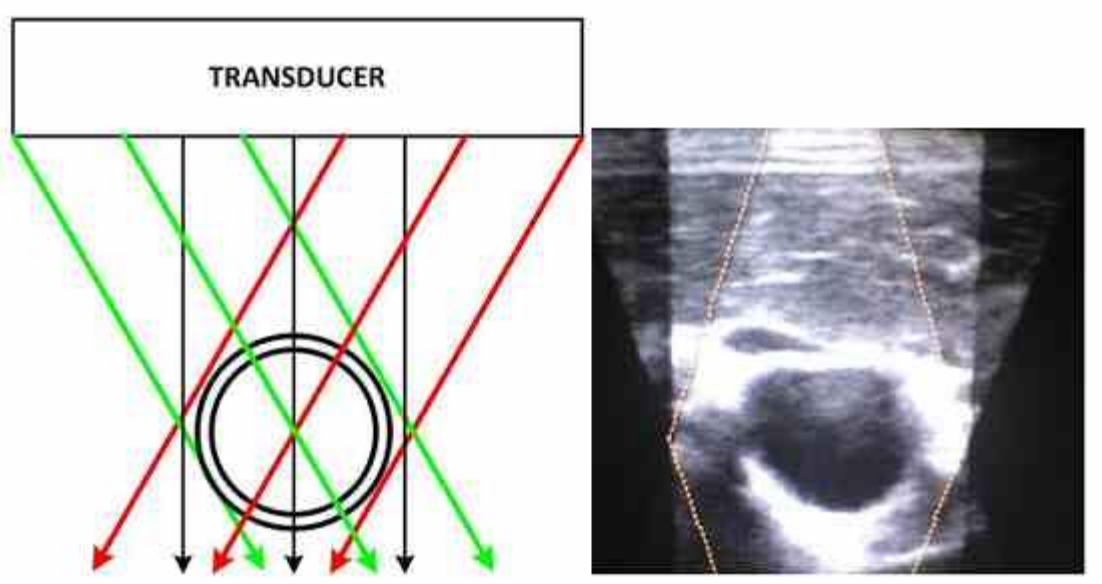

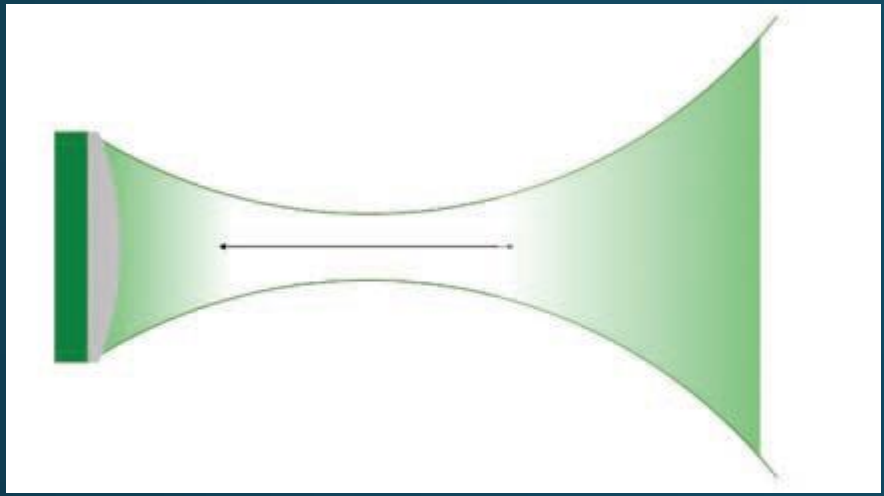



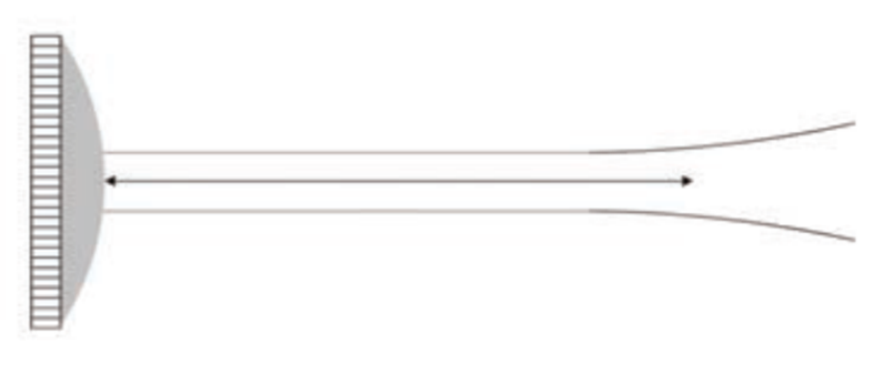

Images courtesy of Philips Healthcare

- If you arrange crystals in both planes you can reduce beam thickness but also steer the beam in 3D



xPlane: live dual plane imaging

- Truly unique to Matrix technology
- speeds up
  - examination time
  - perception of anatomical relationships
  - measurements
- xPlane significantly reduces
  - excessive wrist movement (>15%; RULA)
    - by an average of 70%
  - excessive pressure by operator



Matrix- Bi-plane imaging

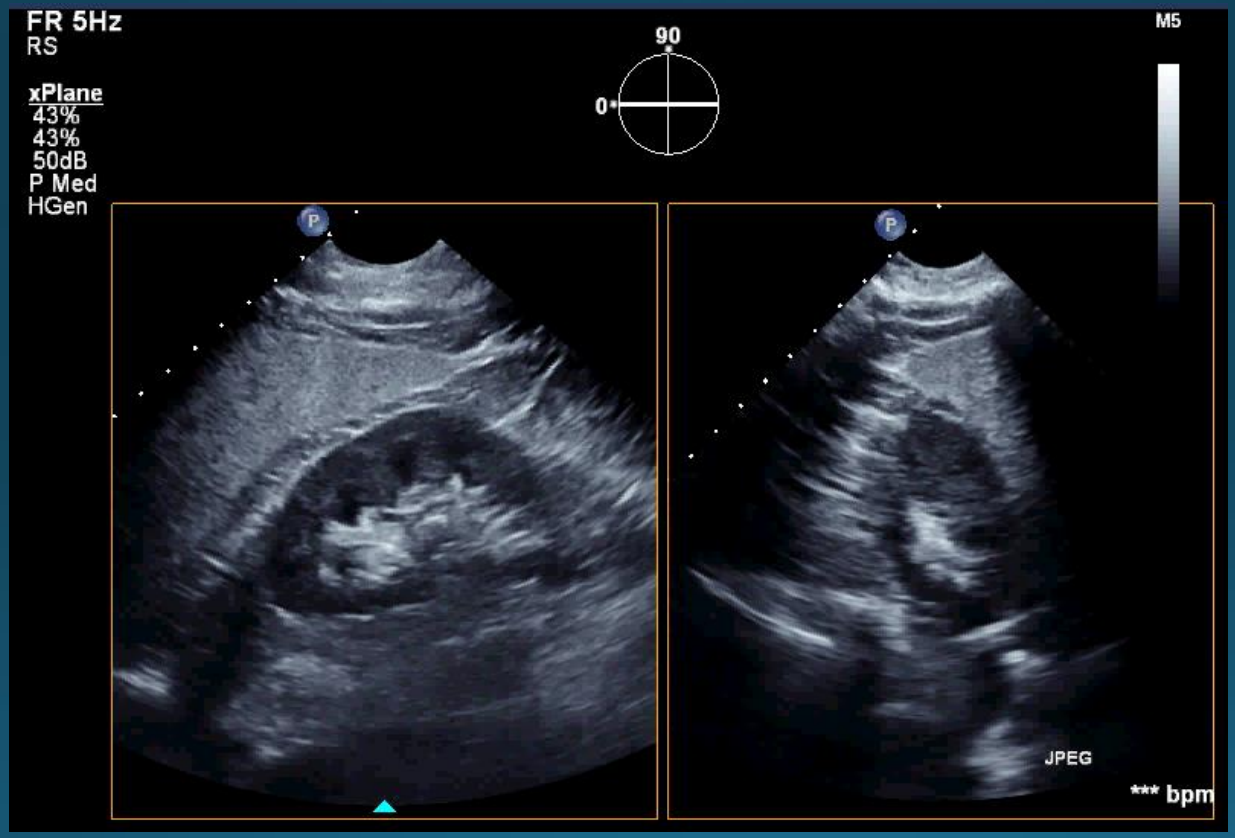

xPlane: live dual plane imaging

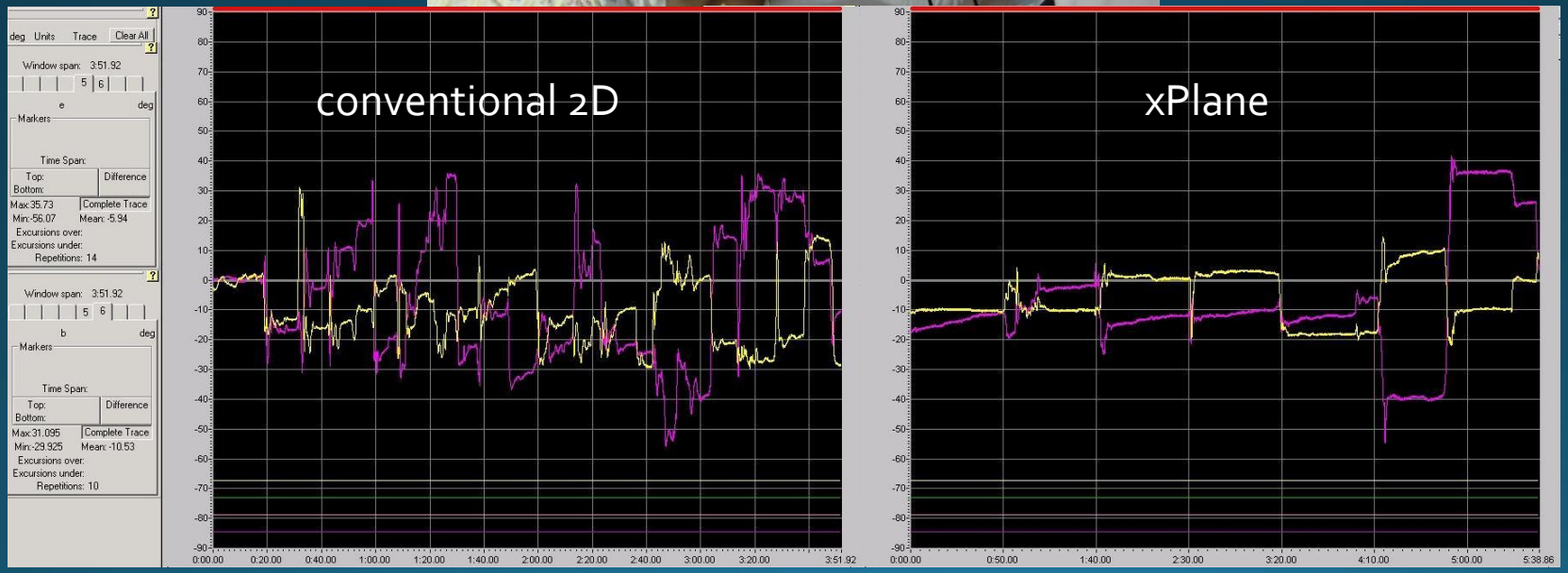

Stenberg B, Elliott ST, 2013, **Can live bi-plane sonography reduce work-related musculoskeletal disorders of the wrist?, J Clin Ultrasound, 41 (3): 140-4**

- Acquire full 3d datasets in very rapid time

3D

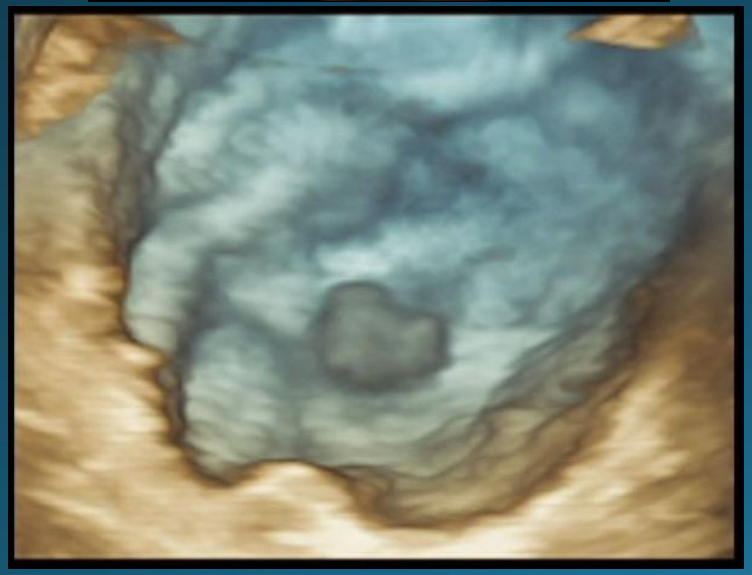

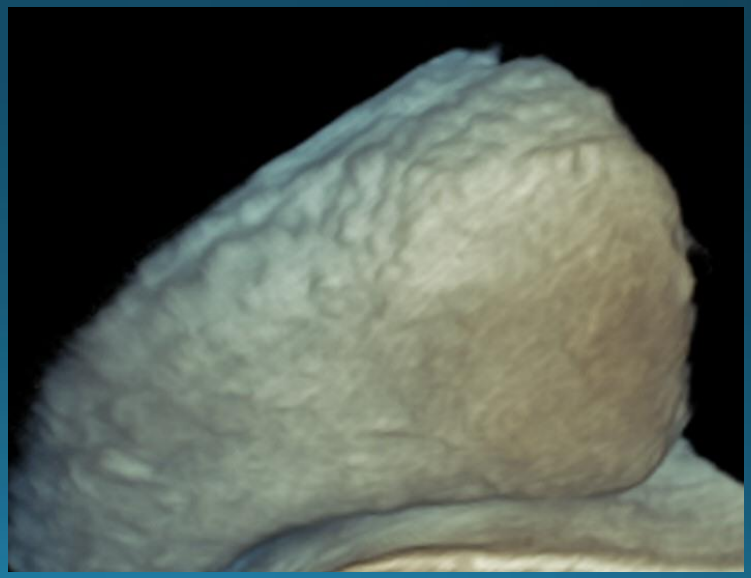

3DUS

- Not just baby faces
- Increased accuracy of volume measurement
  - Reduce error margins form 25% to 10 %
- Reproducibility and full record of examination
- Speed up "on table" time
  - Obstetrics and Gynaecology examinations by 80%
    - Benaceraff et al, 2006, Three-dimensional US of the fetus: volume imaging, Radiology, 238 (3)
- Moves US to a CT/MRI model
  - Offline blind reporting as good as live scanning in detection of pathology
    - Stenberg and Elliott, 2010, Diagnosis of gallbladder problems using 3DUS, European Radiology, 20(4)

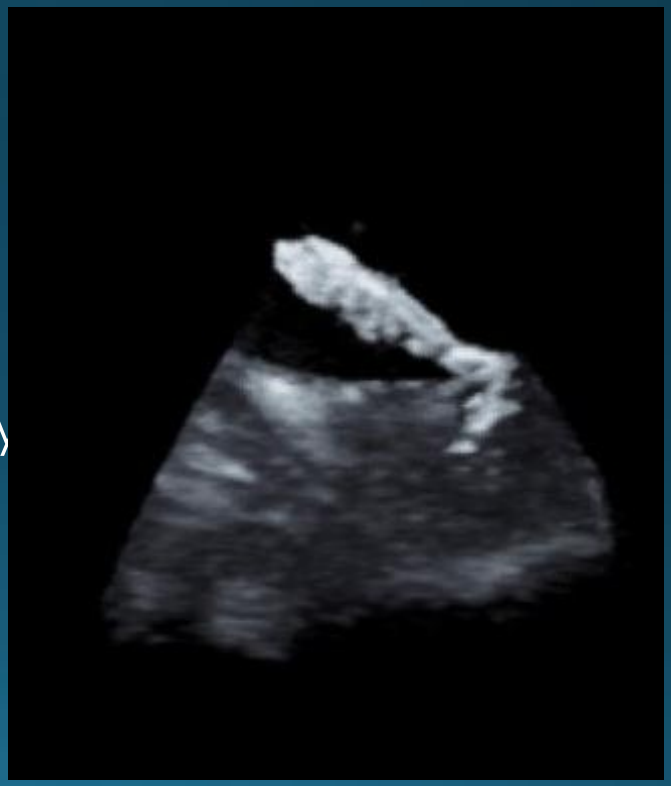

C-plane: renal artery origins

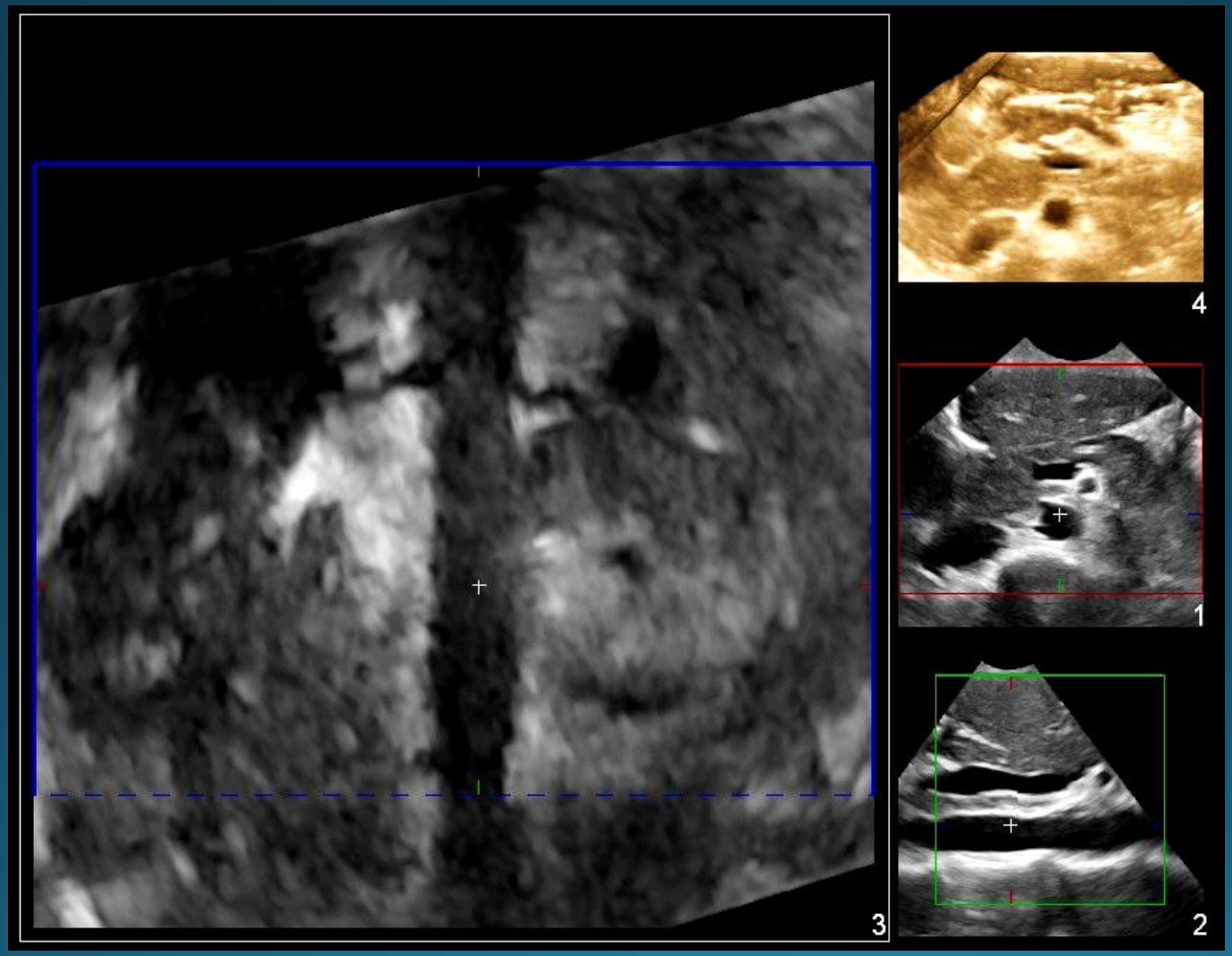

renal vasculature

L renal cell carcinoma

IVC tumour thrombus

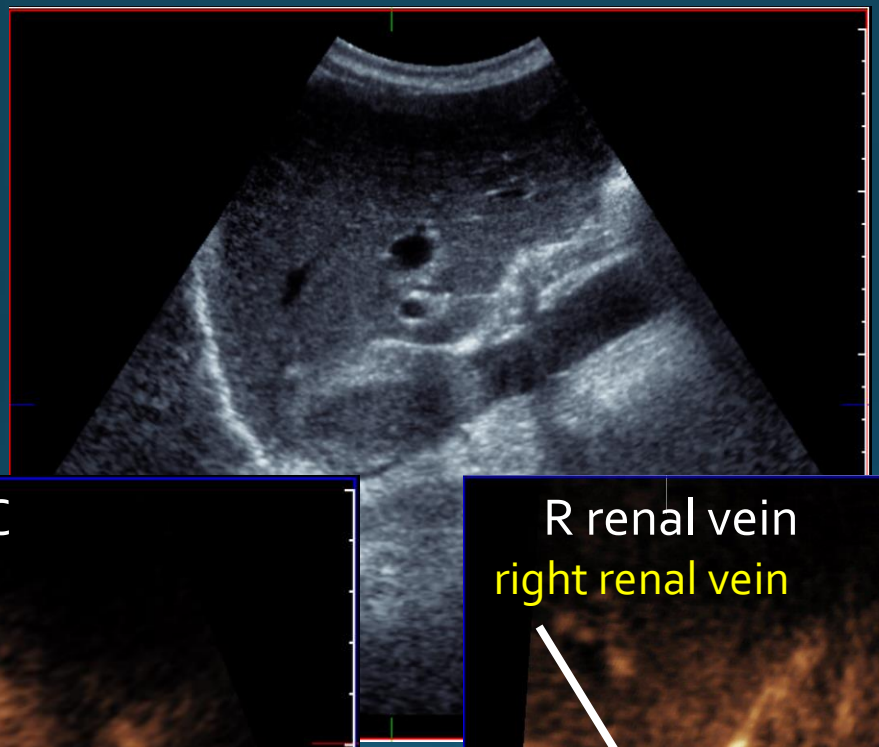

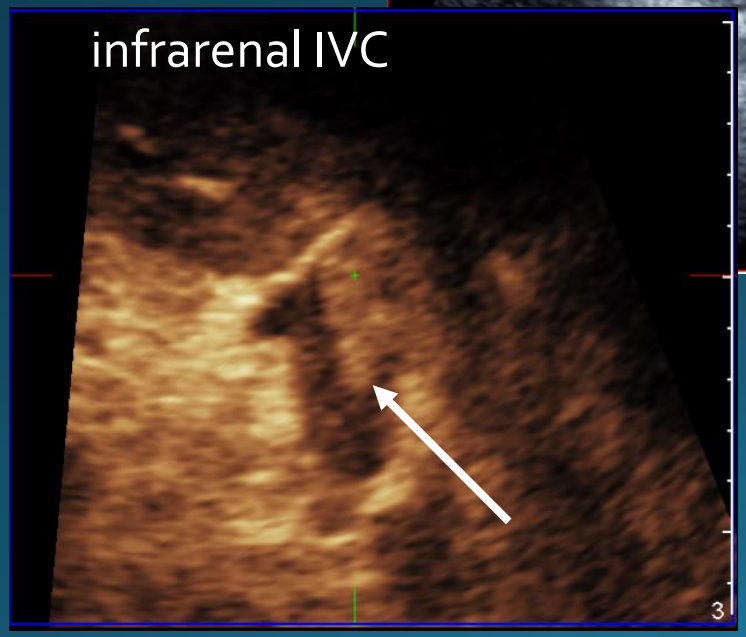

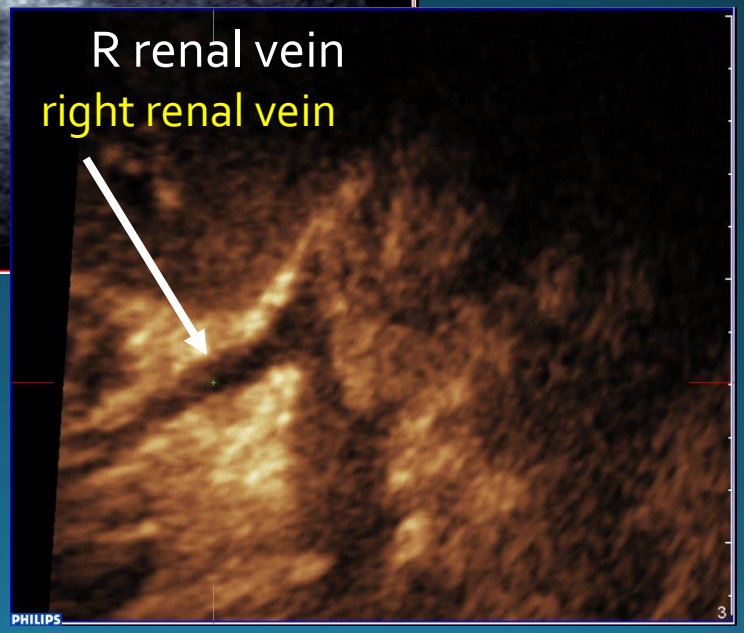

Imaging a renal cyst

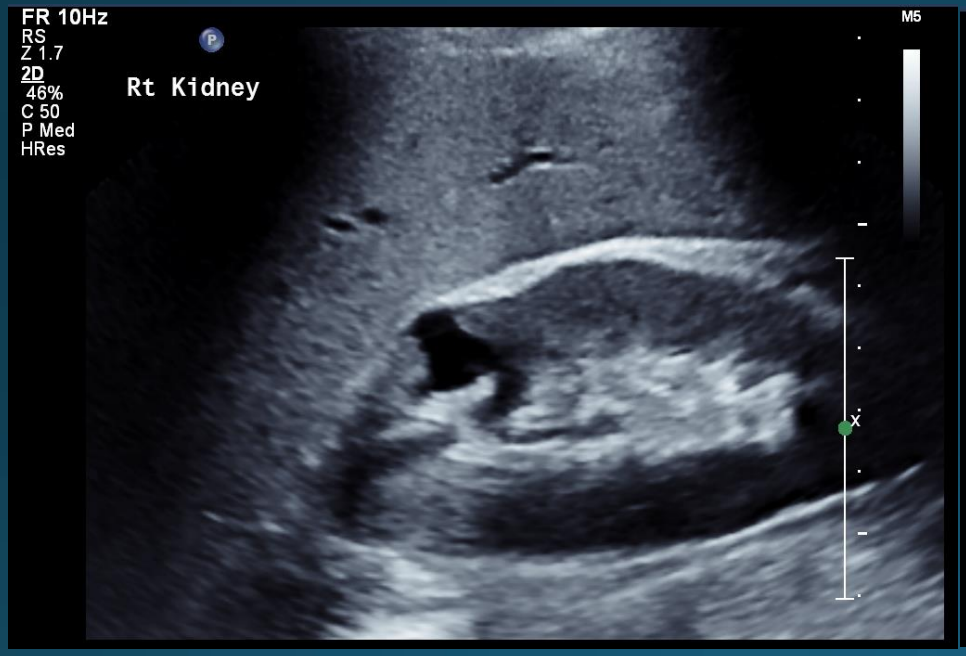

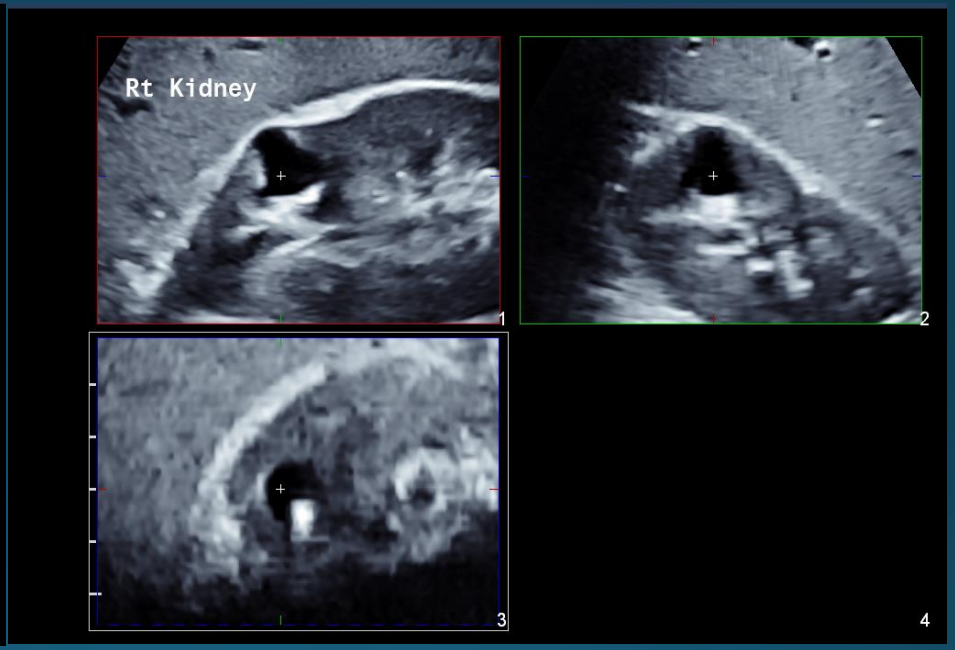

Imaging a renal cyst

1mm slice intervals

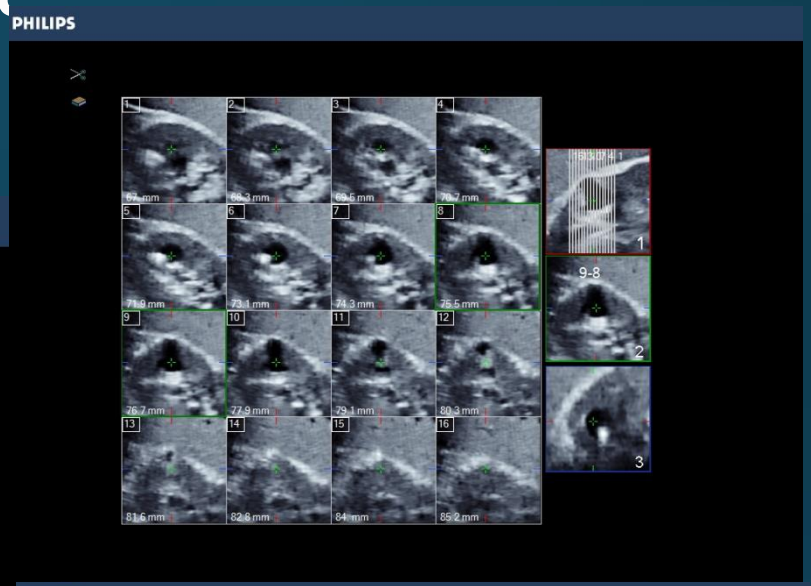

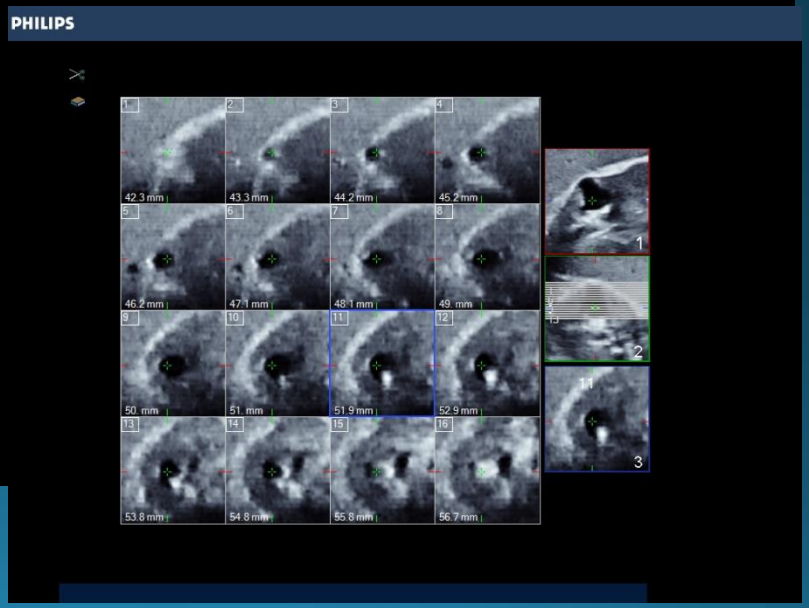

3D - Automated segmentation

- Computer assisted processes

Foetal heart navigation

- Uses 3D US data and organ recognition to provide the standard heart views automatically.
- A computer model with standard anatomy and common anatomical variations is applied to the data. This can be done automatically or with minor assistance to detect the anatomical landmarks

- The system can then provide the standard views of the foetal heart automatically using multi-planar reconstruction.

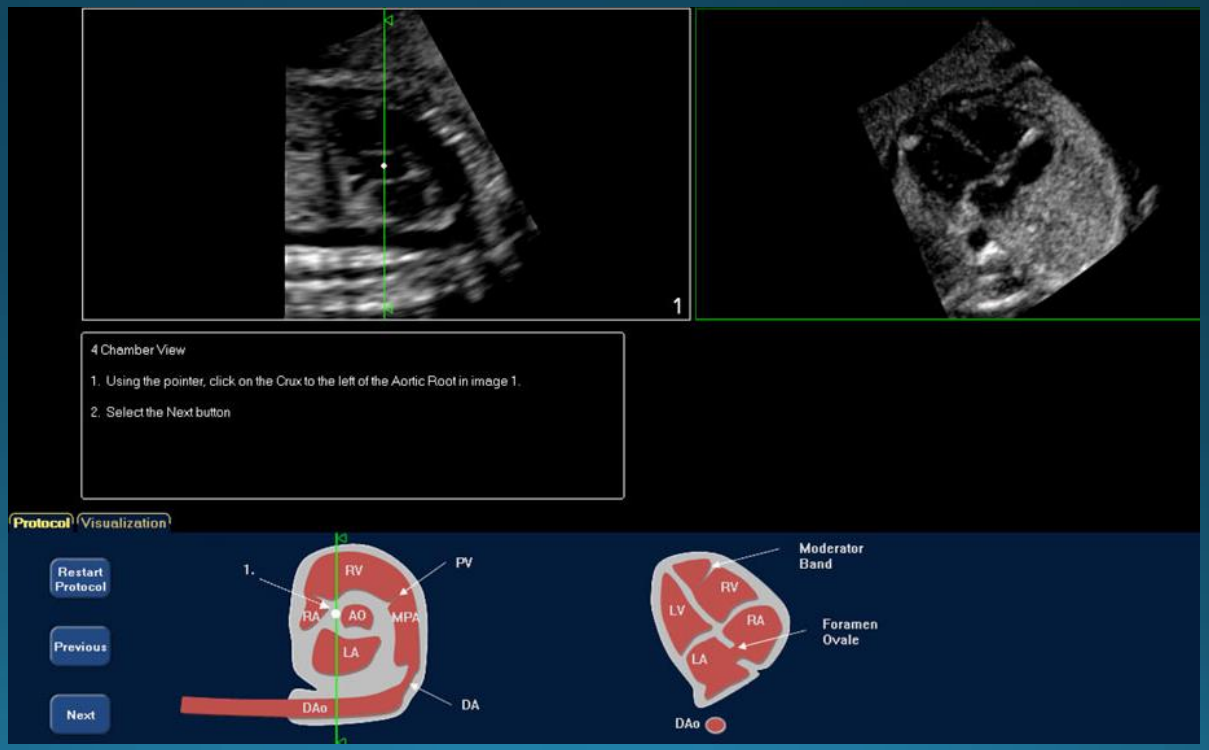

Auto-kidney MPR and segmentation

- Automatically detects the kidney within minimal or no input in over 90% of cases.
- Performing segmentation in under 1 second (average 0.85s)

- Using auto-segmentation can reduce intra- and inter-operator error margins from +/- 10% for length and +/-25% for volume to under +/- 1% (average 0.3%)

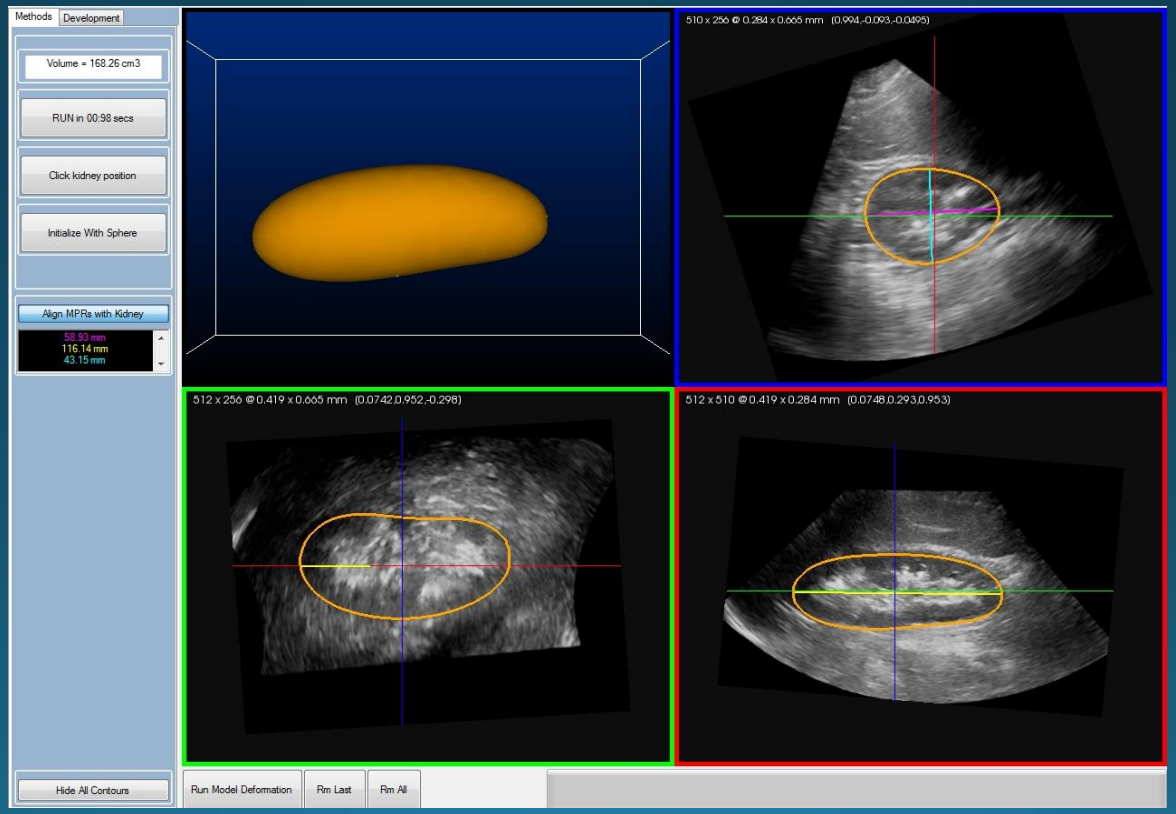

AAA segmentation

- Works 70% of the time with little or no input.
- 30% requires some user input
- Computer vs human had a correlation co-efficient of 0.98.

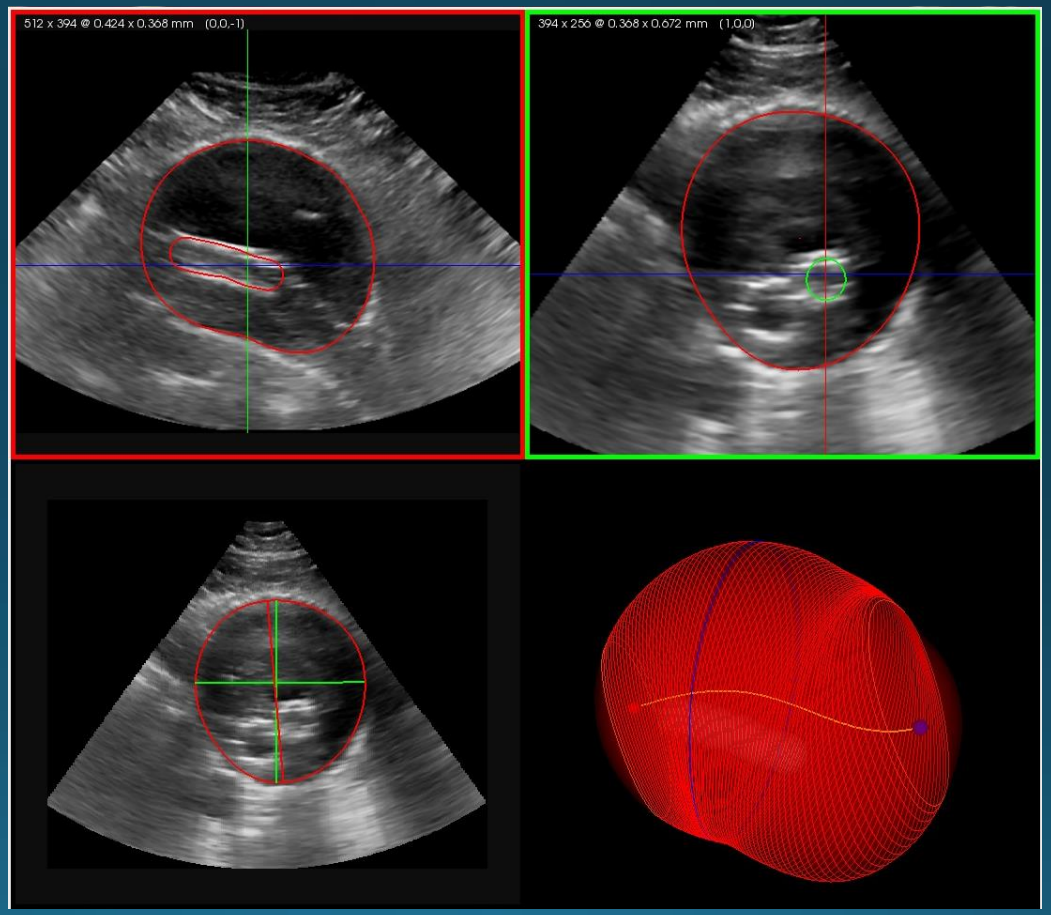

Frequency

- Change the frequency- change the resolution (and penetration)

Low frequency

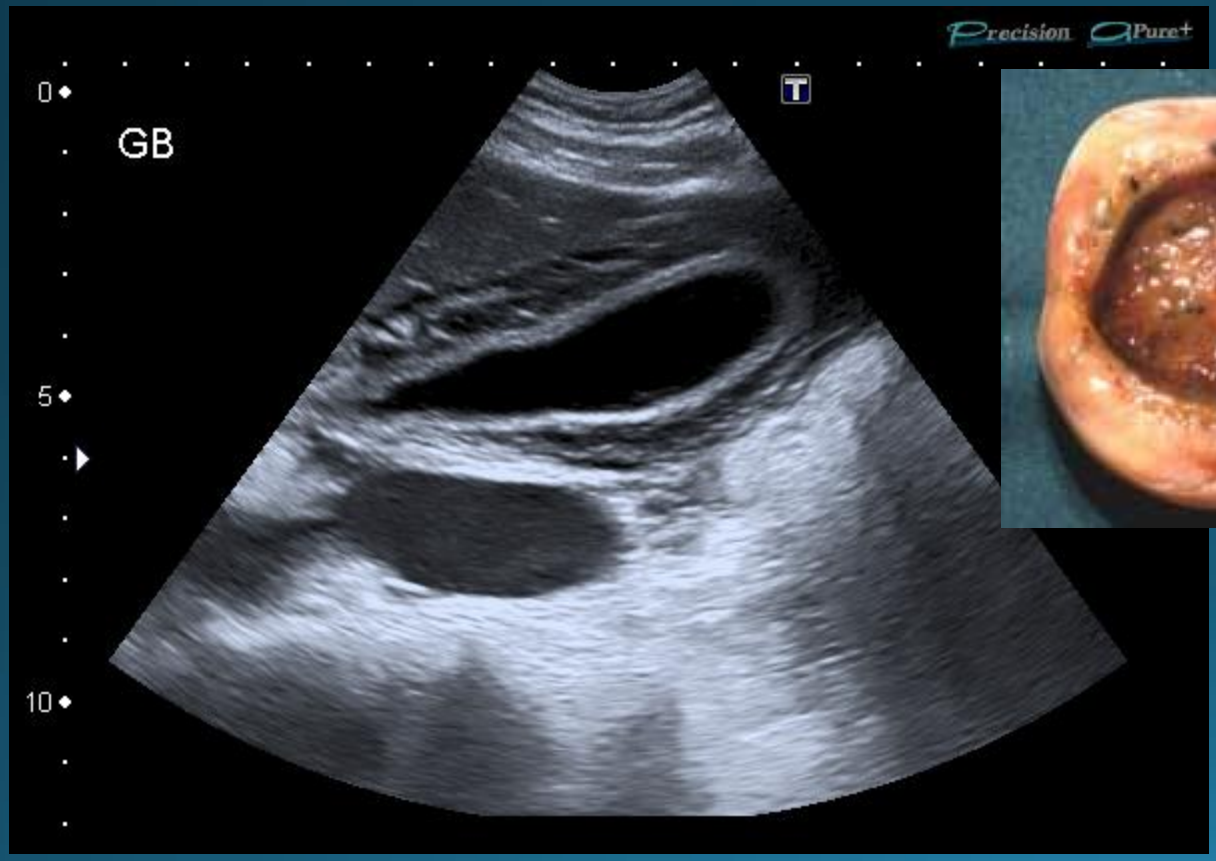

High frequency

Guiding intervention

- Allows accurate intervention as well as diagnosis

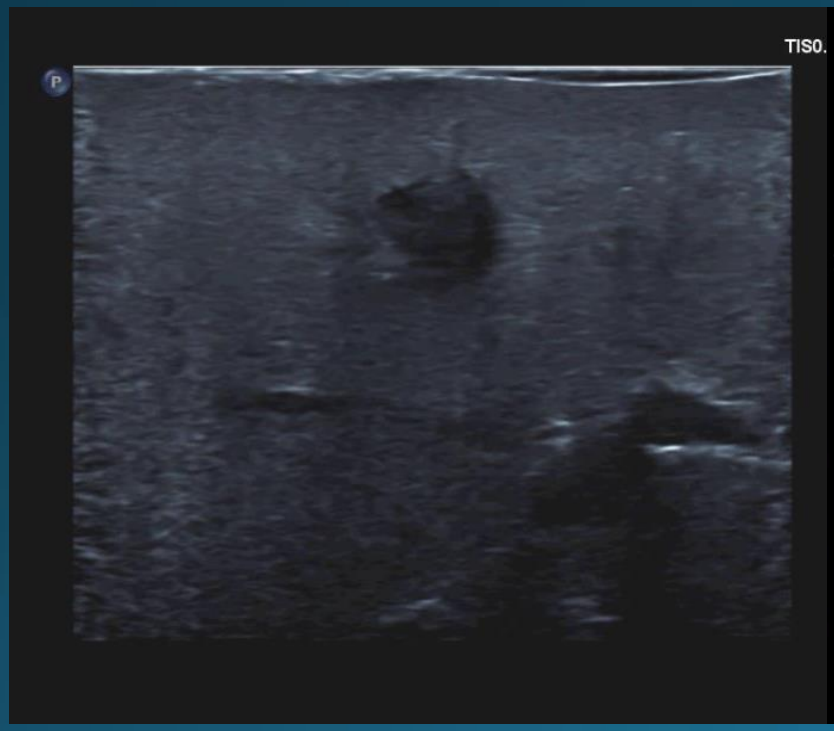

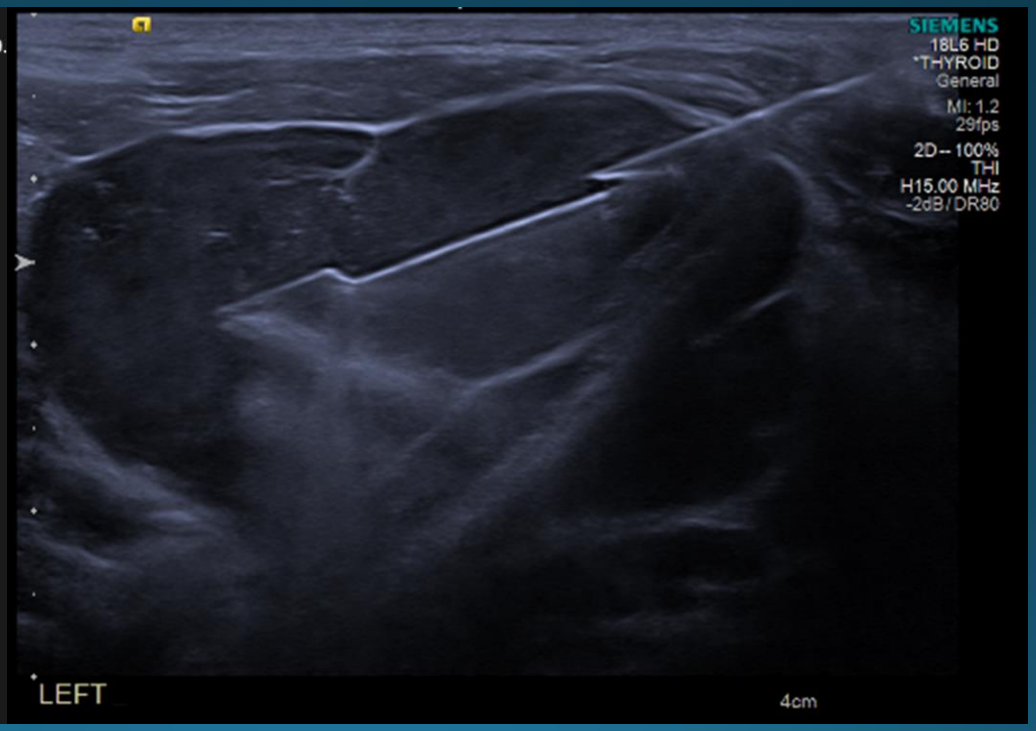

High frequency probes

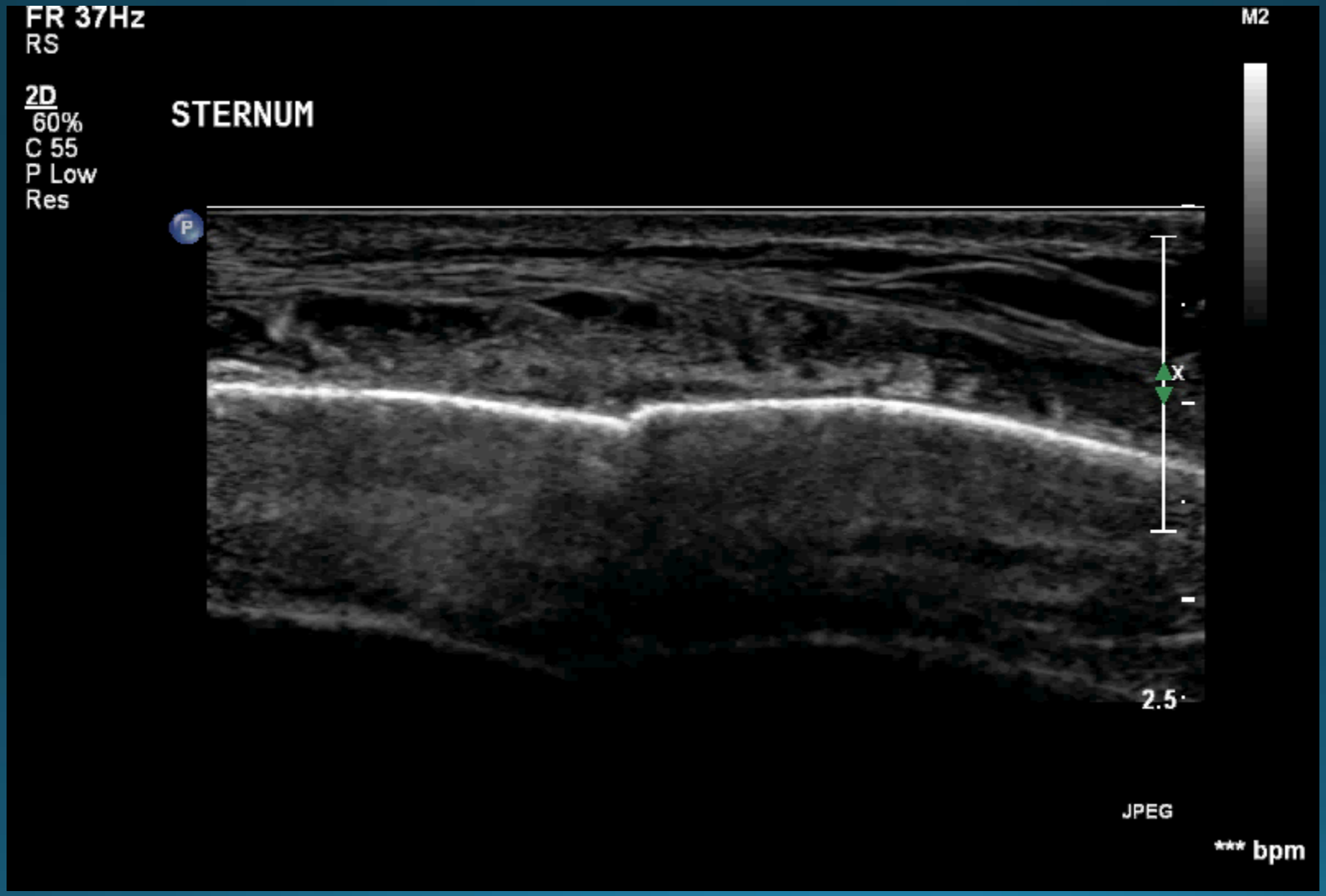

How do you snap a sternum?

Change in frequency- harmonics

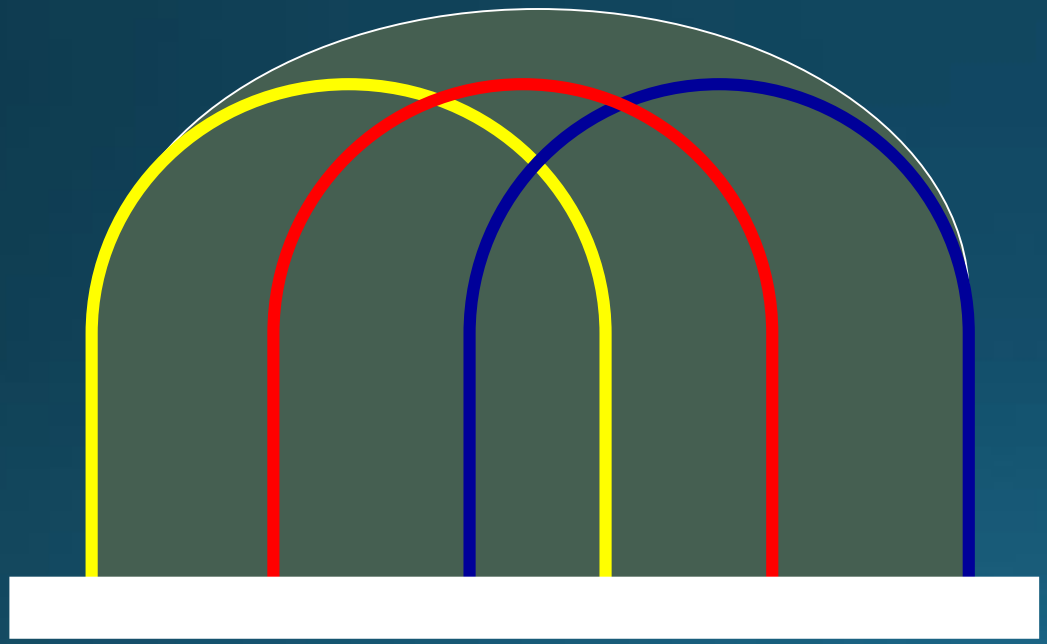

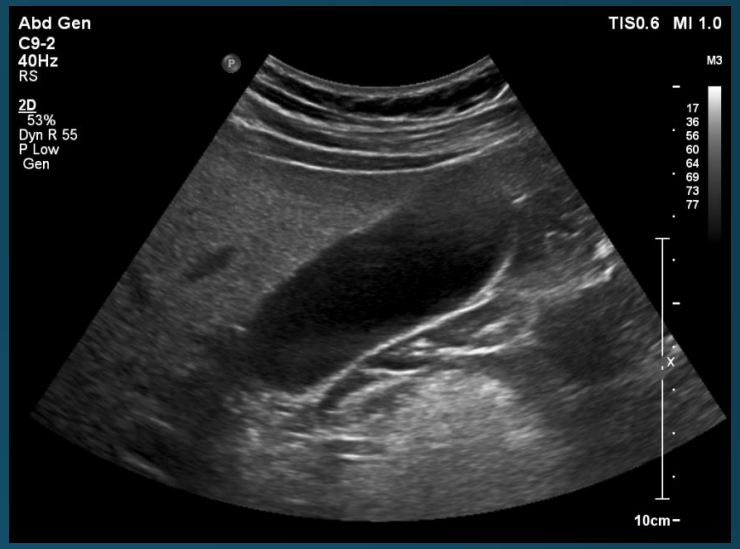

Change in frequency- Doppler

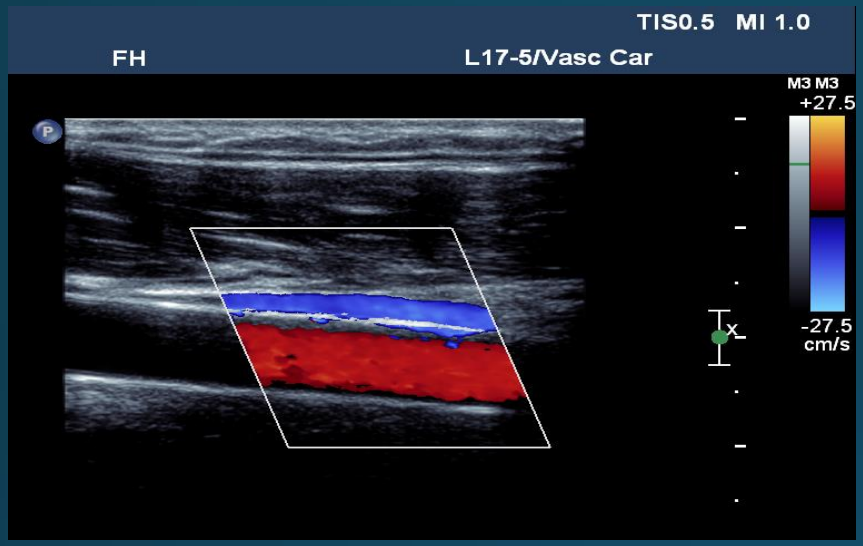

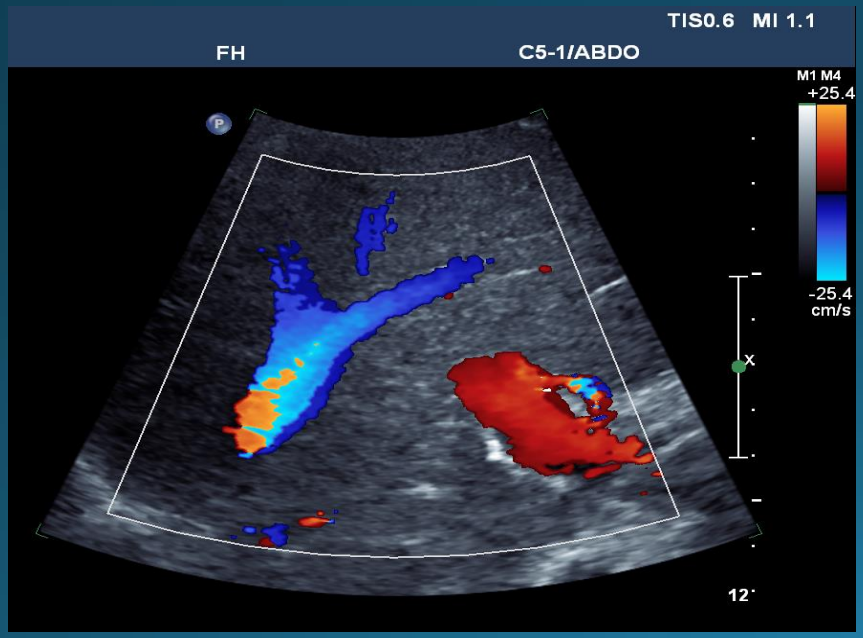

- Uses the Doppler principle to detect a shift in frequency of returning sound from a moving object.
- $f(d) = \frac{2\, f(t)\, V \cos\theta}{C}$
- Power, colour and spectral all have their unique features and uses.

hepatic artery

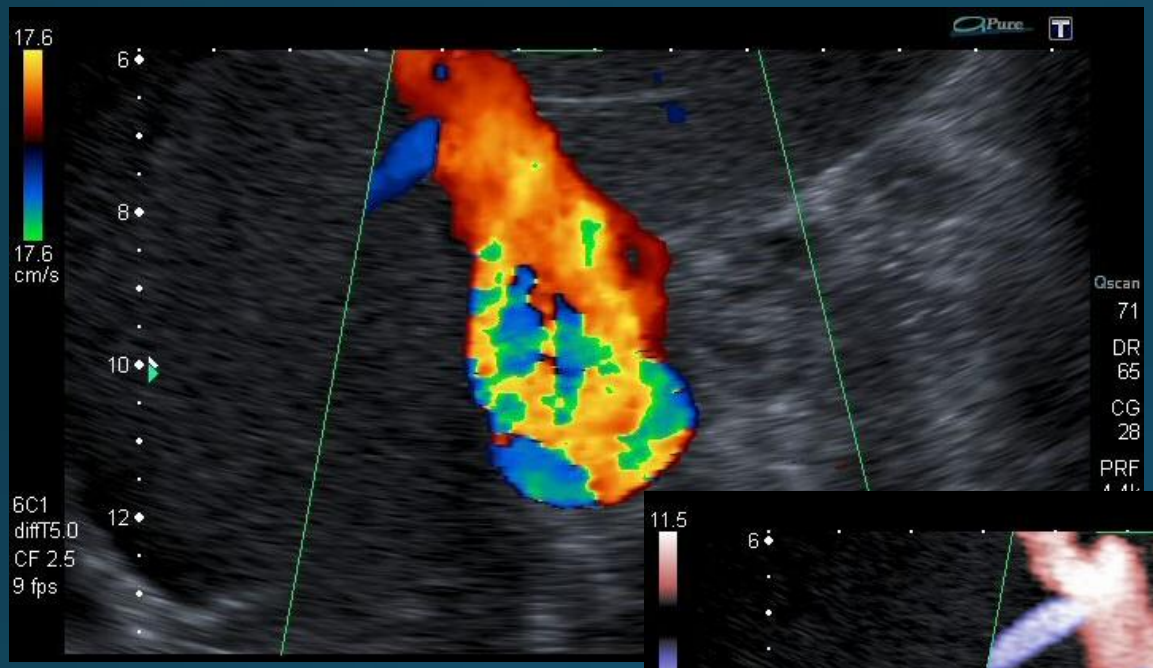

Colour Doppler

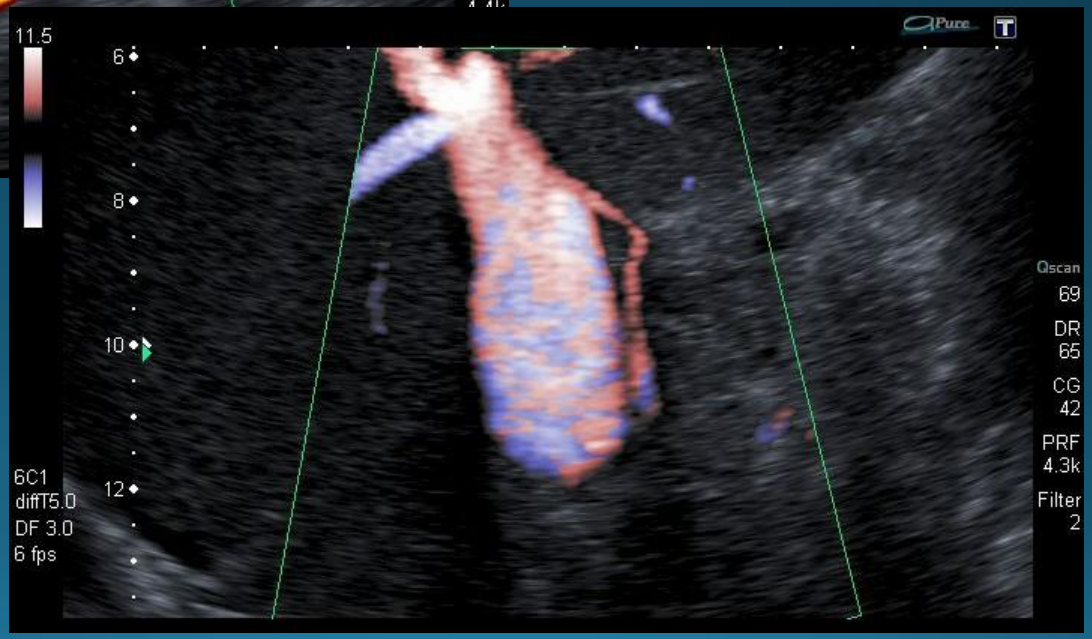

Advanced Dynamic Flow
Toshiba, 2005

Superb Microvascular Imaging/ MicroFlow Imaging

- High resolution and sensitivity Doppler ultrasound

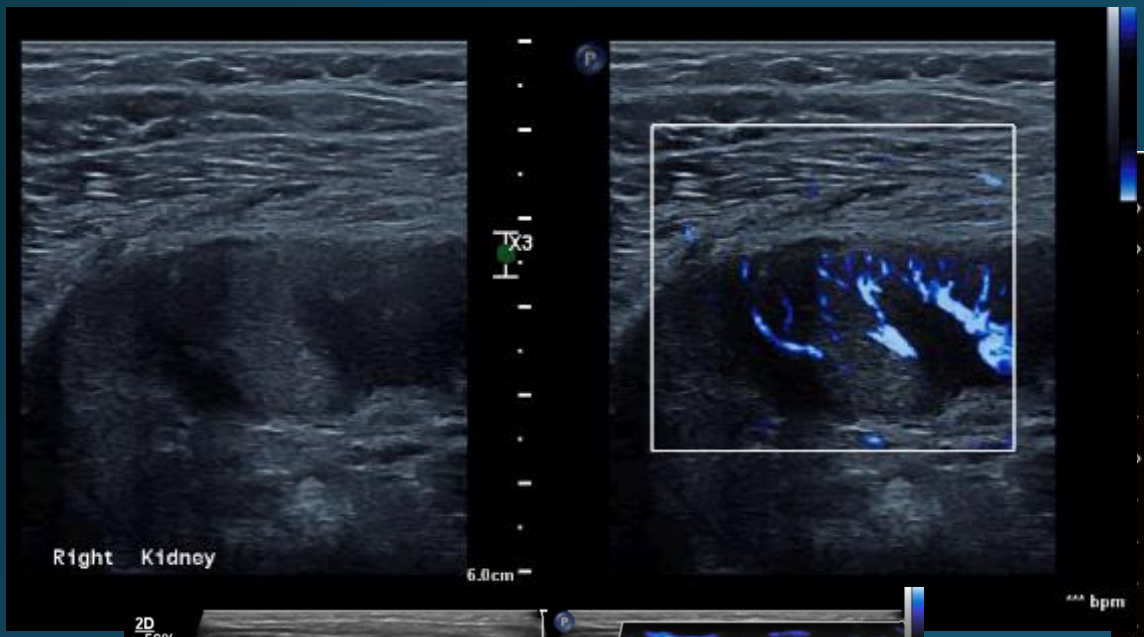

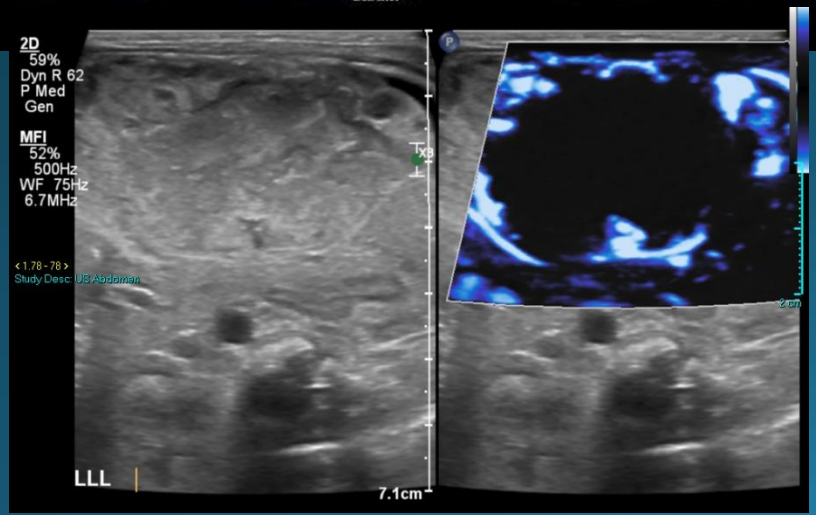

- Good results in EVAR follow up.
- Cervical lymph nodes
- Kidney transplants

Power output

- Important in obstetrics – bone and tissue heating and cavitation (especially with contrast media)

- Exerts a force on the tissue
  - If that force is enough you can see or measure that effect

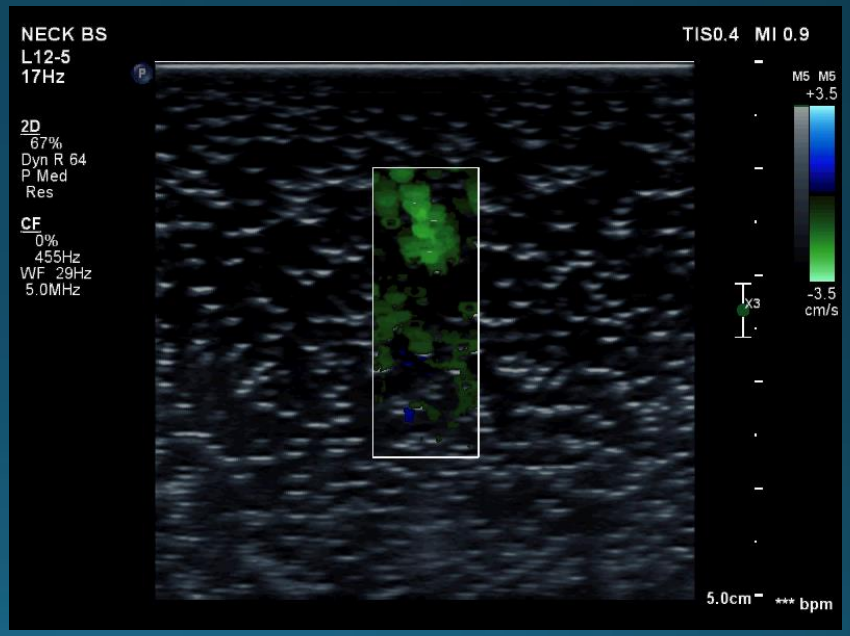

Shearwave Elasticity

- Sound travels faster through stiffer tissue.
- Pulse is passed through the area of interest causing ripples (shearwaves).
- Detection pulse detects the position of these waves and determines stiffness of tissue

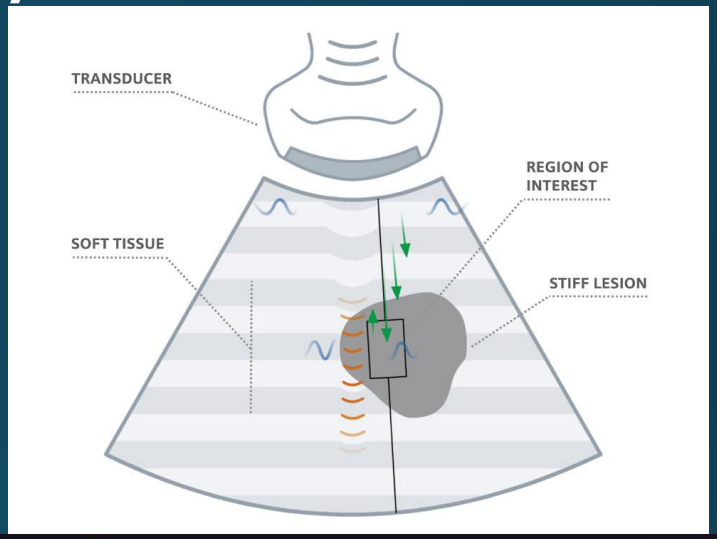

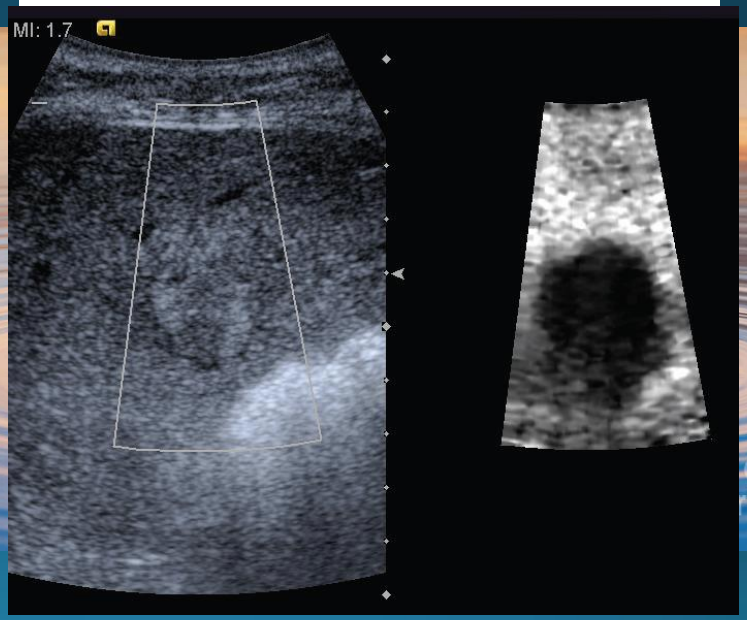

Shearwave elasticity

- Shearwave Elastography- attempt at quantification
  - Validated in Hep B + C, sens (spec) 77% (81%) for F≥2 and 85 % (80%) for F4.
  - This is comparable with fibroscan 76% (71%) and 79% (84%). (NICE, 2015)

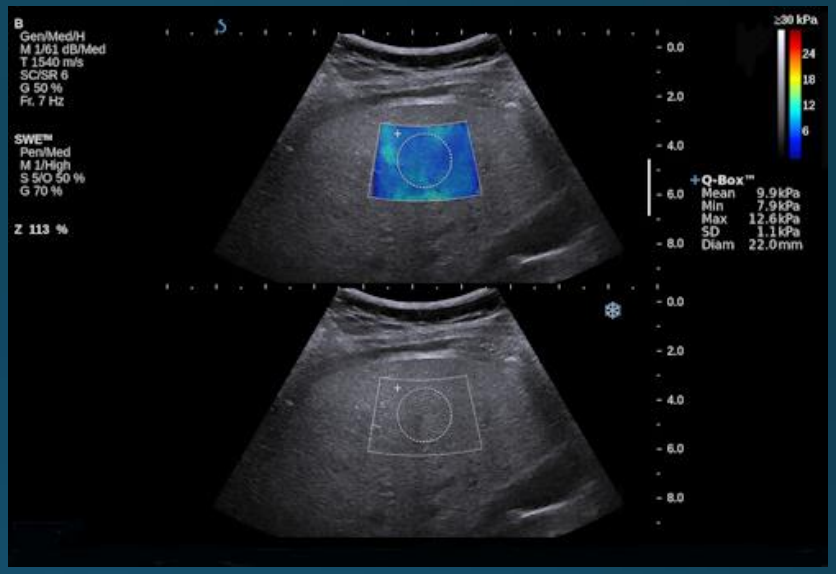

- Can hugely reduce the need for liver biopsy in these patients.

NICE guidance: Virtual Touch Quantification to diagnose and monitor liver fibrosis in chronic hepatitis B and C, September 2015

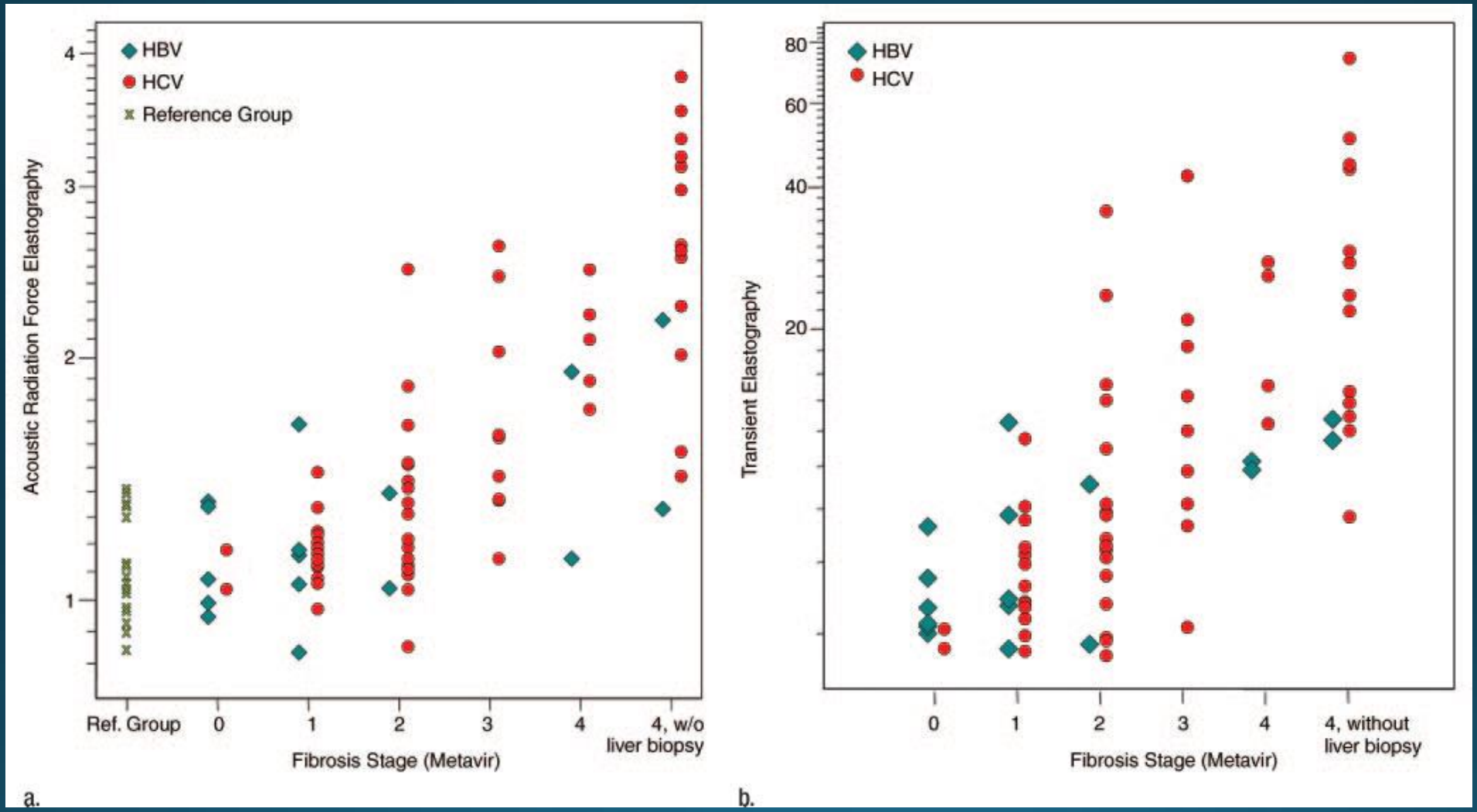

Friedrich-Rust et al, 2009, Liver Fibrosis in Viral Hepatitis: Noninvasive Assessment with Acoustic Radiation Force Impulse Imaging versus Transient Elastography, *Radiology*, 252 (2): 595-604

Power output- HIFU

- High intensity focussed ultrasound
- Used in treating various diseases by causing focal heat and destroying tissue
- Can raise the temperature of the targeted tissue to 80-90 degrees Celsius in 2-3 seconds.
- Physios use ultrasound in muscle, tendon and ligament damage to stimulate repair
- Can be used for ablations in cancer, fibroids, etc.

Power output

- Important in obstetrics
- Exerts a force on the tissue
- But also in utilizing the concept of linear and non linear reflectors react differently to changes in power output
- Bubbles of gas are a perfect example of a non-linear reflector

CEUS

- Tiny bubble of sulphur hexafluoride in a phospholipid shell.
- Each bubble smaller than a red blood cell.
- Resonate at abdominal ultrasound frequency to improve signal return.

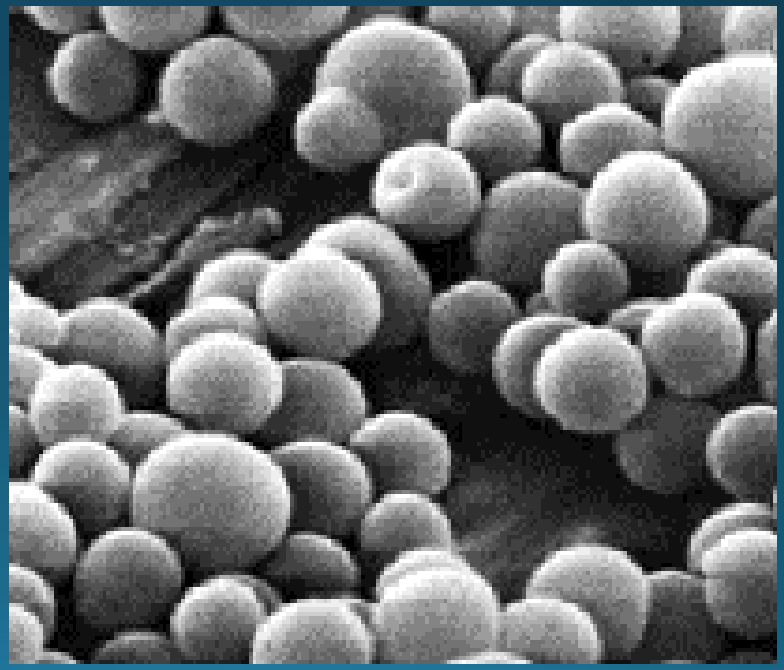

CEUS

- NICE 2013 and EFSUM/WFUMB 2012 guidelines
- Proven to work well in echo and liver
- Now blunt trauma (esp. kids following FDA approval for use in children)
- GB, Kidneys, EVAR, anywhere where you want to know about blood flow

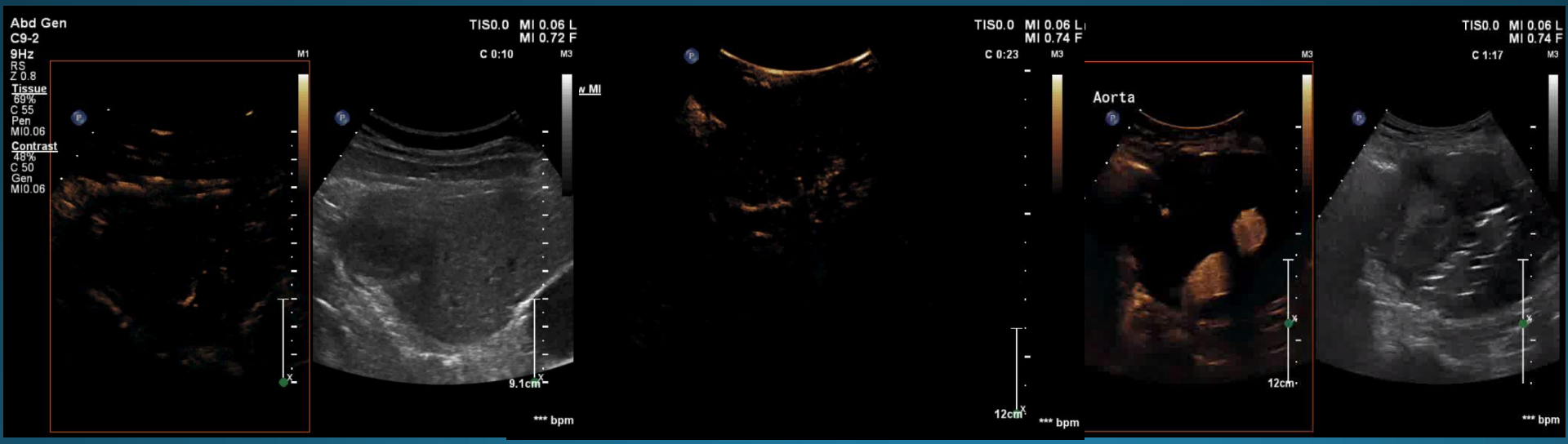

CEUS ex-vivo perfusion

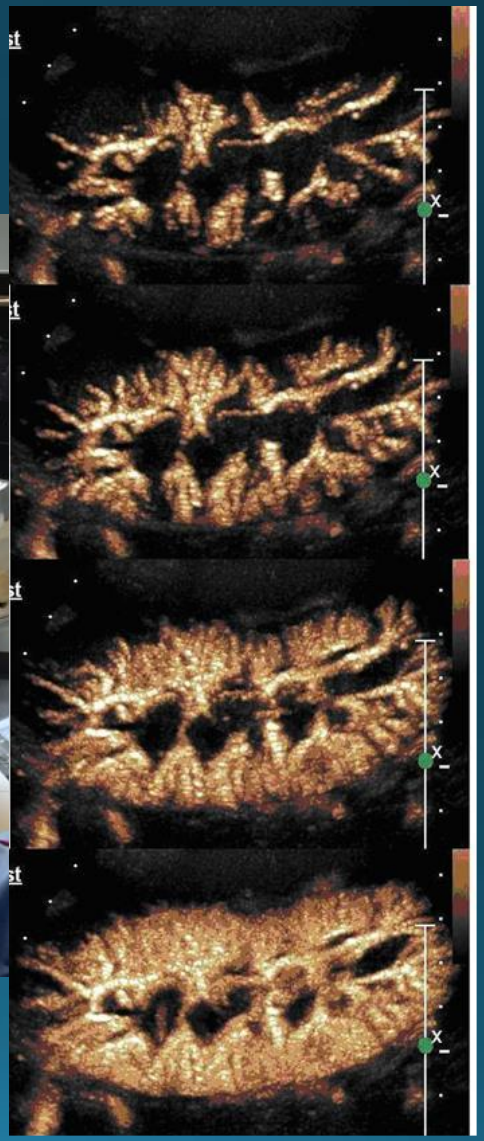

However…

- Sometimes you are following up a lesion with CEUS, biopsy or ablation from MR or CT and you cant find it.
- "If you cant see it you cant interrogate it."
- Particularly important in Ablation in theatre where MRI, PET or CT may not be available
- Not any more…
- We have Fusion

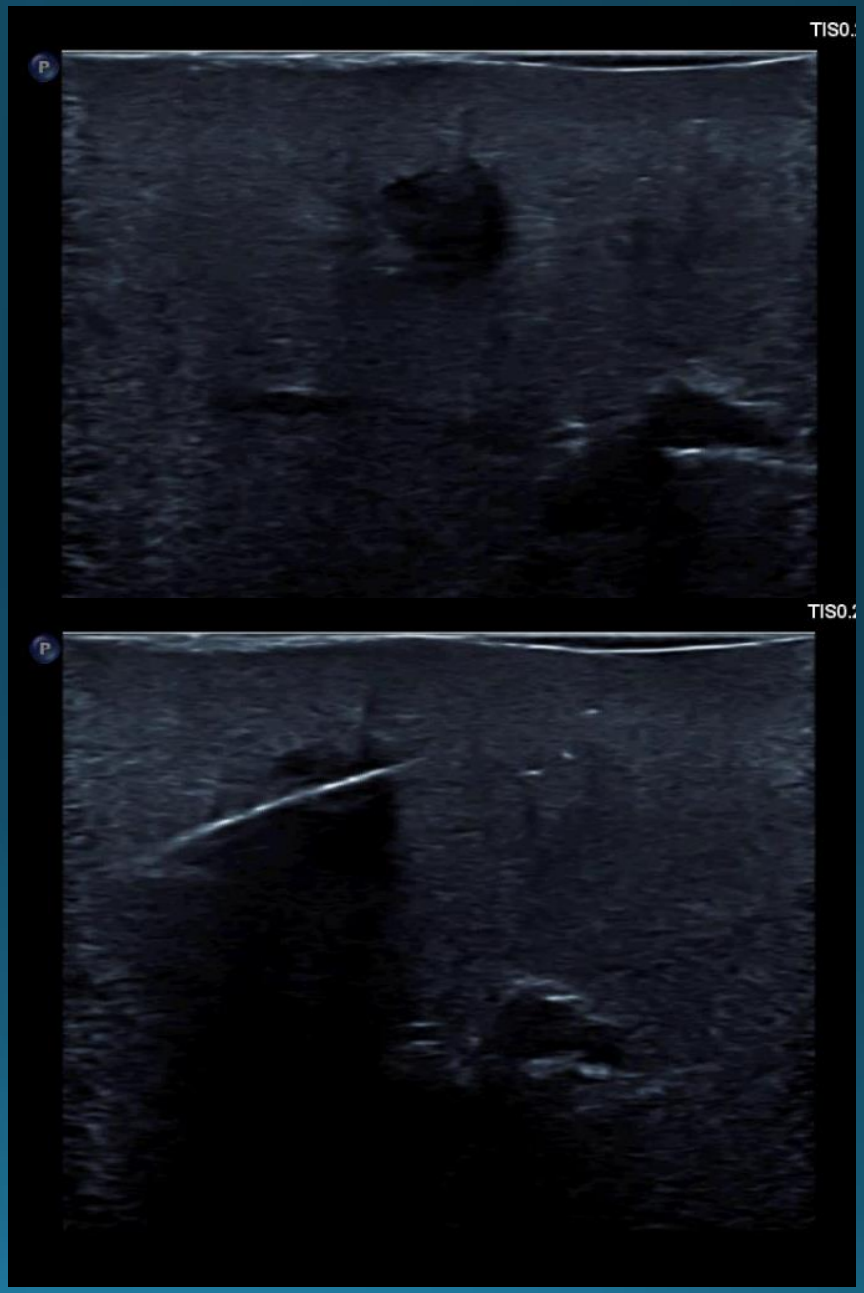

How does it work?


Cine Speed
1
Support
Dual
Zoom
Acquire 2
C5-1


C5-1
PureWave


NUFC

Auto registration

Final product…

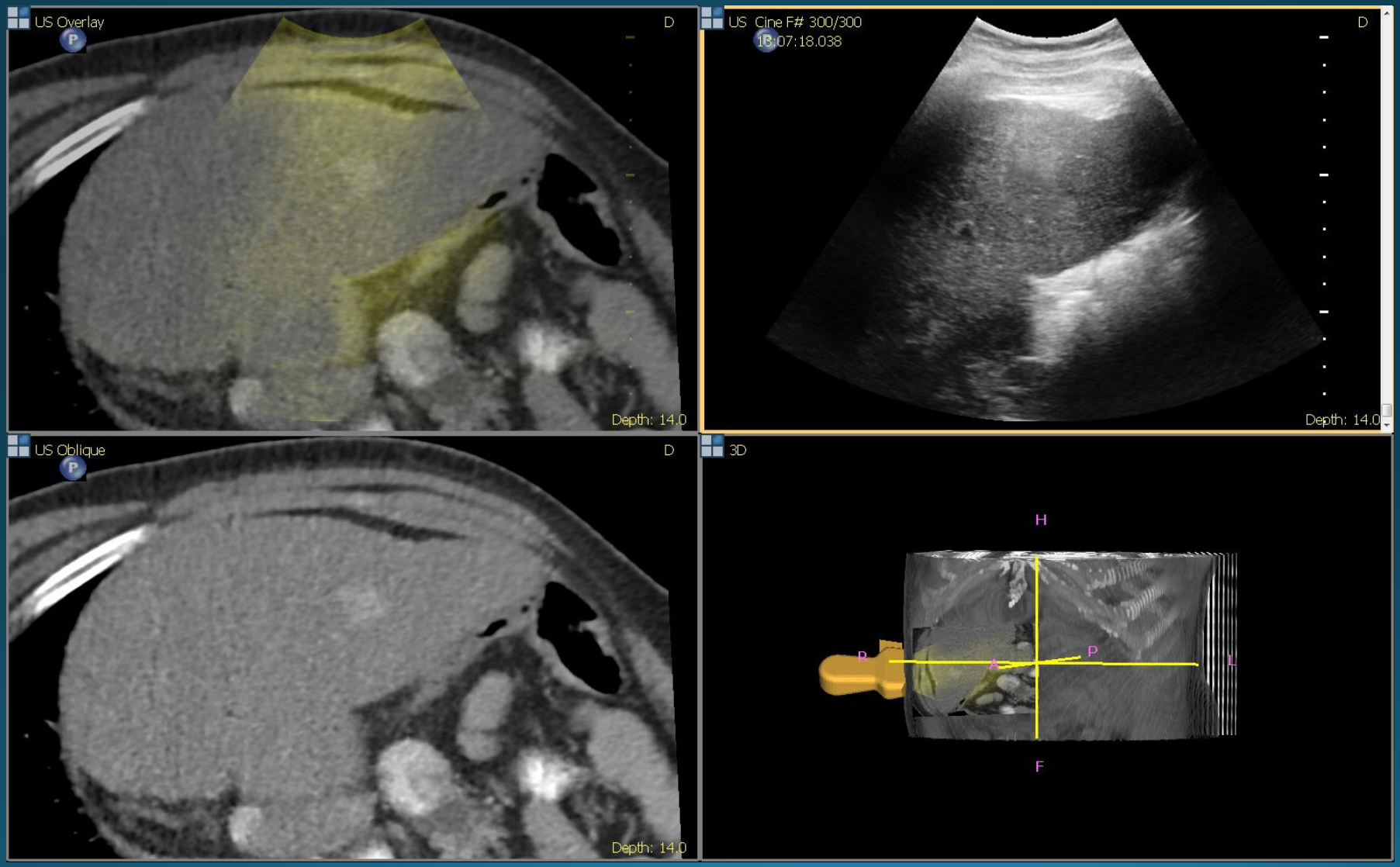

Case 1- making a difference

- 72 YO male with NASH Cirrhosis
- MRI shows HCC
- Co morbidities make transplantation unlikely

- Ablation is only curative treatment option

Baseline MRI

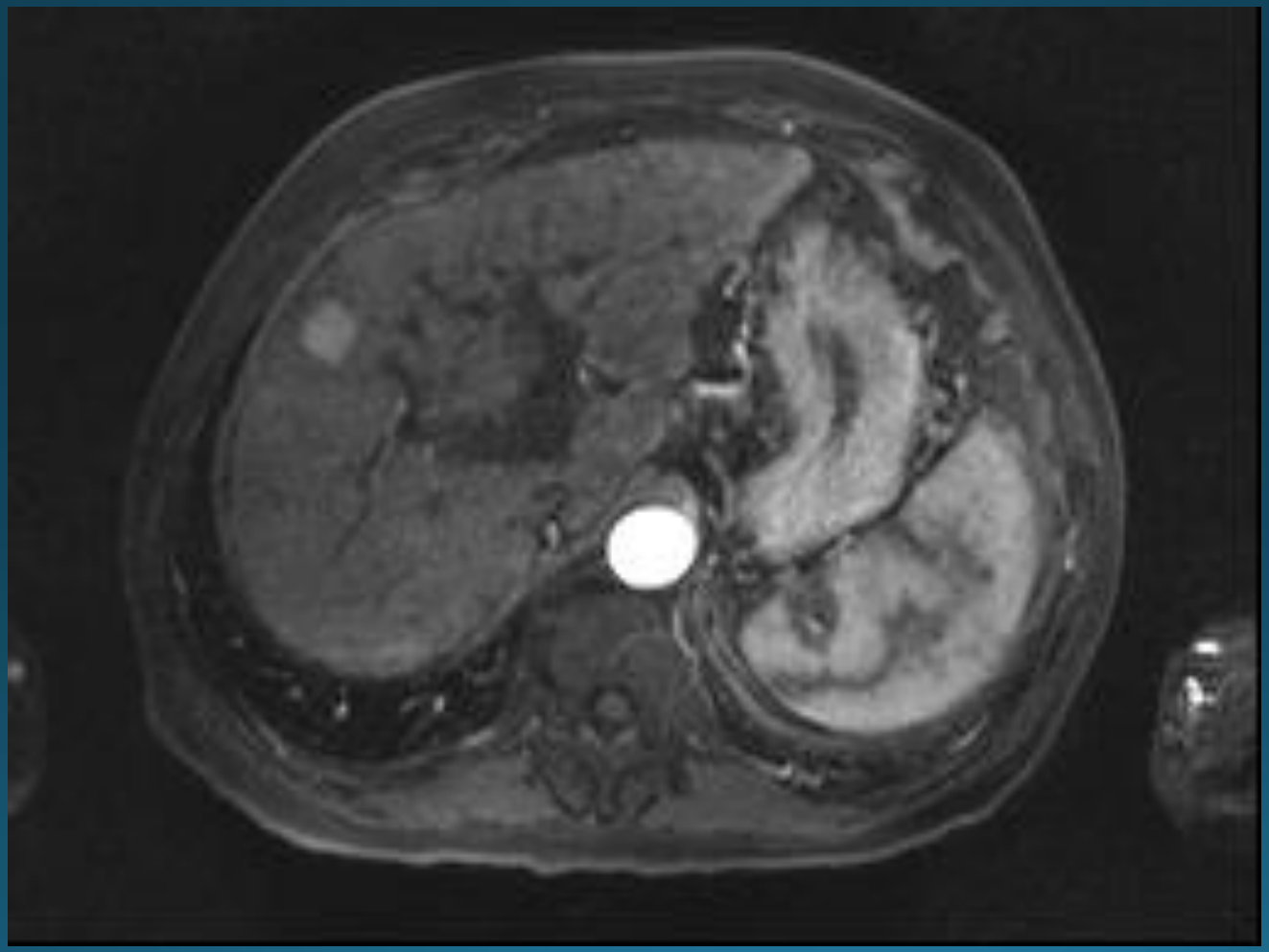

Could not see HCC due to macronodular cirrhosis.

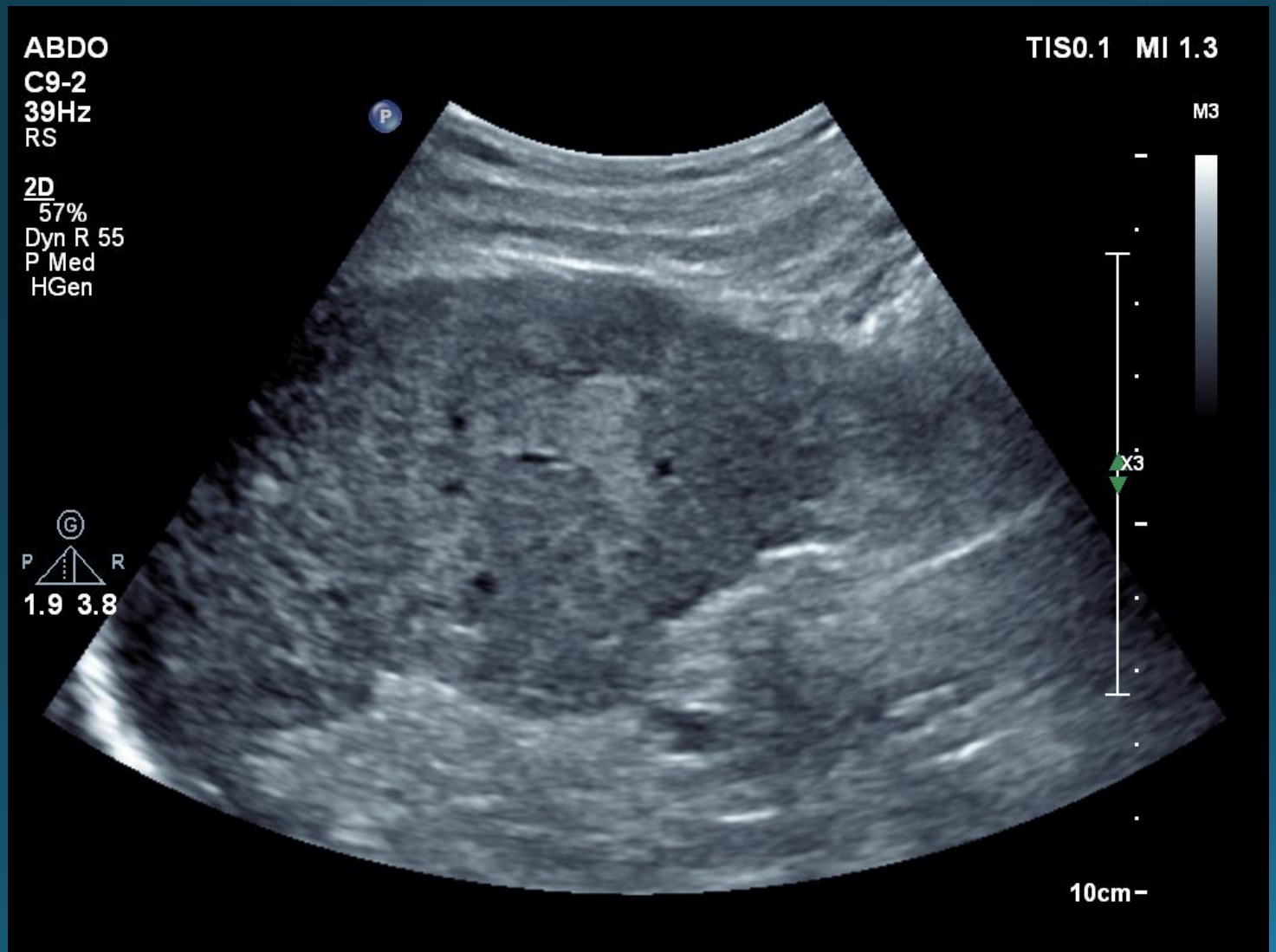

Tried CEUS but without a lesion to focus on very patchy enhancement makes it impossible.

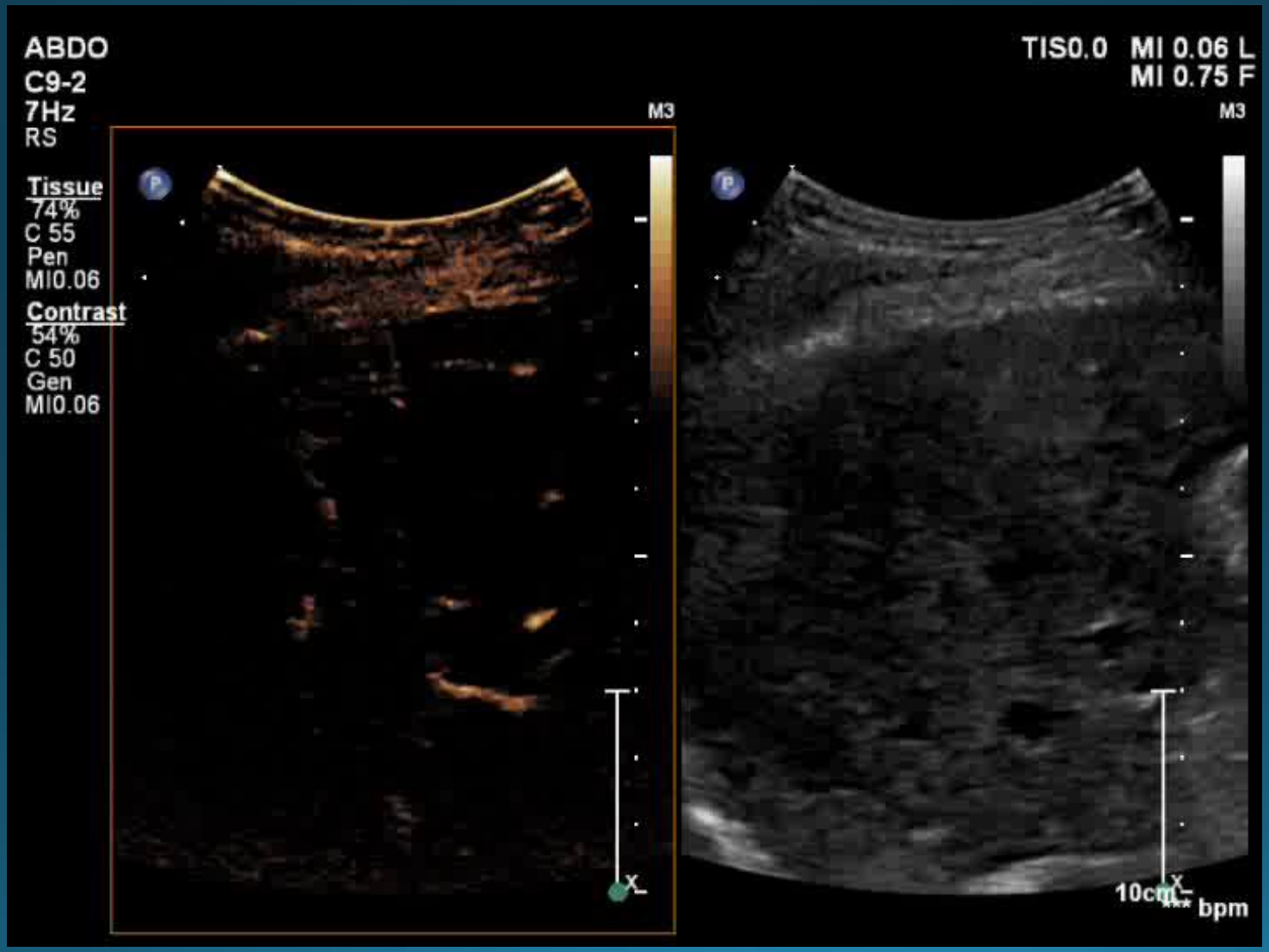

Automatically detects vessels in MRI dataset and 3D US sweep through liver

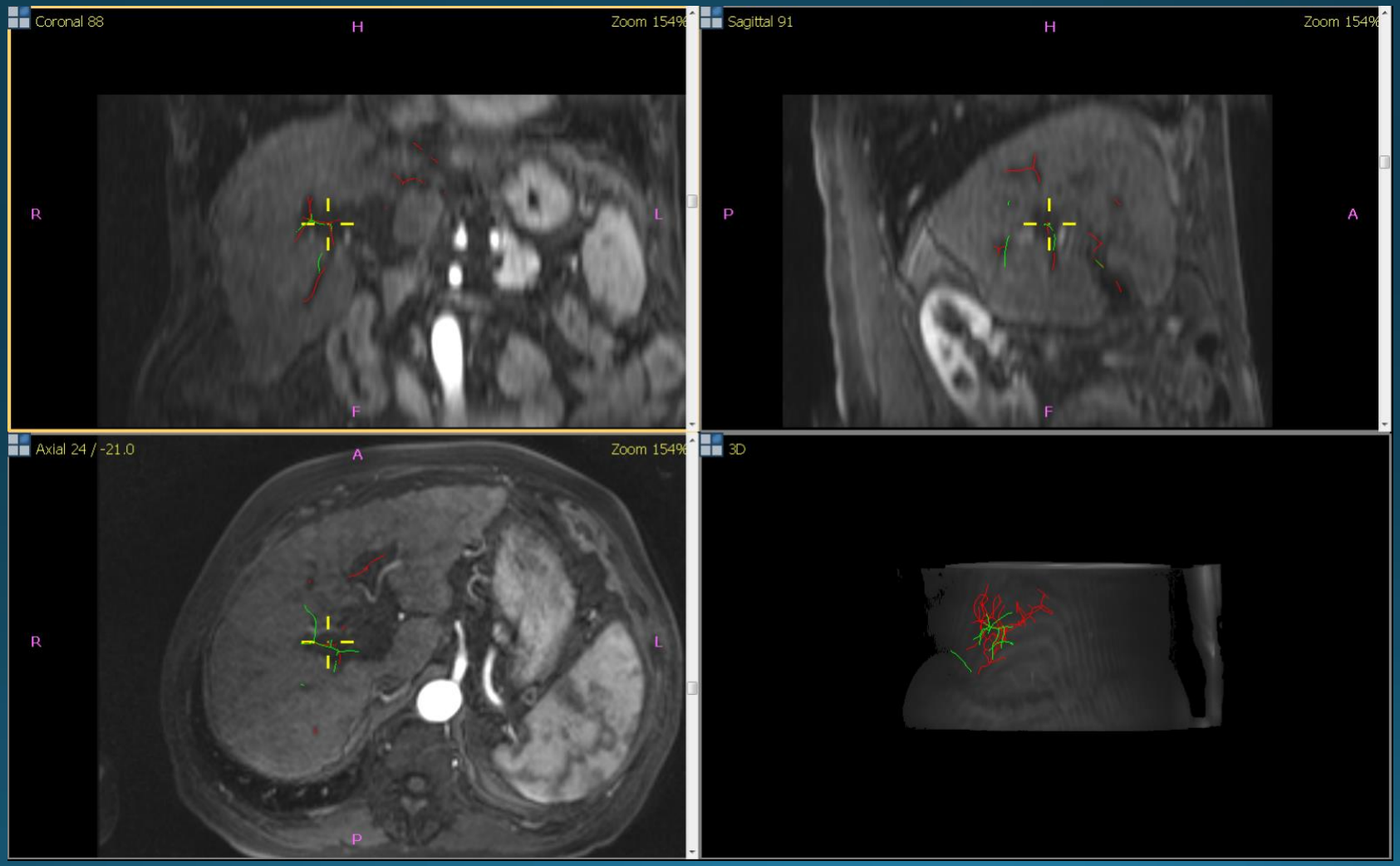

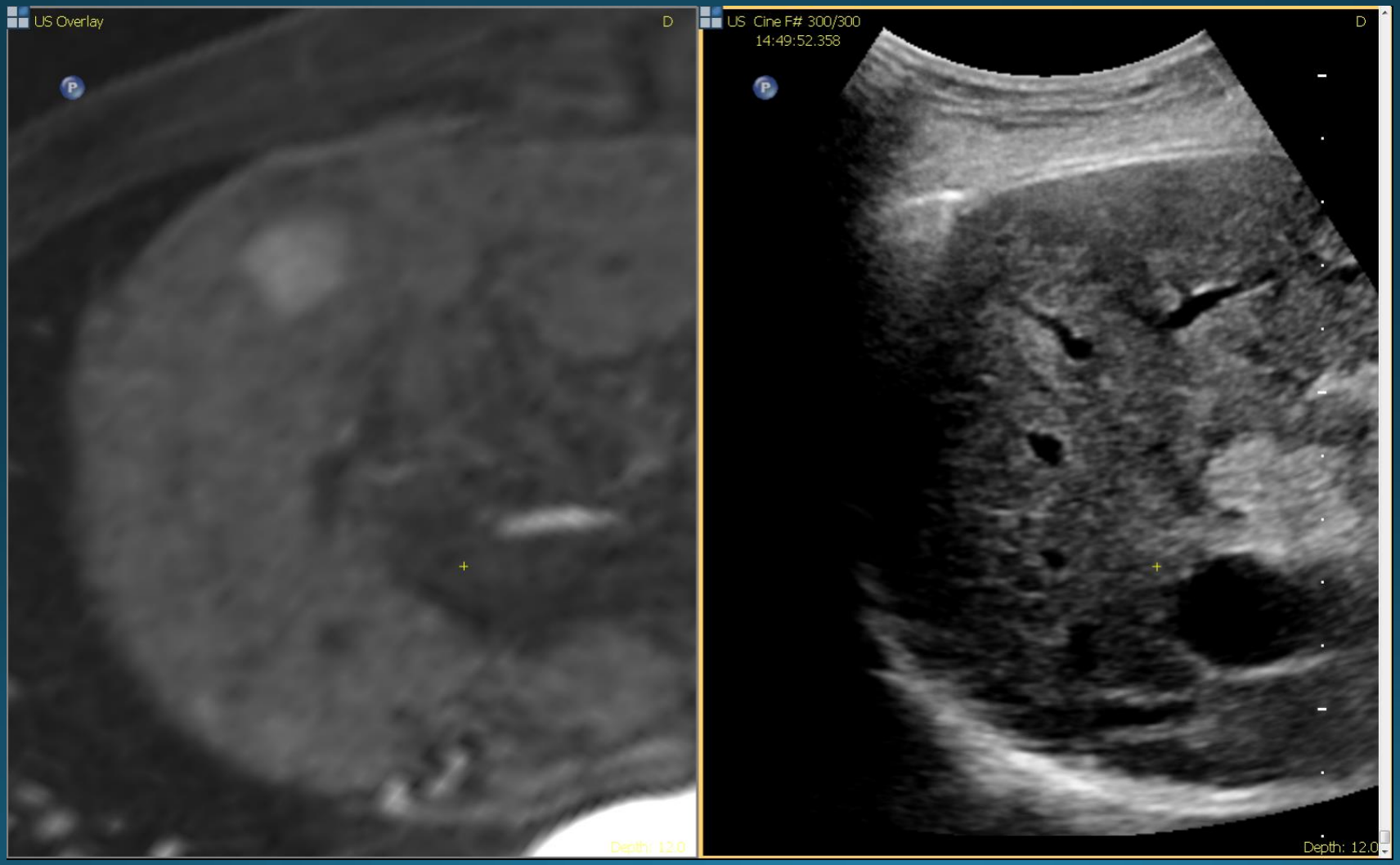
US Overlay
D
US Cine F# 300/300
14:49:52.358
D
Depth: 12.0

- CEUS confirms the fusion.
- Makes ablation under auto-registration MRI/US fusion with CEUS possible

Not just for livers…

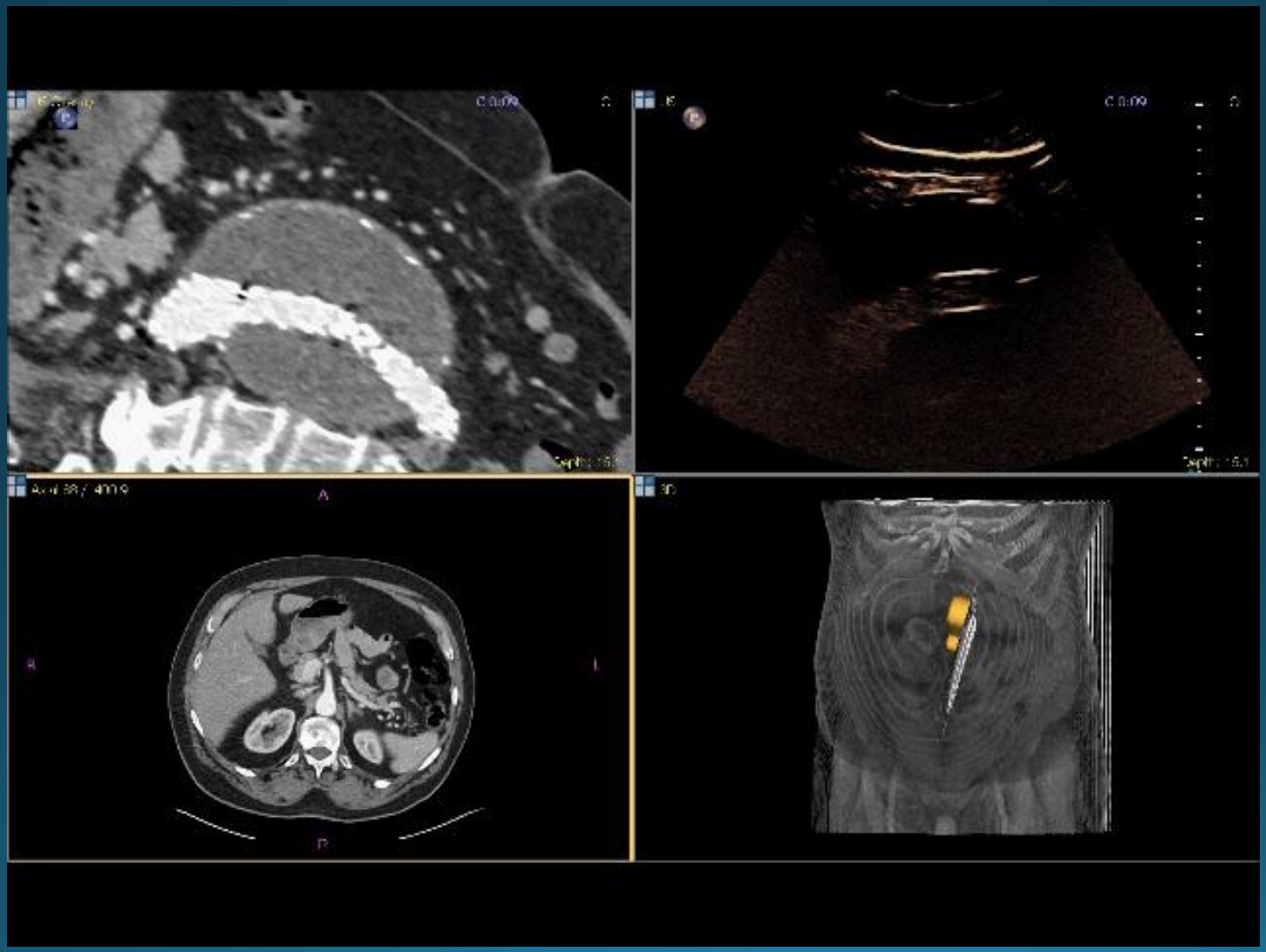

Requirements for fusion guided intervention

- Hardware same as diagnostic but also need a needle tracker.

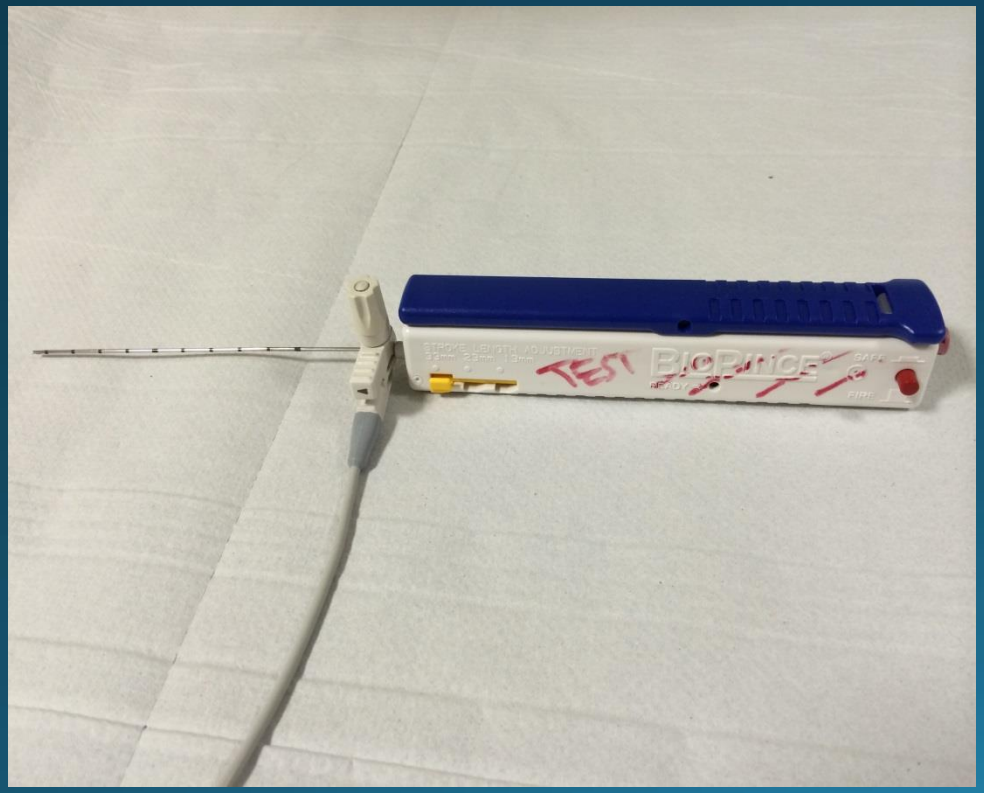

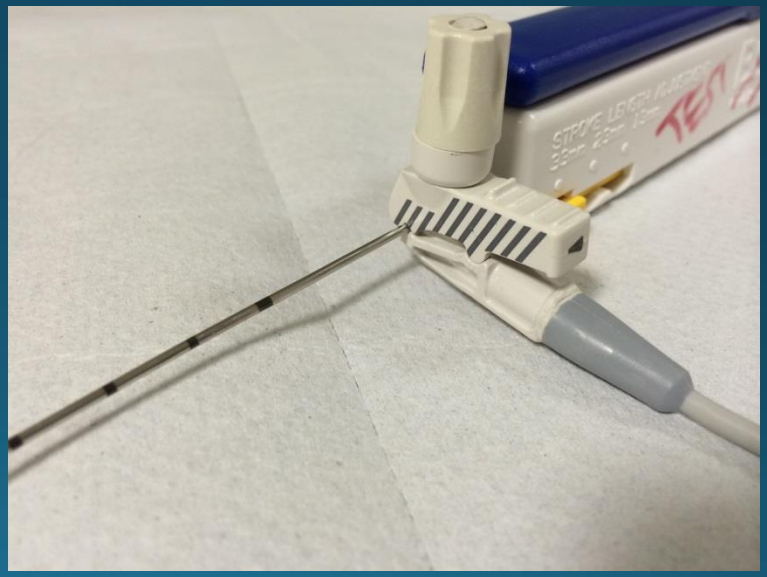

Putting it all together



Other uses of probe tracking

- Breast tracking solution.

Artificial intelligence

- Assisted diagnosis
- Auto-labelling
- Auto-imaging

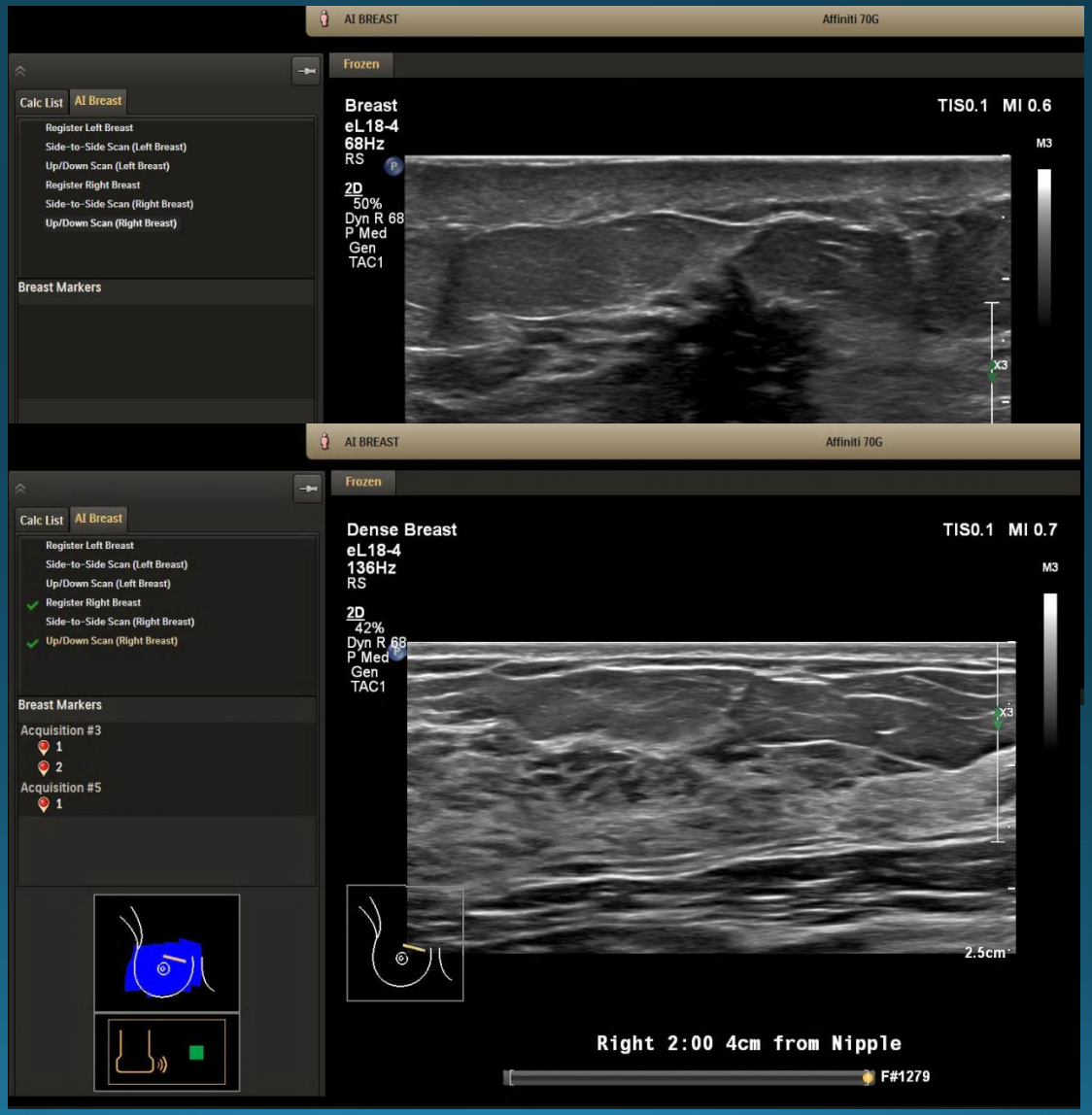

36 seconds

Miniaturisation- US guided TORS

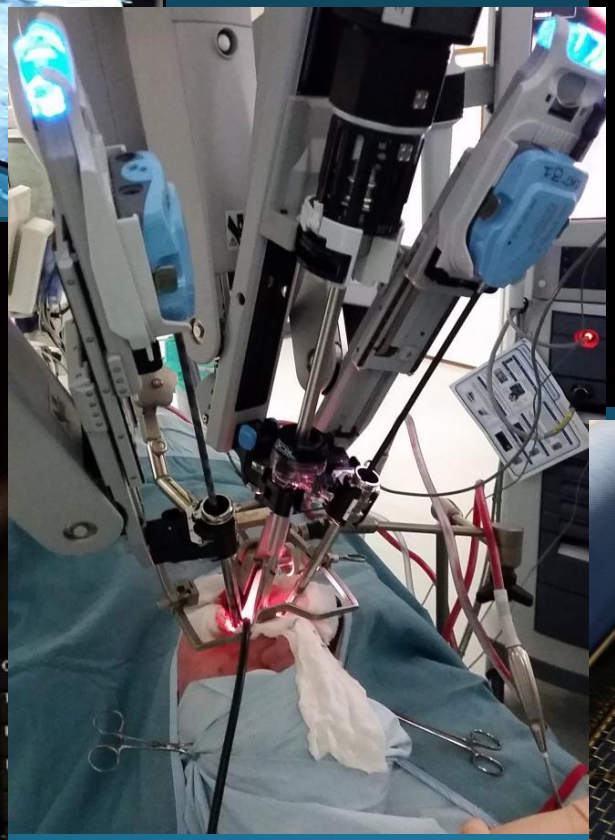

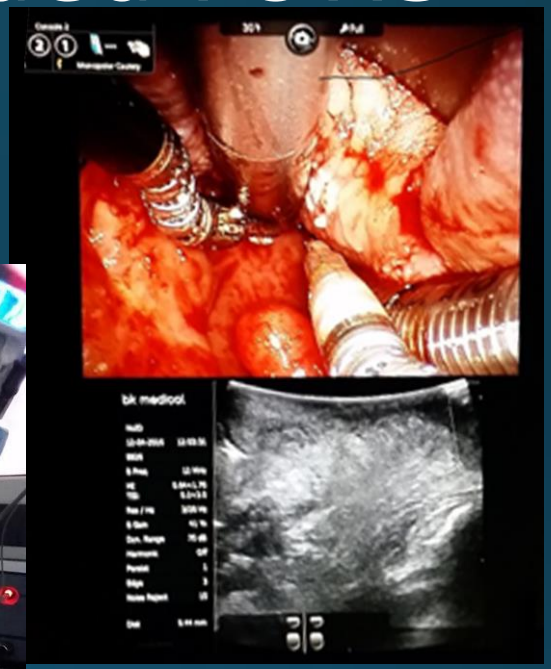

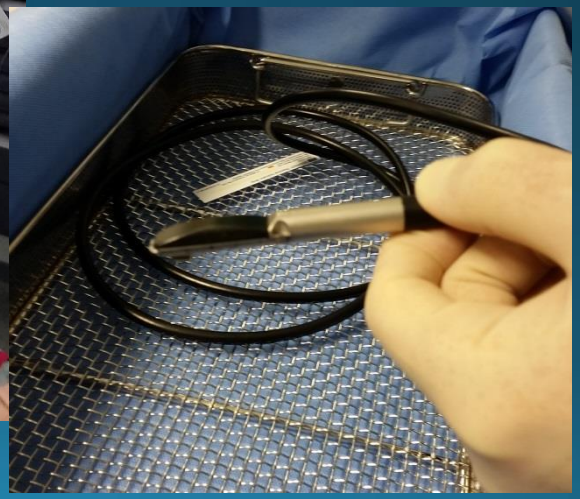

New fields in ultrasound



- Used routinely in vet surgeries but also used in rare species breeding programs such as white rhinos, panda, etc.

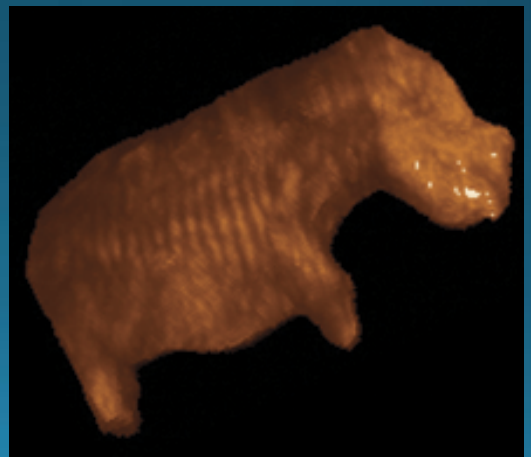


EVO


EVO
B CL3E
5.0MHz
D 15.0cm
Abdominal
G 34dB
N 36dB
F 55dB
User1


Scientists Capture First-Ever Tiger Shark Sonogram
0:31 / 2:10

New fields in ultrasound

Drug and Gene therapy delivery

- Bursting micro-bubbles causes sonoporation.
- Temporary break-down of cell walls
- Allows micro-bubbles contents to pass out of the intravascular space and over cell membranes.

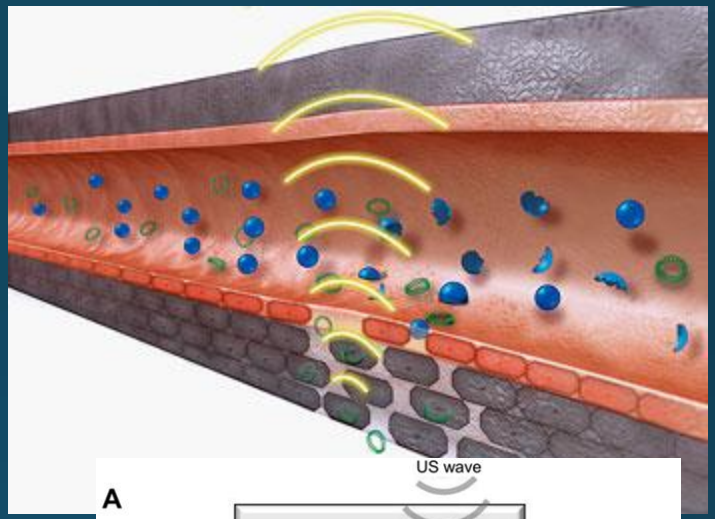

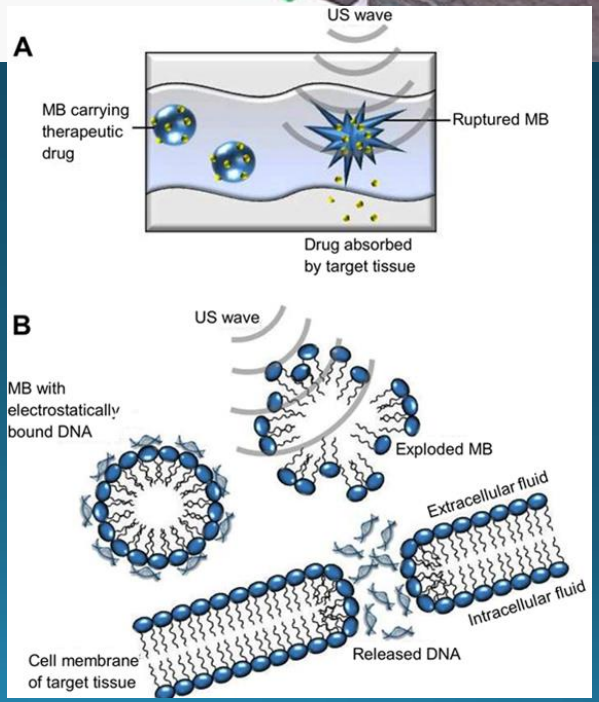

Targeted drug delivery

- Microbubbles can be filled with a range of substances.
- Original research used fluorescent tracers.
- Testing delivering clot busting drugs, anti-angiogenesis drugs direct to tumours, targeted ablations.
- Genetic imaging allows targeted ligands specific to the patient or tumours specific genetic code.

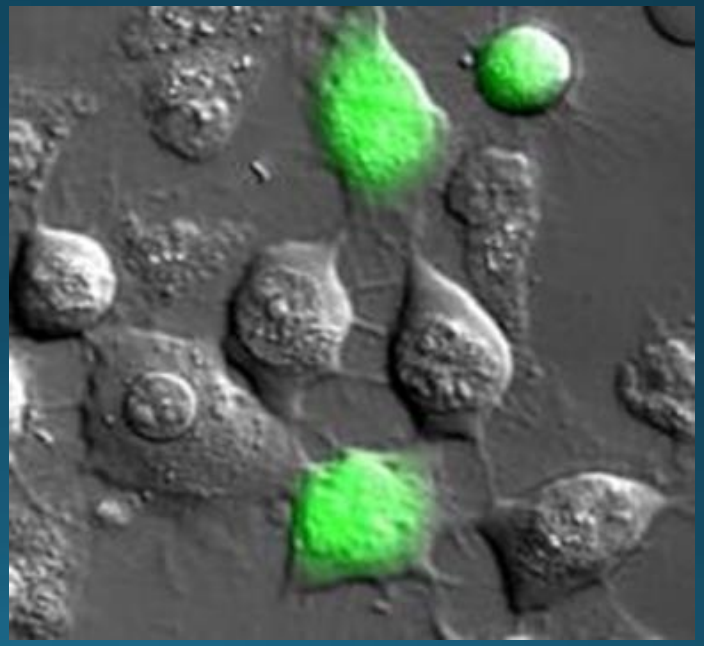

Future of US machine

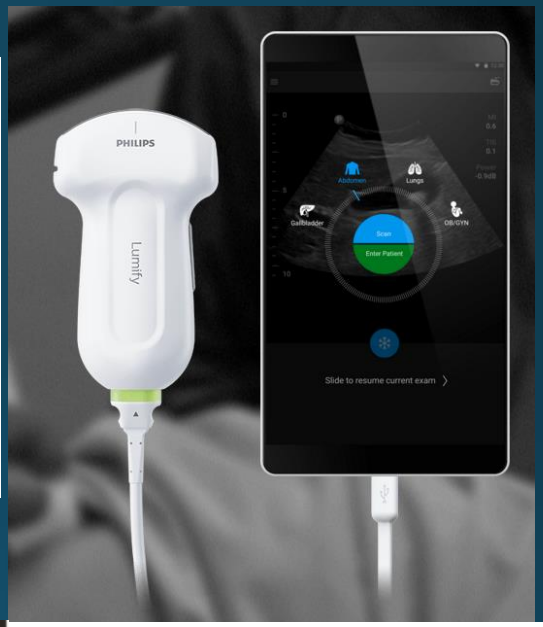

Future direction

- Difficult to say as companies are reluctant to give anything away.
  - Computer assisted diagnosis/ measurement
  - Novel beam forming and post-processing with parallel processing for b-mode and Doppler
  - Different control methods (voice, transducer, gesture)
  - New contrast media for longevity and differing frequencies
  - Drug delivery
  - Ergonomics making machines smaller, lighter, faster

- We shall have to wait and see!

Thanks to

Dr MAF McNeill

Dr ST Elliott

Dr PJ Haslam

Dr McQueen

Jim Edwards