Diaphragmatic Ultrasound: Technique and Cases

PENINSULA RADIOLOGY ACADEMY

Hamilton S, Ramachandraiah S, Riordan R, Gutteridge C

Plymouth Hospitals NHS Trust

BMUS THE BRITISH MEDICAL ULTRASOUND SOCIETY

Introduction

As a consequence of it's non specific presentation, diaphragmatic dysfunction is commonly under diagnosed. Symptoms include dyspnoea, asymmetric breathing, paradoxical movement of the epigastrium, recurrent pneumonia or unilateral collapse, and in mechanically ventilated patients slow respiratory weaning. Diaphragmatic paralysis can be caused by a wide variety of pathologies (see table below). Prompt diagnosis is important because some causes are amenable to treatment and provision can be made for longer term ventilatory support. Ultrasound combines many of the strengths of other imaging modalities offering assessment of both structure and function in a non- invasive, real time manner at a location of choice (bedside or ultrasound room).

Probe position

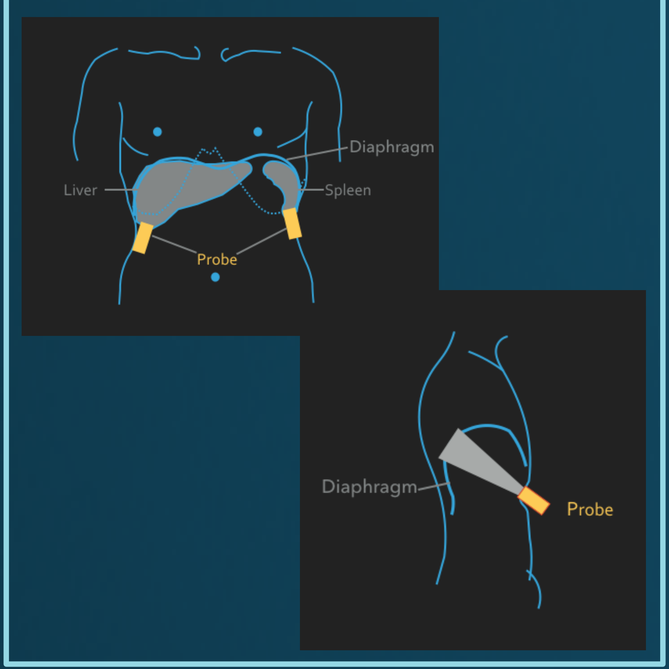

Technique

The method utilises M mode to assess the excursion of each hemidiaphragm. A 3.5-5MHz phased array probe is used. The patient is positioned in the supine or semi supine position. If dyspnoea precludes this, the erect position may be used.

Right hemidiaphragm

The probe is placed in the subcostal area between mid clavicular and anterior axillary lines, and directed medially ,cranially and dorsally aiming to use the liver as a window so that the beam reaches the posterior 1/3 of the right hemi diaphragm. Greyscale (B) mode is used to appropriately position the probe. M mode is then used to record diaphragm movements.

Left hemi diaphragm

A similar position is chosen on the left, in either an intercostal or subcostal position, anticipating the normal lower position of the left hemidiaphragm. The spleen is a smaller acoustic window than the liver and thus it may be more difficult to obtain views on the left .

Causes of diaphragmatic paralysis[1-3]

Neuropathic	Myopathic	Other
Spinal cord transection	Myaesthenia gravis	Adjacent pathology • Pleural fluid/Ascites • Upper abdominal masses
Cervical spondylosis	Polymyositis	
Multiple sclerosis	Muscular dystrophies	
Motor neurone disease		
Guillain Barre syndrome		
Polio		
Phrenic nerve dysfunction • Tumour compression • Blunt trauma • Idiopathic • Iatrogenic Post radiation Cardiac surgery - cold injury, traction, cautery		

Normal findings

On both quiet and deep inspiration, normal movement of the hemidiaphragms is down wards as the anterior chest wall moves upwards. This may be asymmetric and there may be a lag on one side (commonly the right).The excursion of the posterior aspect of the hemidiaphragm is often greater than the anterior part, particularly on the right, so the probe is angled to capture this.

On M mode US we see the normal diaphragmatic descent (towards the probe) as an upward inspiratory slope.

On sniffing both hemidiaphragms move downwards (M mode deflection upwards). Again there may be asymmetry or lag (again commonly right sided). In very vigorous sniffing there may be momentary slight paradoxical upward movement of the anterior aspect of the hemidiaphragm.

Interpretation

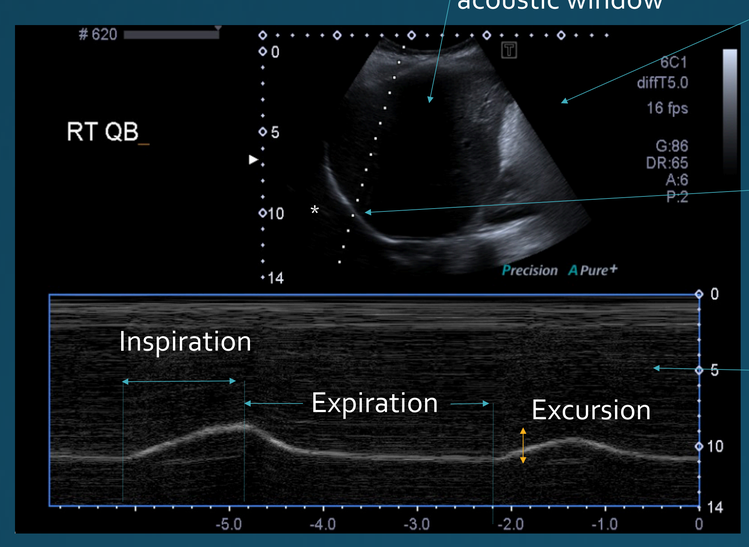

Diaphragmatic excursion

Assessment commences at end expiration. Excursion correlates with sex, height and weight. It is greatest in the supine position. Some authors cite ranges, which may be helpful to assess weakness[1,2]. For example:

- Quiet breathing (QB) : 1.5-2cm. Lower limit 0.9 female, 1cm male
- Deep breathing (DB): 6-7cm. Lower limit 3.7cm female, 4.7cm male.
- Voluntary sniffing (VS): 2.5-3cm 1.6cm female 1.8cm male

Normal traces

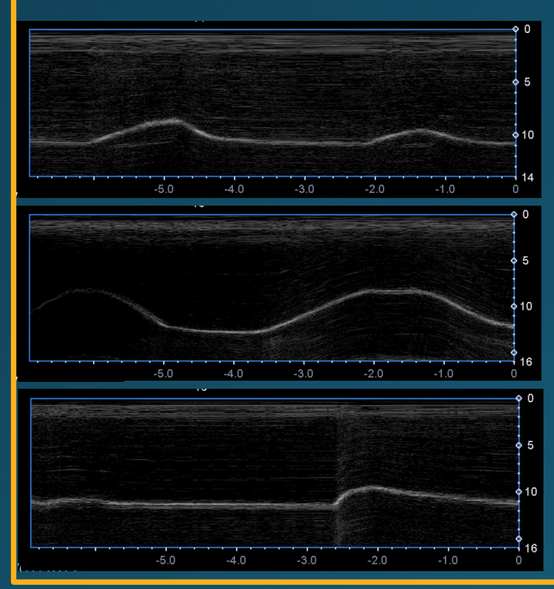

Abnormal findings

Unilateral paralysis – absent or paradoxical excursion on quiet or deep breathing. Paradoxical movement on sniffing

Bilateral paralysis – bilateral absent or paradoxical motion

In weakness excursion is reduced or delayed on quiet and deep inspiration. If severe, excursion may be paradoxical on deep breathing (particularly anteriorly). On sniffing, motion is usually paradoxical.

Case – left hemidiaphragm paralysis

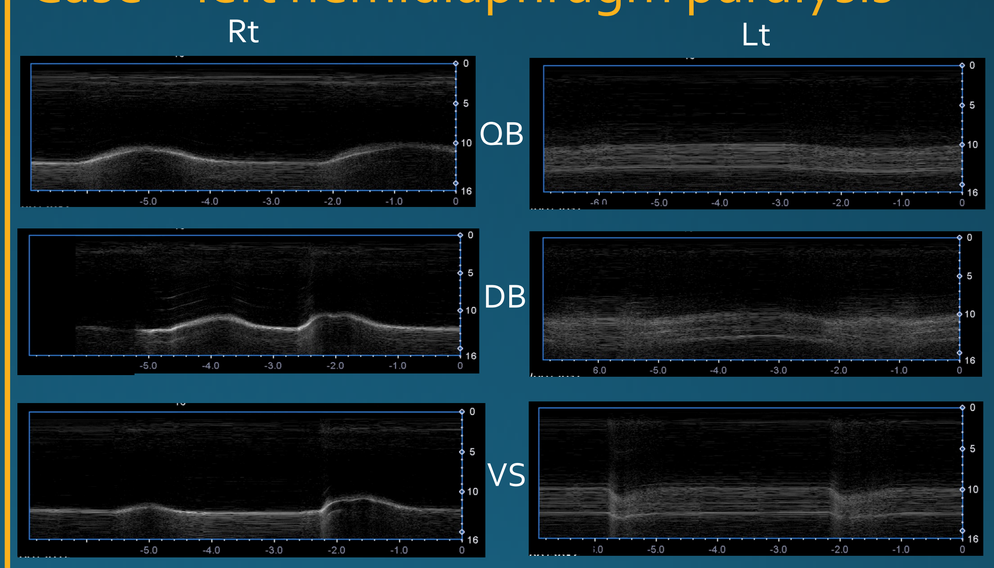

Normal M mode traces from the right hemidiaphragm. In contrast, on the left during quiet breathing there is no discernable diaphragmatic movement, with subtle paradoxical movement (downwards deflection on M-mode) during deep breathing. Confirmation of left hemidiaphragm paralysis is demonstrated during voluntary sniffing, with definite paradoxical motion.

Challenges

- During deep breathing descending lung may obscure the diaphragm – try displacing the probe caudally and adjust angle to remain at 90 degrees to hemidiaphragm
- Increased respiratory effort can result in greater chest wall movements so ribs and lung obscure images in dyspnoeic patients
- Smaller splenic window makes views of left hemi diaphragm more technically challenging to obtain than right

Summary

Evaluation of the diaphragm with M mode is a straightforward and relatively quick technique . Although not new it currently lies outwith the skill set of many experienced sonographers and radiologists, commonly falling to critical care or respiratory physicians. At a time when clinicians are looking for added value we suggest that diaphragmatic ultrasound is easy to learn and a useful skill to retain within the imaging department.

References

1. Boussuges A, Gole Y, Blanc P. Diaphragmatic motion studied by M-mode ultrasonography: methods, reproducibility and normal values. Chest 2009;135;391-400.
2. Gerscovich E et al. Ultrasonographic evaluation of diaphragmatic motion. Journal of Ultrasound in Medicine 2001; 20:597-604.
3. Nason et al. Imaging of the diaphragm: anatomy and function. Radiographics 2012; 32:E51-70.