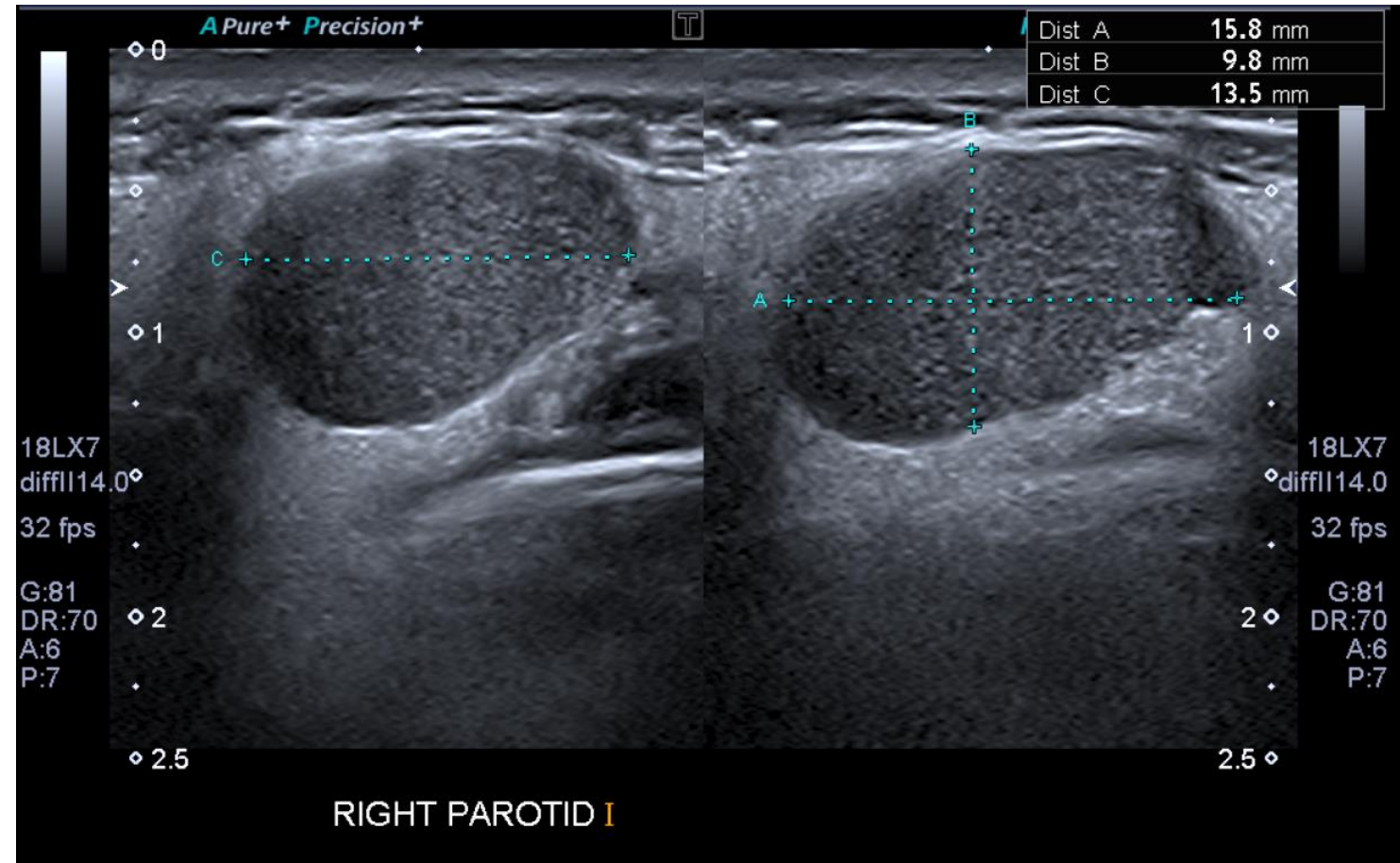
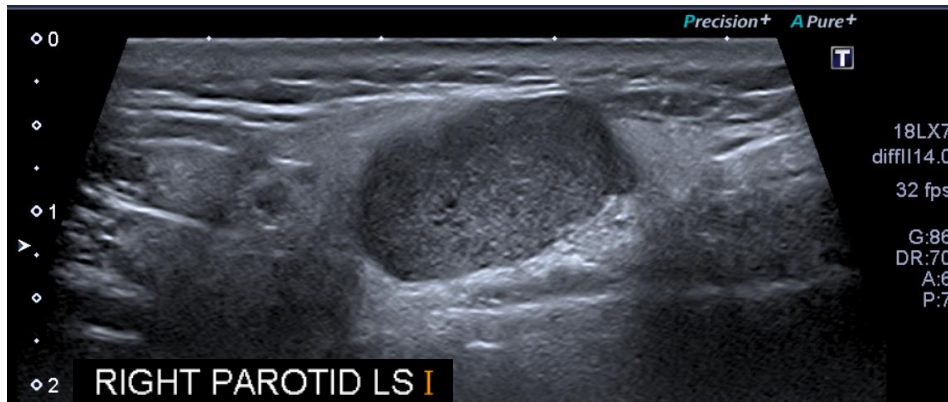


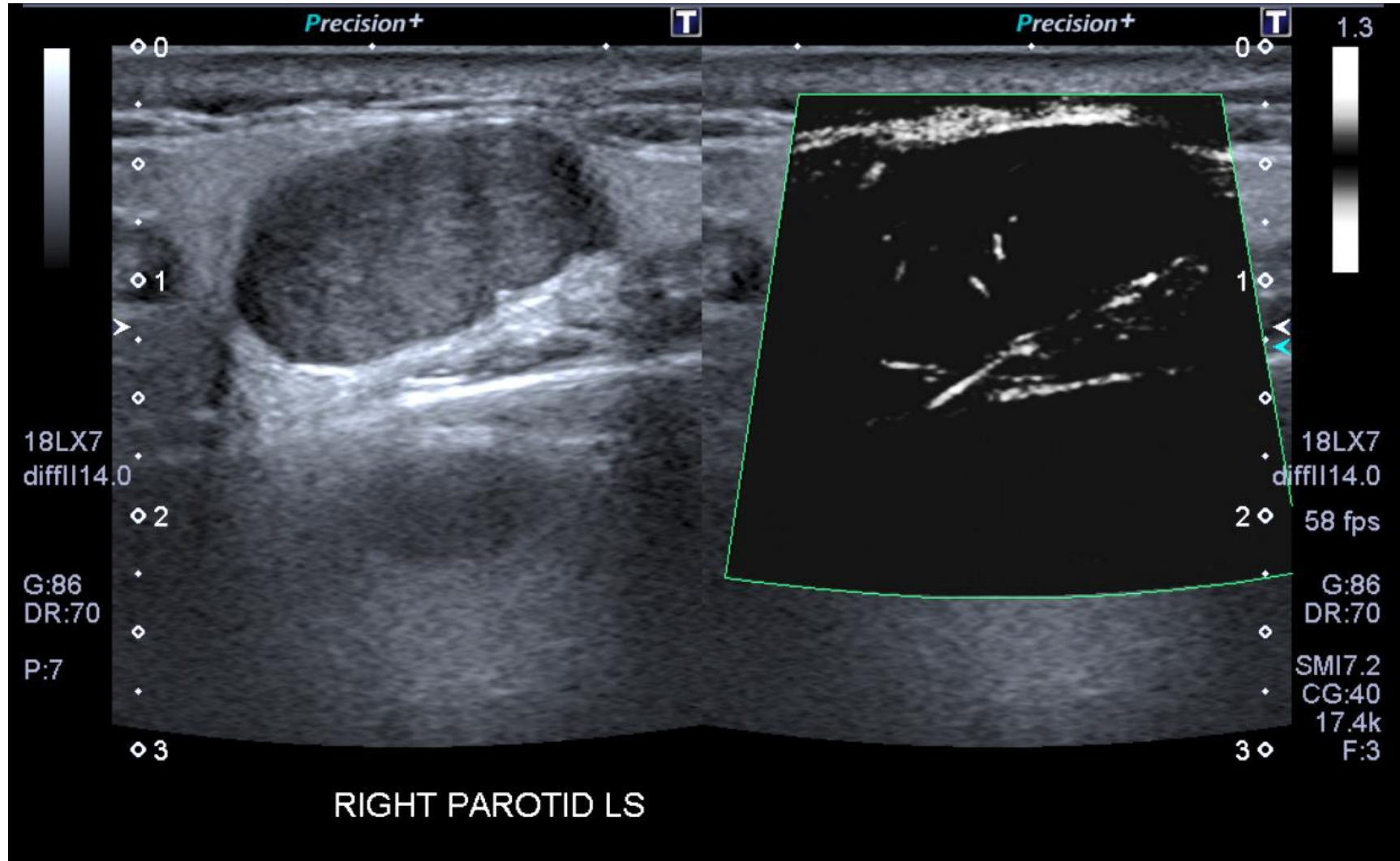
Head and Neck Case 2

March 2023

Clinical details:

Urgent (2ww) lump in parotid gland, growing over 6m.
Starting to get tender. ? adenoma ? cause





Do not progress to next slide until you have attempted to write your own report

US Report:

The palpable swelling, as indicated by the patient, corresponds to a 16 x 10 x 14 mm well-defined, lobulated, homogeneous mass with minimal internal vascularity. Appearances are suspicious for pleomorphic adenoma or benign salivary gland tumour.

Normal appearances of the remaining right parotid, left parotid and both submandibular glands.

No abnormal lymphadenopathy identified in either side of the neck.

The thyroid gland is normal in size and appearance.

Conclusion:

Probable right parotid pleomorphic adenoma. Please refer to the Head and Neck lump clinic for further management.

This report contains a serious, unexpected or urgent finding, requiring acknowledgement.

The patient is aware of the ultrasound findings.

Pleomorphic Adenoma Fact File

Epidemiology/Incidence:

Pleomorphic adenoma is the most common benign salivary gland neoplasm. It represents 45-75% of all salivary gland tumours. Annual incidence is approx three cases per 100,000 population and it occurs more frequently in females.

Risk factors:

Age, smoking habits, alcohol abuse, cholesterol rich diet and previous radiation exposure to face and neck region.

Symptoms:

The signs and symptoms of pleomorphic adenoma typically include the growth of a smooth, painless mass on one side of the face that gradually enlarges over time. It typically begins as a painless lump at the back of the jaw, just below the earlobe.

Treatment:

Superficial or total parotidectomy. Total is favoured to minimise risk of recurrence.