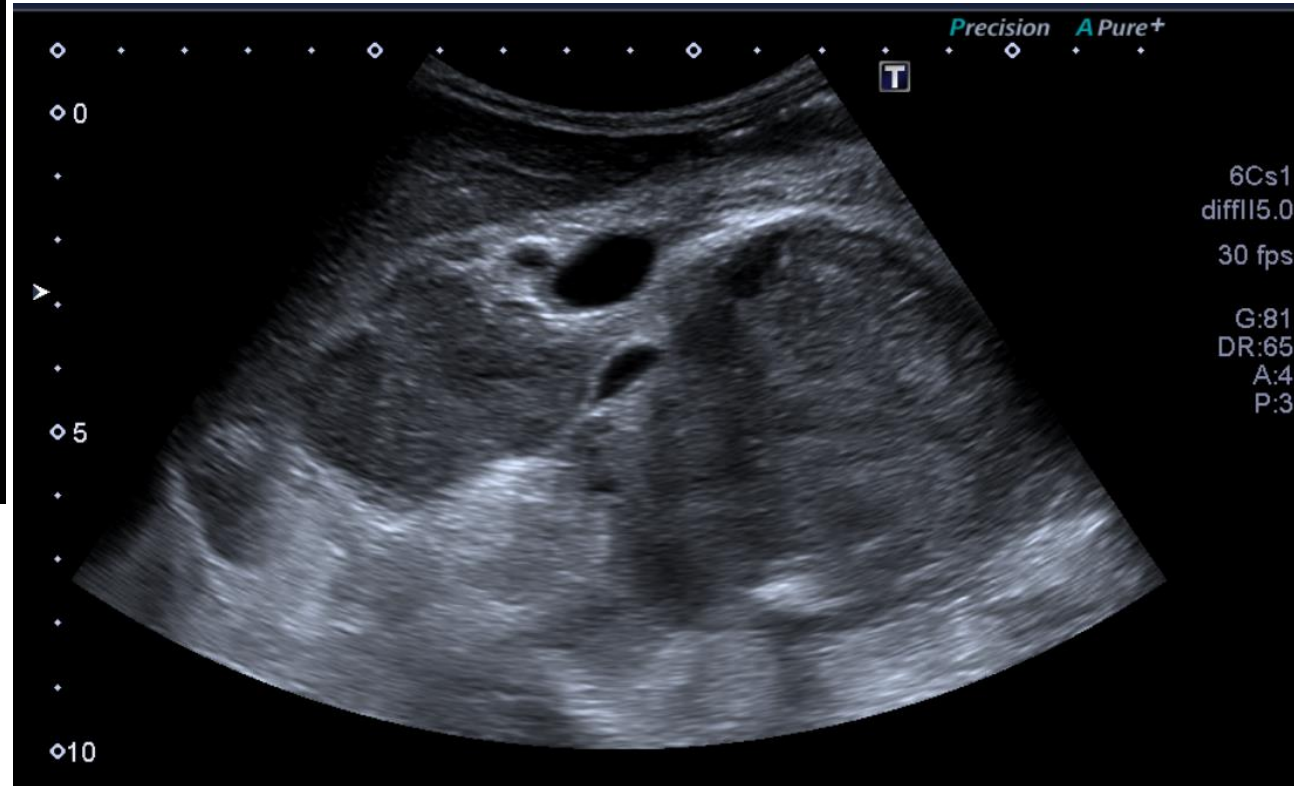
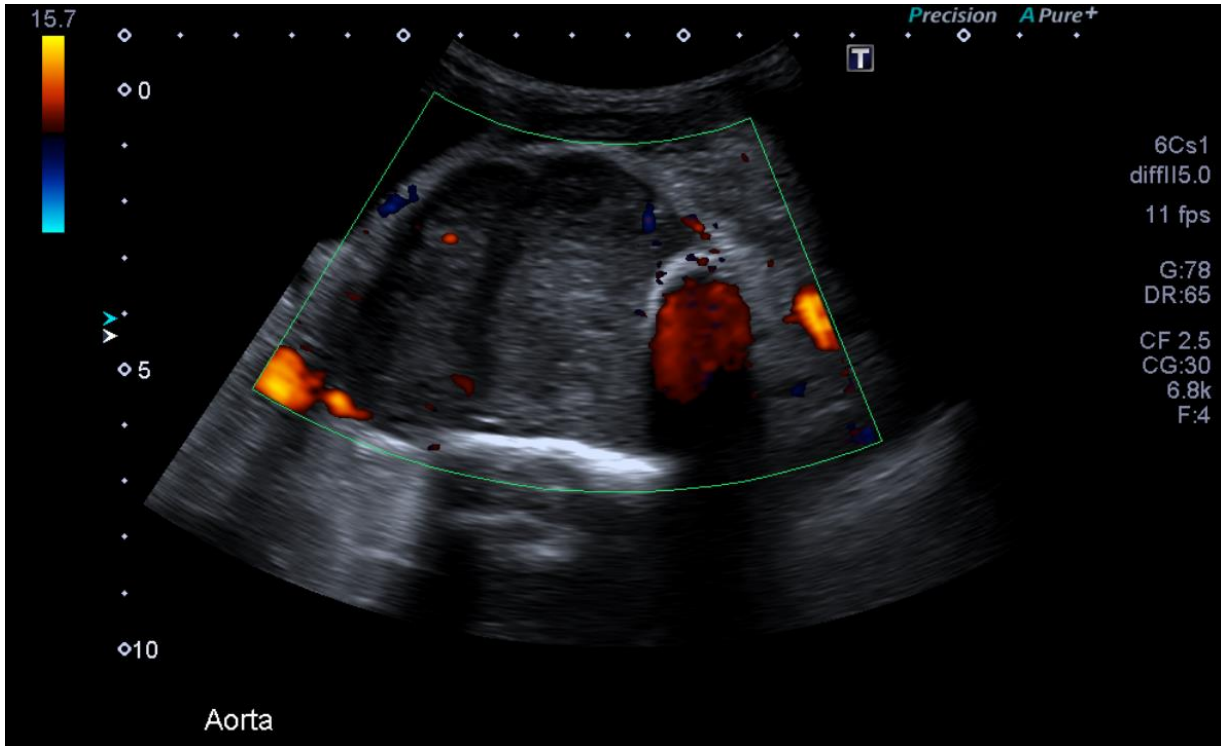


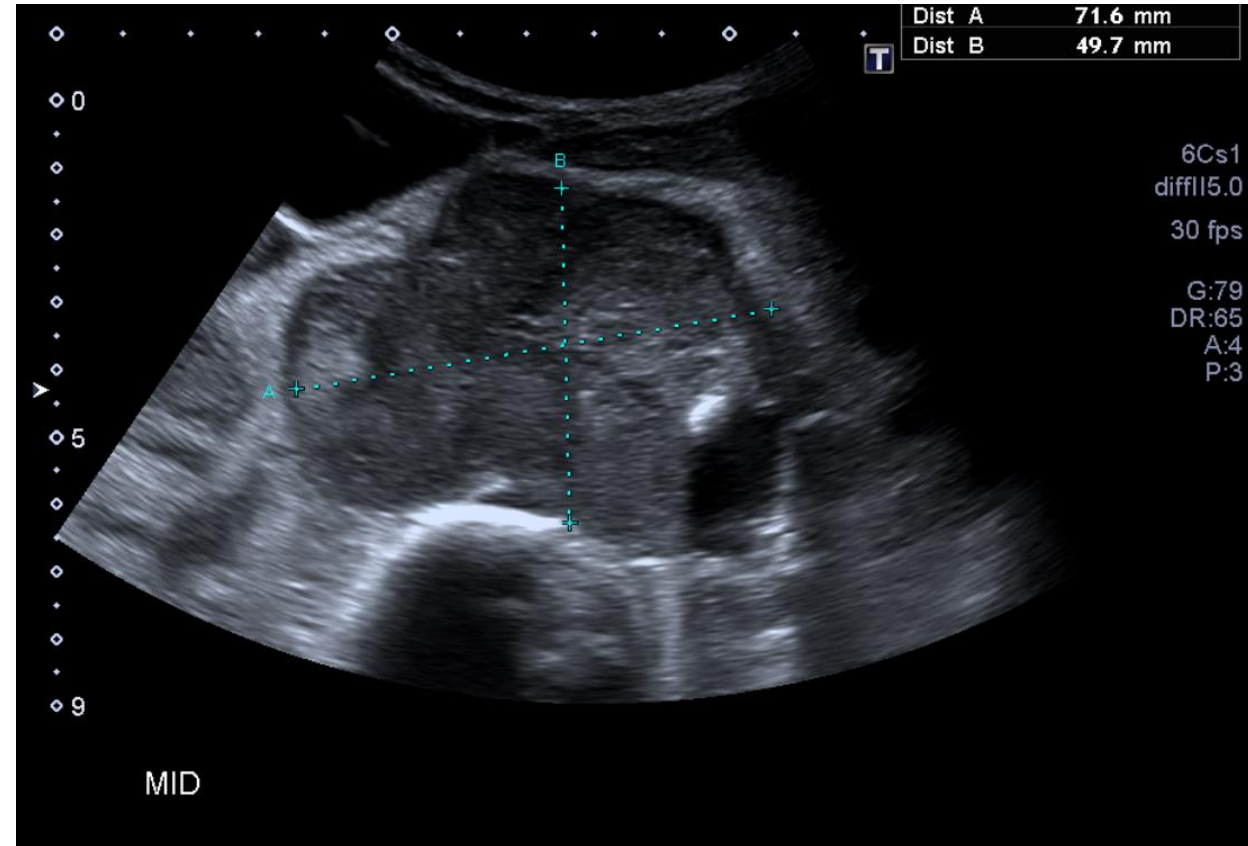
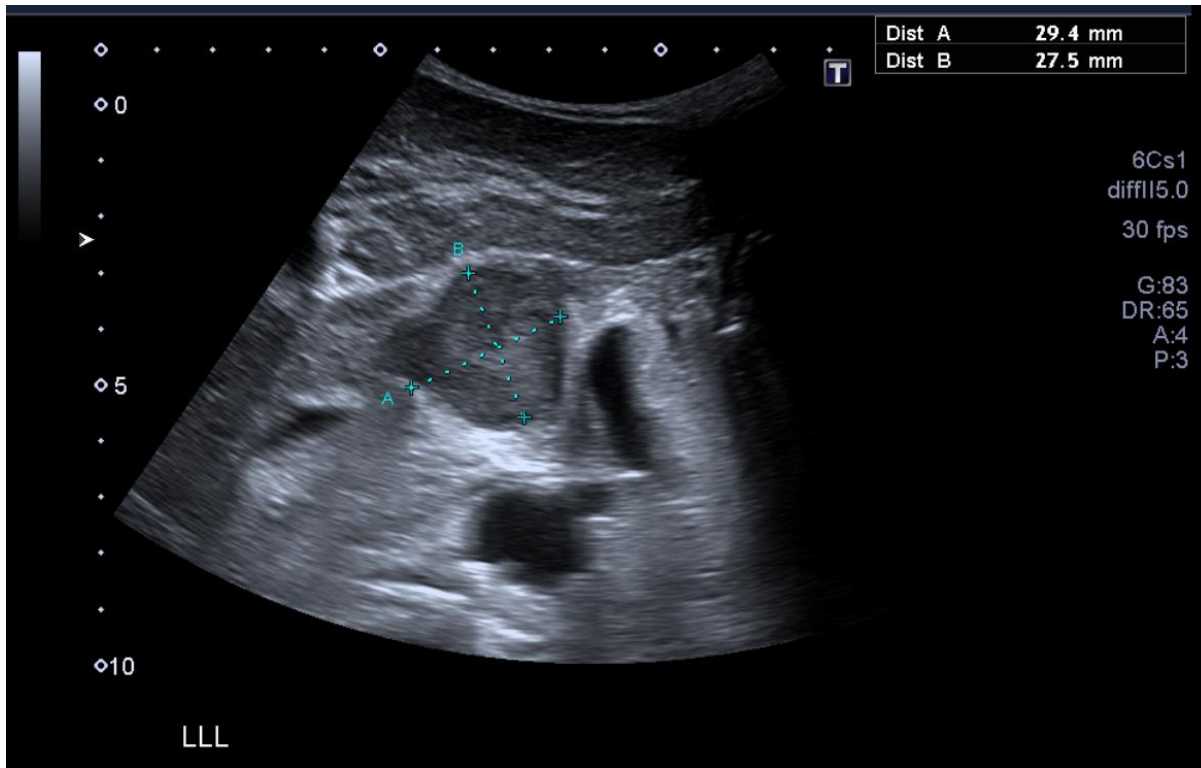
General Medical Case 3

Aug 2021

Clinical details:

66 y/o male. Very cachectic. Lethargy. Anorexia.





Do not progress to next slide until you have attempted to write your own report

US Report:

Within the midline of the abdomen there are multiple abnormal masses, the largest measuring 72x50mm, which appears to be displacing the aorta laterally. There is another 46mm mass to the right of this. Given the location of these masses lymphoma is likely. Differential may be that of retroperitoneal tumours, however this is less likely.

Conclusion:

Grossly abnormal appearances of the midline abdomen. Multiple masses - 75mm, 46mm and 33mm. Aetiology unknown however lymphoma is a strong differential diagnosis.

Lymphoma Fact File

Epidemiology:

Incidence increases over the age of 70.

More common in white males.

Risk factors:

Pre-existing blood conditions, diet high in fat and meat.

Symptoms:

Fatigue, weight loss, night sweats, back/bone pain