


BMUS 

Ultrasound 2016

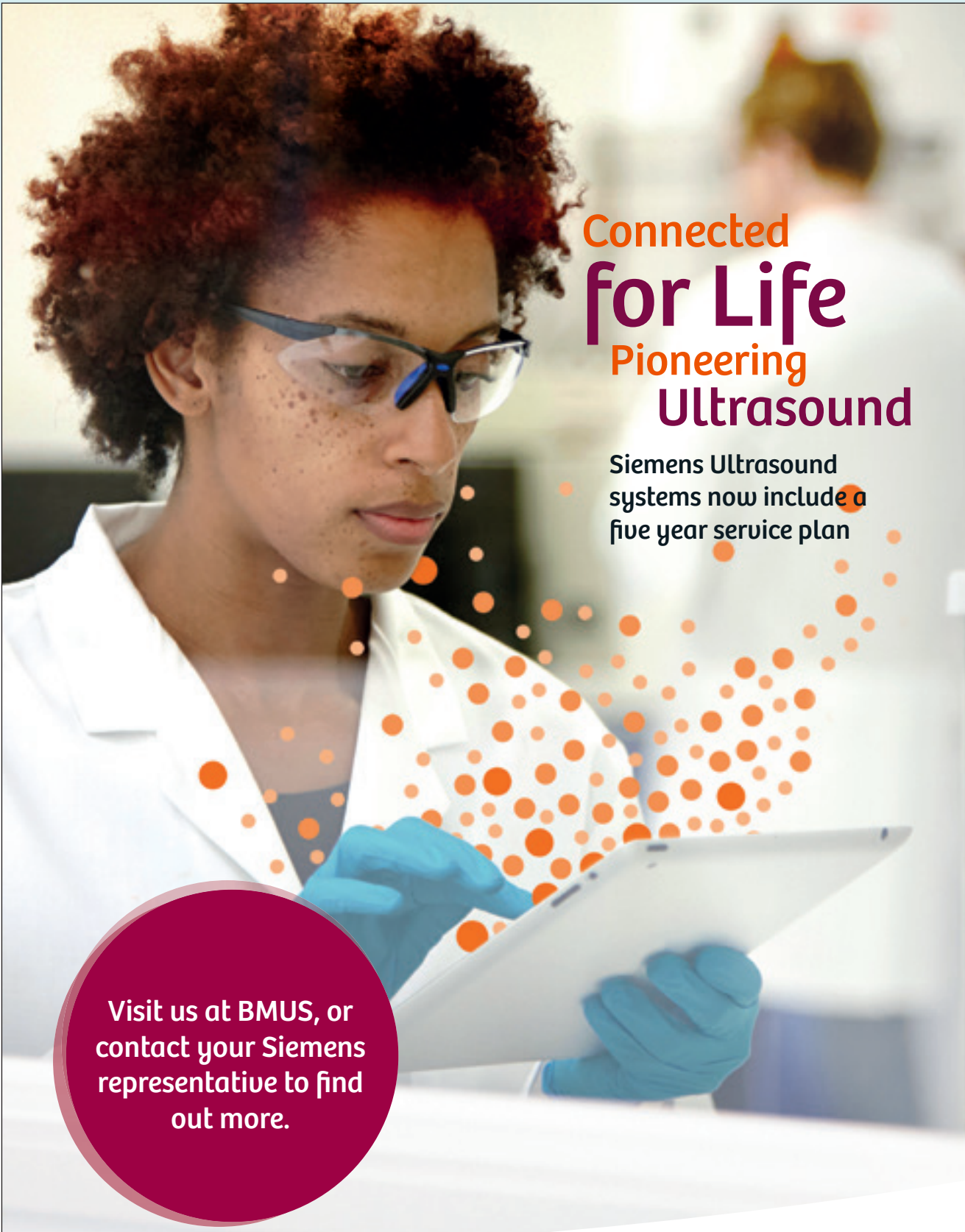
48th Annual Scientific Meeting of the
British Medical Ultrasound Society

7th - 9th December

Final Programme



York Racecourse, York



Connected
for Life
Pioneering
Ultrasound

Siemens Ultrasound systems now include a five year service plan

Visit us at BMUS, or contact your Siemens representative to find out more.

SIEMENS
Healthineers 



“Welcome”

We are delighted to welcome you to the 48th British Medical Ultrasound Society Annual Scientific Meeting in York Racecourse. York is a beautiful historic city and the Racecourse is a wonderful venue providing easy access to all parts of the meeting.

The meeting follows what is becoming the established format of themed days, with integrated training sessions complementing the lecture sessions. Sessions are built around an excellent range of invited speakers. Two of the highlights of the meeting this year will be the Donald, MacVicar, Brown and Peter Twining Lectures, delivered Mrs Jean Wilson from the University of Leeds and Professor Steve Robson from Newcastle, respectively. Additionally we are pleased to welcome Professor Anil Ahuja from Hong Kong, who will deliver a keynote lecture on ‘Evolution of Head & Neck Ultrasound’.

This year we are again pleased to host 2 satellite meetings, the Therapy Ultrasound Group on Thursday and a Translational Ultrasound meeting on Friday.

The exhibition is fully booked and should be lively, with all major manufacturers represented as well as many other exhibitors with products and services to offer the ultrasound community. We are grateful in particular for the support of this year’s Platinum Sponsor, Hitachi Aloka Medical Systems Ltd, who are supporting both the Welcome Reception at the end of Day One and the Annual Dinner and Awards Ceremony being held in the stunning National Railway Museum on Day Two of the meeting.

I should like to thank members of the Scientific and Education Committee and stream leads, listed below, for their hard work in supporting this meeting and in organising study days throughout the year. I should also like to thank Joy Whyte and her team in the BMUS Office; their dedicated organisational efforts and hard work ensure that the meeting actually happens.

Enjoy the meeting and enjoy your visit to York!

Adrian Lim

Chair, Scientific and Education Committee, 2016

BMUS would like to thank the following members of the Scientific Organising Committee and session leads for their contribution to the planning and delivery of this meeting.

Mr Peter Cantin,
Plymouth

Dr Andrew Carne,
Guildford

Dr Steve Colley,
Birmingham

Mrs Nicki Delves,
Guildford

Dr Nick Dudley,
Lincoln

Dr Simon Freeman,
Plymouth

Mrs Tracey Gall,
Manchester

Mrs Alison Hall,
Stafford

Ms Therese Herlihy,
Dublin

Mrs Terry Humphrey,
Leeds

Mrs Catherine Kirkpatrick,
Lincoln

Dr Carmel Moran,
Edinburgh

Mrs Mary Moran,
Dublin

Dr Tim Overton,
Bristol

Mrs Pamela Parker,
Hull

Dr James Pilcher,
London

Mr Steven Rogers,
Manchester

Mrs Borsha Sarker,
Darlington

Prof Gail ter Haar,
London

Mrs Rachel Wilson,
Hull

Mr Stephen Wolstenhulme,
Leeds

**TOSHIBA
MEDICAL**

Made For life



Aplio i-series

Intuitive. Intelligent. Innovative.



Introducing the new Aplio i series

Designed with our customers in mind

The Aplio i-series **intuitive** technology provides unprecedented image clarity for routine and challenging patients.

The **Intelligent** work flow enables you to make faster diagnoses, with more confidence.

The truly **innovative** design with its unparalleled ease of use assists you in meeting day to day departmental challenges without compromising patient outcomes.



Toshiba Medical Systems UK

Find out how we can support you and your department:
call for a chat or take a look at our website

www.toshiba-medical.co.uk | T: 01293 653700



Come and visit us at Stand 2 for a live a demonstration

We are delighted to announce that we have scheduled live demonstrations of our newest ultrasound systems; the Aplio i Series. These private demonstrations are free to all BMUS delegates to attend and offer a first look at some of the advances within ultrasound delivered by our Clinical Applications Specialist. Attending one of these sessions will automatically enter you into a free draw to win an iPad!

CPD points have been applied for.

For more information visit us at:
<http://www.toshiba-medical.eu/uk/bmus-book-a-meeting>



Contents

Information

Ultrasound 2016 Conference App	6
CPD and Feedback	7
General Information	8

Scientific Programme

Day 1 – Wednesday 7th December 2016	12 - 18
Day 2 – Thursday 8th December 2016	22 - 30
Day 3 – Friday 9th December 2016	34 - 42
2016 Keynote Lectures :	9
◆ Donald MacVicar Brown Eponymous Lecture	
◆ Peter Twining Memorial Lecture	
2016 Young Investigator Session	20 - 21
Poster Exhibition	46 - 78
Proceedings	92 - 114

Social Events

2016 Annual Gala Dinner & Awards Ceremony	32
---	----

Technical Exhibition

List of Exhibitors	10
Exhibition Plan	11
Exhibitor Profiles	80 - 91

Future Events

BMUS Study Days 2017	45
Annual Scientific Meeting 2017	116 - 117

The Ultrasound 2016 App

Download The Ultrasound 2016 app to enhance your conference experience.

The app is freely available and will help you get the most out of your time at Ultrasound 2016.

The Ultrasound 2016 app includes;

- Interactive scientific programme
- Details on the Exhibition and the company's in attendance
- Ability to create personalised agendas
- Ability to download posters and abstracts
- A venue map
- Access to BMUS Twitter and Facebook feeds
- Access to the feedback survey

The app aims to support you to make the most of your time at Ultrasound 2016 and enhance your learning experience.

You can download it from the [App Store](#) for Apple devices and [Google Play store](#) for Android devices by searching 'Ultrasound 2016'.



ASM delegate Feedback and CPD Points

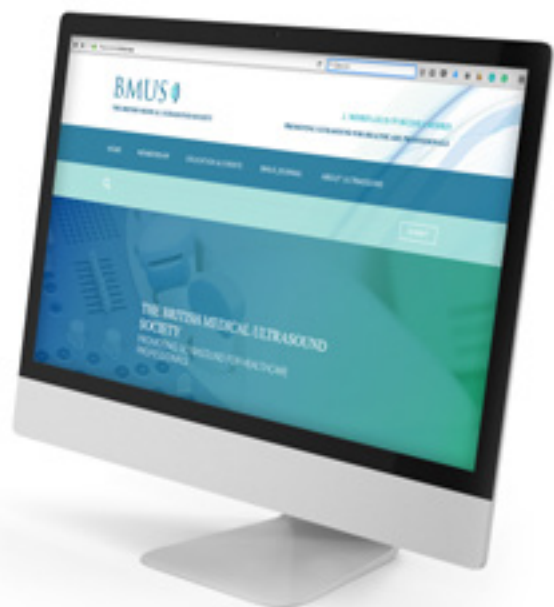This year BMUS will be collecting delegate feedback through Survey Monkey. You can access this either through the BMUS Conference app or via an email that will be sent to you during the conference. We are keen to collect feedback on all aspect of the Annual Scientific Meeting and have produced a comprehensive set of questions covering each session. Please take some time to complete this as it will be used to inform future events.

Once we have received your feedback survey your CPD certificate will be issued from the BMUS office. CPD certificates will only be issued to surveys that are fully complete. You should receive your CPD certificate by the end of January. The Feedback survey will close midnight on 27th January 2017.

The feedback we receive will help us to;

- Prepare for future events,
- Provide constructive feedback to our speakers,
- Feedback to the venue,
- Measure the success and value of the ASM

Thank you in advance for taking the time to complete the feedback questionnaire. If you have any problems regarding this please contact emma@bmus.org



General information

Venue address

York Racecourse
Knavesmire Road
Off Tadcaster Road,
York, YO23 1EX

Conference times

Wednesday 7th December

09:30 - 17:00

17:00 Welcome reception, Ground Floor Exhibition Hall

Thursday 8th December

09:00 -17:00

19.00 BMUS Annual Dinner and drinks, National
Railway Museum, York

Friday 9th December

09:00 -17:00

Delegate badges

Attendees are required to wear their badges at all times to gain access to any part of the event. Access to the practical training sessions is via the appropriate wristband which will be in your delegate pack.

Please leave your badges at the registration desk at the end of your meeting attendance.

Continuing Professional Development (CPD)

The meeting has been awarded the following BMUS CPD credits and Category I RCR CPD credits-

All 3 days- 21 credits

Day 1 - 7 credits

Day 2 - 7 credits

Day 3 - 7 credits

CPD certificates will be provided in an e-format by 31st January on completion of the online feedback form.

Feedback

Feedback will be collected via completion of an electronic feedback form which will be sent to delegates at the end of their attendance at the meeting, the online feedback form will also be available on the 2016 Conference App to complete. BMUS would be grateful if delegates would take time to complete these forms, as the feedback helps the preparation of future meetings.

Catering and refreshments

Lunches and refreshments are included in the registration fee. Catering and coffee points are located in the Exhibition Hall.

Cloakroom

A manned cloakroom is located on the mezzanine level on the right hand side of the Exhibition Hall. Please do not leave bags or personal items unattended. While every effort is made to keep your belongings secure, neither the York Racecourse or BMUS can be held liable for any loss of damage.

WiFi

Free WiFi is available throughout the venue via the venue's network York Racecourse Free Wifi

Social Media

We will be updating our social media throughout the conference.

Our hashtag is #Ultrasound2016 - feel free to get tweeting and posting!

Our Twitter handle is @BMUS_Ultrasound

Our Facebook page is BMUS (British Medical Soc)

2016 Conference App

Please download the conference app from the App Store for Apple devices and Google Play store for Android devices by searching 'Ultrasound 2016'. The app has free access to make the experience simple and quick.

2016 Keynote Lectures

Peter Twining Memorial lecture

This lecture serves as an ongoing tribute to Dr Peter Twining, who had a longstanding close affiliation with BMUS and worked tirelessly for the Society for many years. Each year a “memorial obstetric lecture” is presented by an outstanding individual selected by BMUS. Hitachi Medical Systems UK has kindly sponsored the award since its inaugural year in 2009.

This year, Professor Steve Robson will present his talk, ‘Antenatal diagnosis of abnormally invasive placenta’.



Stephen Robson MB BS MRCOG MD FRCP(Edin) is Professor of Fetal Medicine and a member of the Institute of Cellular Medicine at Newcastle University. He is Clinical Director of the NIHR Clinical Research Network in the North East and North Cumbria. His main research interests are: uterine cell signalling, mechanisms of myometrial quiescence and clinical trials in the area of high risk pregnancy and prenatal screening.

**This talk is on Day 1
Wednesday 7th December
at 11:00 in Plenary 1
Voltigeur 2 on the 3rd Floor.**

The Donald MacVicar and Brown Lecture has been a fixture of the BMUS Annual Scientific Meeting since 1996. The lecture commemorates and celebrates the origins of medical ultrasound.

This plenary keynote lecture honours the 1958 publication of the Ian Donald, John MacVicar and Tom Brown paper in the British journal ‘The Lancet.’ Their paper–‘Investigation of Abdominal Masses by Pulsed Ultrasound’ is credited with transforming maternity care. The lecture is delivered by an invited speaker, recognised by BMUS for their inspirational work and contribution to medical ultrasound practice.

This year the lecture is delivered by Mrs Jean Wilson from University of Leeds and is entitled ‘Sonography – where are we going?’

Jean’s working life began as a sonographer in Leeds, but she later moved into education. She is responsible for the development of the highly

regarded ultrasound education programme at the University of Leeds; which continues to thrive despite increasing pressures within the NHS.

She was a founding member of the United Kingdom Association of Sonographers and was one of the original authors of the UKAS guidelines for professional working practice.

Jean has worked tirelessly promoting sonographers and advanced practice and has been a staunch supporter of BMUS over the years. For last couple of years Jean has been an active member of the BMUS Professional Standards Group who, in association with the Society of Radiographers, have revised and updated the Professional Standards in Ultrasound (UKAS) document which was launched at the 2015 ASM in Cardiff.

Honorary BMUS Membership was awarded to Jean in 2015 as recognition of the work, support and dedication she has given to promoting the ultrasound profession.



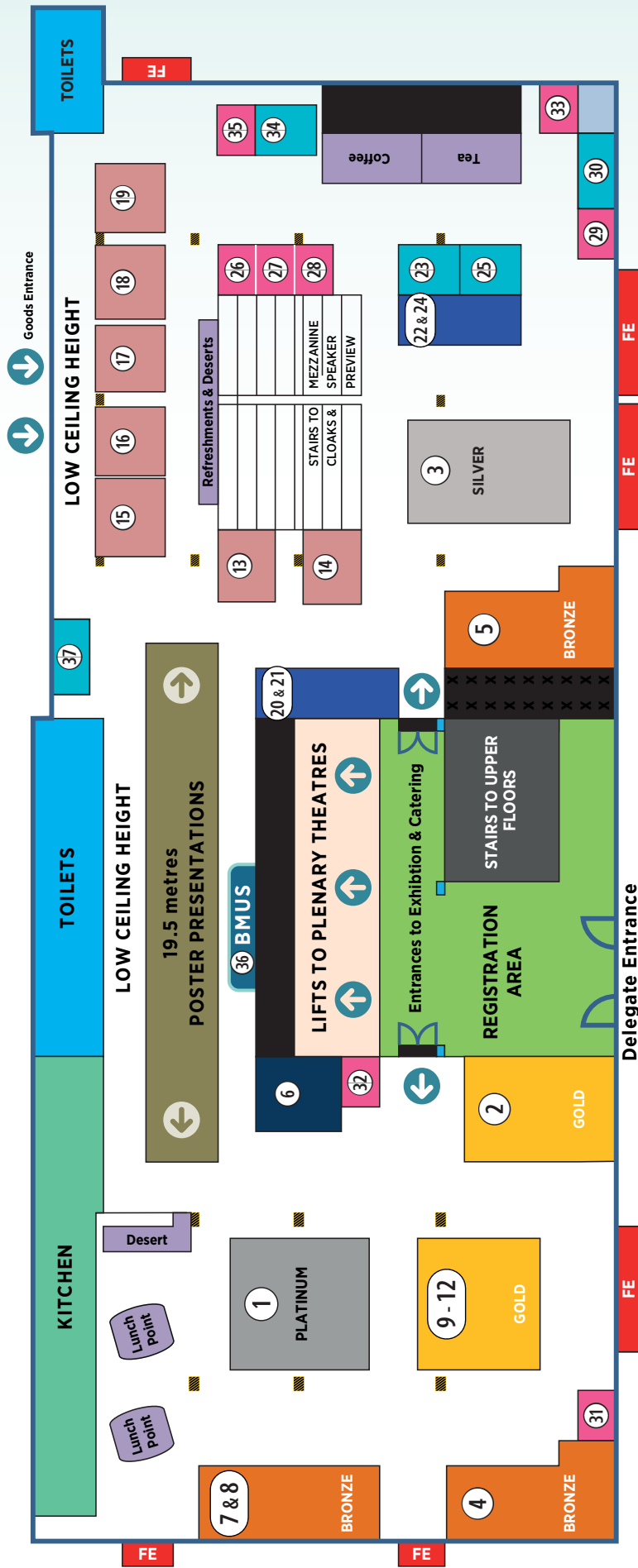
**This talk is on Day 2 –Thursday 8th December at 11:15
in Plenary 1 – Voltigeur 2 on the 3rd Floor.**

List of Exhibitors

Main Exhibition Hall

Stand Number	Company
1	Hitachi Medical Systems
2	Toshiba Medical Systems Ltd
3	MIS Healthcare
4	GE Healthcare
5	Carestream
6	BK Ultrasound
7 & 8	Esaote
9 - 12	Siemens Healthineers
13	Mindray
14	TICCS Ultrasound Services
15	InHealth
16	Tristel Solutions Ltd
17	The College of Radiographers
18	Rothband
19	Medaphor
20 & 21	Philips
22 & 24	Nanosonics
23	Bracco UK Ltd
25	RH Logistics
26	Imaging First Ltd
27	Sanctuary Health
28	Casmed International Ltd
29	Diagnostic Healthcare Ltd
30	PFE Medical
31	Multi-Medix
32	Globe Locums
33	Supersonic Imagine
34	Physiological Measurements Ltd
35	MidCentral Health Board
36	BMUS
37	Bowen Therapy

Floor Plan



At a Glance DAY 1

DAY 1 - WEDNESDAY 7th December 2016				
Session Starts	LECTURES			PRACTICAL TRAINING
	3rd Floor Voltigeur 2	3rd Floor Voltigeur 1	4th Floor Box 2	2nd Floor Dayjur Suite
09.20	President's Welcome			
09.30	Obstetrics 1	MSK Fundamental 1	Physics 1 - Modern Controls	MSK Advanced Practical Session
10.30 Morning Refreshment Break - Exhibition Hall Ground Floor				
11.00	The Peter Twining Memorial Lecture <i>Prof S Robson</i>	MSK Fundamental 2	Physics 2 - Advanced Technologies	MSK Advanced Practical Session (cont'd)
12.30 Lunch Break- Exhibition Hall Ground Floor				
13.30	Obstetrics 3	MSK Advanced 1	Physics 3 - Quality & Safety	MSK Fundamental Practical Session
15.00 Afternoon Refreshment Break- Exhibition Hall Ground Floor				
15.30	Obstetrics 4	MSK Advanced 2	Physics 4 - Modern Doppler	MSK Fundamental Practical Session (cont'd)
17:00 End of Day 1				
17.00 Welcome Reception - Ground Floor Exhibition Hall				

Scientific Programme 2016

Day 1 – Wednesday 7th December

Plenary 1 – 3rd Floor, Voltigeur 2

Opening & Presidential Address

09.20 Dr Carmel Moran, BMUS President

Obstetrics 1

09.30 – 10.30 **Chairs** - Dr Tim Overton, St Michael's Hospital, Bristol, Mrs Alison McGuinness, Mid Yorkshire Hospitals NHS Trust

09.30 **New opportunities for the first trimester scan**, Dr Meekai To, Kings College London

10.00 **Multiple pregnancy in the 1st trimester – findings and pitfalls**, Dr Bill Martin, Birmingham Women's Hospital

Obstetrics 2

11.00 – 12.30 **Chairs** - Dr Tim Overton, St Michael's Hospital, Bristol, Dr Simon Freeman, Derriford Hospital, Plymouth

11.00 **Peter Twining Lecture**
Sponsored by Hitachi Medical Systems

Antenatal diagnosis of abnormally invasive placenta, Prof Stephen Robson, Institute of Cellular Medicine, Newcastle University

11.45 **Vasa Praevia: Targeted or universal screening - a review**, G Coleman, Nottingham University Hospitals NHS Trust

12.00 **Women's experience of late pregnancy ultrasound**, A Dacey, Cambridge University NHS Foundation Trust

Obstetrics 3

- 13.30 – 15.00** **Chairs** – Dr Tim Overton, St Michael’s Hospital, Bristol, Mrs Catherine Kirkpatrick, Lincoln County Hospital
- 13.30** **3D scanning – is it worth it?** Dr Samina Dornan, Royal Maternity Hospital Belfast Trust
- 14.00** **Ultrasound assessment of anomalies of the fetal thorax**, Dr Graham Tydeman, NHS Fife, Kirkcaldy
- 14.30** **Ultrasound diagnosis of facial anomalies**, Dr Paul Moran, Royal Victoria Infirmary, Newcastle

Obstetrics 4

- 15.30 – 17.00** **Chairs** – Mrs Alison McGuinness, Mid Yorkshire Hospitals NHS Trust, Mr Peter Cantin, Derriford Hospital, Plymouth
- 15.30** **How useful is Doppler in the assessment of fetal well-being?** Dr Christoph Lees, Imperial College London
- 16.00** **Case-based discussions in obstetric ultrasound**, Dr Tim Overton, St Michael’s Hospital, Bristol

Plenary 2 – 3rd Floor, Voltigeur 1

MSK Fundamental 1

- 09.30 – 10.40** **Chairs** – Mrs Ciara J Brown, Birmingham City & Sandwell Hospital, Dr Mark Maybury, Heart of England NHS Trust

This session is aimed at those with limited experience in MSK ultrasound, but a thirst to learn more. These sessions will be a combination of lectures and practical demonstrations. This is a superb opportunity to hear a mixed discipline of experts present the clinical viewpoint on shoulder scanning, see a practical demonstration and discuss shoulder imaging beyond ultrasound. We will also have expert practical demonstration and discussions on foot/ankle and hand/wrist ultrasound.

- 09.30** **What the shoulder surgeon wants to know from ultrasound imaging**, Mr Jacob Dertavitian, Hull and East Yorkshire Hospitals NHS Trust
- 09.55** **Demonstration of a shoulder scan**, Mrs Clare Drury, Hull and East Yorkshire Hospitals NHS Trust
- 10.15** **When alternative imaging is more appropriate than ultrasound**, Dr Damien Taylor, Hull and East Yorkshire Hospitals NHS Trust

MSK Fundamental 2

- 11.00 – 12.30** **Chairs** – Mrs Ciara J Brown, Birmingham City & Sandwell Hospital, Dr Mark Maybury, Heart of England NHS Trust
- 11.00** **Ultrasound imaging of the foot & ankle**, Mr Steve Duffy, Norfolk & Norwich University NHS Trust, Mr James Dent, Kings College Hospital, London
- 11.30** **Ultrasound imaging of the hand & wrist**, Mrs Lorelei Waring, University of Cumbria, Mrs Katie Simm, St Helens and Knowsley Hospitals NHS Trust
- 12.00** **MDT Ultrasound Procedure Clinic in rheumatology outpatients – A year's experience**, Mr G Johnson, Tameside Hospital NHS Foundation Trust
- 12.15** **Achilles tendon rupture: do the ends oppose in equinus? Our specialist foot and ankle unit protocol and a review of the imaging findings**, L Ramsay, Royal Surrey County Hospital NHS Foundation Trust

MSK Advanced 1

- 13.30 – 15.00** **Chairs** – Mrs Nicki Delves, Royal Surrey County Hospital NHS Foundation Trust, Dr Andrew Carne, Royal Surrey County Hospital NHS Foundation Trust

This session is aimed at those already working in the field of MSK ultrasound, wishing to further and broaden their knowledge. This will be a superb opportunity to hear internationally renowned MSK radiologists speaking on diverse subjects, the clinical viewpoint from a hand surgeon, with practical demonstrations and open forum discussions.

Suitable for radiologists, sonographers, sports physicians and physiotherapists with experience in musculoskeletal ultrasound.

- 13.30** **Ultrasound imaging of the upper limb**, Prof Carlo Martinoli, San Martino University Hospital, Genoa, Italy
- 13.55** **Ultrasound interventions of the upper limb**, Dr Harun Gupta, Leeds Teaching Hospitals NHS Trust
- 14.20** **What the hand surgeon wants to know from ultrasound imaging**, Mr Sean Hughes, Royal Surrey County Hospital NHS Foundation Trust
- 14.40** **Challenges and pitfalls in paediatric MSK ultrasound**, Dr Kate Kingston, York Teaching Hospitals NHS Trust



MSK Advanced 2

- 15.20 – 17.00** **Chairs** – Mrs Nicki Delves, Royal Surrey County Hospital NHS Foundation Trust, Dr Andrew Carne, Royal Surrey County Hospital NHS Foundation Trust
- 15.20** **Groin anatomy reviewed**, Dr Raju Peddada, University Hospital of North Tees
- 15.45** **Ultrasound of the hip**, Dr Emma Rowbotham, Leeds Teaching Hospitals NHS Trust
- 16.10** **International request for MSK injection teaching - collaboration between Essex University and ASA**, Ms Sue Innes, School of Health and Human Sciences, University of Essex, Mrs Alison Hall, Royal Wolverhampton NHS Trust
- 16.30** **Open Forum discussion** with Prof Carlo Martinoli, San Martino University Hospital, Genoa, Italy, Dr Simon Ostlere, Nuffield Orthopaedic Centre, Oxford

Plenary 3 – 4th Floor, Box 2

Physics 1 – Modern Controls

- 09.30 – 10.30** **Chairs** – Dr Nick Dudley, United Lincolnshire Hospitals NHS Trust, Dr Carmel Moran, University of Edinburgh

This session aims to discuss the impact of modern ultrasound machine controls on diagnostic value, and the safe management of equipment. It will be of interest to all those using modern equipment and to those providing scientific and technical support to ultrasound services.

- 09.30** **Advanced processing: Under practitioner control?** Mr Stephen Wolstenhulme, Leeds Teaching Hospitals NHS Trust
- 10.00** **Equipment management: Good practice!** Dr Fiammetta Fedele, St Thomas' Hospital, London

Physics 2 – Advanced Technologies

- 11.00 – 12.00** **Chairs** – Dr Nick Dudley, United Lincolnshire Hospitals NHS Trust, Dr Carmel Moran, University of Edinburgh

This session aims to provide an overview of some of the advancing technologies in vector Doppler and elastography and their clinical impact.

It will be of interest to those using, or planning to use, these technologies and to those providing scientific and technical support to ultrasound services.

- 11.00** **Vector Doppler: Technology and Clinical Impact**, Dr Kristoffer Lindskov Hansen, Rigshospitalet University Hospital of Copenhagen, Denmark
- 11.30** **Elastography: Shear or Strain**, Prof Adrian Lim, Imperial College, London

Physics 3 – Quality & Safety

13.30 -15.00

Chairs –Dr Carmel Moran, University of Edinburgh, Prof Adrian Lim, Imperial College, London

This session covers the basic physics underlying acoustic hazards in ultrasound, translating this into day to day practical advice, and provides an update on developments in QA.

It will be of interest to all those with responsibility for quality and safety, including department leads and scientific and technical staff, and also to those wanting to learn more about safety and QA.

13.30

Physics of interactions with tissues: Challenges in Practice, Prof Gail ter Haar, Institute of Cancer Research, Sutton

14.00

Developments in Ultrasound QA, Dr Nick Dudley, United Lincolnshire Hospitals NHS Trust

14.30

The relationship between depth of field and focus position on image quality: Raising awareness in student sonographers, G Taylor¹, A Culpán¹, S Wolstenhulme², ¹University of Leeds, ²Leeds Teaching Hospitals NHS Trust

14.45

Validation of automated measurements of air reverberation patterns, D Rowlands, C Sanders, T Evans, Leeds Teaching Hospitals NHS Trust

Physics 4 – Modern Doppler

13.30 -15.00

Chairs – Dr Nick Dudley, United Lincolnshire Hospitals NHS Trust, Mr Stephen Wolstenhulme, Leeds Teaching Hospitals NHS Trust

This session provides an update on Doppler ultrasound and should be of interest to Doppler users and those providing scientific and technical support to ultrasound services.

15.30

Technologies for assessing blood flow and their clinical impact on modern practice, Prof Neil Pugh, University Hospital of Wales, Cardiff

16.00

Visualising the pulsing brain using Doppler ultrasound, Dr Emma Chung, University of Leicester



Practical Workshop Session – 2nd Floor, Dayjur Suite

MSK Advanced Practical Session

09.30 – 12.30 **Chair** - Mrs R Wilson, Hull and East Yorkshire Hospitals NHS Trust

An opportunity to gain hands-on scanning practice, advice and pearls from experienced MSK radiologists and sonographers on cutting edge ultrasound systems.

This workshop is intended for those with a sound knowledge of ultrasound and a reasonable knowledge of MSK scanning techniques, ready to extend their practice to a more advanced level.

Faculty -

Dr Andrew Carne, Royal Surrey County Hospital NHS Foundation Trust,
Mrs Nicki Delves, Royal Surrey County Hospital NHS Foundation Trust,
Dr Harun Gupta, Leeds Teaching Hospitals NHS Trust,
Mrs Alison Hall, Royal Wolverhampton NHS Trust,
Dr Kate Kingston, York Teaching Hospitals NHS Trust,
Prof Carlo Martinoli, San Martino University Hospital, Genoa, Italy,
Dr Simon Ostlere, Nuffield Orthopaedic Centre, Oxford,
Dr Raju Peddada, University Hospital of North Tees

MSK Fundamental Practical Session

13.30 – 16.30 **Chairs** - Dr Mark Maybury, Heart of England NHS Trust, Mr James Dent, Kings College Hospital, London

This is an opportunity to work in small groups with experienced ultrasound trainers who will help with basic MSK ultrasound techniques on cutting edge ultrasound systems.

This workshop is intended for those with sound knowledge of ultrasound instrumentation but little or no experience in MSK u/s scanning.

Faculty -

Mrs Claire Pattison, Queen Victoria Hospital NHS Foundation Trust, East Grinstead
Mrs Kirsty Godson, Northern Medical Ultrasound
Mr Trevor Parker, Hull and East Yorkshire Hospitals NHS Trust
Mrs Ciara Browne, Birmingham City & Sandwell Hospital
Mr Andrew Longmead, Kings Mill Hospital, Sutton in Ashfield
Mrs Sue Foster, Northern Medical Ultrasound
Mrs Lol Waring, University of Cumbria
Mrs Katie Simm, St Helens and Knowsley Hospitals NHS Trust

SAMSUNG

Share the wonder in a click



Hello Mom Ultrasound Image Sharing App



MIS Healthcare
Tel: 0208 205 9500 (Sales)
Email: info@mishealthcare.co.uk
www.mishealthcare.co.uk

Download the Hello Mom app on your smartphone

ANDROID APP ON Google play

Available on the App Store



© Google Play is a trademark of Google Inc.
App Store is a registered trademark of Apple Inc.

Young Investigator Session

The young investigator session is a show-case of the best abstracts submitted by authors who are 39 years old or younger. The best presentation from this session wins the BMUS Young Investigator of the year award and is given the opportunity to present their work on behalf of BMUS at the 2017 Euroson Meeting being held in Ljubljana, Slovenia on 22nd – 25th September 2017.

Ayesha Jameel




The clinical efficacy of Contrast Enhanced Ultrasound in Focal Hepatic Lesion characterisation, A Jameel¹, A Chhabu², D Cosgrove¹, C Harvey¹, A Lim¹, ¹Imperial College Healthcare Trust, London, ²Imperial College, London

Ayesha Jameel is a radiology registrar at Imperial College Healthcare Trust. Having trained at Imperial College Medical school via an intercalated BSc in Management from Imperial College Business school. It seems the fruit doesn't fall far from the tree!

Ayesha has been working closely on this project with Dr Adrian Lim and Dr Chris Harvey, both experts in contrast enhanced ultrasound with over 10 years experience - their input has been invaluable. Arif Chhabu, a dedicated final year medical student from Imperial College, has been involved from the very inception of the study. The team hope this work will inspire both Arif and the next generation of sonographers and radiologists to continue to explore technological advances in imaging!

Piero Miloro



Measurement of temperature increase in a phantom for transvaginal ultrasound scans: Audit results, P Miloro¹, E Martin², A Shaw¹,¹National Physical Laboratory, ²University College London

Piero is a researcher in high-technology engineering fields. He moved to the Ultrasonics Group of the National Physical Laboratory in 2015 after completing his PhD in Biomedical Engineering in Italy. At the moment, he is involved in different research projects on ultrasound safety, in-vitro acoustic stimulation of cells, tissue mimicking materials and therapeutic ultrasound. He is responsible for the hydrophone calibration service and the thermal test objects manufacturing for NPL.

James Moggridge



Investigating the benefits of using an app driven user test quality assurance scheme, James Moggridge, University College London Hospitals NHS Foundation Trust

I am a clinical scientist working at University College London Hospitals. Although I now work in the field of scientific computing my background is in ultrasound physics and I still take an active role in supporting ultrasound services here at UCLH and perform the occasional quality assurance test as required. This project allowed me combine my interests in programming and ultrasound whilst introducing me to a world of Bootstrap and SQL Alchemy.

Maria Theodorou



Permelastography: Quantitative poroelastic property imaging by combining shear wave and strain elastography with a force sensor, M Theodorou^{1,2}, J Fromageau^{1,2}, N deSouza^{2,3}, J Bamber^{1,2,1}, Joint Department of Physics, Sutton, London, ²Cancer Research UK Cancer Imaging Centre, Sutton, London, ³Royal Marsden NHS Foundation Trust, Sutton, London

My name is Maria Theodorou and I am a medical physicist, currently on the final year of my PhD at the Institute of Cancer Research in London. My research has been focused on developing a breast imaging prototype using advanced ultrasound techniques to estimate non-invasively biomechanical properties associated with the tumor microenvironment. I am interested in translational research and during my doctoral training I have benefited from working closely with both scientists and clinicians.

Anant Shah



Combined contrast ultrasound and optoacoustic imaging in the evaluation of tumour hypoxia, A Shah, N Bush, G Box, S Eccles, J Bamber, Institute of Cancer Research, London

Anant Shah received his Ph.D. degree in biophysics in 2014 from the Institute of Cancer Research, for his work on photoacoustic imaging of molecular markers of cancer prognosis and response using gold nanoparticles. He is currently working as a postdoctoral researcher at the Institute of Cancer Research. His research is oriented towards assessing the potential of photoacoustic imaging for cancer treatment planning and treatment response.


Lucie Lévêque



Assessing Quality of Experience for Medical Tele-Assistance: Preliminary Study with Ultrasound Exams, L Lévêque¹, Y Cheng¹, P Parker², ¹University of Hull, ²Hull & East Yorkshire Hospitals

I am a French PhD student in Medical Engineering. I am happy to share my interest for telemedicine, and learn more things about this topic. When I have some spare time, I love travelling... in UK, in Europe, or even further! :) I recently went to Iran where I discovered a very interesting culture and awesome people.

Matthew Spurr



Are Radiologists aware of their boundaries? M Spurr, E Hallett, S Berry, R Rhys, Royal Glamorgan Hospital, Llantrisant

I have just finished my foundation training and am in the process of applying for Radiology. My free time was previously filled playing football, running and cycling. However, recently all I seem to do is contemplate the relationship between imaging modalities and extra-capsular spread.

This session takes place on Day 2 – Thursday 8th December 9:00 – 10:45 in Plenary 3 – 4th Floor, Box 2

At a Glance DAY 2

Day 2 – THURSDAY 8th December 2016					
Session Starts	LECTURES			PRACTICAL TRAINING	SATELLITE SESSION
	3rd Floor Voltigeur 2	3rd Floor Voltigeur 1	4th Floor Box 2	2nd Floor Dayjur Suite	4th Floor Box 5
09.00	Head & Neck 1	Professional Issues 1 – Meeting Demand and Managing Targets	BMUS Young Investigator 2016	Carotid Masterclass	Therapy in Ultrasound Group Meeting
10.45 Morning Refreshment Break – Exhibition Hall Ground Floor					
11.15	Donald MacVicar Brown Lecture <i>Mrs Jean Wilson</i>				Therapy in Ultrasound Group Meeting
12.00 Lunch Exhibition Hall Ground Floor			12.15 BMUS AGM All members welcome		
13.00	Head & Neck 2				
13.30	Gynaecology 1 – Imaging Common Gynaecological Findings	Professional Issues 2	Paediatrics 1	Head & Neck Integrated Training Session	Therapy in Ultrasound Group Meeting
15.00 Afternoon Refreshment Break - Exhibition Hall Ground Floor					
15.30	Professional Issues 3 – Developing Safe Practice	Paediatrics 2	Gynaecology 2 – Beyond the Uterus	Head & Neck Integrated Training Session (cont'd)	Therapy in Ultrasound Group Meeting
17:00 End of Day 2					
19.00 BMUS 2016 Annual Gala Dinner & Awards Ceremony at the National Railway Museum					

Scientific Programme 2016

Day 2 – Thursday 8th December

Plenary 1 – 3rd Floor, Voltigeur 2

Head & Neck 1

09.00 – 10.45 **Chairs** - Dr Rhodri Evans, Morriston Hospital, Swansea, Mrs Catherine Kirkpatrick, United Lincolnshire Hospitals NHS Trust

The session will provide in depth insight into the speciality of head and neck ultrasound scanning and reporting by experts in their field. The aim is to give confidence in reporting, using the BTA thyroid guidelines for the assessment of nodules, and comprehensively cover the examination of the parathyroids with ultrasound detailing requirements and consideration, in order to provide a thorough investigation. Professor Ahuja will guest speak from Hong Kong.

09.00 **BTA Thyroid**, Dr Steve Colley, Queen Elizabeth Hospital, Birmingham

09.30 **Parathyroids**, Dr John Robinson, Newcastle upon Tyne Hospitals NHS Foundation Trust

10.00 **Evolution of Head & Neck Ultrasound**, Prof Anil Ahuja, The Chinese University of Hong Kong

11.15 – 12.00 **Donald MacVicar Brown Keynote Lecture**

Chairs - Dr Carmel Moran, Edinburgh University, Prof Adrian Lim, Imperial College London

11.15 **Sonography – where are we going?**, Mrs Jean Wilson, University of Leeds

Head & Neck 2

13.00 -13.30 **Chairs** - Dr Rhodri Evans, Morriston Hospital, Swansea, Mrs Catherine Kirkpatrick, United Lincolnshire Hospitals NHS Trust

13.00 **Unusual Salivary Gland Abnormalities**, Prof Anil Ahuja, The Chinese University of Hong Kong



Gynaecology 1 - Imaging Common Gynaecology Findings

13.30 – 15.00 **Chairs** – Mr Peter Cantin, Derriford Hospital, Plymouth, Mrs Rachel Wilson, Hull and East Yorkshire Hospitals NHS Trust

Fibroids are demonstrated in a significant proportion of gynaecological ultrasound examinations. To most practitioners they are common and easy to diagnose. However, to aid management and improve outcomes of patients a simple diagnosis of the presence of fibroids is no longer sufficient. Endometriosis affects a large proportion of our patients but ultrasound diagnosis is poorly understood. Classifying ovarian masses can be improved with greater understand of the diagnostic criteria commonly seen.

The aim of this session is to provide delegates with up to date advice for imaging whilst providing an insight in to the needs of the patient and clinician in these common gynaecological findings

This session is suitable for all practitioners who perform gynaecological examinations, either routinely or as an adjunct to other fields of ultrasound practice.

13.30 **Fibroid mapping**, Dr Dimitrios Mavrelou, University College London Hospitals NHS Foundation Trust

13.55 **Classifying adnexal masses on ultrasound**, Mrs Alison McGuinness, Mid Yorkshire Hospitals NHS Trust

14.25 **Imaging pathways of the indeterminate adnexal mass**, Dr Andrea Sanderson, Mid Yorkshire Hospitals NHS Trust

14.45 **Unexpected finding in the hunt for an IUCD**, R Turney, A Ahead, K Kingston, York Teaching Hospitals NHS Trust

Professional Issues 3 - Developing Safe Practice

15.30 – 17.00 **Chairs** – Mrs Alison Hall, Royal Wolverhampton NHS Trust, Mrs J Wilson, University of Leeds

Safe practice in ultrasound is paramount to deliver high quality, reliable care to our patients. All ultrasound practitioners will be aware of safety considerations and the BMUS safe practice guidelines produced by our safety committee will be embedded into daily practice. However, there are wider safety issues to consider, and subsequently manage, which can appear daunting to the uninitiated. The faculty will present their own experience in developing safe working practices and provide the latest in advice from BMUS and professional bodies.

The aim of this session is to provide delegates with an overview of safety issues that require consideration and advice as to how to implement and manage within your service. The presentations will be followed by an opportunity to ask the expert faculty for advice in producing your own documents to support safe practice. Topics covered include patient information leaflets, PGD's, CQC evidence requirements, guidelines of practice and clinical audit. Delegates are invited to bring specific examples and issues that they require assistance with for discussion with peers and faculty.

15.30 **Safety Considerations in ultrasound practice – beyond MI**, Mr Peter Cantin, Derriford Hospital, Plymouth

- 15.50 **Top Tips in producing documents – meeting patient needs and CQC expectations**, Mr Gerry Johnson, Tameside Hospital NHS Foundation Trust
- 16.10 **So you perform clinical audit – now what?** Mrs Pamela Parker, Hull and East Yorkshire Hospitals NHS Trust
- 16.30 **RCR Standards for the provision of ultrasound service 2015. Was a whole service audit useful? What did we learn?** W Gardner, Bradford Teaching Hospitals NHS Foundation Trust
- 16.40 **Ask the BMUS experts – Q&A session. Topics from the floor**, Faculty & Chairs

Plenary 2 – 3rd Floor, Voltigeur 1

Professional Issues 1 - Meeting Demand and Managing Targets

- 09.00 – 10.45** **Chairs** – Mrs Pamela Parker, Hull and East Yorkshire Hospitals NHS Trust, Mr Peter Cantin, Derriford Hospital, Plymouth

The majority of practitioners working within clinical ultrasound services will be juggling increasing demand against delivering targets. Targets within healthcare are contentious but have led to reduced waiting times for patients, efficiency improvements and are a driver for increasing skill mix within radiology. The advanced practice and consultant sonographer roles within ultrasound imaging can, and do, help services deliver targets but the mere mention of the word “target” can be negative and disincentive the workforce across the board.

The aim of this session is to gain an understanding as to why targets matter locally and in the wider context of the healthcare system. The impact of targets on patient care and sonographer role development will be considered

This session will be valuable to all practitioners involved in patient care including radiologists, sonographers, managers, and healthcare providers.

- 09.00 **Why targets matter**, Mr J Wood, Hull and East Yorkshire Hospitals NHS Trust
- 09.25 **Clinical implications of unachieved imaging targets – what do we miss**, Dr Oliver Byass, Hull and East Yorkshire Hospitals NHS Trust
- 09.50 **Commissioning ultrasound services – what can be done to support increasing demand**, Dr V Rawcliffe, Hull Clinical Commissioning Group
- 10.15 **Sonographer role development – how can this help?** Mrs Alison Hall, Royal Wolverhampton NHS Trust

Professional Issues 2

- 13.30 – 15.00** **Chairs** – Mrs Pamela Parker, Hull and East Yorkshire Hospitals NHS Trust, Mr Gerry Johnson, Tameside Hospital NHS Foundation Trust
- 13.30 **Integrating transabdominal simulators into an ultrasound curriculum: Our experience at the Peninsula Radiology Academy**, K Orr, S Hamilton, Peninsular Radiology Academy, Plymouth

13.40 **Mentoring the mentor – what's in it for you?** Dr Dai Roberts, Dr Chris Williams, University Hospital of Wales, Cardiff

Most healthcare professionals working in imaging are expected to teach and train but many are given little, if any, formal training in teaching. Feedback is increasingly recognised as a vital component of learning new skills. We will provide a framework and suggestions of different methods of teaching skills, providing feedback and how to tailor trainee and student development aims i.e. PDPs. The session will be highly interactive with short lectures and we will break out into practical small group sessions, with an experienced faculty.

The workshop is suitable for those who currently have an active role in training and those wishing to become more involved in training, with no previous experience necessary. We welcome trainers from all clinical and non-clinical backgrounds, with our workshop primarily focused on ultrasound training.

Paediatrics 2

15.30 – 17.00 **Chairs** – Mrs Terry Humphrey, Leeds Teaching Hospitals NHS Trust, Dr Helen Woodley, Leeds Children's Hospital

This second paediatric neonatal session will focus on cranial ultrasound. We will hear a neonatologist's view on the information that is most useful in guiding patient management. Imaging protocols, normal appearances and a variety of pathologies will be discussed in the preterm and term infant. Scanning technique will also be covered including the use of Doppler in the assessment of hypoxic ischaemic encephalopathy.

The session is aimed at radiologists, trainees and sonographers with a paediatric interest.

15.30 **Cranial Ultrasound - what the neonatologist wants to know?** Dr Sharon English, Leeds Children's Hospital

16.00 **Cranial Ultrasound in the preterm infant,** Dr Helen Woodley, Leeds Children's Hospital

16.30 **Cranial Ultrasound in the term infant,** Dr Annmarie Jeanes, Leeds Children's Hospital

Plenary 3 – 4th Floor, Box 2

Young Investigator Session 2016

09.00 – 10.45 **Chairs** – Dr Carmel Moran, University of Edinburgh, Mrs Terry Humphrey, Leeds Teaching Hospitals NHS Trust

Seven chosen presenters, under the age of 39, will battle it out to become the UK representative at Euroson 2017 in Ljubjana, Slovenia.

09.00 **The clinical efficacy of Contrast Enhanced Ultrasound in Focal Hepatic Lesion characterisation,** A Jameel¹, A Chhabu², D Cosgrove¹, C Harvey¹, A Lim¹, ¹Imperial College Healthcare Trust, ²Imperial College

09.15 **Measurement of temperature increase in a phantom for transvaginal ultrasound scans: audit results,** P Miloro¹, E Martin², A Shaw¹, ¹National Physical Laboratory, Sutton, ²University College London

- 09.30 **Investigating the benefits of using an app driven user test quality assurance scheme,**
J Moggridge, University College London Hospitals NHS Foundation Trust
- 09.45 **Permelastography : Quantitative poroelastic property imaging by combining shear wave and strain elastography,** M Theodorou, J Fromageau, N Desouza, J Bamber, Cancer Research UK Cancer Imaging Centre, Sutton
- 10.00 **Combined contrast ultrasound and optoacoustic imaging in the evaluation of tumour hypoxia,** A Shah, N Bush, G Box, S Eccles, J Bamber, Institute of Cancer Research
- 10.15 **Assessing quality of experience for medical tele-assistance: Preliminary study with ultrasound exams,** L Lévêque¹, Y Cheng¹, P Parker², ¹University of Hull, ²Hull and East Yorkshire Hospitals NHS Trust
- 10.30 **Are Radiologists aware of their boundaries?** M Spurr, Royal Glamorgan Hospital, Llantrisant

Paediatrics 1

- 13.30 – 15.00** **Chairs** – Mrs Terry Humphrey, Leeds Teaching Hospitals NHS Trust, Dr Annemarie Jeanes, Leeds Children's Hospital

This year the paediatric sessions will focus on the neonate.

In this session the prenatal diagnosis and postnatal surgical repair of pulmonary and gastrointestinal anomalies will be discussed. This will be a joint radiology and paediatric surgical presentation and will give an insight into the detection, management and outcome of a variety of antenatal detected conditions. The session will conclude with a review of the ultrasound findings in the sick and post-surgical neonate.

The session is aimed at radiologists, trainees and sonographers with a paediatric interest.

- 13.30 **The prenatal diagnosis of pulmonary and gastrointestinal anomalies,** Dr Mike Weston, Leeds Teaching Hospitals NHS Trust
- 14.00 **The paediatric surgical repair of pulmonary and gastrointestinal anomalies,** Mr David Crabbe, Leeds Children's Hospital
- 14.30 **Abdominal ultrasound in the sick and post-surgical neonate,** Dr Tom Watson, Great Ormond Street Hospital



Gynaecology 2 - Beyond the Uterus

15.30 – 17.00 **Chairs** – Mrs Rachel Wilson, Hull and East Yorkshire Hospitals NHS Trust, Mrs Alison McGuinness, Mid Yorkshire Hospitals NHS Trust

Pelvic pain in the female patient is often assumed to be gynaecological in nature with referrals for ultrasound imaging being common place in this patient group. Ultrasonically normal uterus, endometrium and ovaries can be falsely reassuring as alternative causes of pain and significant pathology can be overlooked. Thorough imaging of the cervix, as well as an appreciation of non-gynaecological cause of pain will improve the diagnostic impact of your examination and aid future management of the patient.

The aim of this session is to provide delegates with up to date advice for imaging the cervix whilst providing an insight in to non-gynaecological cause of pelvic pain in the female patient.

This session is suitable for all practitioners who perform gynaecological examinations, either routinely or as an adjunct to other fields of ultrasound practice.

15.30 **Non-gynaecological causes of pelvic pain**, Dr Mike Weston, Leeds Teaching Hospitals NHS Trust

16.00 **The cervix – the role of US in imaging and diagnosis**, Dr Ann Marie Coady, Hull and East Yorkshire Hospitals NHS Trust

16.30 **Alternative imaging of the cervix – what more can we see**, Dr Sarah Swift, United Leeds Hospital Trust

Practical Workshop Session – 2nd Floor, Dayjur Suite

Carotid Masterclass

09.00 – 10.45 **Led by** - Mrs Tracey Gall, Mr Steven Rogers,

This session is aimed at anyone new to carotid ultrasound or those wanting to brush up their skills and includes :

- ◆ Introduction to faculty
- ◆ Review of scan protocols and image taking - what to include?
- ◆ How to approach difficult pathology (and difficult patients)
- ◆ Plenty of hands on experience and opportunity to discuss scanning issues with experienced sonographers / vascular scientists.

Head and Neck Integrated Training Session

13.30 – 17.00 **Led by** - Dr Rhodri Evans, Morriston Hospital, Swansea, Dr Rhian Rhys, Royal Glamorgan Hospital, Llantrisant

This session will follow the same successful format as in previous year's workshops. The anatomy of the head and neck will be taught in small groups. Each area will be taught through a series of standard sweeps through the neck, devised and led by Dr Rhian Rhys, each area being initially demonstrated by live scanning by Dr Rhodri Evans. Following each demonstration the delegates will then scan the models under the supervision of a member of

the head and neck faculty in their respective groups. The neck will be systematically covered outlining the key structures that need to be identified, starting from the submental triangle and ending with the larynx. Tips and pitfalls will be highlighted allowing a comprehensive scanning technique of the neck to be mastered under the guidance of the faculty.

Faculty -

Dr Rhodri M Evans, Morriston Hospital, Swansea
 Dr Rhian Rhys, Royal Glamorgan Hospital, Llantrisant
 Dr Steve Colley, Queen Elizabeth Hospital, Birmingham
 Mrs Catherine Kirkpatrick, United Lincolnshire Hospitals NHS Trust
 Mrs Jean Bainbridge, Hull and East Yorkshire Hospitals NHS Trust
 Dr Lol Berman, Addenbrookes Hospital, Cambridge University
 Dr Chris Greenall, Morriston Hospital, Swansea
 Dr Dave Salvage, Hull and East Yorkshire Hospitals NHS Trust

Satellite Session – 4th Floor, Box 5

Therapy in Ultrasound Group Meeting (ThUGs)

09.00 – 12.40 **Chair :** Prof Steven Freear, University of Leeds

- 10.40** **Vapour bubble nucleation in boiling histotripsy**, M de Andrade¹, S Haqshenas¹, K Joo Pahk², N Saffari¹,¹ UCL Mechanical Engineering, University College London,² Biomedical Research Institute, Korea Institute of Science and Technology (KIST)
- 11.00** **Experimental validation of simulated transcranial ultrasound propagation**, L Robertson, E Martin, B Cox, B Treeby, Biomedical Ultrasound Group, Department of Medical Physics and Biomedical Engineering, University College London
- 11.20** **Evaluation of the resonance frequency shift of ultrasound-driven microbubbles embedded in tissue-mimicking phantoms**, A Jamburidze, A Huerre, M De Corato, V Garbin, Department of Chemical Engineering, Imperial College London
- 11.40** **Microbubble trapping and destruction for targeted drug delivery**, L Nie¹, S Harput^{1,2}, D Cowell¹, T Carpenter¹, J McLaughlan^{1,3}, S Freear¹, ¹School of Electronic and Electrical Engineering, University of Leeds, ²Department of Bioengineering, Imperial College London, London, ³Division of Biomedical Imaging, University of Leeds
- 12.00** **A hybrid multiscale model to simulate in vitro experiments of focused ultrasound mediated heating combined with radiotherapy**, S Bruening¹, G Powathil², I Rivens¹, J Ijaz¹, U Oelfke¹, M Chaplain³, G ter Haar¹.¹Institute of Cancer Research, ²Department of Mathematics, Swansea University, ³School of Mathematics and Statistics, University of St Andrews



SCIENTIFIC PROGRAMME

- 12.20 **Designing an ultrasound transducer for targeted cancer drug delivery by ultrasound-mediated large volume mild hyperthermia**, B Chu, R Cleveland, C Coussios, Dept of Engineering Science, University of Oxford
- 12.40 **Lunch provided in the 2016 BMUS Technical Exhibition on the ground floor**
- 13.40 – 15.50** **Chair** : Prof Robin Cleveland, University of Oxford
- 13.40 **ThUNDDAR – who or what?** G ter Haar, Institute of Cancer Research, Sutton, Surrey
- 13.50 **Acceleration techniques for Acoustic Holography**, D Sinden, P Miloro, S Chretien, A Shaw, National Physical Laboratory, Teddington, Middlesex
- 14.10 **Pre-clinical combination of Focused Ultrasound and Radiotherapy, using Photoacoustic Imaging as planning and monitoring tool ultrasound**, M Costa, A Shah, I Rivens, T O'Shea, C Box, J Bamber, G ter Haar, Joint Department of Physics, The Institute of Cancer Research: Royal Marsden NHS Foundation Trust, Sutton, Surrey
- 14.30 **FLIR thermography and optical spectroscopy for assessment of changes in ex vivo tissues exposed to high-intensity focused ultrasound**, J Raymond, E Edwards, R Cleveland, R Roy, Dept. of Engineering Science, University of Oxford
- 14.50 **An investigation into the biological and immunological effects of heat**, P Mouratidis, G ter Haar, Joint Department of Physics, The Institute of Cancer Research: Royal Marsden NHS Foundation Trust, Sutton, Surrey
- 15.10 **Preliminary results of Synthetic Aperture Imaging using random phased arrays**, M Zubair, R Dickinson, Department of Bioengineering, Imperial College London
- 15.30 **Full-wave modelling of therapeutic ultrasound propagation to the kidney in CT based patient models**, V Suomi¹, J Jaros², B Treeby³, R Cleveland¹, ¹Department of Engineering Science, University of Oxford, ²Faculty of Information Technology, Brno University of Technology, Czech Republic, ³Department of Medical Physics and Biomedical Engineering, University College London

2016 ANNUAL DINNER AND AWARDS CEREMONY, National Railway Museum, Leeman Rd, York YO26 4XJ

19.00 - late Supported by Hitachi Medical Systems

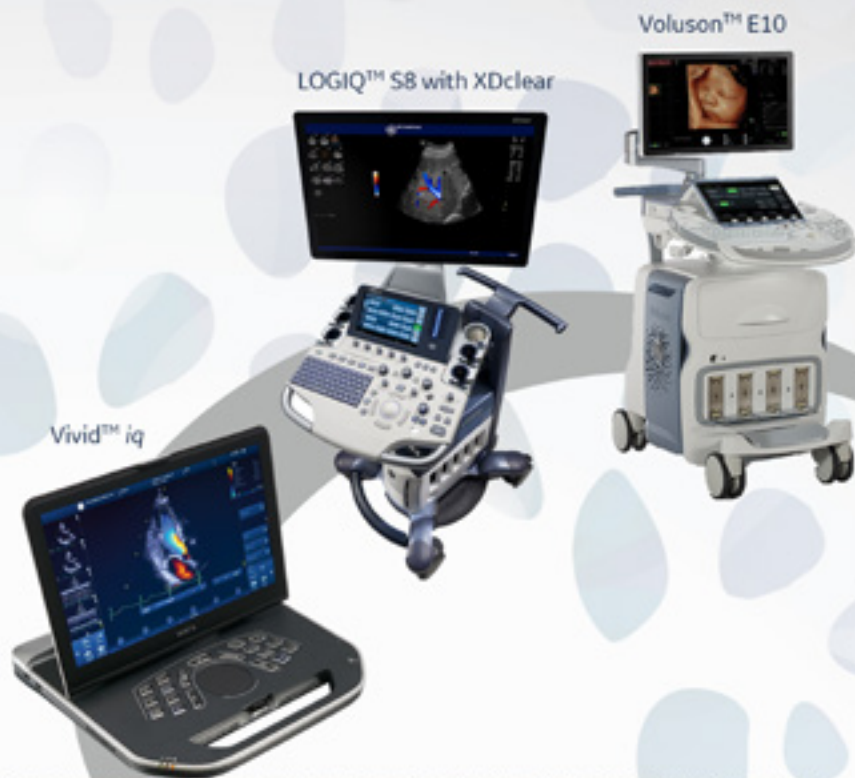

GE Healthcare

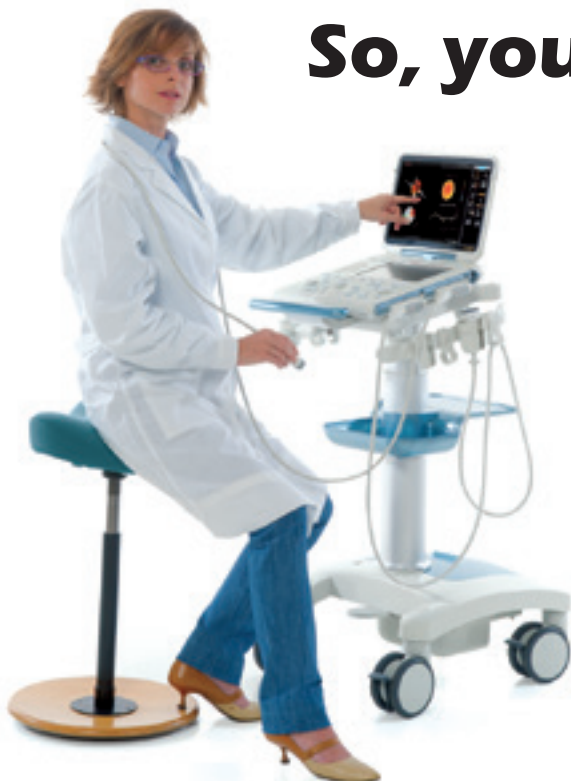**Extraordinary images.
Specialised systems.
Innovative solutions.**

Every GE Healthcare ultrasound system is designed with you, your specialty, and your patients in mind.

Visit us at **Stand #4** at **BMUS 2016**, or email: Ultrasound.MarketingUKI@ge.com



© 2016 General Electric Company. All rights reserved. GE and GE Healthcare are trademarks of General Electric Company. GE Healthcare, a division of General Electric Company. GE Medical Systems Ltd Registered Office: Fulbourn Road, Houghton Lane, Chalfont St Giles, Bucks, HP8 4SP, UK. * Trademark of General Electric Company.



So, you know Esaote?

So you know:

- We are one of only two suppliers approved to supply scanners to the AAA screening programme.
- We were the first company to introduce Fusion Imaging.
- Our scanners include a MSK image library to assist in teaching and development.

For more surprises and to see how we can enhance your patient care, visit our stand at BMUS 2016 or contact us at infouk@esaote.com

esaote
Creativity in Healthcare

8th December 2016
National Rail Museum, York

HITACHI
Inspire the Next

Sponsors

BMUS
ANNUAL GALA DINNER
& AWARDS CEREMONY

19:00 Pre-Dinner Drinks

Amidst fascinating railway history such as the Flying Scotsman, romance of Brief Encounter and the splendor of Orient Express, enjoy a glass of wine on the promenade.

19:45 Gala Dinner & Awards Ceremony

Relocate to the Station Hall and dine amidst luxurious carriages and iconic collections such as 'Palace on Wheels. Variety entertainment during the BMUS awards ceremony, include illusions and magic, Michael Jackson Act, Vegas-style Cirque Du Soleil, show girls, fun casino tables, DJ and disco.

Award ceremony: winners of the Scientific Poster session, BMUS Young Investigator 2016, Post Graduate Journal Prize and Paul Allan Best Published Paper will be announced. The ceremony will also host the presidential inauguration of Dr Simon Freeman as BMUS President for 2017/2018

Carriages at 12.30am

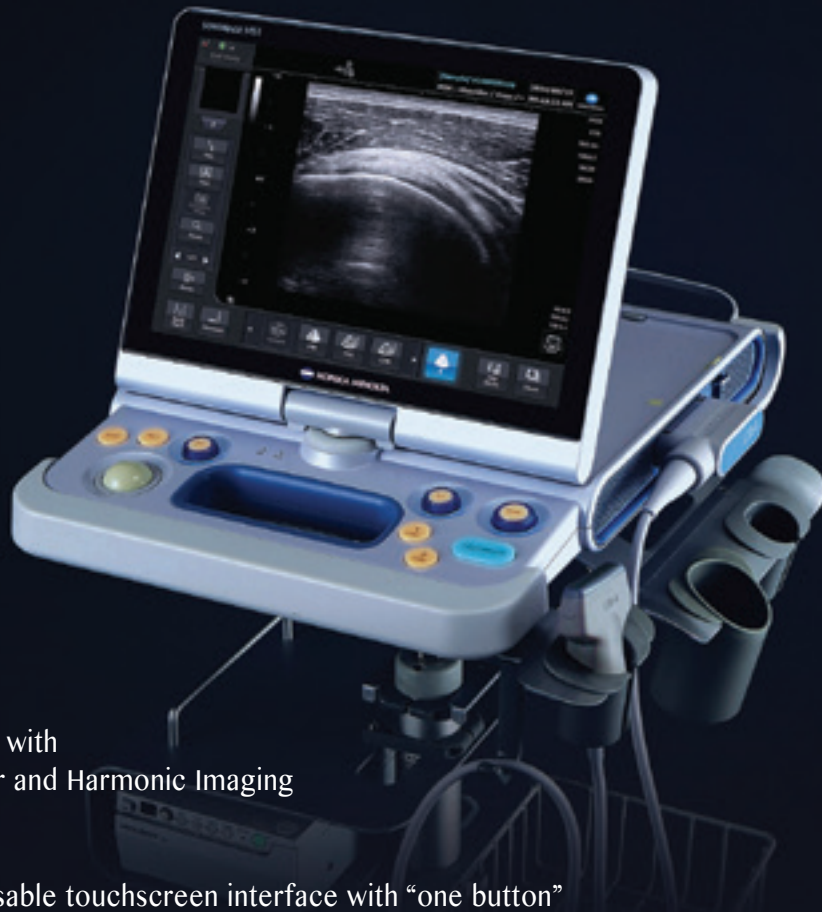

KONICA MINOLTA

PRIMARY IMAGING
SOLUTIONS

Konica Minolta. Right Solutions. Right Time.

U L T R A S O U N D S Y S T E M
SONIMAGE HS1



Best in class imaging with
Advanced Transducer and Harmonic Imaging
Technology

Easy to use, customisable touchscreen interface with “one button”
image optimisation

Unique, Simple Needle Visualisation Technology

Giving Shape to Ideas



Distribution Partner
www.wsrimaging.com

Call 01706 830086 to
arrange a trial.

At a Glance DAY 3

Day 3 - FRIDAY 9th December 2016					
Session Starts	LECTURES			PRACTICAL TRAINING	SATELLITE SESSION
	3rd Floor Voltigeur 2	3rd Floor Voltigeur 1	4th Floor Box 2	2nd Floor Dayjur Suite	4th Floor Box 5
09.00	Abdominal / General Imaging 1 - Dilemmas in Scrotal Ultrasound	Professional Issues 4 - CASE	Vascular 1 - Aneurysms	Elastography Masterclass	Translational Ultrasound Imaging Meeting
10.30 Morning Refreshment Break - Exhibition Hall Ground Floor					
11.00	Abdominal / General Imaging 2 - Diffuse Liver Disease	Professional Issues 5 - The BMUS Debate	Vascular 2 - Carotid	DVT Integrated Training	Translational Ultrasound Imaging Meeting
12.30 Lunch Break- Exhibition Hall Ground Floor					
13.30	Abdominal / General Imaging 3 - Cystic Lesions in the Abdomen	Early Pregnancy 1-1st Trimester Screening	Vascular 3 - Peripheral Arterial	DVT Integrated Training (Cont'd)	Translational Ultrasound Imaging Meeting
15.00 Afternoon Refreshment Break- Exhibition Hall Ground Floor					
15.30	Abdominal / General Imaging 4 - Conundrums in General Ultrasound	Early Pregnancy 2 - Hot Topics in Early Pregnancy and Management	Vascular 4 - Case Study Workshop		Translational Ultrasound Imaging Meeting
17.00 CLOSE					

Scientific Programme 2016

Day 3 – Friday 9th December

Plenary 1 – 3rd Floor, Voltigeur 2

Abdominal / General Imaging 1 - Diagnostic and Management Dilemmas in Scrotal Ultrasound

09.00 – 10.30 **Chairs** – Mr Peter Cantin, Derriford Hospital, Plymouth, Dr Oliver Byass, Hull and East Yorkshire Hospitals NHS Trust

While ultrasound is a sensitive and effective tool in the diagnosis of testicular cancer, ultrasound appearances are sometimes encountered which have a broader differential diagnosis or where the differentiation between normal and pathological appearances is more difficult.

This session is aimed at radiologists, sonographers and trainees and will assist them in reporting and management of scrotal abnormalities.

09.00 **Varicoceles - diagnosis and difficulties**, Dr Jane Belfield, Royal Liverpool University Hospital

09.25 **Ultrasound of extra-testicular masses**, Dr Dean Huang, Kings College Hospital, London

09.50 **Ultrasound management of the impalpable testicular lesion**, Dr Simon Freeman, Derriford Hospital, Plymouth

Abdominal / General Imaging 2 - Diffuse Liver Disease

11.00 – 12.30 **Chairs** – Dr Simon Freeman, Mr Peter Cantin, Derriford Hospital, Plymouth

Chronic liver disease is an increasing problem worldwide and this session discusses the current and emerging role of Ultrasound in the diagnosis and work up of these patients.

This session is suitable for all practitioners who perform General Abdominal Ultrasound Examinations.

11.00 **The clinical value of ultrasound in assessing patients with chronic liver disease**, Dr Lynsey Corless, Hull and East Yorkshire Hospitals NHS Trust

11.25 **Ultrasound of diffuse liver disease and advanced applications**, Prof Adrian Lim, Imperial College NHS Trust, London

11.50 **Pitfalls in Hepatobiliary Ultrasound**, Dr Christopher Harvey, Imperial College Healthcare NHS Trust

12.15 **Comparative Study Of Shear Wave Elastography Systems On Two Ultrasound Units In Patients With Known Or Suspected Liver Disease**, Mrs Pamela Parker, Hull and East Yorkshire Hospitals NHS Trust

Abdominal / General Imaging 3 - Cystic Lesions in the Abdomen

13.30 – 15.00 **Chairs** – Dr Simon Freeman, Derriford Hospital, Plymouth, Mr Peter Cantin, Derriford Hospital, Plymouth

Cystic lesions are a common finding during abdominal ultrasound examinations. However, assessing their significance can sometimes be difficult. This session aims to review the appearances of commonly encountered abdominal cystic lesions, their significance and recommendations for further management.

This session is aimed at radiologists, sonographers, trainees and interested clinicians.

13.30 **Cystic lesions of the Pancreas**, Dr Abdul Razak, Hull and East Yorkshire Hospitals NHS Trust

13.55 **Cystic lesions of the Liver**, Dr James Pilcher, St Georges Hospital, London

14.20 **Cystic lesions of the Kidney**, Dr Oliver Byass, Hull and East Yorkshire Hospitals NHS Trust

14.45 **Contrast enhanced ultrasound (CEUS) imaging of focal liver lesions at a single centre: initial experience**, M Thyoka, J Wild, M Hood, C Clout, Sheffield Teaching Hospitals NHS Trust

Abdominal / General Imaging 4 - Conundrums in General Ultrasound

15.30 – 17.00 **Chairs** – Dr Simon Freeman, Derriford Hospital, Plymouth, Dr James Pilcher, St George's Hospital, London

The use of ultrasound in some clinical scenarios is controversial. This session aims to examine the advantages and drawbacks of ultrasound in specific clinical scenarios.

The session is aimed at Radiologists, Sonographers, Trainees and other interested clinicians.

15.30 **What is the role of ultrasound in trauma?** Dr Dave Gay, Derriford Hospital, Plymouth

15.50 **Point of Care ultrasound: Are we practicing safely?** A Weerasinghe, A McGuinness, P Tung, C Mapatuna, Z Ahmed, Mid Yorkshire Hospitals NHS Trust

16.00 **What is the role of ultrasound in inflammatory bowel disease?** Dr Peter Rodgers, University Hospitals of Leicester NHS Trust

16.20 **SMI in the GIT**, N Grunshaw, University Hospitals Morecambe Bay NHS Trust

16.30 **What is the role of ultrasound in renal obstruction?** Mr Peter Cantin, Derriford Hospital, Plymouth

Plenary 2 – 3rd Floor, Voltigeur 1

Professional Issues – CASE

09.00 – 10.30 **Chairs** – Mrs Pamela Parker, Hull and East Yorkshire Hospitals NHS Trust, Dr Rhodri Evans, Morriston Hospital, Swansea

The shortage of qualified sonographers has reached a critical level within the UK with many Trusts unable to recruit into vacant positions. Ultrasound services are being delivered with heavy reliance of agency and locum staff which is unsustainable and detrimental to the growth and development of a sonographic career pathway. Health Education England has been working with the Centre for Workforce Intelligence, relevant professional bodies, educationalists and service users over the last 18 months to review the causes of the current shortfall and develop short, medium and long term plans to alleviate the staffing crisis.

CASE plays a pivotal role in setting and maintaining standards for sonographic education through its accreditation scheme. Proposed changes to sonographic education will impact on how and who accredits future training courses. Any proposed changes to career pathways will impact on existing staff and how service is delivered in the future. Our professional bodies are working through how best to support career development, increase staff numbers and ensure patient safety remains the top priority.

The aim of this session is to deliver an overview of the opportunities for education in imaging given recent changes to funding and how this will impact on service and sonographic career development in the future.

This session will be of benefit to all service providers including managers and sonographers, educationalists and radiologists.

- 09.00** **Vision and opportunities for supporting lifelong learning in diagnostic imaging professionals**, Mrs Anne-Marie Culpan, University of Leeds
- 09.30** **Changes to the sonographic career pathway - Impact to the profession**, Mr Richard Evans OBE, The College of Radiographers
- 09.50** **Changes to the sonographic career pathway - Impact to the education**, Mr Simon Richards, Teesside University / Chair of CASE
- 10.10** **Sonographer workforce survey**, S Morrissey, Mid Yorkshire Hospitals NHS Trust
- 10.20** **Growing capacity for sonographer training – rethinking clinical academic partnership**, H Venables¹, A Ferguson², ¹University of Derby, ²Derby Teaching Hospitals NHS Trust

Professional Issues – CASE

11.00 – 12.30 **Chairs** – Dr Rhodri Evans, Morriston Hospital, Swansea, Dr James Pilcher, St Georges Hospital, London

11.00 **Ultrasound is dangerous and should be controlled like drugs, alcohol and arms**
Speaking for the motion : Dr Roger Moshy, Peterborough and Stamford Hospitals NHS Foundation Trust

Speaking against the motion : Prof Gail ter Haar, Institute of Cancer Research, Sutton
Contributors : H Woodgate, N Emmerich, C Brezinka, P Salvesen

Early Pregnancy 1 - 1st Trimester Screening – Will free fetal DNA testing replace the 12 week scan?

13.30 – 15.00 **Chairs** – Mrs Alison McGuinness, Mid Yorkshire Hospitals NHS Trust, Dr Roger Moshy, Peterborough and Stamford Hospitals NHS Foundation Trust

There has been much discussion and evidence produced that free fetal DNA testing will replace the need for 12 week nuchal translucency screening in the near future. Three eminent experts here discuss this highly topical and eagerly anticipated subject.

The 12 week scan has more to offer than dating and NT measurement. The invited speakers will give a comprehensive review of fetal abnormality detection as well as how this examination can be used to predict preeclampsia, growth restriction and assess cervical length. The adjunct of the anticipated blood test and the merits of using this in 1st trimester screening will be discussed.

A session not to be missed by any practitioner working in this demanding field of practice.

13.30 **Free Fetal DNA Blood test – the answer to 1st trimester screening**, Dr Sarah Bower, Harris Birthright Centre, Kings College Hospital NHS Trust, London

13.55 **1st Trimester Anomaly detection – more than a screening test**, Dr Ann Marie Coady, Hull and East Yorkshire Hospitals NHS Trust

14.20 **Beyond abnormalities and screening – what more can the 1st trimester scan offer?**
Dr Elena Greco, The Royal London Hospital

14.45 **Q & A session**

Early Pregnancy 2 - Hot Topics in Early Pregnancy and Management

15.30 – 17.00 **Chairs** – Mrs Catherine Kirkpatrick, United Lincolnshire Hospitals NHS Trust, Dr Roger Moshy, Peterborough and Stamford Hospitals NHS Foundation Trust

As imaging improves our understanding of ultrasound findings in early pregnancy is challenged. Coupled with rising patient expectations and complexity of presentation this field of imaging practice can be difficult. This session aims to provide delegates working in early pregnancy with the latest advice for imaging and management of common and less common, but highly significant, clinical presentations and findings.

15.30 **Gestational trophoblastic disease and Doppler – an aid to diagnosis**, Prof Adrian Lim, Imperial College NHS Trust, London

16.00 **Potential pitfalls in the diagnosis of miscarriage and ectopic pregnancy**, Dr Jackie Ross, Kings College Hospital, London

16.30 **Hot Topics in Early Pregnancy imaging - test your knowledge and skills**, Mrs Alison McGuinness, Mid Yorkshire Hospitals NHS Trust, Dr Jane Arezina, University of Leeds

Plenary 3 – 4th Floor, Box 2

Vascular 1 - Aneurysms

09.00 – 10.30 **Chairs** – Mrs Tracey Gall, University Hospital of South Manchester, Dr Richard Simpson, University Hospital Nottingham

This session looks at innovative new technologies for the assessment of aneurysm and EVAR.

09.00 **Update from NAAASP**, Ms Lisa Summers, Public Health England

09.25 **Fusion Imaging of AAA**, Mrs Borsha Sarker, Independent Sonographer

09.50 **Extracranial arterial wall volume is increased in idiopathic Parkinson's Disease**, Mr Steve Ball, University Hospital of South Manchester

10.10 **Case Study - A leaking Abdominal Aortic Aneurysm**, S Dunne, Maidstone and Tunbridge Wells NHS Trust

10.20 **EVAR follow-up with ultrasound - 6 years of experience in York**, M Nicolls, G Johnson, M Crowe, L Patrick, York Teaching Hospitals NHS Foundation Trust

Vascular 2 - Carotid

11.00 – 12.30 **Chairs** – Mrs Tracey Gall, University Hospital of South Manchester, Mr Steven Rogers, University Hospital of South Manchester

11.00 **Ultrasound and carotid plaque imaging**, Dr Richard Simpson, Nottingham University Hospital

11.25 **Carotid plaque fusion**, Mr Lee Smith, University Hospital of South Manchester

11.50 **UKAS Vascular Lab Accreditation: The story so far....**, Mr Richard Pole, IVS Ltd, Manchester

12.10 **A strong arm leads to a weak point - the role of ultrasound in the diagnosis of Upper Extremity Deep Vein Thrombosis**, K Cronin^{1,2}, A Kelly², M Stanton¹, T Herlihy T¹, ¹University College Dublin, ²St Vincent's University Hospital, Dublin

12.20 **Case Study - Ocular Ischaemic Syndrome in a patient with retrograde flow in the left carotid arteries**, Mrs Tracey Gall, University Hospital South Manchester

Vascular 3 - Peripheral Arterial

- 13.30 -15.00** **Chairs** – Mr Lee Smith, University Hospital of South Manchester, Dr Richard Simpson, Nottingham University Hospital
- 13.30** **Digital artery assessment in the treatment of syndactyly in paediatric patients**, Mr Robert Winterton, University Hospital of South Manchester / University of Manchester
- 13.55** **Ultrasound guided angioplasty for the dialysis access fistula – initial experience**, Mr Ben Freedman, Kings College Hospital, London
- 14.15** **Ultra high frequency ultrasound for vascular applications**, Mr Steven Rogers, University Hospital of South Manchester
- 14.40** **Reliability of Doppler velocities across a new vascular network**, M McKenna, T Robinson, University Bristol Hospitals Trust
- 14.50** **Early detection of atherosclerosis using non-invasive high-frequency preclinical ultrasound imaging**, J Janus¹, B Kanber³, E Karamanavi², K Ramnarine³, N Samani², E Stringer², M Kelly¹, ¹Preclinical Imaging Facility, University of Leicester, ²Department of Cardiovascular Sciences, University of Leicester, ³Medical Physics Department, University Hospitals of Leicester NHS Trust

Vascular 4 – Case Study Workshop

- 15.30 - 17.00** **Led by** – Mrs Tracey Gall, University Hospital of South Manchester, Mr Steven Rogers, University Hospital of South Manchester
- 15.30** Interactive session using audience voting system to review and discuss a range of vascular ultrasound images.



Practical Workshop Session – 2nd Floor, Dayjur Suite

Elastography Masterclass

09.00 – 10.30 **Led by** – Prof Adrian Lim, Imperial College, London

This workshop will outline the different Elastography technologies available followed by a practical session on how to perform strain and shearwave elastography using different scanners. Potential clinical applications will also be discussed

The workshop is aimed at sonographers and sonologists who would like to start utilising Elastography in their routine clinical practice.

DVT Integrated Training

11.00 – 15.00 **Led by** - Mrs Borsha Sarker

This training session provides 3 hours of practical training with experts in this field. Ideal for students and those who wish to improve their technique.

The session will cover DVT scanning in the arm, pelvis, fem-pop segment, calf veins and includes technique, pathology and reporting advice.

Faculty -

Mrs Jean Bainbridge, Hull and East Yorkshire Hospitals NHS Trust
 Mr Gavin Hope, Queen Elizabeth Hospital, Gateshead
 Ms Khalida Jan, City Hospitals Sunderland NHS Foundation Trust
 Mrs Gemma Norris, Freeman Hospital, Newcastle
 Mrs Yasmin McGrady, Independent Sonographer
 Mrs Borsha Sarker, Independent Sonographer
 Mrs Rachel Wilson, Hull and East Yorkshire Hospitals NHS Trust



Satellite Session – 4th Floor, Box 5

Translational Ultrasound Imaging Meeting

- 09.30 – 12.30** **Chair** – Dr Carmel Moran, University of Edinburgh
- 09.30** **Arrival and registration**
- 10.00** **An investigation into the variability of shear wave elastography acquisition methods in muscle**, Mr Abdulrahman Alfuraih, PhD Research Fellow, Leeds, Institute of Rheumatic and Musculoskeletal Medicine
- 10.30** **Theranostic Micro & Nano Bubbles: From formulation to application**, Prof Steve Evans, Professor of Molecular and Nanoscale Physics, University of Leeds
- 11.00** **Refreshment break**
- 11.30** **Characterisation of neonatal cardiac growth and regeneration following injury using high resolution in-vivo ultrasound**, Mr Raphael Castellan, University of Edinburgh
- 12.00** **Multimodal imaging to track cells and assess organ function**, Dr Jack Sharkey, Cellular and Molecular Physiology, University of Liverpool
- 12.30** **Lunch provided in the 2016 BMUS Technical Exhibition on the ground floor**
- 14.00 – 16.30** **Chair** – Dr Louise Colletta, University of Leeds
- 14.00** **The potential of photoacoustic imaging biomarkers for monitoring tumour oxygenation**, Dr Sarah Bohndiek, University Lecturer in Biomedical Physics, University of Cambridge
- 14.30** **Drug loaded microbubbles for the treatment of pancreatic cancer**, Prof John Callan, Norbook, Chair in Pharmaceutical Science, University of Ulster
- 15.00** **Refreshment break**
- 15.30** **Combining ultrasound laser light and nanoparticles for improved cancer detection and therapy**, Dr James McLaughlan, University of Leeds
- 16.00** **Characterising pregnancy disorders in mice using ultra-high frequency ultrasound**, Dr Colin Murdoch, Marie Curie International Fellow, Aston Medical Research Institute



Wednesday

Thursday

Friday



1 Pristine image quality

2 Advanced ergonomic design

3 Extraordinary workflow

© Carestream Health, Inc., 2016. CARESTREAM is a trademark of Carestream Health.

f t YouTube

TOUCH

Feel the power for yourself on Stand 5

the power of TOUCH

From a world leader in diagnostic imaging comes Touch Prime, taking ultrasound image quality to a new level of detail and clarity.

Touch Prime combines advanced ultrasound beam-forming with unique algorithms that process the acoustic data. The system goes even further by applying advanced computing capabilities to deliver powerful graphic processing for image and data optimization. The result is high spatial and contrast resolution, a high frame rate and consistent beam uniformity throughout. This means more detailed and more accurate information – including deep abdominal imaging – delivered faster.

Add to all this the two other touchstones of our design – advanced ergonomic design and extraordinary workflow – and it's clear that with CARESTREAM, ultrasound users are in capable hands.

Visit our website to discover more.

Carestream
carestream.com/touch

New Zealand is...



CALLING ALL SONOGRAPHERS

Come to Stand Number **35** at **BMUS 2016!** Find out about **NEW ZEALAND.**

Put yourself in the centre of it all!

Let us talk with you about the positions available, the lifestyle choices and general information about the different hospitals and locations. Contact Christine Wood at centralregionradiology@midcentraldhb.govt.nz

Put yourself in the centre of it all and experience the Kiwi lifestyle in a region that includes the coolest little capital in the world (says Lonely Planet), outdoor pursuits – limitless opportunities to either thrill you or chill you. This is a region that has a food and wine culture that will captivate you.

www.kiwihealthjobs.com/home

March Clinical Ultrasound for Hepatologists

April 27th – Gynaecology

May 20th & 21st – MSK Study Weekend, Stafford

June 6th – Head and Neck
19th & 20th – Kings CEUS Paediatric Course, London

September 5th – Abdominal
29th – Paediatrics

October 13th – Obstetrics

December Ultrasound 2017 – the 49th Annual Scientific Meeting

For the latest updates, please visit our website :
www.bmus.org/education-and-events/bmus-study-days/

Poster Exhibition 2016

Research

1. **Twinkle artefact in the ultrasound diagnosis of superficial epidermoid cysts**, R Clarke¹, S Freeman², P Suresh², R Thomas³, ¹Peninsula Radiology Academy, Plymouth, ²Derriford Hospital, Plymouth, ³The Austin Hospital, Australia

Aim

The aim of the study was to evaluate whether the twinkle artefact is a valuable feature in the sonographic diagnosis of superficial epidermoid cysts. Materials and methods: A retrospective search was undertaken of our institution's Radiology Information System and pathology database to identify cases of superficial masses showing the twinkle artefact that proceeded to surgical excision.

Results

Eighteen superficial masses demonstrating the twinkle artefact were identified that were submitted for pathological analysis. Of these, 17 were confirmed to represent epidermoid cysts and only 1 case had an alternative diagnosis (proliferating trichilemmal cyst).

Conclusion

The presence of the twinkle artefact appears to be a specific and valuable ancillary sonographic feature for the diagnosis of superficial epidermoid cysts.

2. **Should there be a standard guideline or threshold value for endometrial thickness in postmenopausal women with abnormal uterine bleeding in England?**, R Reeve, Portsmouth Hospitals NHS Trust / King's College London

Background

Postmenopausal bleeding is the presenting symptom in 95% of cases with TVS recommended as the first line investigation in these women. Despite numerous studies assessing the accuracy of endometrial thickness measurement with TVS in women with PMB, without the use of HRT/Tamoxifen, currently there are no national guidelines. Previously 5mm was recommended by the literature as the most effective threshold, however more recently 3mm is described as the most sensitive threshold to reliably exclude endometrial malignancy. Alternative guidelines from international organisations show a variety of thresholds, varying from 3-5mm, with none currently published by English professional bodies.

Methods

A service evaluation of ultrasound department protocols in the form of online survey was performed to provide data on current practice. Following a pilot study a questionnaire was advertised including 10 questions to discover; what endometrial thresholds were used, who created the protocol, when protocols were updated and if participants felt a need for more national guidance. Participants were ultrasound lead/managers, consultant sonographers and sonographers who currently work within NHS hospitals in England.

Results

Results show despite no statistically significant difference in ET "cut-off" values between ultrasound departments, there is a difference between what has been most recently advised as the most effective endometrial threshold (3mm). Of the responses, 92.9% felt that services would benefit from national guidelines. When looking at influences on department practice, overall survey results show that there is little impact on protocols by creator or information sources.

Conclusions

Results highlight a need for national guidelines to ensure standardised care throughout ultrasound departments within the NHS, with consideration of additional training and audit systems within hospitals to increase sonographer and clinician confidence regarding accuracy of TVS for detecting endometrial cancer in patients presenting with PMB.

3. Examination of the maximum grip strength of ultrasound practitioners and associated factors affecting grip strength, A Wood¹, G Harrison², A Harris², ¹Ashford and St Peter's Hospital, ²City University of London

Methods

A questionnaire was distributed to ultrasound practitioners at a BMUS conference and at supervisor training days at City University London. In addition, measurements of the responding ultrasound practitioners' maximum grip strength of their dominant and non-dominant hands were taken using a Jamar Dynamometer. The questionnaires were analysed and factors were chosen to investigate.

Past injury was also investigated to determine if age, years scanning, gender or perceived percentage of obese patients scanned had an effect on maximum grip strength. The maximum grip strength measurements were examined and the above factors were analysed using non-parametric statistical tests with significance level of $p < 0.05$.

Results

The response rate obtained was 15.4%, with 96 participants out of a total of 624. It was found that males had higher maximum grip strength than females, for all ages. Gender and past injury had a statistically significant effect on the maximum grip strength of the scanning hand and the non-scanning hand. Further investigation into past injury showed that there was a significant effect of age, years scanning and gender.

Statistical tests revealed that age, BMI, years scanning and the self-reported estimates of obese patients scanned had no statistically significant effect on maximum grip strength. Similarly the self-reported estimates of the percentage of obese patients scanned showed no statistically significant effect on past injury.

Conclusion

The findings for maximum grip strength values were most similar to the reference values by Bohannon et al. (2006). Males had higher maximum grip strength than females and those who had not had an injury had higher maximum grip strength than those who had. Ultrasound practitioners should be aware of the impact of past injury and gender on their maximum grip strength. Awareness should also be made of the impact of gender, age and years scanning.

4. The use of simulation in ultrasound education: A qualitative study, C Hynes, P Mitchell, Sheffield Hallam University

Background

Increasing pressures in clinical departments, including staff shortages and an increased demand for services, mean that alternative methods of teaching clinical skills are being sought by educators. The role of simulation in healthcare education is increasing rapidly, and as technology has improved, high-fidelity virtual reality based simulators are capable of providing a variety of learning experiences.

Aim

To investigate the experiences and perceptions of students and staff using simulation in ultrasound education.

Methodology

A qualitative study was undertaken, using semi-structured interviews to investigate the experiences of a group of ultrasound students and academic staff.

Results

The findings confirm that ultrasound simulation provides learning opportunities in an unpressured environment, which can improve clinical skills, and therefore reduce risk to patients. However simulation learning cannot support the development of the full range of skills required by sonographers, and is therefore not suitable as a replacement for clinical experience, or as a summative assessment tool. The fidelity of the simulation, and therefore the transferability of skills into the real clinical environment requires further study.

Conclusions

Simulation can play a useful role in clinical training, however it remains a useful addition to clinical placements, rather than a replacement for learning in the real clinical environment.

5. **The effect of ultrasound with acoustic radiation force on rabbit lung tissue: Preliminary study**, N Takayama¹, Y Ishiguro¹, N Taniguchi¹, W Takano², H Sasanuma¹, N Nitta³, I Akiyama², ¹Jichi Medical University, ²Doshisha University, ³National Institute of Advanced Industrial Science and Technology

Background

Acoustic Radiation Force (ARF) elastography was recently introduced as a diagnostic modality that applies higher acoustic power with longer pulse durations than conventional diagnostic ultrasound. Several reports have described lung injuries in animal models exposed to ultrasound at conventional diagnostic levels. The effect of ultrasound with ARF on the lung is unknown. We report lung injuries induced by ultrasound with ARF in a rabbit lung model.

Methods

A focused 2.5 MHz transducer that emits ultrasound with ARF was placed in the subcostal region of two anesthetized rabbits aimed at the lung through the abdominal wall and liver. Exposure settings were varied in the two animals and included: #1: mechanical index (MI) 0.80, pulse duration (PD) 10ms, pulse repetition time (PRT) 5s, exposure time 150s, #2: MI 0.62, PD 10ms, PRT 5s, exposure time 150s. After exposure, the rabbits were sacrificed and the lungs and trachea removed for macrophotography and histopathologic study.

Results

One red spot was observed on the surface of the lung corresponding to the area of exposure in each animal. Alveolar hemorrhage was observed in the microscopic study.

Discussion

Although ARF elastography is designed to operate within accepted diagnostic limits (MI 1.9), ultrasound with ARF is significantly different from conventional diagnostic ultrasound, especially with respect to pulse duration. Since lung injury may be induced at a lower exposure threshold, the safety of ultrasound with ARF should be confirmed in an in vivo study. These results identify a potential risk of lung injury associated with ARF elastography when the transducer is directed toward the lung, especially during liver or breast imaging.



Professional Issues

6. **Walk-in community ultrasound service**, R Wilson, Hull and East Yorkshire NHS Hospitals

There are a number of non-obstetric ultrasound examinations which lend themselves to being provided in a community setting and which improve patient management if they are undertaken as promptly as possible. With this in mind, the ultrasound service provided by Hull and East Yorkshire Hospitals NHS Trust initiated a pilot scheme to provide direct access capacity for ultrasound services at the Westbourne NHS centre. A walk-in service for general abdominal and gynaecological ultrasound referrals has been offered Monday to Friday 10.30am – 5pm. This commenced on 19th October 2015 and ran until the end of Jan 2016

The pilot aims were to:

- Improve access for GP ultrasound referrals providing
- Reduce referral rate and demand into the ultrasound service provided in the secondary care setting

This presentation will review the outcomes and the issues from this pilot study.

7. **Automatic classification of abdominal ultrasound findings as normal, abnormal or inconclusive**, N Zulkarnain, G Crofts, F Meziane, University of Salford

Variations in writing style, content, format, and terminology of an ultrasound report impacts the way a report is interpreted. Some ultrasound reports are commonly written in a free-form paragraph which will later be read by referring clinicians in order for them to make decisions. Often reports are produced in free-form style which can lead to variation in the way reports are interpreted and this can be a time consuming task. What is needed is a more standardised ultrasound reporting system that enables relevant information to be acquired more efficiently and effectively to allow for improved decision making.

We present a prototype of an ultrasound reporting system that takes a free-form ultrasound report as input and transforms it into a structured form where findings are presented as structured and standardised sentences. Each line of findings highlights the area being observed. Check boxes are also included to classify the findings as normal, abnormal or inconclusive. This method of presenting ultrasound report findings makes it easier in reading and identifying relevant information. It also forces report writers to classify their finding so that it is more meaningful for the referring clinicians.

In this prototype, we also present a method to automatically classify each finding as normal, abnormal or inconclusive depending on the information available in each sentence. This prototype uses ontology and rule based method to automatically classify these findings. The development of this ultrasound reporting system will enable referring clinicians faster and easier reading of reports.



Abdominal

- 8. Hepatic steatosis by ultrasound: Qualitative evaluation vs quantitative evaluation,** R Santos, A Silva, A André, Coimbra Health School

Background

Hepatic steatosis is a pathological liver condition and it's difficult to characterize and detect. Ultrasound has been increasingly used on hepatic steatosis evaluation. Despite quantitative evaluation is becoming preferred; the qualitative assessment still dominates the ultrasound evaluation of steatosis.

Purpose

To evaluate liver echo-intensity by ultrasound. To verify the correlation of different quantitative index of liver evaluation and to compare the effectiveness of quantitative and qualitative methods of ultrasound evaluation.

Methods

Ninety-two subjects with an average age of 24. 77 were submitted to a liver ultrasound evaluation (GE Logiq e). Three images of the liver were acquired and subsequently their echo-intensity was assessed using the software Image J. From the echo-intensity values was calculated Hepatorenal index (IHR) (the average value of echo-intensity liver / renal echo-intensity value). All the images were evaluated from two independent evaluators.

Results

There were no correlations between IHR index and with alcohol consumption variables, smoking and liver dimensions. There are significant differences between IHR index and the observer 1 evaluation and no significant differences between IHR index and the observer 2 evaluation.

Conclusions

In the study, the steatosis was evaluated through the echo-intensity differences between the hepatic parenchyma and kidney cortex. The statistical analysis revealed that CH is a good indicator of the presence of steatosis with a correlation of 0.5. It was also found that the quantitative evaluation is shown to be more effective than a qualitative evaluation. The qualitative evaluation is more subjective and dependent on the inter-operator observation.

- 9. How accurately can contrast-enhanced (CE) ultrasound characterise focal splenic lesions in comparison to CE computed tomography and CE magnetic resonance imaging? A systematic review,** R Smith¹, J Wilson², ¹York NHS Teaching Hospital, ²University of Leeds

Background

Unenhanced conventional ultrasound is the main first-line imaging method for investigating a wide variety of abdominal symptoms. As a result, it is often the first imaging modality to incidentally detect focal lesions of the spleen. Ultrasound alone is of limited value to accurately differentiate benign from malignant lesions. Current options for further investigation include contrast-enhanced computed tomography (CECT), contrast-enhanced magnetic resonance imaging (CEMRI) or biopsy. However a new technique, which involves the addition of a second-generation microbubble contrast agent to an ultrasound examination, may improve its diagnostic ability to a level comparable to the diagnostic investigations currently employed.

Objective

To compare diagnostic performance of contrast-enhanced ultrasound (CEUS) using the contrast agent SonoVue with that of CECT and CEMRI in the assessment of adults with an inconclusive, non-traumatic focal splenic lesion (FSL) incidentally detected on previous abdominal imaging.

Methods

Systematic review methods employed in this review adhered to current published guidance. From the 21 March to the 6 April 2015, 10 electronic databases were searched. Hand searching and grey literature searching were also undertaken.

Results

From a total of 480 records identified, 4 studies were included in this review. All studies were diagnostic test accuracy (DTA) studies. The methodological quality of each study was assessed using the recommended appraisal tool QUADAS-2. All four studies were judged as potentially at risk of bias due to a general lack of reporting of key methodological issues and therefore a meta-analysis was deemed inappropriate. All studies concluded CEUS demonstrated a diagnostic performance that was similar to that of CECT and CEMRI for characterising incidentally detected non-traumatic FSLs.

Conclusion

CEUS may well be a valid alternative to CECT and CEMRI in this clinical scenario, however this systematic review was unable to draw firm conclusions. Further research is warranted to confirm the findings of this review.

10. **Wild Goose Chase: A foreign body mimic on an ultrasound image**, L Khalid¹, H Brunger², A Sahu¹, ¹Ealing Hospital, ²King's College London

Background

Suspected foreign body ingestion, insertion or retention may warrant investigative imaging. Further and follow-up imaging may also be required for example, if the site is inaccessible or removal is inappropriate, at the time of presentation. In interpreting any images, a high index of suspicion can help to prevent potential morbidity or mortality. However, false positives can arise. These can lead to unnecessary or inappropriate management. For this reason, it is vital to correlate any images obtained with the clinical presentation. Additionally, sonographers and radiologists must be mindful of possible foreign body migration, artefacts and limitations of the imaging modality and themselves. X-ray, ultrasound, CT or MRI may be indicated. The appearance of a foreign body on imaging may vary not only with its material and site, but between modalities too.

Case Report

A woman in her fifties presented with pain in the lower abdomen, post-surgically. An abdominal ultrasound scan identified what appeared to be part of a surgical drain in the anterior abdominal wall. Due to this, the patient had exploratory surgery. However, no foreign body was found. One cause of non-identification is foreign body migration, so the patient had an abdominal CT scan. Again, no foreign body was identified.

Despite the convincing appearance of foreign body on initial ultrasound imaging, further investigations suggested that there was none.

Discussion

This case study demonstrates how even the most convincing appearance on ultrasound imaging, done by an experienced sonographer, can be misleading. It also demonstrates how a false positive can lead to unnecessary investigations, including further follow-up imaging.

As with all imaging modalities, there are limitations which must be considered during interpretation. Healthcare professionals must remain vigilant of the possibility of false positives, ensuring they consider all possible reasons for the appearance of an image. This will support appropriate patient management.

11. **Ultrasound findings in the investigation of haematuria - something or nothing?** S Kennish, J Wild, N Jobling, Sheffield Teaching Hospitals

Background

Sonographer led ultrasound has replaced Computerised Tomography (CT) as the first line imaging for the investigation of haematuria at our tertiary institution. A one-stop haematuria clinic with dedicated imaging and a flexible cystoscopy is seen as best practice. Delays in appointing and reporting CT scans had previously thwarted this approach.

Patients with persistent unexplained haematuria despite normal ultrasound appearances and those with abnormalities identified on ultrasound are often further evaluated with CT. The review of stored ultrasound images and subsequent CT reporting by specialist radiologists has highlighted false positive and false negative findings on ultrasound. Cases have been collated and reviewed to highlight learning points.

Case Report

Ultrasound offers an excellent real time radiation free method of evaluating the renal tract. Small calculi and other subtle pathologies can be detected. Unfortunately normal structures can be mistaken for pathology. Prostatic hyperplasia can be mistaken for bladder tumour. A column of Bertin can be mistaken for an endophytic renal tumour. Peripelvic renal cysts are often mistaken for hydronephrosis. Midline prostatic cysts can be mistaken for seminal vesical cysts. Normal intra-renal vessels can be mistaken for renal calculi and calcified fibroids can be mistaken for bladder tumours. Abnormal structures may be mistaken for normal findings. Exophytic renal cysts need to be carefully evaluated in order not to miss focal complex features. Renal cysts can distract the operator from coincident endophytic solid renal tumours. Bladder wall thickening is often non-specific, but should be regarded as suspicious when focal, especially within a diverticulum.

Discussion

Cases depicting common pitfalls are pictorially reviewed and learning points are outlined to increase awareness and help the sonographer to optimise the scan. CT protocols can be directed by the ultrasound findings. A high quality ultrasound service can replace CT as first line imaging for haematuria.

12. Contrast-enhanced ultrasound of the spleen, G Zamfir, K Orr, S Freeman, Derriford Hospital, Plymouth

Aim

We aim to summarize the evidence for the applications of splenic Contrast-Enhanced Ultrasound (CEUS) with case examples from our department.

Background

The use of CEUS is rising. Initial guidance focused mainly on liver applications but over the years there has been more interest in non-liver applications. There is now increasing evidence to support the use of CEUS in the spleen.

Focal lesions in the spleen are less common than in other solid organs. When they do occur, the majority of splenic lesions are benign. However, malignant or infective lesions as well as infarcts can occur and imaging findings are often non-specific. A definitive diagnosis can be achieved with splenic biopsy, but this is an invasive procedure with associated risks of bleeding and infection. CEUS is a real-time investigation, which allows dynamic assessment of the spleen. It is a safe test with no associated radiation burden. The unique vascularisation of the spleen leads to a characteristic enhancement pattern, with homogeneous enhancement at around 1 minute and persistent late enhancement lasting longer than 5 minutes. Characterization of the enhancement pattern and presence or absence of washout with CEUS can confirm the nature of splenic lesions and can avoid the need for biopsy.

Content

We will outline the technical aspects of performing CEUS and review the current evidence for splenic applications. We will present our experience of CEUS of the spleen with cases from our ultrasound department. We will use these cases to demonstrate the enhancement characteristics of the normal spleen and benign and malignant splenic pathology

Conclusion

CEUS is a safe, dynamic examination, which can be used to characterize lesions in the spleen.

13. Post-Operative Ultrasound Assessment of En Bloc Kidney Transplants, A White, I Wijetunga, N Ahmad, M Weston, Leeds Teaching Hospitals NHS Trust

Background

Kidneys from donors under 5 years or 15kg are usually transplanted en bloc with the abdominal aorta and inferior vena cava. In the past, these donors have rarely been offered for donation. Recent UK legislation has allowed diagnosis of brain-stem death in infants under 2 months of age, expanding this potential donor pool. Ultrasound is the first line investigation of choice for the evaluation of the post-renal transplant patient and is vitally important to the clinical team in post-operative management. This presents a challenge to the ultrasound practitioner particularly when the donor is very young and the kidneys very small.

Methods

Twenty-eight en bloc kidney transplants (EKT) were performed over 11 years at our institution. Twelve were from donors less than two-months of age. We present a pictorial review of the expected post-operative development and of complications such as primary non-function (PNF), renal vein stenosis and hydronephrosis. CEUS, CT and MRI images are incorporated to illustrate certain examples.

Results

Twenty-two transplants are still functioning. Causes of graft loss were 1 PNF, 2 renal vein thrombosis and 3 due to chronic allograft nephropathy. Two patients required nephrectomy of one of the kidneys either intra-operatively or early in the post-operative period due to single kidney non-function. Four patients developed mild hydronephrosis in one or both kidneys.

Conclusions

EKT from very young donors is an emerging field with the largest UK single centre experience of EKT from donors under 2 months of age being at our institution. Patients receiving EKT are at relatively higher risk of vascular and ureteric complications. Ultrasound assessment of post-operative growth and identification of complications is of upmost importance in the management of these patients. Experienced sonographers in dedicated centers working with the clinical teams are best placed to assess complications and the normal expected growth of these organs.



MSK

- 14. Ultrasound imaging of the Quadriceps tendon – diagnosis of partial and complete rupture**, D Denniss¹, G Dolbear², ¹The Queen Elizabeth Hospital Kings Lynn NHS Trust, ²Canterbury Christchurch University

Content:

The classic ultrasound appearance of a normal quadriceps tendon has been described as resembling ‘the wind blowing snow over the mountain’ - the patella being the mountain and the intact quadriceps like snow blowing off the peak. This poster describes the anatomy of the anterior knee, the ultrasound technique used for obtaining optimal diagnostic images of the quadriceps tendon and the ultrasound appearance of both partial and complete ruptures of the tendon. The role of ultrasound in the diagnosis of rupture is reviewed comprehensively with reference to existing literature and studies. The value of ultrasound is compared to clinical diagnosis and other imaging modalities.

Conclusion

Ultrasound is an extremely useful tool for the evaluation of quadriceps tendon rupture and can provide invaluable information regarding the degree of rupture in conjunction with clinical findings. If the snow is not blowing over the mountain top consider a quadriceps tendon rupture!

- 15. The role of Ultrasound in Cubital Tunnel Syndrome**, J Brooks, C Kirkpatrick, United Lincolnshire Hospitals NHS Trust

Background:

Cubital tunnel syndrome is the most common form of ulnar nerve entrapment and the second most common entrapment neuropathy of the upper limb after carpal tunnel syndrome and may occur at the condylar groove or at the edge of the arcuate ligament.

Case Report

A 42 year old male was referred by his GP for an ultrasound examination of the right elbow for clinical history of transient pins and needles in the right hand in ulnar distribution, symptoms often being elicited during active movement of the elbow joint. Ultrasound examination revealed proximal thickening and oedema of the proximal ulnar nerve compared to the more distal fibres at the condylar groove. Appearances raised the possibility of an accessory anconeus epitrochlearis muscle resulting in entrapment syndrome. An MRI scan was requested for confirmation.

Discussion

Findings from this case study highlight that ultrasound is the initial choice of imaging modality in patients with suspected nerve entrapment because it is a cost effective, non-invasive, quick and a reliable modality for imaging the ulnar nerve that analyses the physical properties of the nerve, anatomical abnormalities and enables dynamic scanning. MRI was undertaken as a result of the ultrasound for confirmation and to provide additional information. Current literature supports these findings.

- 16. ALVAL - Aseptic lymphocytic vasculitis associated lesion**, S McGarry, C Chisholm, R Botchu, S James, M Davies, C Azzopardi, The Royal Orthopaedic Hospital, Birmingham

Metal on metal (MoM) hip resurfacing has provided many patients with a successful outcome with less risk of dislocation and perceived better functional outcome than hip replacement. The metal on metal hip is manufactured from as-cast Cobalt Chrome. It is bone conserving because most of the joint is retained. A low wear metal sphere is shaped to the femoral head and the acetabular socket is fitted with a corresponding metal cup. This is often referred to as a MoM (metal on metal) hip. There are however disadvantages to metal on metal arthroplasties. A recognised complication of metal on metal hip replacement and resurfacing is an ALVAL (Aseptic Lymphocytic vasculitis associated lesion). Patients with hypersensitivity to metal ions which is monitored through blood tests may develop a lymphocyte-mediated response and tissue necrosis in a pseudotumour. We present a guide on what to expect when performing an ultrasound of a MoM hip

- 17. Don't confuse intersection syndrome (proximal and distal) for De Quervain's syndrome,** S McGarry, C Azzopardi, S James, R Botchu, M Davies, C Chisholm, The Royal Orthopaedic Hospital, Birmingham

Intersection syndrome is an overuse disorder of the distal forearm involving inflammatory changes at the crossover or intersection point of Compartments 1 (APL, EPB) and 2 (ECRL, ECRB). Distal intersection syndrome relates to tenosynovitis of the crossover or intersection point of compartments 3 (EPL) and 2 (ECRL, ECRB). It is distinct from intersection syndrome which occurs more proximally. Sometimes clinically misdiagnosed as De Quervain's, ultrasound is an effective form of imaging to diagnose and differentiate between Distal and Proximal Intersection and other inflammatory disorders. We present a guide to scanning and a pictorial view of Intersection Syndrome.

- 18. A mimic for Achilles tendon injuries: Plantaris tendon tears. A DGH experience,** G Constantinescu¹, M Norris¹, K Chettiar¹, K Papakostas¹, S Morgan¹, M Gulati², ¹Darent Valley Hospital, Kent, ²Queen Elizabeth Hospital, London

Background and purpose

Ultrasound examination is the first line investigation for injuries of the Achilles tendon, which can accurately identify complete and partial tears of the tendon. Subsequently, complete tears can be reliably marked for extent and location, as an adjunct for surgery. A small number of cases, with sonographically normal Achilles tendon, but with obvious pain and functional disability, present, in fact, with tears of the Plantaris tendon.

Method

Patients presenting to the Emergency Department or to the Orthopedic Clinic with injuries of the Achilles tendon, were examined sonographically for suspected Achilles tendon tears. Three dedicated MSK Radiologists performed an initial Ultrasound scan evaluation with a view of identifying the eventual tears, quantifying the extent of injury, marking the injured site and assess for additional, synchronous injuries.

Results

Within a year period, twenty-seven patients (n=27) presented with suspected Achilles tendon injuries to the Emergency Department. The cohort examined included twenty-one (n1=21) male patients and six (n2=6) female patients. Three (p=3) patients had normal sonographic appearances of the Achilles tendon, but presented with partial or complete tears of the Plantaris tendon (all male patients). Two patients (p1=2) had complete tears of the Plantaris tendon, whilst one patient (p2=1) had a partial tear.

Conclusion

Plantaris tendon tears (complete or partial) are a challenge for diagnosis, in the clinical setting of suspected Achilles tendon injuries. A sonographically normal Achilles tendon should, in this context, prompt a dedicated search for a Plantaris tendon tear, mimicking Achilles tendon injuries. If doubts persist, correlation with MR scanning is needed.

- 19. Ultrasound guided lumbar facet joint injections as an alternative to fluoroscopic guided injections- preliminary results and perspective,** G Constantinescu¹, S Menon¹, R King², M Gulati³, A Tavakolizadeh², ¹Darent Valley Hospital, Dartford, ²Blackheath Hospital BMI London, ³Queen Elizabeth Hospital, London

Background and purpose

Lumbar facet joint injection is a procedure performed routinely, in many centers, usually under fluoroscopic guidance, for both diagnostic and therapeutic purposes, in patients presenting with low back pain. The purpose of our limited study was to demonstrate the feasibility and advantages of performing this procedure under ultrasound guidance

Methods

Three (n=3) patients were referred to the radiology department of our hospital over a six months' interval for lumbar, therapeutic facet joint injections. Two (n1=2) were male patients and one (n2=1) female patient. The facet joints were deemed to be a pain generator on a clinico-radiological basis. Appropriate consent with risks and benefits explained was obtained. Under ultrasound guidance, local anaesthesia and an aseptic technique, with the patients in prone position, a small amount of a mixture of local anaesthetic and steroid were injected into the lumbar facet joints. Multiple levels were injected bilaterally, at the same setting. Depending on the number of levels injected the procedure requires in between 20 to 30 minutes. The procedure was performed on an outpatients' basis.

Results

All patients reported significant improvement, with no pain- or minimal residual pain at 3-, and respectively 6 months' interval, with no need for a second session of injections. No complications were seen.

Conclusion

Lumbar facet joint injections can be safely performed using ultrasound guidance. The procedure is radiation free, is performed real life and does not require radiographer assistance. It is also associated with a reduced cost and saves radiographers' time.

20. Is it possible to predict the eventual outcome of a Graf Type IIa hip by graphical extrapolation? D Walden, Salisbury NHS Foundation Trust

Introduction

For a Graf Type IIa hip that has not matured to a Graf Type I after two ultrasound scans, assuming a linear progression of maturation, is it possible to predict the eventual outcome by graphical extrapolation?

Objective

The purpose of the study was to investigate whether it is possible to reduce the number of follow up ultrasound scans for monitoring Developmental Dysplasia of the Hip (DDH).

Method

244 infants with high risk factors for DDH referred for hip sonography in a six month period were included in this study. Sonographic examinations were performed using the Graf technique. Both hips were measured and the Graf classification determined.

Results

149 infants had Graf Type I hips at the first scan. 93 infants were referred for a follow up ultrasound scan of which 72 matured to a Graf Type I and 11 were referred for treatment. 10 were referred on for a third scan, of which 9 matured to a Graf Type I and one referred for treatment. The results for the 10 infants that required three scans were used to test graphical extrapolation techniques.

Conclusion

The analysis showed that in general there is a linear maturation of the hip. This means that it is possible to predict the outcome from two scans using graphical extrapolation. In this study, 100% agreement between the extrapolated prediction and the clinical decision was demonstrated when the result from the first and third scan were used. However only 85% agreement was demonstrated when the first and second scans were used. The study shows that it is possible to predict the eventual outcome for a Type IIa hip. The study also shows that the number of follow up scans can be reduce

21. Intramuscular abscess caused by cystercercosis, M Shah, M Mangat, J Pilcher, St George's University Hospitals NHS Foundation Trust

Background

Cystercercosis is uncommon in the UK but endemic in South America, Asia and Africa. Radiologists, especially those working in areas with transient or immigrant populations, should be aware of this infection and the pathognomonic appearances since the infection can have serious complications yet is easily treated.

Cystercercosis can infect tissues throughout the body and ultrasound serves as a useful diagnostic tool.

We present a case of gluteal intramuscular abscess secondary to cystercercosis diagnosed on ultrasound and review its clinical features, imaging appearances and management.

Case Report

A fit and well young Caucasian male presented with a one month history of unilateral buttock pain and swelling. He denied any preceding history of trauma, ill health or medication use. Ultrasound examination demonstrated discrete hypoechoic areas within the subcutaneous fat and surrounding inflammation. A provisional diagnosis of fat necrosis was made. The patient returned 2 weeks later with increasing pain, swelling and now discharge. An urgent ultrasound examination demonstrated a gluteus maximus collection. On careful scrutiny, a cystic lesion with a central hyperechogenic focus was seen within the haematoma (multiple images provided). During the examination the scanning Radiologist established that the patient had recently moved to the UK having lived in India since birth. A diagnosis of cystercercosis complicated by intramuscular abscess was made. The abscess was drained under ultrasound guidance and the infection successfully medically treated.

Discussion

Although a rare cause of muscle abscess, a working knowledge of cystercercosis is important as it can be easily detected and treated. This case reinforces the utility of ultrasound in diagnosing cystercercosis but also illustrates the opportunity for clinicians to make critical diagnoses using information obtained at the bedside.

22. Incidental ultrasonic diagnosis of fractures, R Turney, K Kingston, York Teaching Hospital NHS Foundation Trust

Ultrasound is not the conventional modality employed in the diagnosis of a fracture. However, the ubiquitous use of ultrasound in musculoskeletal evaluation means that detecting a fracture by ultrasound is not an infrequent occurrence. Often they are detected when the scan is performed for persistent pain following injury but occasionally they may be an unexpected finding when assessing a lump or scanning for an effusion in an infant not using a limb.

In our pictorial review we present some of the fractures picked up during general MSK and paediatric lists in our DGH. The most common is a metatarsal stress fracture found during assessment of the joints or for exclusion of Morton's neuroma. Avulsion fracture of the greater tuberosity detected during rotator cuff evaluation is also relatively common. We will include fractures of the ribs, clavicle, avulsion and intra-articular fractures, some of which remain occult on subsequent X-ray. Occasionally the fracture is not well seen on X-ray or ultrasound but sub-periosteal haematoma alerts us to the presence and MRI or CT is used to confirm the diagnosis. We have also used ultrasound to diagnose fracture separation of the non-ossified distal humeral epiphyses in a non-accidental injury case where X-rays were equivocal.

Musculoskeletal ultrasound has wide applications and the high frequency linear transducers used provide excellent spatial resolution and exquisite depiction of the bones, joints and peri-articular soft tissues. Subtle changes in the bone cortex or periosteum can be detected and unexpected or occult fractures diagnosed.

23. An unexpected abdominal wall mass, A Adshead, K Kingston, York Teaching Hospital NHS Foundation Trust

Ultrasound is our modality of choice for patients with and abdominal wall mass lesions. High frequency linear transducers allow the layers of the abdominal wall to be delineated and the location, morphology and imaging characteristics of lesions to be determined. The dynamic examination allows Valsalva manoeuvres to increase intra-abdominal pressure, aiding diagnosis of abdominal wall hernias.

We present a case of a 35 year old lady referred by her GP for evaluation of a recently noticed abdominal wall mass. The lesion was firm, slightly tender and the putative diagnosis was a hernia. The patient was 33 weeks pregnant and the lesion had become noticeable as her girth increased. Initial evaluation was with a high frequency linear transducer as per MSK protocols. The lesion lay just below and to the right of the umbilicus. ultrasound demonstrated divarication of the rectus muscles. The lesion was solid and heterogeneous with minimal internal vascularity. It did not appear to be a hernia nor was it typical for a haematoma. We were pondering other diagnoses when the lesion suddenly shifted position under pressure from the probe. Manual examination showed the lesion to be fairly mobile, easily moved from side to side. On further discussion with the patient she asked whether it could be a fibroid. We changed to curvilinear probe to assess the uterus and although we could not demonstrate a definite connection between the mass and the uterus, the echogenicity was similar to the uterine muscle. Comparison with images from earlier in her pregnancy revealed a large anterior sub-serosal fibroid in the lower uterine segment.

Ultrasound is excellent for assessing abdominal wall lesions, the dynamic examination allows us to adapt and modify the examination and it is helpful to be able to talk to the patient. We will compare images with common abdominal wall lesions.



Physics

- 24. Depth of field and focus position: Impact on subjective image quality in ultrasound,** C Collier¹, S Wolstenhulme², A Culpán¹, ¹The University of Leeds, ²Leeds Teaching Hospital

Objective

Manipulation of scanning parameters allows measurable and subjective improvement of ultrasound image quality (IQ). The aim of this study was to evaluate the relationship between depth of field (DOF) and focus position (FP) on subjective IQ.

Method

Prospective observational study using six 'test' images of anechoic cystic structures obtained by a student practitioner using a single ultrasound machine and linear-array transducer with a tissue mimicking phantom. DOF and FP were manipulated independently with other parameters kept constant. Six experienced sonographers viewed the images in random order with DOF and FP information obscured under standardised conditions and scored IQ using a bespoke criterion based evaluation tool. Criteria included: lateral cyst definition, cyst visibility, discrimination of cysts from surrounding tissue, noise, contrast resolution, potential clinical interpretability and overall IQ. Intra-observer variability was assessed by repeating image analysis 12 days later.

Results

No intra-observer variability was detected. Image 2 (DOF, 12cm; FP, 6cm) rated highest, mean score 22.8/35 (range 14 - 25) although three (50%) sonographers agreed that Image 6 (DOF, 9cm; FP, 6cm) was their 'favourite', mean score 21.8/35 (range 15-25).

Image 4 (DOF, 15 cm; FP, 6 cm) rated lowest, mean score 16.3 (range 11 - 21), with three (50%) sonographers agreeing this was the 'worst' image.

The highest scoring images had FP level with the targets and DOF at the same level or just below the lower target borders. Increasing DOF beyond the target lower borders had a more detrimental effect on subjective IQ scoring than moving the FP.

Conclusion

This bench top study shows how subjective IQ in diagnostic ultrasound might be influenced by optimising depth of field and focal position to the region of interest. Suboptimal manipulation of DOF and FP had the potential to reduce IQ and might increase the chance of misinterpretation and misdiagnosis.

- 25. Monitoring the pulsating brain with Brain TV: Characterising brain tissue displacement and artefacts in recordings from healthy volunteers,** S Venturini¹, C Banahan², K Beach³, M Moehring⁴, A Dewaraja⁴, K Ramnarine², E Chung¹, ¹University of Leicester, ²University Hospitals of Leicester NHS Trust, ³University of Washington, ⁴Broadview Laboratories

Objectives

Healthy brain tissue pulsation, resulting from a periodic 1% expansion of tissue due to the cardiac cycle, remains to be understood and quantified. A novel Transcranial Doppler (TCD) ultrasound technique (Brain TV) is being developed to measure brain tissue displacement. This feasibility study aims to characterise tissue displacement waveforms and evaluate artefacts generated by coughing, blinking, swallowing and yawning.

Methods

TCD and ECG data were acquired simultaneously from volunteers. TCD data were collected from 33 gates (22-86mm depth range) for 8 seconds with the ultrasound transducer positioned at the temporal window and on the forehead. Gates were grouped into six 1 cm blocks of increasing depth. Waveforms were filtered to remove respiration and averaged over the cardiac cycle; data were compared between the two transducer positions, and age groups (<40, >40 yrs).

Results

15 volunteers (6 males, age range 21-68) were recruited. Displacement amplitudes were not statistically different for transducer positions ($p=0.31$, Anova). Amplitudes increased with increasing depth (8.3 μm at 22-30 mm, 18.6 μm at 72-80 mm). Displacements were statistically different between age groups for all 1 cm blocks ($p<0.05$, Anova); the younger group had greater mean displacement amplitude (20.7 \pm 6.4 μm) compared to the older (11.7 \pm 2.6 μm). Coughing, yawning, blinking, and swallowing caused reproducible artefacts across all gates.

Conclusions

The feasibility of measuring brain tissue pulsation from volunteers was demonstrated, and artefacts characterised. Displacement magnitude tended to increase with depth. Displacement amplitudes were higher in younger participants. Further work is underway to compare tissue pulsation and MR imaging to advance waveform characterisation.



Head and Neck

- 26. An audit evaluating the ultrasound assessment of thyroid nodules at North Bristol NHS Trust,** L Frank, R James, H Marsh, S Morgan, Southmead Hospital, Bristol

Background and Aim

The British Thyroid Association guidelines on the Management of Thyroid Cancer (2014) state that all patients with a suspected thyroid nodule should undergo an ultrasound scan in secondary care. They recommend using the U1 – U5 grading system and performing ultrasound guided FNAC on all U3-U5 nodules. This audit aimed to evaluate our practice against the current guidelines.

Methods

All patients who underwent an ultrasound scan of a thyroid nodule between the 1st October 2015 and the 31st December 2015 were included. Electronic patient records were interrogated retrospectively. Patients who had normal ultrasound thyroid appearances or a thyroid abnormality without a discrete nodule were excluded.

Results

Eighty two cases met the inclusion criteria. The median patient age was 53 years (interquartile range: 45-69 years). The U grade was recorded for 45 patients (55%). Thirty were graded U2, 1 graded U2/3, 10 graded U3, 2 graded U3/4 and 2 graded U4. Measurements were given for 30 (67%) of the graded thyroid nodules. Fifteen nodules were graded U3-U5 and ultrasound guided FNAC was performed in 13 cases (87%). All the patients who underwent FNAC were discussed at the thyroid MDT meeting. In 10 patients the initial ultrasound guided FNAC was diagnostic. Two were repeated and 1 patient was referred for surgical review. Final cytology yielded, 9 patients with cytology results suggestive of a follicular neoplasm (Thy 3f) and 1 patient had a malignant cytology result (Thy 5).

Conclusion

55% of thyroid nodules had a U grade recorded. Our unit effectively performs diagnostic ultrasound guided FNAC for U3-U5 nodules. Feedback of these audit results will improve our compliance with the guidelines in the future.

- 27. Are ultrasound 'U' values accurate predictors of malignancy? A retrospective audit evaluating whether ultrasound 'U' values can accurately predict cases of malignancy in thyroid nodules at a DGH,** C Ramsay, NHS Borders,

Background

In 2014 The British Thyroid Association published their 3rd edition of Guidelines for the Management of Thyroid Cancer. In this they include an ultrasound grading criteria which helps determine whether a thyroid nodule requires fine needle aspiration cytology (FNAC). Since this criterion has been implemented in the hospital where the researcher is based there appears to be an increase in the number of FNAC. This audit intends to evaluate the outcomes of the nodules that have undergone FNAC as a result of a U3/4/5 ultrasound grading in order to establish whether the ultrasound criteria are accurately predicting malignant nodules.

Method

The histology outcomes of thyroid nodules that underwent FNAC as a result of their ultrasound grading were evaluated over a one year period.

Results

Of the 321 ultrasound thyroid examinations, 55 nodules had a FNAC as a result of a U3/4/5 grading on ultrasound. Ten were graded U4/5 of which 5 (50%) were found to be malignant and 5 (50%) were benign. The remaining 45 nodules were graded U3. Of these, six (13%) were found to be malignant with 37 (82%) benign. There were two (5%) U3 nodules that remained unresolved at the time of the audit.

Discussion

The percentage of malignant nodules in the U4/5 category was slightly lower than expected but this was primarily due to the small sample. Despite this, the audit outcome supports continuing FNAC of this category. There appeared to be a high number of benign outcomes for the U3 category (82%). Although this is comparable with other studies it questions whether FNAC of this category is justified.

Conclusion

Ultrasound criteria have been shown to be a useful tool for the selection of thyroid nodules requiring FNAC, however further research into the U3 category is warranted in order to keep the number of benign nodules receiving FNAC to a minimum.

28. The role of ultrasound-guided tissue sampling techniques in the management of extra-ocular orbital lesions,
P Touska, A Timmis, J Uddin, J Pilcher, St George's University Hospitals NHS Foundation Trust

Background

Multiple disease processes may arise within the orbit and imaging plays a vital role in the evaluation of such lesions. The orbital contents are readily amenable to evaluation by ultrasonography. Furthermore, the modality can be used to guide tissue sampling (FNA or core biopsy) and may obviate the requirement for invasive surgical biopsy.

Methods

We carried out a retrospective review of ultrasound-guided FNAs/core biopsies of extra-ocular orbital lesions undertaken at our institution. The anatomical locations, sonographic appearances and sampling techniques were analysed.

Results

There were 7 FNAs and 1 core biopsy carried out during the period analysed. Multimodality imaging was available in all cases. The majority of lesions were located in the region of the lacrimal gland. All procedures were well-tolerated and there were no post-procedure complications.

Conclusion

Many extra-ocular, orbital neoplasms are amenable to ultrasound-guided tissue sampling and the procedure is well tolerated. However, a clear understanding of orbital anatomy, differential diagnosis and technique is required to enable safe sampling. Furthermore, a collaborative, multimodality approach is imperative for optimal patient management.

29. Accuracy of using ultrasound alone in the preoperative localisation of parathyroid adenoma prior to minimally invasive parathyroidectomy, A Barnes, R Vaidhyath, University Hospitals of Leicester

Background and purpose

Primary hyperparathyroidism occurs in 1% of the population. Solitary adenoma is the underlying cause in a majority of patients (85%) which has led to a shift from traditional four gland bilateral neck exploration to minimally invasive parathyroidectomy. This approach requires accurate preoperative localisation imaging studies. Imaging protocols includes a combination of ultrasound and Technitium-99M Sestamibi SPECT scanning. More recently 4D CT has also been used as an alternative to traditional imaging. Our institutional imaging protocol is to initially perform ultrasound of the neck. Patients with equivocal or negative results went on to have a Technitium-99M Sestamibi SPECT scan.

The purpose of our study was to evaluate if ultrasound alone can reliably identify parathyroid adenoma prior to minimally invasive parathyroidectomy

Methods

A retrospective review of 46 consecutive patients who underwent minimally invasive parathyroidectomy between 2013-15 based on ultrasound identification of parathyroid adenoma was performed. Surgical cure was defined as normocalcemia at 3 to 6 months follow-up.

Results

Average age of the patients was 61 years with a female to male ratio of 3:1. All patients exhibited elevated parathyroid hormone level median 25.2 pmol/l, range 8.4 – 86.9 pmol/l in the presence of hypercalcaemia: median: 2.88mmol/l :range 2.61-3.32 mmol/l.

Ultrasound identified single adenoma in 42 patients (91%) and multiple adenomas in 4(9%). Post-surgery calcium level measured at 3 to 6 months follow-up was median 2.31mmol/l: range 1.91 - 2.75 mmol/l. The calcium was elevated at 3 to 6 months follow-up in 2 patients. One patient the persistent hypercalcaemia was marginal (2.63 mmol/l) and is under medical management. The other patient had a calcium level of 2.75mmol/l and awaiting bilateral neck exploration pending fitness for surgery.

Conclusions

Ultrasound alone is found to be accurate in the pre-operative localisation of parathyroid adenoma.

30. Case of ultrasound detection of right tonsil squamous cell carcinoma, J Bainbridge, Hull and East Yorkshire NHS Trust

Background

54 year old female who presented to the ENT lump clinic with a history of a 4 month swelling in the right level 2. This swelling was fluctuant. She was experiencing right otalgia and reduced movements of the tongue. Clinical examination of the neck revealed a firm swelling right level 2 and an FNA was performed in the clinic. The patient subsequently went for an ultrasound examination of the neck.

Case report

Ultrasound revealed a suspicious right jugulodiagastric lymph node which was slightly lobulated in outline with a short axis diameter of 14 mm. This was essentially homogeneous in texture and no fatty hilum was demonstrated. There was a small cystic area measuring 7 mm demonstrated within the cortex of this lymph node; this may be as a result of the earlier FNA, however an area of cystic necrosis cannot be excluded. The right tonsil appeared enlarged, irregular and hypoechoic. The left tonsil could not be visualised. No other abnormal lymphadenopathy demonstrated in the neck. Normal appearances of both submandibular parotid glands.

Patient subsequently had the neck re-examined and the right tonsil demonstrated clinical features of squamous cell carcinoma, a biopsy was taken of this and of a suspicious lesion on the right lateral tongue. Patient is awaiting pathology results of the biopsies taken and a MRI scan of the head and neck.

Discussion

Traditionally the tonsils are not examined using ultrasound; however this case shows that abnormalities in this area can be detected when performing a detailed examination of the neck.

Suspicious level 2 lymphadenopathy should raise concerns of a tonsillar or a floor of mouth primary and this area should be examined in close detail.

Quality and Governance

- 31. Ultrasound QA: Maximum return for minimal effort – what you need to know**, N Dudley¹, D Woolley², ¹United Lincolnshire Hospitals NHS Trust, ²Multi-Medix

Background

The Health & Social Care Act and HSE PUWER require that equipment is suitable for purpose, regularly inspected, properly maintained and that risks are assessed and mitigated. The CQC require that health care providers have operational policies and procedures and maintenance budgets to maintain their equipment to be sound, operationally safe and exhibiting only minor deterioration. Quality Assurance forms an essential part of safely managing ultrasound scanners, and is a key element in ensuring compliance with relevant guidance and legislation.

Our aim was to provide evidence supporting the case for regular QA and to show how the majority of faults may be detected using simple methods, with minimal effort.

Methods

We surveyed the literature to find fault detection rates achieved using simple methods. We surveyed the condition of probes on 12 sites in England using these simple methods. Based on the results we recommend a minimum testing regime.

Results

It is possible to detect the majority of faults by frequent visual inspection and a simple uniformity test. Simple, less frequent, phantom tests may detect more subtle faults.

Conclusion

Ultrasound users adopting simple, frequent, tests will detect the majority of scanner and probe faults. This should be part of a formal QA programme to ensure that appropriate records are made and actions taken

- 32. Duty of Care: Impact on healthcare professional's practice within an ultrasound service**, K Langstaff¹, S Wolstenhulme², ¹St James's Hospital, Leeds, ²Leeds Teaching Hospitals NHS Trust

Background and Purpose

In 2013 the Mid Staffordshire NHS Trust Public Inquiry was published. It exposed serious systemic failings in the patient care provided within the Trust between 2005 and 2009. Public World (2013) produced 'The Duty of Care Of Healthcare Professionals' document outlining the concept of a 'duty of care' and how it may conflict with the expectations of employers and the increasing pressure that comes when providing a service where demand far outstrips capacity. It addresses ways to raise concerns if health professionals feel their duty of care is being compromised.

The purpose of the poster is to explore the principles set out within the Duty of Care documents and examines the impact upon non-medical ultrasound practitioner's practice.

Discussion

- Consider the practical advice on the duty of care of healthcare professionals and their employers.
- Consider steps required to help protect patients and staff.
- Evaluate how ultrasound practitioners may be inadvertently in breach of their duty of care.
- The way professional duty of care impacts on an ultrasound service.
- The procedures to follow to raise a duty of care concern.
- Consider the responsibility of the employer to support staff raising issues and concerns about clinical practice
- Appraise the legal protection for employees raising a duty of care concern.

Conclusion

Ultrasound services (employees and employers) continue to develop their practice to improve their Duty of Care. All healthcare professionals are accountable for their own practice.

Obstetrics

33. Failed nuchal translucency audit, S Morrissey, Mid Yorks Hospitals NHS Trust

Introduction

All pregnant patients are offered first trimester combined screening for T21, T18/13. However, anecdotally, all patients requesting screening are not completed. An audit was carried out to identify patients requesting screening but not performed at booked appointment. Audit is a requirement from the QA guidelines recommended by the fetal anomaly screening programme (FASP). Failsafe mechanisms for safe and timely processes

Aims and Objectives:

Identify the number of first trimester screening scans not performed at time of the scan appointment and analyse the reasons for the non-performance.

- Improve the non-performance rate
- Demonstrate learning outcomes
- Disseminate findings to improve pathway
- Ensure all women requesting screening are identified.

Methodology

Retrospective analysis of all patients requesting first trimester screening from 1/4/15-31/3/16 identified using Radiology information system.

Reasons analysed;

- Too early or late for NT measurement - unsure dates or errors by Midwives, sonographers or Appointment Centre.
- Declined test at attendance,
- Miscarriage,
- Twins identified at scan (requires re-counselling)
- Unable to accurately measure NT/CRL due to technical reasons

Results

In the period 1st March 2015 to 31st March 2016 3931 patients had NT scan appointments.

1114(28%) patients did not have an NT scan performed

183(16%) patients declined Downs's screening at attendance, which represents wastage of capacity.

310 patients where NT not measured for technical reasons i.e. patient body habitus preventing adequate visualisation, fetal position.

170 patients attended too late in pregnancy for NT measurement to be performed.

350 patients attended too early in pregnancy for NT measurement to be performed.

A small number of patients could not have NT performed due to miscarriage (65), complex reasons or detection of twins (17) requiring further counselling.

Conclusions

The vast majority of failed NT appointments are out of the control of screening service. Action is taken to reduce numbers of failed NT which screening service can influence.

34. Compliance with image recording standards at the 20 week anomaly scan, C Bullock, R Hennessy, P Cantin, Derriford Hospital, Plymouth

Objectives

- i. Assess compliance of ultrasound image recording standards at the anomaly scan against published standards.
- ii. Introduce interventions to increase compliance, if necessary.
- iii. Re-audit to assess the effect of the interventions.

Methodology

In 2015, 100 anomaly scans were randomly selected and the images were retrospectively reviewed by two auditors. Each auditor assessed whether each of the FASP image recording standards had been fulfilled by comparison against standardised published reference images. Incomplete anomaly scans and multiple pregnancies were excluded.

Interventions were: Discussion of expected standards with staff twice at 6 monthly intervals and placing a poster, depicting reference images, in each room. Re-audit was undertaken after one year. Adherence to expected standards was compared between the two audits (with the exception of 3 new standards introduced in 2016).

Results

The adherence to the HC & Vp, TCD and NF, lips, AC, FL, 4C, RVOFT and total number of images 100% adherent standards all increased in percentages ranging from a 2% increase to 72% increase. The spine image standard remained at 88% compliant and the LVOFT standard reduced in compliance from 78% to 70%. The newly added stomach and bladder, placenta and cord insertion standards for 2016 achieved 80%, 86% to 68% adherence respectively.

Conclusion

There remains room for improvement, but the interventions have resulted in marked improvements of image recording performance during the anomaly scan.



Gynaecology

35. **Pictorial review of ovarian cysts**, L Laver, J Moffatt, Great Western Hospitals NHS Trust

Background

Ovarian cysts are commonly encountered in gynaecological ultrasound, the majority of these are physiological or benign findings and many resolve on repeat ultrasound. For the more complex cysts a classification system is often used to determine the risk of malignancy. Different models of classification include the Risk of Malignancy Index (RMI) index and the Assessment of Different NEoplasias in the adneXa (ADNEX) classification.

Findings

As part of recent research conducted in our institution two sonographers were asked to review ovarian cyst ultrasound images for 100 patients. As part of the research the patient age, histology and CA125 data was also available. This poster aims to provide readers with a pictorial review of commonly found ovarian cysts, both malignant and benign, including serous and mucinous cyst adenomas, fibromas and teratomas. The poster will also incorporate descriptions of each pathology alongside information on CA125 testing and comparison of the RMI and ADNEX classification systems.

Conclusion

The accurate reporting of complex ovarian cysts is valuable in the management of that patient. By increasing sonographer knowledge of common benign and malignant appearances, as well as discussing the classification systems, the patient management pathway may be made more appropriate and consistent.

36. **Transvaginal ultrasound (TVUS): An essential skill for the general radiologist**, M Al-Khoury, K Orr, A Jones, Derriford Hospital, Plymouth

TVUS is a useful diagnostic test, particularly in young women of childbearing age for whom radiation protection is important. Although it is an intimate examination, it is a safe and usually well tolerated test. In some patients, TVUS can avoid the need for CT and the associated radiation burden. The standards for the provision of an ultrasound service issued by the Royal College of Radiologists (RCR) states that both transabdominal and endovaginal approaches are required to fully evaluate suspected gynaecological pathology. The radiology curriculum set by the RCR includes performing abdominal and pelvic ultrasound as a core skill. Despite this, many radiologists do not routinely perform transvaginal ultrasound and therefore the availability of TVUS during some inpatient ultrasound lists and out of hours is variable.

This poster aims to illustrate the usefulness of TVUS as an acute diagnostic tool and argue that it should be a core radiology skill performed by all general radiologists and not a subspecialty examination. We will present a series of patients with acute pathology found on TVUS, some requiring urgent management. We will highlight learning points for these cases. By offering this test in the acute situation we can often answer the clinical question, avoiding the need for further imaging with CT and reducing the risks associated with radiation. We hope to encourage more general radiologists and radiologists in training to increase their exposure to TVUS and embrace it as an essential skill across radiology.

37. **ROCKeTS: Our experience of recruitment to an NIHR Portfolio Trial**, S Robinson, M Roberts, Newcastle Upon Tyne Hospitals

Background

The Newcastle Upon Tyne Hospitals Trust (NUTH) is a recruitment centre onto Phase 3 of the Refining Ovarian Cancer Test Accuracy Scores study (ROCKeTS)(Birmingham University) funded by the National Institute for Health Research (NIHR). ROCKeTS aims to identify more effective ways of detecting ovarian cancers at earlier

stages, to better calculate probability and risk of other ovarian pathologies, therefore minimising intervention and worry to patients with benign pathologies. Study recruits participants with abdominal symptoms and either an abnormal CA125, abnormal ultrasound scan (USS) or both. USS must include a transvaginal approach reported in accordance with the International Ovarian Tumour Analysis (IOTA) classification.

Method

IOTA classification aims to standardise the definition and terms used in the reporting of adnexal masses. To commence recruitment, sonographers, gynaecologists and a nominated radiologist required training and accreditation. A reporting template stored on PACS and all scans quality assured by the lead radiologist. Patients attending the gynaecology Rapid Access Clinic (RAC) were targeted.

Our experiences

Patients referred to RAC due to abnormal CA125 or USS have a repeat scan for clarification and confirmation of findings, it was thought this may increase workload, but adds confidence for referral to Cancer centres. Some recruitment bias has been experienced with benign pathologies as well as scan specific issues such as image anonymisation.

Scans that were reported using the IOTA template were discussed in a feedback session led by the lead gynaecologist and radiologist. Patient outcome, reporting difficulties and classification were reviewed. This cemented good working relationships and offered support, staff morale grew and pending cases are discussed openly with advice sought where required.


Conclusions

We have recruited 72 participants to date, from the ROCKETS target population of 1050 postmenopausal women and 1400 premenopausal women. This study will hopefully go some way towards better detection of ovarian cancers.

38. An unusual case of endometriosis deposits in the urinary bladder diagnosed with transvaginal ultrasound, J Collings, South Devon Healthcare NHS Foundation Trust

The use of high detail transvaginal ultrasound in the subfertile woman is a crucial part of their work up in fertility investigations within the modern gynaecology department. It is essential that new qualified and experienced sonographers are aware of examining the bladder for unusual lesions within the female pelvis and manage their case with appropriate onward referral and treatment. The sooner this occurs the better the chance of improving fertility and symptoms in the female.

This poster presents an unusual case of deeper endometriosis affecting the bladder wall which is rare and the exact cause is unknown. The use of colour Doppler is routine in our department when such lesions are identified and this helps characterise an active nodule requiring biopsy or removal. The penetration of the endometriosis can vary within two forms; superficial endometriosis is found on the outer surface of the bladder and deeper endometriosis is found on the inside of the bladder lining or wall, this can cause a nodule, which can also affect the ureter.



39. The value of 3D imaging in the assessment of abnormal IUD positions during routine transvaginal ultrasound,
R Hirani, R Batool, Northwick Park Hospital, London

Aims/objectives

We present a pictorial review to demonstrate the value of 3D imaging in the assessment of abnormally placed IUDs' including inverted, mal-rotated, penetrating and extruded IUDs'. This review will compare routine 2D transvaginal images with supplementary 3D images acquired using a transvaginal probe with the ability to produce high quality reformatted 3D images in the coronal plane

Background information

Intrauterine devices (IUD's) are one of the most popular methods of contraception worldwide offering effective, reversible long-term contraception. There are well established complications of IUDs including pain particularly after insertion, lost threads and also irregular bleeding. Ultrasound is the main imaging modality of choice in the assessment of IUDs as it is inexpensive, reproducible and does not involve ionizing radiation. The ability to assess the IUD in the coronal plane is critical in evaluation not only the shaft of the IUD but also visualize the two arms and importantly assess any evidence of myometrial penetration.

Methods

We present a number of clinical cases to illustrate the advantage use of 3D images as part of the routine transvaginal ultrasound to demonstrate abnormally placed IUDs

Results

The images clearly illustrate the value of 3D imaging in conjunction with 2D transvaginal ultrasound when assessing the position of IUD's and allows visualization of the entire IUD in all three planes.

Conclusion

Ultrasound has a crucial role in the evaluation of abnormally placed ICDs as we have clearly demonstrated in this pictorial review 3D imaging should be part of the standard scanning protocol of IUDs. It produces high quality imaging in the coronal plane without increasing scanning time using one probe and is essential in the assessment of myometrial penetration without necessitating further imaging.



General Imaging

40. **Overview of Ultrasound Appearances of Lymph Nodes**, C Griffin¹, L Magilton Griffin², ¹Royal Liverpool & Broadgreen University Hospitals NHS Trust, ²Aintree University Hospital NHS Foundation Trust

The main purpose of this abstract is to help clarify the importance of the role of ultrasound (ultrasound) in the assessment of lymph nodes (LNs) throughout the body. The assessment of LNs can be confusing as, depending on the anatomical placement of the nodes in question, the clinical features important in the investigation can vary. This overview aims to show clinical staff the basic features required to fully interrogate and diagnose the LN abnormalities.

The assessment of LNs not only helps in the diagnosis of disease, but also will ultimately aid in the patient's prognosis. The benefits of ultrasound when compared to other imaging methods are the increased spatial resolution of the modality and the ability to allow for ultrasound-guided sampling with either fine needle aspiration (FNA) or core biopsy (CBx).

Normal LN anatomy and the sonographic assessment of LNs including; interrogation of size, shape, hilar architecture, cortical thickness, vascularity and echogenicity will be explored in this presentation. The LN regions to be explored in this overview include: head & neck, axillary, para-aortic and inguinal.

With these details and example images provided, it is hoped that this will help clinical staff in their understanding of ultrasound appearances for both normal and abnormal LNs. This presentation will be a useful aid for clinicians whilst providing images and text to support the sonographic criteria for differential diagnosis of LN appearances and pathology.

41. **The “Typical” lipoma: A cross-discipline overview of the ultrasound appearances**, R Moore¹, C. Griffin¹, L Magilton Griffin², ¹Royal Liverpool & Broadgreen University Hospitals NHS Trust, ²Aintree University Hospital

Background

There is a large crossover of the presentation of the standard “fatty lump” across multiple disciplines within ultrasound practice. These are seen routinely in head & neck, breast, musculoskeletal (MSK) and general medical ultrasound requests. The purpose of this poster is to aid standardisation of the assessment and diagnosis of the benign lipoma.

Method

This presentation will include an overview of the normal ultrasound characteristics of a typical lipoma. These will include; size, shape, location, vascularity and echogenicity in order to help ultrasound practitioners assess these lesions to produce a consistent and structured report. The reporting of a “typical” lipoma is something that should not be taken lightly as there can be multiple complex features and differential diagnoses that also need to be considered. The aim of this poster is to ensure that ultrasound practitioners are aware of the most common benign features so that it is easy to recognise the lesions that require a more specialist review or complimentary imaging.

Results

This poster is a collaboration of highly specialist Ultrasound Advanced Practitioners (of different disciplines), to ensure that all aspects of this common ultrasound finding are reviewed and described in terms that a range of ultrasound practitioners are familiar with.

Conclusion

Whilst a typical lipoma can be a finding on almost any ultrasound list, the assessment and reporting of these benign lesions can vary and a standardised approach can aid in these common but complex lesions.

42. Image Quality: Old versus new, S Wolstenhulme, K Langstaff, St James's Hospital, Leeds**Methods**

One experienced sonographer obtained XX comparable images of the upper abdomen from one adult volunteer, using four different ultrasound machines and a trans-abdominal transducer. The following parameters were manipulated; compound imaging, speckle reduction and frequency. The poster will allow you to review and evaluate the images, which will allow the delegates to determine the impact of these important factors on IQ.

Discussion

Direct comparison of the images produced will show the profound effect modern ultrasound technology has on IQ. After evaluating these images consider in your own department the impact of these parameters on your levels of diagnostic confidence.

Conclusion

21st century medicine requires high resolution ultrasound image quality (IQ) to aid patient diagnostic pathway. This interactive e-poster highlights the difference between aging and new equipment, using a simple experiment to directly compare images from one healthy volunteer. It demonstrates the importance of leading edge technology when undertaking diagnostic imaging.

43. Painless testicular enlargement: A delayed presentation of testicular torsion, R Bradley, Northern Lincolnshire & Goole NHS Foundation Trust**Background**

The acute painful scrotum is a common indication for testicular ultrasound, typically with the request to differentiate testicular torsion from other acute pathology. Ultrasound appearances of testicular torsion can vary widely depending on the time interval between symptom onset and presentation. Here I present the ultrasound appearances of a delayed presentation of testicular torsion following referral with a painless enlarged left testicle.

Case details

A 24 year old male was referred from primary care for scrotal ultrasound with a painless, swollen left testicle. Ultrasound examination showed an enlarged left testis with a heterogeneous internal echotexture. The spermatic cord was twisted with absence of flow within the testicle itself. Imaging appearances were consistent with a testicular torsion.

On direct questioning the patient gave further history of an episode of acute scrotal pain 8 weeks before, which started suddenly when running during a football match. Despite significant discomfort the patient had continued playing, with the pain initially persisting but beginning to subside 48 hours later. Subsequent treatment with oral antibiotics and anti-inflammatories in primary care was associated with further improvement in symptoms.

The ultrasound was reported as consistent with a delayed presentation of testicular torsion but with testicular enlargement rather than atrophy. Following Urological review the decision was made to perform an elective orchidectomy and contralateral orchidopexy. Histological examination confirmed complete infarction of the left testis with fibrosis and myofibroblastic proliferation suggesting long standing infarction.

Learning points

Testicular atrophy in the context of a missed torsion takes time to occur. After testicular infarction, fibrotic enlargement can be misleading and if there is minimal discomfort at presentation, may be suspected to represent testicular tumour. A focused clinical history greatly assists the interpretation of unexpected imaging findings.

Paediatrics

- 44. Whirlpool sign: Ultrasound finding in a neonate with midgut volvulus,** M McCarthy, N O'Donnell, M Stanton, T Herlihy, University College Dublin

Background

This poster discusses a case of midgut volvulus diagnosed on ultrasound after observing the 'whirlpool sign'. A full term 17 day old baby girl presented with projectile bilious vomiting initially immediately to 3-4 hours post feeding and failure to thrive since birth. On examination, her abdomen was soft, non-tender and not distended. An urgent abdominal ultrasound referral was made to assess for signs of intestinal obstruction.

Ultrasound findings

A heterogeneous epigastric volvulus mass consisting of spiralling mesentery and mesenteric vessels was demonstrated on the transverse midline sonographic view of the mid upper abdomen. The superior mesenteric artery (SMA) was located on the right of the superior mesenteric vein (SMV). Visualisation was enhanced by the vascular signal at color Doppler flow demonstrating the peripheral clockwise swirling pattern of the SMV twisted around the SMA giving the 'whirlpool sign'. These ultrasound findings indicated anatomic malrotation due to inversion of mesenteric vessels, whereas torsion of the vein around the artery (whirlpool) could be observed in midgut volvulus. The close apposition of the SMA and SMV with opposing multidirectional flow indicated that the whirlpool contained the SMV and its tributaries but also branches of the SMA. Patient prognosis for midgut volvulus depends on timely identification and surgical treatment of midgut malrotation and volvulus before necrosis occurs. The neonate underwent successful Ladd's procedure.

Conclusion

The diagnostic value of the 'whirlpool sign' in detecting midgut volvulus was significant in this case. It played a crucial role in the early diagnosis and prompt surgical management. This poster proposes that colour Doppler ultrasonography is the principal modality for the diagnosis of midgut volvulus, especially for the newborn, for whom the available diagnostic tests are limited.

- 45. Neonatal respiratory distress syndrome diagnosis: Chest X-Ray or lung ultrasound?,** M Hiles¹, C Watts², S Wolstenhulme³, ¹University of Leeds, ²Hull and East Yorkshire NHS Trust, ³Leeds Teaching Hospitals NHS Trust

Objectives

Neonatal respiratory distress syndrome (NRDS) is a leading cause of morbidity and mortality among preterm new-borns. The diagnostic reference standard involves clinical testing and chest X-Ray (CXR) with associated exposure to ionising radiation. The aim of this systematic review was to summarise evidence from primary research to assess in symptomatic neonates >42 weeks gestational age with suspected NRDS, what the diagnostic accuracy of lung ultrasound (LUS) is compared to CXR against the reference standard.

Methods

A systematic literature search of OVID Embase 1996-2015, OVID Medline (R) 1996-2015, PUBMED 1996-2015, Science Direct 1995-2015, Leeds University Library's Journals/Books@OVID(full-text),CINAHL 1990-2016 and The Cochrane Library 2005-2015 identified 804 studies. Six studies were retrieved for further analysis and were assessed for quality before data extraction.

Results

Four prospective cohort studies and two case control studies which included 480 neonates were found to be of a moderate methodological quality although heterogeneity was evident across the studies. The sensitivity and specificity of LUS was 97% (95% confidence interval [CI] 94%-0.99%) and 91% (CI: 86%-95%) respectively. Sixteen false positive results were identified; these included eight cases of pneumonia, three transient tachypnea, one pneumothorax and one case of meconium aspiration syndrome. Three of the sixteen false positives and seven of the nine false negatives identified were insufficiently reported and the eventual diagnoses are unknown. The remaining two false negatives were diagnosed as partial pneumothorax, which can be a complication of NRDS along with other air-leak syndromes.

Conclusions

LUS was found to be highly sensitive for the detection of NRDS. Its sensitivity for diagnosing air-leak syndromes, which often co-exist with NRDS, is incompletely understood. LUS cannot replace CXR entirely, although the evidence supports LUS screening in order to rule out the disease and poses the possibility of a follow-up role to monitor on-going treatment.

- 46. Cranial ultrasound giving us the “Heads Up” in neonatal bacterial meningitis,** E O’Driscoll^{1,2}, R Fitzgerald¹, T Herlihy², M Stanton², ¹Our Lady’s Children Hospital Crumlin, Dublin, ²University College Dublin

Background

Neonatal bacterial meningitis (NBM) can be debilitating even life threatening, with favourable patient outcomes relying heavily upon prompt diagnosis and early treatment. Antibiotics have revolutionised the successful treatment of NBM however neuroimaging, has greatly enhanced its non-invasive diagnosis. In neonates ultrasound remains the first line examination given its portability, absence of ionising radiation and as a technique it is also typically accepted by the child’s parents.

Ultrasound Findings

Due to its high spatial and temporal resolution, cranial ultrasound is the initial choice for detecting NBM and its complications. In the neonate, ultrasound through the anterior fontanelle plays a key role in demonstrating ventriculitis, meningeal thickening and empyema. In the case presented, ultrasound demonstrated echogenic ventricular margins, representative of ventriculitis and meningeal thickening. It also revealed debris within bilateral extra dural collections consistent with empyema.

Discussion

NICE state that diagnosis of NBM can be difficult owing to its salient clinical and radiological features. The diagnosis is further complicated in patients in whom LP is contraindicated. These dilemmas reinforce why ultrasound should be used as a routine diagnostic tool to eliminate misdiagnosis of a covert presentation of NBM. Advancements in ultrasound have allowed it to, even rival CT and MRI. This poster presents a visual representation of the sonographic findings of NBM that were not detectable on CT. As the ultrasound appearances were so suspicious for NBM the patient was immediately commenced on antibiotics for 21d and made a full recovery.

Conclusion

Success rates in treating NBM in the early stages of its onset, justifies the need for good imaging that can lead to an accurate early diagnosis. With the quality of imaging we can provide with high resolution ultrasound we should be able to avoid lifelong neurodevelopmental sequelae for the neonate.

- 47. Ultrasound of the acutely unwell child: A guide to on-call scanning,** C Miller, T Kalami, Leeds Teaching Hospitals Trust

Background

Children aren’t small adults; they are affected by different pathologies and are often unable to convey their symptoms. Understanding the relevance of clinical signs in different conditions and utilising appropriate investigations is necessary for prompt diagnosis and management of acutely unwell children. Ultrasound is a key tool in paediatrics enabling radiation free imaging with superior resolution to CT in children.

Learning Objectives

Scanning acutely unwell children is a core skill for radiology trainees and general sonographers as children often present out of hours when a paediatric radiologist or sonographer are unavailable. Therefore it is necessary to recognise when imaging should be performed, and be able to perform and interpret paediatric ultrasound in several important conditions.

Content

The ultrasound findings of six paediatric conditions; pyloric stenosis, posterior urethral valves, intestinal malrotation with midgut volvulus, intussusception, septic arthritis and appendicitis - are presented in a pictorial poster. In addition the ultrasound technique, overview of clinical signs and symptoms, disease pathogenesis, further investigations performed and subsequent management of each condition are discussed and illustrated to provide an all encompassing educational guide.

- 48. Rhabdomyosarcoma: A cheeky thing,** K Foley-Friel¹, R Fitzgerald¹, M Stanton², T Herlihy², ¹Our Lady's Children Hospital, Crumlin, ²University College Dublin

Background

Rhabdomyosarcoma (RMS) is a soft tissue sarcoma arising from immature striated skeletal muscle. It is the most common soft tissue sarcoma seen in children. A 3-year-old male presented to the emergency department with unilateral facial swelling on his cheek for approximately 6 weeks. The patient was referred for a soft tissue ultrasound (ultrasound) which revealed a well defined mass in the masseter muscle.

Case Report

Ultrasonography of the cheek confirmed a 1.8 x 1.5 x 1.1 cm solid appearing mass located in the right masseter muscle overlying the right angle of mandible. The mass appeared hypoechoic with areas of increased echogenicity suspicious of necrosis. The borders of the mass were well defined. Power Doppler revealed internal vascularity and bilateral cervical lymphadenopathy was also evident. As a result of the ultrasound appearances and clinical history, a fine needle aspiration biopsy was recommended.

Discussion

Ultrasound is the first imaging modality used in children and offers high resolution. A study performed by Chandak et al (2011) stated ultrasound had a sensitivity of 100% and a specificity of 98% for diagnosing malignant neoplasms of the head and neck. The sonographic appearances of the mass have a number of differential diagnoses including neuroblastoma, ewings sarcoma, neuroectodermal tumour and lymphoma. For this patient, the sonographic appearances favored a malignant mass. The location of the mass accompanied with patient demographics increased the suspicion of malignancy. Ultrasound findings vary with RMS. Indicative ultrasound features exhibited in this patient included: a solid rounded hypoechoic mass, necrosis and neoangiogenesis. A painless fixed mass that is rapidly growing for several weeks is potentially malignant. The results of imaging might strongly suggest RMS. However, histology tests are the most reliable method of diagnosis. In this case histology confirmed that the mass was a masseter embryonal rhabdomyosarcoma.

- 49. Clinical audit of paediatric patients undergoing contrast enhanced ultrasound for indeterminate liver lesions,** M Taylor-Allkins¹, N Brown², ¹Great Ormond Street, ²University of Hertfordshire

Presentation of an audit submitted as part of an MSc in ultrasound for the University of Hertfordshire. Data was amalgamated from two centres; GOSH & Kings College.

Background

Liver lesions are common accounting for 6% of intraabdominal lesions in paediatrics and although a small figure, 2 out of 3 will be malignant requiring timely diagnosis essential for management. Contrast-enhanced ultrasound (CEUS) can provide immediate results which are fundamental in patient pathways to diagnose indeterminate lesions and increase diagnostic accuracy, with high sensitivity and specificity rates bringing ultrasound in line with cross-sectional imaging. Micro-bubble technology remains off license in paediatrics; however despite this centres worldwide are adopting the technique as an initial investigation. With high safety profiles, lack of radiation and potential for a wide range of application, coupled with reported accuracy rates and the dynamic component, CEUS will become a favorable addition to imaging services.

Objective

To evaluate if CEUS is sufficient in providing a definitive diagnosis for indeterminate liver lesions and assess the number of patients requiring additional examinations for characterisation of inconclusive lesions.

Materials and methods

Retrospective audit of paediatric CEUS services over an 8 year period from two sites.

Results

Of 108 patients, 97 (89.8%) received a diagnosis with CEUS, 92 were definitive and 5 required additional imaging for confirmation of initial CEUS diagnosis. Alternative examinations (CT, MRI and biopsy) were required for 11 patients (10.2%) as CEUS failed to characterise lesions. 1 patient received an incorrect diagnosis with CEUS, identified on MRI.

Table of breakdown of individual diagnosis to be included with a graph of distribution of examinations.

Conclusions

The study suggests CEUS is effective in diagnosis of indeterminate liver lesions; however more knowledge of microbubble uptake characteristics for certain pathologies are required to enhance the techniques sensitivity. Recommendations for future research.

50. **Paediatric Ultrasound in a District General Hospital: The need for the local expert**, G Chambers, J Cooper, A Murphy, York Teaching Hospital NHS Foundation Trust

With an ever-increasing demand made on tertiary paediatric services, paediatric ultrasound expertise with a broad knowledge base is vital in District General Hospitals (DGH.) Tertiary clinical specialists are performing more outreach clinics.

Pathologies that are seen regularly in specialist paediatric centres may only be seen once a year (or much less frequently) in these more peripheral sites. This requires a different approach and knowledge base to paediatric imaging that goes beyond technical competency.

It follows that the role of a paediatric radiologist assisted by the sonographer in a DGH does not stop at knowing when to make urgent referrals, which require specialist surgical or medical input. In addition they are required to identify cases where local management, with or without tertiary consultation, is sufficient, thus reducing the anxiety of the patient, their carers and the clinical team.

In a time when service pressures are great, the ability to triage patients who need urgent referral from those who can be discharged, or treated locally, is paramount. This work will provide a short series of cases encountered over a 3 month paediatric radiology attachment, which highlight varying management options from reassurance to specialist referral and follow-up imaging. This aims to give radiology and sonographer trainees some examples of the scope of conditions that may be encountered in DGHs and a learning outcome from each case pertaining to the likely treatment pathway.

51. **Ultrasound in the assessment of paediatric musculoskeletal injuries**, R Turney, K Kingston, York Teaching Hospital NHS Foundation Trust

In paediatric musculoskeletal trauma ultrasound is of most use in the sub-acute setting. We are often asked to assess patients with persistent pain, swelling or loss of function. ultrasound is well tolerated by children, is quick, non-invasive with no need for sedation or general anaesthetic. The dynamic nature of the examination allows discussion of the mechanism of injury and observation of active and passive movement of joints, ligaments and muscle-tendon complexes.

The purpose of this pictorial review is to discuss injuries more common in children. We shall describe the muscle-tendon-bone complex and changes that occur with increasing skeletal maturity and how this affects the type of injury encountered. Discussing acute and chronic traction apophyseal injuries, muscle tears and tendon abnormalities. We will include other paediatric specific injuries involving the physeal plate, epiphysis and other non ossified structures. Unusual cases such as pseudoaneurysm of the temporal artery, tendon injury from deeply penetrating splinter and fat fracture after being bitten by a horse will also be included.

ultrasound assessment of musculoskeletal injuries allows us to ascertain the anatomical structures involved and the severity of the injury. Movement of joints and tendons allows dynamic assessment of their function. The radiologist is well placed to guide the referrer towards the most appropriate future management of the patient be it reassurance, conservative management, more complex imaging investigation or surgical intervention.

Other

52. **Educating undergraduate radiotherapy students in the role of ultrasound in cancer treatment**, C Williams, K Barton, A Williams, University of Portsmouth

Technological advances are rapidly transforming cancer treatment and the role of ultrasound is gaining momentum in image guided radiotherapy (IGRT), targeted drug delivery and tumour ablation. To date, the role of ultrasound in cancer treatment within the UK has focused on IGRT for prostate cancer, the aim of which is to minimise inter-fractional variation in tumour position caused by altered bladder, bowel and tumour volume. This ensures adequate dose to the tumour whilst limiting dose to surrounding organs. Previously, cone-beam CT has been the preferred modality for this function, however, ultrasound has a number advantages over this modality as it is portable, relatively low in cost and has no concomitant dose. As a result, its role is now extending beyond the prostate to include IGRT applications for cervix and breast and research is currently taking place to determine its potential role in intra-fractional radiotherapy.

As ultrasound for IGRT remains in its infancy, these developments pose an interesting training challenge for service providers and higher education institutions. Currently there is a lack of appropriately trained staff within departments, which is compounded by the fact that training in ultrasound applications is not a specific requirement listed in the Standards of Proficiency for radiotherapists (HCPC, 2013). At the University of Portsmouth we recognised this issue and in collaboration with The Institute of Cancer Research, designed and delivered a one-day ultrasound workshop to introduce the growing role of ultrasound in cancer treatment to our final year undergraduate radiotherapy students. The aim was to provide them with a unique foundation in this relatively new area of practice and aid their future career development in a continually evolving profession. This poster provides a summary of the workshop and evaluates the student experience, as a means of piloting dedicated training in this area.

53. **Ultrasound in testicular trauma: Everything you need to know**, P Jarvis¹, K Orr¹, S Freeman², ¹Peninsula Radiology Academy, ²Plymouth Hospitals NHS Trust

Testicular trauma is relatively uncommon but when it does occur there can be significant consequences, sometimes resulting in loss of the testis. Therefore, a quick and accurate diagnosis is essential for guiding management and optimising outcome. Testicular injuries are most common in children and young adults, the majority of which occur during sporting activities.

Ultrasound is the primary imaging modality for evaluation of the scrotum and testes, especially in the context of trauma when pain and oedema often limit clinical examination. It is a safe and relatively simple test to perform. Despite this, performing scrotal ultrasound can cause anxiety for those with little prior experience and this is heightened in the high stakes scenario of testicular trauma presenting out of hours.

Possible testicular injuries range from small haematocoeles or haematomas that can be managed conservatively to testicular rupture, which requires urgent surgical intervention. A ruptured testis can be salvaged in more than 80% of cases if surgical repair is performed within 72 hours. Ultrasound is an excellent modality for demonstrating this pathology with a sensitivity of up to 100% and specificity of 65%. Scrotal ultrasound is therefore a vital tool for anyone performing acute ultrasound in order to direct appropriate surgical management.

The aim of this poster is to increase ultrasound practitioners' confidence in the assessment of testicular trauma. We will provide a systematic approach to testicular ultrasound, highlighting areas of particular importance in trauma. We will present a range of cases of testicular trauma with a description of the ultrasound findings. Finally, we will discuss important considerations in the ongoing management of these patients with an emphasis on findings requiring urgent surgical intervention.

54. Benign and Malignant Ultrasound Features of Breast Lesions, L Magilton Griffin¹, C Griffin², ¹Aintree University Hospitals, ²Royal Liverpool & Broadgreen University Hospitals NHS Trust

Background/Purpose

The purpose of this poster is to highlight the importance of differentiating between benign and malignant breast lesions. This is the fundamental task of breast ultrasound and this will be explored in this poster. This is aimed at trainees in breast ultrasound imaging and as a reference tool for qualified practitioners.

Methods Used

There are several diagnostic features that are used in the assessment of breast lesions including: shape, margin contour, internal reflectivity, through transmission, width-depth ration, mobility and compressibility. This poster will use example images and easy to follow tables to highlight the differences between benign and malignant lesions.

Results

The resulting knowledge from this poster will aid in the diagnosis, decision for ultrasound-guided sampling, treatment and ultimately the prognosis of breast lesions.

Conclusions

Pictorial based posters as teaching aids and reference guides are ideal to help act as a reminder for both trainees and the most experiences clinical practitioners to provide the best quality imaging and reports in the assessment of benign and malignant lesions.

55. Choosing the appropriate prospective trainee ultrasound advanced practitioner candidate: A holistic approach, C Griffin, Royal Liverpool & Broadgreen University Hospitals NHS Trust

Introduction

Due to the national shortage in advanced practitioners in ultrasound, and the funding issues affecting the NHS today, it is important that the correct candidate is selected for advanced practitioner training posts. Staff retention is also an issue that needs to be addressed as NHS trusts and the private sector can offer more competitive jobs and salaries in order to both recruit and retain staff. ultrasound is an ever growing modality with multiple clinical applications. Therefore future prospects of this modality are potentially endless as technology progresses.

Methods

Our centre's assessment process includes the grading of a candidate's personal statement of interest, an academic assessment via a written assignment (marked at Masters Level), a practical ability review during a clinical assessment day and final assessment during a formal interview panel. The grading of candidates occurs with the use of a customised Likert scale model to assess multiple predetermined characteristics and topics to ensure that the candidate possesses the essential skills and personality required for a career as an advanced practitioner in ultrasound.

Discussion

The appointment of staff on the basis of a single panel interview basis is not always appropriate, especially in healthcare, as multiple aspects of candidate's personality and character is required. The roles, responsibilities and attitude of advanced practitioner radiographers/sonographers are a fundamental function of their role, and must be carefully vetted and prepared prior to commencement of the job to ensure the best possible standard of practice and care for our patients and other service users.

Conclusion

This model allows for a holistic and systematic approach to assessing potential candidates' professional attitude and practical and academic aptitude. Applications and adaptations of this model are possible in all aspects of radiography and other allied health professional groups, with further potential in nursing, midwifery and medicine.

Vascular

- 56. A Strong Arm Leads To A Weak Point: The role of ultrasound in the diagnosis of Upper Extremity Deep Vein Thrombosis,** K Cronin^{1,2}, A Kelly², M Stanton¹, T Herlihy¹, ¹University College Dublin, ²St. Vincent's University Hospital, Dublin

Background

Paget-Schroetter syndrome is the spontaneous thrombosis of the axillary/subclavian vein. It is a rare disorder (2 per 100,000 persons per year). It occurs predominately in young, otherwise healthy and fit people who participate in repetitive upper extremity activity. The underlying mechanisms of such thrombosis are thought to be a venous compressive anomaly at the thoracic outlet or intimal damage due to a strain at the subclavian and axillary veins by retroversion or hyperabduction. Typical movements like this occur during sporting activities such as rowing, stick and racket sports or weight-lifting. In this case the patient, a 17 year old female who frequented the gym on a regular basis for weight lifting activities presented to the Emergency Department with a 3 day history of severe arm swelling. The patient had no history of trauma, was currently on no medication and had a negative history of venous thrombosis.

Ultrasound Findings

Colour Doppler ultrasound is a rapid, accurate, and non-invasive technique used in the evaluation of upper extremity deep vein thrombosis. Depending where the thrombus forms may require the sonographer to manipulate the arm and reproduce vascular compromise. In this case study, when the subclavian vein was augmented stasis was noted rather than an occluded vessel. The stasis prompted an examination of the vessel proximally. The sonographer asked the patient to elevate their arm resulting in thrombus moving from beneath the clavicle.

B-mode ultrasound illustrated a rouleaux formation indicating slow flow within the subclavian vein. When colour Doppler ultrasound was utilized it highlighted stasis rather than occlusion within the vessel. Once the patient elevated her arm, under B mode ultrasound, a fresh clot was seen moving from beneath the clavicle.

Discussion

Paget-Schroetter syndrome is rare venous condition. However it has potential for significant morbidity and can cause a potentially fatal complication. Timely, accurate clinical recognition of the signs and symptoms is crucial to facilitate an appropriate medical referral and treatment. Duplex ultrasound is the leading imaging tool in diagnosing and monitoring venous disease in the upper extremity and a skilled sonographer can play a vital role in the rapid diagnosis of Paget-Schroetter syndrome.



Have you renewed your membership yet?

You can now pay your membership fee quarterly, using Direct Debit, starting as low as £21.75!

Journal Ultrasound
read about publish your ultrasound research

Ultrapost & BMUS News
newsletters providing society and ultrasound news

Professional Guidance
access to professional guidance documents prepared by industry experts



Study days & conference
reduced registration fees for attending our BMUS events

EFSUMB and WFUMB
reduced registration fees for EFSUMB and WFUMB events

CPD Online
our members can gain CPD points using our online CPD portal

Membership Rates for 2016 - 2017*



Sonographer - £87.00
Student - £33.00
Consultant/GP - £112.00



Overseas Member - £130.00
Retired/Unwaged - £65.00
Vascular/Scientist - £75.00



European Member - £92.25
Superintendent - £99.75
Radiologist - £112.00

**Rates apply only for members opting for Direct Debit*

Submit or Renew Your Membership Application Online

to ensure hassle free payment process and enjoy an uninterrupted membership

Exhibitor Profile

▶ **HITACHI MEDICAL SYSTEMS** **The Front Runner at York Racecourse!**

HITACHI
Inspire the Next

Stand 1

Expanding their impressive range of diagnostic ultrasound systems, Hitachi introduce the latest ARIETTA Prologue at BMUS ASM 2016; a unique hand-carried portable ultrasound system that has received exceptional reports from the ultrasound community for POC and MSK examinations. With wireless communication and a highly compact design, the Prologue delivers superior imaging quality and advanced diagnostics complementing Hitachi's extensive ultrasound portfolio. Elastography including shear wave technology, fusion imaging and contrast together with ergonomically centric designs deliver premium ultrasound across all applications. Discover your system on Hitachi Booth 1.

Hitachi Medical Systems proudly sponsoring BMUS ASM 2016.

Find out more at : www.hitachi-medical-systems.co.uk | 0844 800 4294

▶ **TOSHIBA MEDICAL SYSTEMS LTD**

TOSHIBA
Leading Innovation >>>

Stand 2

For radiology professionals seeking clinical excellence and operational efficiency, we offer an unbeatable combination of high quality MR, CT, XR and ultrasound scanners with the UK's most responsive and reliable support. Using a combination of technology and flexibility, Toshiba Medical Systems works with together with customers to provide solutions relating to the increase challenges that the NHS face each day.

Come and visit us at BMUS this year on stand number 2 where we will be launching a brand new system which is the most intuitive, intelligent and innovative ultrasound scanner on the market. Our experienced Toshiba representatives will be happy to talk to you

Visit www.toshiba-medical.eu/uk/bmus

▶ **MIS HEALTH CARE**



Stand 3

As the newest entrant into medical imaging, Samsung has rapidly integrated its world leading IT, image processing, semiconductor and communication technologies into a growing range of advanced high performance diagnostic ultrasound systems that are increasingly acclaimed by leading experts. Samsung's speed of innovation, delivered by MIS Quality Services, helps medical professionals deliver great healthcare to their patients.

Please visit : www.mishealthcare.co.uk

GE Healthcare



▶ GE HEALTHCARE

Stand 4

GE Healthcare is pleased to welcome delegates to this year's BMUS Annual Scientific Meeting.

GE Healthcare provides transformation medical technologies and services to meet the demand for increased access, enhanced quality and more affordable healthcare around the world. From medical imaging, software & IT, patient monitoring and diagnostics to drug discovery, biopharmaceutical manufacturing technologies and performance improvement solutions, GE Healthcare helps medical professionals deliver great healthcare to their patients.

Please visit : www3.gehealthcare.co.uk/en-gb/products/categories/ultrasound#

▶ CARESTREAM

Carestream

Stand 5

On Stand 5 Carestream will demonstrate the Touch Ultrasound platforms that offer features designed to address current challenges in sonography.

The Touch Ultrasound platform's design is based upon recommendations by sonographers and ultrasound professionals across the world. The CARESTREAM Touch Prime Ultrasound System and the CARESTREAM Touch Prime XE Ultrasound System are both premium systems designed for general diagnostic imaging use in radiology, OB/GYN, musculoskeletal and vascular applications. Carestream's new ultrasound systems have earned praise for an all-touch control panel and expanded capabilities.

Carestream is a worldwide provider of dental and medical imaging systems and IT solutions.

Please visit : www.carestream.com/touch



▶ BK ULTRASOUND



Stand 6

The BK name has a proud history and a reputation as an innovator in procedure-driven ultrasound.

Our newly launched bk3500 and the award-winning flex Focus™ systems have changed expectations for small footprint, extremely manoeuvrable, premium performance systems. The bk3500 systems uses technology developed for gaming, so that image processing is now done using GPU's, instead of the conventional CPU used in the past; this gives improved image quality at all depths and quicker frame rates.

We are a leading provider of real-time image guidance in urology and surgery. The new systems are uniquely suited for many surgical applications, and our groundbreaking Quantum Technology™ takes our premium image quality to a level that meets the clinical needs of other markets such as interventional ultrasound, general imaging and point-of-care applications.

Please visit : www.bkultrasound.com

▶ ESAOTE



Stand 7-8

The Esaote Group is a leading player in the biomedical equipment sector, with a particular focus on ultrasound, dedicated magnetic resonance, and software for managing the diagnostic process. Esaote has over 1,335 employees, 19% of which are employed in R&D activities and it has industrial and research and development units in Italy, the Netherlands and China. Esaote is internationally recognised as one of the "Top Ten" diagnostic imaging companies in the world and enjoys the co-operation of worldwide scientific and clinical research centres and universities. Within the UK Esaote has a team of people dedicated to providing the highest levels of service and support to all its customers.

Please visit : www.esaote.com/en-GB/

▶ SIEMENS HEALTHINEERS



Stand 9-12

Siemens Healthineers enables healthcare providers around the world to meet their current challenges and to excel in their respective environments. A leader in medical technology, Siemens Healthineers is constantly innovating its portfolio of products and services in both its core areas in imaging for diagnostic and therapeutic purposes as well as in laboratory diagnostics and molecular medicine. With Siemens pioneering ultrasound technologies, your patients can depend on you to provide accurate diagnoses and help them to make the best decisions for their care.

For further information please visit www.siemens.co.uk/ultrasound

► MINDRAY



Stand 13

Mindray is a leading global provider of medical devices and imaging solutions. Our mission is to “Share Medical Technologies with the World” and we are dedicated to innovation in Medical Imaging Systems – including Ultrasound, X-ray and MRI. We also lead with Patient Monitoring & Life Support systems and In-Vitro Diagnostics.

Headquartered in Shenzhen, China with 10,000 employees worldwide Mindray runs global sales, marketing, R&D and Service networks through 42 subsidiaries and branch offices in 32 countries across North and Latin America, Europe, Africa and Asia-Pacific, as well as 32 branch offices in China.

We are proud to launch Resona 7 to the UK market at BMUS 2016

Resona 7 is our Premium flagship model of the Resona Series and marks an important step forward “ Leading new Waves in Ultrasound Innovation.”

Powered by our revolutionary ZONE Sonography® Technology, Resona 7’s new ZST+ platform gives Practitioners far higher image quality with zone acquisition and channel data processing. Resona 7 also provides useful tools for clinical research, such as V Flow for vascular haemodynamic evaluations.

We will also have a great line up of hand carried and cart based systems including :-

- **TE7** **Tablet system for Point of Care**
- **M9** **Laptop system for Point of Care, MSK and Cardio-Vascular**
- **DC Series** **Cart-based compact systems**

We look forward to welcoming you on Stand No: 13 to discuss solutions for your imaging needs.

Contact details: Mindray UK Limited, Mindray House, Kingfisher Way, Hinchingsbrooke Business Park, Huntingdon, Cambs, PE29 6FN
Tel: 01480 416840 | Fax: 01480 436588

Email: ukcustomerservice@mindray.com | Website: www.mindray.com

► TICCS ULTRASOUND SERVICES



Stand 14

TICCS Ultrasound Services is a leading independent provider of ultrasound services to various CCGs, hospitals and private partners across England. Celebrating its 10th anniversary of provision this year, TICCS Ultrasound provides a Consultant led ultrasound service with a robust clinical framework to support all of our clinicians and respond to clinical queries from referrers.

An In-house MSK PG Cert is available for our senior experienced Sonographers to ensure that TICCS continues to deliver on its vision and strive to be the best ultrasound provider to work for, bar none.

Contact TICCS Ultrasound via Phone: 0845 490 3176 and Email: ultrasoundinfo@ticcs.co.uk

▶ **INHEALTH**



Stand 15

InHealth is a leading independent provider of managed diagnostic services and healthcare solutions to the NHS and the independent sector. InHealth has worked collaboratively with Trusts & CCGs across the UK for many years, delivering a portfolio of MRI/CT, PET-CT, DXA, ultrasound, mammography, X-ray, endoscopy, audiology and interventional cardiology from 350 mobile and static sites to over 1 million patients each year. InHealth is committed to improving accessibility, affordability and speed of diagnosis, whilst always delivering excellence in patient care.

Please visit : www.inhealthgroup.com

▶ **TRISTEL SOLUTIONS LTD**



Stand 16

Tristel is a manufacturer of infection prevention and contaminating control products. Its lead technology is a chlorine dioxide formulation, which has been a ground-breaking innovation in the world of Infection Control. Please visit Tristel at stand 16 to find out about Tristel products particularly suitable for Ultrasound.

Please visit : www.tristel.com

▶ **THE COLLEGE OF RADIOGRAPHERS**



Stand 17

The College of Radiographers is committed to developing and promoting the science and practice of medical imaging and radiation therapy. We put the unified voice of sonographers in the UK to good effect in developing and promoting policy on current and emerging educational, professional and workforce issues related to sonography.

A major feature of our educational work recently has been the development of e-LfH learning units for obstetric and non-obstetric ultrasound – come and see these excellent resources on our stand. The College of Radiographers has also been working with Health Education England and other stakeholders to try and resolve the current shortage of sonographers.

We welcome visitors to our stand where representatives will be on hand to discuss a wide range of topics, including regulation, workforce shortages and development, work-related injuries, continuing professional development, etc. So, please visit us – members and non-members are all very welcome.

Please visit : www.sor.org

▶ ROTHBAND



Stand 18

Rothband have been a leading supplier of equipment to healthcare professionals since 1860.

During that time, there have been many innovations, developments and partnerships that have helped us grow and forge our credibility as a provider to medical imaging departments.

At BMUS 2016, we are proud to announce our latest partnership, with Konica Minolta. This new relationship will allow us to continue building our diagnostic equipment portfolio by bringing the latest, cutting edge ultrasound technology to the UK marketplace.

Healthcare is changing. Providers are challenged to do more with less. Konica Minolta Sonimage HS-1 answers these needs with solutions that deliver economic value, clinical confidence, and worry-free operation. With SONIMAGE HS1's Best-in-Class Image Quality, clinicians can visualise structures as small as several hundred microns, making it ideal for detailed tissue visualisation and differentiation that increases clinical confidence and productivity.

Please visit : www.rothband.com

▶ MEDAPHOR



Stand 19

MedaPhor is a global provider of advanced ultrasound skills training simulators for medical professionals. Founded in 2004, the Company is headquartered in Cardiff, UK and San Diego, USA, with customers in over 16 countries across the world. MedaPhor offers some of the world's leading ultrasound education platforms which include:

ScanTrainer, an ultrasound skills training simulators and CPD platform offering an immersive, 24/7 self-learning experience for doctors and sonographers.

HeartWorks, a simulator and online training platform to help teach medical practitioners Transthoracic and Transoesophageal echocardiography.

ScanTrainer Examine, an ultrasound skills examination simulator designed for hospitals and examination bodies to test a medical professional's ultrasound skills.

Please visit : www.medaphor.com



▶ PHILIPS HEALTHCARE

PHILIPS

Stand 20-21

Philips has been at the forefront of innovation in ultrasound for more than 30 years. Today, we continue to advance ultrasound through a unique combination of high-quality images and clinical information. Helping clinicians achieve first time right diagnosis, every time, and in less time. Even in the most difficult cases. Exactly what you'd expect from the UK's most preferred ultrasound provider*.

*IPSOS Survey - of 244 healthcare professionals sampled, 36% said they preferred Philips over other leading competitors.

Please visit : www.philips.co.uk/healthcare/solutions/ultrasound

▶ NANOSONICS



Stand 22-24

The trophon is a Hydrogen Peroxide based, automated High Level Disinfection system that is fast, intuitive and environmentally friendly. The trophon is designed to ensure safe and effective decontamination of semi-critical; semi-invasive and non-invasive ultrasound probes between patient uses. The trophon is a fully validated system which provides full traceability of each and every cycle. It is validated for use on over 1,000 ultrasound probes by all major and smaller suppliers of ultrasound systems.

Furthermore the trophon system is the only high level disinfection system proven to kill natural, infectious Human Papilloma Virus (HPV). HPV is the causative agent of cervical cancer and plays an important role in anogenital and oropharyngeal cancers. Residual HPV virus has been found on intra-cavity ultrasound probes following routine use in hospitals.

For more information visit: www.hpvdisinfection.co.uk

Tel: 01484 860581 or e-mail ukinfo@nanosonics.eu

▶ BRACCO UK LTD



Stand 23

Bracco Imaging SpA is one of the worlds leading imaging companies, its products are sold in over 80 countries with a global reputation for excellence. Bracco UK Limited, established in 2001 supports customers with products for X-Ray, Magnetic Resonance and Ultrasound imaging modalities including echocardiography

Please visit : www.bracco.com

▶ RH LOGISTICS

Stand 25

Richard Hindle has built and watched our company grow from its infancy to becoming one of the leaders in the niche market of specialist medical transport logistics. In addition to our logistics service we offer a bespoke asset management & warehousing facility. Our Eco friendly vehicles are purpose built to ensure paramount safety & security of your equipment, and our friendly team specialises in all aspects of the transport / warehousing sectors. Located in Hertfordshire we have direct access to reach any part of the UK with ease including off mainland and beyond.

Please visit : www.rhlogistics.com



▶ IMAGING FIRST LTD

Stand 26

Distributors of Alpinion range of ultrasound systems. With outstanding quality and refined acoustics, ALPINION's unique and flexible imaging platform, Flexcan™ architecture enhances system stability and helps to maintain system performance to the latest software versions. The reliable imaging platform guarantees uniform image quality.

Please visit : www.imagingfirst.co.uk



▶ SANCTUARY HEALTH

Stand 27

Working with NHS trusts and private hospitals across the UK, Sanctuary Health recruits for a wide variety of locum roles for fully qualified and HCPC registered sonographers, covering all areas of Ultrasound.

Having been appointed by the four main NHS frameworks (Crown Commercial Service (CCS), Collaborative Procurement Partnership (CPP), HealthTrust Europe and Shared Business Services) for the supply of a number of healthcare roles to NHS Trusts, including sonographers, we are able to match suitably qualified candidates with the ideal position.

Please visit : www.sanctuaryhealth.com




▶ CASMED INTERNATIONAL LTD

Stand 28

For over 30 years Casmed has supplied high quality products for use in all aspects of ultrasound including needle guides and cyst aspiration needles. We offer one of the industry's most complete selections of high quality disposable latex and latex-free probe covers for all makes of ultrasound probes. Contact us at info@camed.co.uk

Please visit : www.camed.co.uk



▶ DIAGNOSTIC HEALTHCARE

Stand 29

Our passionate clinical leads strive to promote best practice and professional development with a personal commitment to both employees and clients alike.

With an ever expanding and evolving presence in the market we can boast a flexible, stable and attractive approach to work including; contracted, temporary, locum arrangements, and attractive benefits with an option to join a reputable pension scheme. Diagnostic Healthcare offers practitioners a supportive and diverse working environment with a variety of skill mix.

Training is a key philosophy engrained in our company providing opportunities for clinical placements and professional development.

Visit our stand 20 at BMUS and say hello.

Please visit : www.diagnostichealthcareltd.com



▶ PFE MEDICAL

Stand 30

Probe Decontamination Specialists

Our Antigermix Range uses UV-C light to fully disinfect the entirety of a probe in a maximum of 200 seconds. Being used widely across the UK this range offers reproducible, validated probe decontamination solutions.

Speak to our product specialists to explore the various packages and options available.

Please visit : www.pfemedical.co.uk



▶ MULTI-MEDIX LTD



Stand 31

Multi-Medix are a UK independent diagnostic imaging ultrasound specialist, offering services designed to meet today's need for quality and affordability, including;

- **Quality Assurance**
- **Probe Repair**
- **Probe Sales**
- **System Sales**
- **Advanced Test Equipment**

We stock a comprehensive range of probes (new/used/refurbished) from all major manufacturers and have access to an extensive supply chain.

All probes are fully tested and shipped with a warranty and comprehensive report, detailing condition, performance and electrical safety.

Multi-Medix's team are built on the foundations of ex-NHS Clinical Scientists and Clinical Technologists; we are passionate about quality, patient safety and customer service.

Please visit : www.multi-medix.com

▶ GLOBE LOCUMS



Stand 32

Since our formation in 2011, Globe Locums has become one the preeminent specialist sonography recruitment firms in the UK being on all three national frameworks – CCS, CPP and HTE. This gives us unprecedented access to all NHS Sonography vacancies. Our global reach encompasses UK, Ireland, Australia, New Zealand & Asia Pacific, allowing Globe Locums to source both locum and permanent sonographers of the highest calibre. Globe Locums is clinician owned and run allowing our ethical focus to grow with our company, making us unique in a very busy marketplace.

We are always available on sono@globelocums.co.uk and 0207 229 2620 for an informal chat.



▶ SUPERSONIC IMAGINE



Stand 33

SuperSonic Imagine's Aixplorer® ultrasound system provides exceptional image quality and is the foundation of several innovations which have changed the paradigm of ultrasound imaging: ShearWave™ Elastography (SWE™), UltraFast™ Doppler, Angio PL.U.S – PLanewave UltraSensitive™ Imaging and now TriVu*, a real-time simultaneous imaging of B-mode, ShearWave™ Elastography and Color+. The new TriVu mode allows physicians to visualize anatomy, tissue stiffness, and blood flow at the same time

Please visit : www.supersonicimagine.com

▶ PHYSIOLOGICAL MEASUREMENTS



Physiological
Measurements Ltd.

Stand 34

Our community Ultrasound services are aligned to our successful integrated patient pathway, providing patients with high quality investigations close to home. Utilising the latest innovative technology, providing the highest standards of clinical and information governance compliance we are able to provide the highest quality ultrasound services in a community setting supported by Consultant Radiologists.

Please visit : www.physiologicalmeasurements.com

▶ MID CENTRAL HEALTH BOARD



MIDCENTRAL DISTRICT HEALTH BOARD
Te Pae Hauora o Ihuatira o Tairāwhiti

Stand 35

New Zealand! - Central Region Radiology Group consists of six District Health Boards across the lower North Island. They work together to support initiatives for workforce, quality improvement, standardised clinical indicators and access criteria. The Central Region is a mix of urban and rural communities – something for everyone!

Please visit : www.midcentraldhb.govt.nz



▶ BMUS



Stand 36

Come and visit the BMUS stand opposite the Poster Exhibition to find out about our latest plans for BMUS.

It is your chance to have your say on the future of the society and make suggestions for future workshops.

Please visit : www.bmus.org

▶ BOWEN THERAPY



Stand 37

Bowen Therapy Professional Association (BTPA), is an independent non-profit making organisation. Practice standards are set by an elected committee of members. The group is part of the national Complementary and Natural Health Care (CNHC) council, which is a voluntary regulator for practitioners, set up in 2008 with government funding.

Bowen Therapy is a gentle technique using the pads of fingers and thumbs to roll over soft tissue and ligaments. Bowen is suitable to be used in all age groups and especially where pain is present. It does not attempt to force change; rather it asks the body to recognise and make changes necessary to bring it back to homeostasis. Experience has shown that Bowen Therapy is very relaxing and in cases of emotional stress, where relaxation is a prime factor in easing pain and anxiety. It is also often a great help in improving the quality of life for those who are terminally ill.

Please visit : www.bowentherapy.org.uk



Proceedings of the British Medical Ultrasound Society 48th Annual Scientific Meeting

7th – 9th December 2016

York Racecourse, UK

Day 1 Wednesday 7th December

Obstetrics

Vasa Praevia: Targeted or universal screening. A review, G Coleman, Nottingham University Hospitals NHS Trust / University of Derby

Background

Vasa Praevia is an obstetric complication currently not screened for within the United Kingdom, which if undiagnosed prenatally can lead to fetal death when the membranes rupture. Internationally, guidelines are available for guidance on the best screening policy and management pathways however the UK National Screening Committee and Royal College of Obstetricians and Gynaecologists do not support screening due to a lack of evidence in support of a screening strategy.

Methods

A literature review was conducted to assess current research on the ability of ultrasound screening to detect Vasa Praevia prenatally within the general population versus targeted screening of the high risk population. There is no general consensus as to the 'best' screening strategy however the majority of authors noted that targeted screening of the high risk population is the most achievable and cost-effective screening strategy. A targeted screening strategy would hopefully provide the most cost effective strategy for detecting a large majority of Vasa Praevia cases in the high risk population. Even with a standard screening protocol though, not all cases will be detected. A universal screening strategy would have an initial large impact on the obstetric ultrasound community whilst a training programme would be implicated but long term may be the better option for detecting Vasa Praevia as not all cases occur in the high risk population.

Conclusion

Introduction of a screening strategy would affect training needs of professionals within the UK and would create the need to produce guidelines for patient management and quality assurance.

Research is required to define which screening method would be most effective and most accepted within the general population. The impact on staff training needs and management of patients following diagnosis would also need addressing.

This review provides details of current best practice evidence.

Womens experience of late pregnancy ultrasound, A Dacey, Cambridge University NHS Foundation Trust

Background

Ultrasound screening during pregnancy is accepted as part of routine antenatal care in the Western world (Garcia, 2002). Existing literature reflects UK clinical practice by focusing on the clinical implications and experiences of women undergoing ultrasound screening in the first and second trimester (Kohut, Dewey & Love 2002; Lalor & Devane, 2007). There is limited evidence demonstrating the implications, benefits and experiences of third trimester ultrasound scans. The implications of late pregnancy ultrasound remain unexplored and raise a number issues pertaining to understandings and beliefs about risk This study addresses these gaps in the literature.

Objectives

To retrospectively explore the experiences of women undergoing late pregnancy ultrasound during their first pregnancy, within the context of research participation in a large cohort study. The goal was to understand how late pregnancy ultrasound impacts on retrospective narratives of scans and where they 'fit' in understandings and emotional responses to themes such as risk and diagnosis in antenatal care.

Study Design

This qualitative study is theoretically informed by grounded theory. It draws on data collected through semi-structured interviews (n=50) following participation in the pregnancy outcome prediction study. Interviews were audio recorded and transcribed verbatim.

Results

Ultrasound plays a pivotal role in mediating women's anxiety regarding pregnancy progression and the well-being of the fetus. The visual aspect of 'seeing' the unborn child provides a level of reassurance beyond other aspects of routine care and has become the significant and defining moment of reassurance for expectant mothers. Despite clear guidelines as to the screening role of ultrasound during pregnancy, women consistently talked of ultrasound in non-diagnostic terms. While there were no clear differences between how women experienced late trimester ultrasound from earlier scans, the data revealed important findings pertaining to the environment of scanning, and the psychological implications of scans in the third trimester.

How useful is Doppler in the assessment of fetal well-being? C Lees, Imperial College London

Fetal Doppler has now established itself as essential in the assessment of fetal wellbeing. Particularly in the context of fetal growth restriction, where umbilical and middle cerebral artery Doppler give information on fetal condition and the ductus venosus can help time delivery. But increasingly, subtle Doppler changes also occur in fetuses that are not growth restricted but are compromised. Some of these Doppler changes are associated with adverse pregnancy and neonatal outcome. Yet the role of-for example the cerebro placental ratio-is still not properly defined. In this talk I will review the evidence for Doppler assessment: 'when and why' and discuss areas of particular controversy.

MSK Fundamental

MDT ultrasound procedure clinic in rheumatology outpatients year experience, G Johnson, Tameside Hospital NHS Trust

Ultrasound guided intervention is a well established technique in many ultrasound departments. Guided interventional techniques including soft tissue injections and aspirations allow greater patient acceptability and improve patient outcome. At our institution we have a Consultant MSK Sonographer led ultrasound procedure clinic which is performed in the general rheumatology outpatient clinic. Over the last 2 years we have introduced a MDT joint injection clinic where patients have input from a Rheumatology Nurse Specialist, Physiotherapy Specialist and a Consultant MSK Sonographer. We aim to discuss the role of MDT working and review the case mix presenting to this innovative one stop clinic. We explore the set up of the clinic, and value of the one stop approach to enhance patient experience and prompt care.

Achilles tendon rupture: Do the ends oppose in equinus? Our specialist foot and ankle unit protocol and a review of the imaging findings, L Ramsay, N Delves, A Carne, Royal Surrey County Hospital

Aims:

Achilles tendon (TA) rupture is increasing in prevalence as sporting and activity patterns change. The majority of ruptures occur in men between 30 and 40 years of age and at the musculotendinous junction approximately 2-6 cm from the insertion. Non-operative treatment for TA rupture is possible, and demonstrates benefits in reduced treatment costs and avoidance of operative complications such as wound breakdown or sural nerve injury. However, non-operative treatment can lead to incorrect tendon lengths and high re-rupture rates if the cohort is not carefully chosen through the use of ultrasonography and clinical features.

Methods:

In our dedicated foot and ankle unit, we have developed a protocol for determining operative or non-operative TA rupture treatment, designed to enable speedy response to the question "do the ends oppose in equinus?". We present our protocol for decision making in the acute setting and how we use real time group communication to facilitate multidisciplinary team working.

Results:

Along with our departmental protocol and methods, we review the imaging findings and required diagnostic information for acute TA rupture. Features against non-operative management include a tendon gap of >1cm in equinus on ultrasound and a presentation delay of >2 weeks. We discuss technique and examine common imaging pitfalls, including an intact plantaris tendon and symptomatic deep venous thrombosis. We also discuss what the radiologist or sonographer can do prior to review by the orthopaedic surgeons.

ABSTRACTS

Conclusions:

Achilles tendon rupture is a common injury with long term consequences to the patient's strength and function. Return to sport may be delayed significantly and gait abnormalities persist if correct treatment is not chosen. Appropriate decision-making regarding operative and non-operative treatment options can be significantly aided by careful sonography and excellent multidisciplinary team communication.

Physics

Vector Doppler: Technology and clinical impact, K Lindskov Hansen, Rigshospitalet University Hospital of Copenhagen, Denmark

Ultrasound velocity estimation is widely used for evaluation of the cardiovascular system. However, conventional methods only estimate the axial velocity component. Several methods for finding the velocity vector have been developed and investigated. This lecture will concern vector flow imaging using Transverse Oscillation, plane wave and synthetic transmit aperture imaging. The clinical impact of vector flow imaging will be illustrated by examples obtained on patients with different cardiovascular diseases, where conventional flow measures as well as new flow parameters only obtainable with vector flow imaging are discussed.

The relationship between depth of field and focus position on image quality: Raising awareness in student sonographers, G Taylor¹, A Culpán¹, S Wolstenhulme², ¹University of Leeds, ²Leeds Teaching Hospitals Trust

Introduction:

High image quality is vital in ultrasound diagnosis and is achieved through a combination of spatial and contrast resolution. The relationship between focus position and depth of field is important for image resolution optimisation.

Objectives:

The aim of this study was to increase student awareness of the relationship between depth of field and focus position and image quality in gynaecological ultrasound.

Methods:

Nine test images of echo-poor target groups mimicking ovarian cystic structures were obtained using an AST Laboratories multipurpose phantom 539 (Bridgeport, USA) and a MC9-4 transvaginal transducer (Siemens Medical Solutions, Mountain View, USA). The images were masked by cropping out focal position and depth of field information. Four sonographers of varying experience reviewed the images and rated subjective image quality.

Results:

The results suggested a direct relationship between perceived image quality and alignment of focus depth and depth of field to the region of interest (ROI). The highest rated image (average score of 9/10) had the focus depth and depth of field set to the same level as the ROI. The two lowest rated images (both with an average score of 1.25/10) did not align depth of field and/or focus settings to the ROI.

Conclusion:

The results demonstrated how poor image optimisation, when the depth of field and focus position are not aligned to the ROI, reduces perceived image quality. This simple simulation experiment increases student awareness of how important of image quality optimisation might be when imaging cystic structures within ovaries.

Validation of automated measurements of air reverberation patterns, D Rowland¹, C Sanders², T Evans¹, ¹Leeds Teaching Hospitals NHS Trust, ²St George's University Hospitals NHS Foundation Trust

Introduction

Measurement of the depth to the last reverberation is a useful tool for detecting degradation of ultrasound equipment. Automation has the potential to yield non-subjective high quality data enabling evidence based equipment management decisions to be made. A computerised method of automated measurements was developed and validated.

Method

A macro was developed using ImageJ software to analyse the reverberation pattern of 24 images from 2 scanners and 6 probes. The software automatically plotted averaged pixel value against distance from the transducer face for a region of interest (ROI) in the centre of the images.

One operator calibrated the image, defined the (ROI) and used the macro to analyse the images. The data were transferred to a spread-sheet to calculate the position of the last significant peak (LSP).

A second operator measured the depth to the last reverberation plane on the same images using the ImageJ line tool. This was repeated 6 times by the second operator without sight of the previous results. The averages and standard deviations of the manual measurements were calculated for each image.

The manual results were then compared with the automated LSP data.

Results

The average standard deviation from the manual measurements was 2.2% (relative) and ± 0.17 mm (absolute). The R-squared, gradient and offset for all the data were 0.86, 0.83 and +0.20 mm respectively. One outlying data point was observed which came from an image that had significant noise within the ROI. Without this data point the R-squared, gradient and offset were 0.97, 0.91 and -0.3mm respectively.

Conclusion

There is good correlation between automated and manual measurements. If automation is to be successful, images should be captured with gain levels set below the noise threshold. Further refinements to the method are recommended to extract more data from reverberation patterns.

Day 2 Thursday 8th December

Gynaecology

Unexpected finding in the hunt for an IUCD, R Turney, A Adshead, K Kingston, York Teaching Hospital NHS Foundation Trust

Ultrasound is the modality of choice for the initial assessment of IUCD position in young female patients. Patients usually present with inability to feel the threads of the IUCD and are referred to ultrasound by their GP after speculum examination has confirmed the finding. Our protocol starts with full bladder trans-abdominal scan with a curvilinear probe, progressing to trans-vaginal scanning in only a few cases. An abdominal X-ray is usually performed if the coil is not in situ within the uterus.

We present the case of a 32 year old patient referred for ultrasound assessment of IUCD position as the threads of a recently fitted device were no longer visible. Trans-abdominal scanning failed to demonstrate evidence of the IUCD within the uterine cavity. However, an incidental complex adnexal mass lesion was discovered and we proceeded to evaluate further with trans-vaginal scanning. The patient mentioned that she had suffered with endometriosis in the past. During evaluation of the complex cystic adnexal mass a brightly echogenic linear structure was seen within one of the locules of the cyst, this had reverberation artefact associated with it. It did not appear typical for calcification and an abdominal film confirmed that the IUCD was within the pelvis. MRI evaluation of the cystic structure confirmed that the IUCD had become extra-uterine and was located within part of the adnexal cyst. We will discuss the normal appearances of IUCD position in the uterine cavity and provide ultrasound, AXR and MRI images from this case.

Ultrasound is the best modality for initial evaluation of patients in whom IUCD position is in doubt. Usually this is a routine evaluation, but there are occasional surprises as in this case.

Professional Issues

RCR Standards for the provision of ultrasound service 2015: Was a whole service audit useful? What did we learn?, W Gardner, Bradford Teaching Hospitals NHS Foundation Trust

Aim:

Assess the level of compliance with RCR Standards for the provision of an ultrasound service 2015. Review the lesson we learned as an organisation. Comment on the wider applicability and usefulness of the Standard.

Method:

Focus was given to the key areas to which the Standard applies, general medicine, gynaecological and musculoskeletal. Equipment (including procurement, suitability, maintenance, QA, and life cycle), operator training, clinical examination (including protocols and applicable standards), reporting, audit and image management form the 6 subjects of the Standard and were taken in turn and compliance with the Standard assessed. Lesson learned and areas of good practice were fed back through clinical governance routes.

Conclusion:

An incredibly useful exercise. The amount of work required to undertake such an audit should not be underestimated, what will we do differently next time? What did we learn and how was that fed back into our practice?

Integrating transabdominal simulators into an ultrasound curriculum: Our experience at the Peninsula Radiology Academy, K Orr, S Hamilton, Peninsula Radiology Academy, Plymouth

Simulation is increasingly being used in medicine for learning and refining clinical skills in a safe, protected environment. Ultrasound simulators are established for learning interventional and intimate examinations, such as transvaginal ultrasound. Transabdominal ultrasound simulators are a relatively new phenomenon, with no current literature on this topic.

The obvious benefits of a simulated environment for learning invasive ultrasound skills are improved patient safety and comfort. While these factors are less of an issue with transabdominal ultrasound, there are several advantages to using simulation in this context. Across the UK the demand for ultrasound is increasing. This has resulted in increasing numbers of patients per ultrasound list. This increased pressure often results in shorter

appointment times and less hands-on experience for those learning ultrasound. This is of particular importance early in ultrasound training, when trainee sonographers and radiologists require more time to master the basics. This can result in lists overrunning, fewer patients being scanned or suboptimal training. For some radiology trainees, limited hands-on ultrasound experience early on can result in low confidence and ultimately, in some cases, a lack of enthusiasm for ultrasound training.

Using transabdominal ultrasound simulators in early ultrasound training offers trainees protected time to practice their ultrasound skills with none of the added pressure of someone looking over your shoulder or anxiety about holding up busy lists.

For these reasons, we decided to introduce transabdominal ultrasound simulation at the Peninsula Radiology Academy. We acquired a Medaphor transabdominal simulator in December 2014 and have integrated the simulator into the ST1 ultrasound training curriculum, which the first cohort of trainees have now completed.

We present our findings following one year of transabdominal ultrasound training, looking at performance in a clinical ultrasound assessment and the qualitative experience of the trainees undergoing this training.

Young Investigator 2016

The clinical efficacy of Contrast Enhanced Ultrasound in Focal Hepatic Lesion characterization, A Jameel¹, M Chhabu², B Pitrola¹, D Cosgrove¹, C Harvey¹, A Lim¹, ¹Imperial College Healthcare Trust, London, ²Imperial College, London

Aim:

To explore the clinical and financial impact of contrast-enhanced ultrasound (CEUS) in the characterisation of focal hepatic lesions (FHLs) compared with cross-sectional imaging (CT/MRI).

Materials and Methods:

Retrospective analysis of the diagnostic pathway for 414 consecutive CEUS scans at 2 large teaching hospitals between 2012-2014.

Cases were characterised into 3 sub-categories where CEUS:

- i. was comparable to CT/MRI and would have obviated the need for further imaging
- ii. offered a definitive diagnosis on lesions that were indeterminate on CT/MRI
- iii. was inferior in diagnostic capability to CT/MRI or was equally inconclusive and provided no diagnostic benefit

The gold standard was either histological diagnosis or stability. FHL with known diagnoses or no prior cross-sectional imaging were excluded.

A cost review was performed to assess the financial impact of utilising CEUS.

Results:

- 218 FHLs included –(145 benign and 73 malignant).
- 75 CEUS obviated the need for further imaging. (34.4%)
- 121 CEUS characterised previously indeterminate FHLs (55.5%)
- 21 CEUS provided no additional diagnostic benefit. (9.6%)

Cost review demonstrated financial benefit of CEUS in 89.3%, a total saving of £19,775 over 2 years.

Conclusion:

CEUS is a reliable, cheaper, often superior alternative to CT/MRI for characterisation of FHLs. CEUS significantly complements the imaging armamentarium for liver imaging.

Measurement of temperature increase in a phantom for transvaginal ultrasound scans: Audit results, P Miloro¹, E Martin², A Shaw¹, ¹National Physical Laboratory, ²University College London

Background

Every year, approximately 0.5 million transvaginal ultrasound scans are performed in the NHS. Recommendations suggest that a 4°C increase for 5 minutes is potentially hazardous to the foetus. Currently, however, the evaluation of temperature increase is currently entrusted to measures in air or values derived from measurements in water (i.e. the Thermal Index).

ABSTRACTS

Method

We designed a temperature controlled phantom with 5 thin wire (75 μ m) thermocouples embedded into a matrix of IEC agar-based tissue mimicking material, at the surface and at depths of 7, 14, 32 and 60 mm. The temperature was monitored during a clinical-scan like protocol which included 2D, Colour Flow and Pulsed Wave modes. The overall length of the test was 16 minutes.

We have tested 30 US scanner/probe combinations from 6 manufactures in 15 different UK centres. Only routine pre-set conditions for both obstetrics and gynaecology were tested.

Results

An example of temperature rise curve is shown in Figure 1, while an overview of the results is shown in Figure 2. The average temperature rise at the end of the test was $1.69^{\circ}\text{C} \pm 0.62^{\circ}\text{C}$ at the surface, which reduced to $0.75^{\circ}\text{C} \pm 0.29^{\circ}\text{C}$ and $0.30^{\circ}\text{C} \pm 0.12^{\circ}\text{C}$ at 7mm and 14mm respectively. No significant temperature increases were observed at greater depths. Colour Flow and Pulsed Wave modes can significantly increase the temperature peak and values over 3°C have been encountered in 8 cases.

Discussion

Temperature measurements show a variegated range of results depending on the scanner and on the setting. From our tests, it appears that the strongest source of heat is the transducer itself. Based on our measurement protocol, no temperature increases above 4°C were observed but use of Pulsed Wave or Colour Flow for periods longer than 30s could lead to greater heating.

Investigating the benefits of using an App driven user test quality assurance scheme, J Moggridge, University College London Hospitals NHS Foundations Trust

Background

There are clear benefits in end users performing simple quality assurance tests on ultrasound systems to detect early signs of crystal drop-out, membrane wear or loss of sensitivity. Issues such as time constraints and changing of personnel however can disrupt such schemes and make results inconsistent and difficult to compare to any existing baseline measurements. Added to this is a degree of subjectivity in determining when a difference in measured to baseline value is significant. The aim of this project was to determine if a web application could be used to help the end user complete the maximum reverberation line depth test and record the data centrally.

Method

A web application was written using Flask with a backend database running on MySQL. Prior to deploying the application, the database was prepopulated with details regarding the scanners and associated probes to allow the user to select the appropriate scanner/probe combination from a drop down selection. In addition to this an ultrasound physicist set up an appropriate preset for each probe/scanner combination and recorded baseline measurements for the deepest reverberation test. From this selection of the appropriate scanner and probe, the application would instruct the end user as to what preset to select and if there were any further settings to adjust prior to recording a measurement. The user would be warned if there was any significant difference in measurements from the previous or baseline measurements and, if the user was concerned, they could use the application to take an image of the screen which could be saved and emailed to their local ultrasound physics/engineering support team.

Results

Preliminary results and feedback from the project to be presented at the conference.

Quantitative poroelastic property imaging by combining shear wave and strain elastography, M Theodorou¹, J Fromageau¹, N Desouza² J Bamber¹, ¹Joint Department of Physics and Cancer Research UK, ²Royal Marsden NHS Foundation Trust and Cancer Research UK

Background:

Poroelastic theory may be used to explain both cellular [1] and tissue rheology [2,3]. It describes the movement of fluid away from a region of tissue during sustained compression. The resulting time and spatially-varying deformation of the tissue matrix may be imaged as a change in ultrasound echo strain over time. Strain movies allow the quantitative imaging of the product of the tissue's aggregate modulus and fluid permeability, Hk , and its Poisson's ratio, ν . We have successfully developed a novel ultrasound technique to measure tissue fluid permeability, k , independently of H , which we have assessed on tissue-mimicking phantoms.

Methods:

In the new method, which we call permelastography, H is calculated from ν and the tissue's Young's modulus, E , where E is obtained from shear wave elastography (SWE) [4]. This was tested on a series of agarose phantoms of varying matrix pore size, controlled by varying agarose concentration.

Results:

By combining the H , ν and E maps, the permeability was extracted with an estimated uncertainty of $\pm 5.8\%$ and varied systematically and reproducibly with matrix pore size. Intra-phantom variation in k was about 15% of the mean, and the mean values of k fell within about 28% of those measured using an independent but destructive method [5].

Discussion:

The non-invasive estimation of the biomechanical properties E , k and ν could be valuable clinically because cancer is associated with altered ability of fluid to move in tissue due to increased collagen deposition and leakiness of the microvasculature associated with angiogenesis. We have now adapted our experimental setup into a light, 3D printed hand-held design comprising one ultrasound and one SWE transducer jointly held above a compressor plate, which provides force-feedback to the operator. The prototype is being evaluated clinically to characterize the poroelastic behavior of tumours, surrounding normal tissues and the post-irradiated breast.

[1] E Moeendarbary et al, *Nature Materials*, 12, 2013. [2] GP Berry et al, *Ultrasound Med Biol*, 32, 2006. [3] RL Liederman et al, *Phys Med Biol*, 51, 2006. [4] M Tanter et al, *Ultrasound Med Biol*, 34, 2008. [5] Johnson and Deen. *AIChE J*, 42, 1996.

Combined contrast ultrasound and optoacoustic imaging in the evaluation of tumour hypoxia, A Shah, N Bush, G Box, S Eccles, J Bamber, Institute of Cancer Research

Introduction

Optoacoustic imaging (OAI) has demonstrated the potential of imaging hypoxia in cancer but provides limited information on haemodynamics. Conversely, dynamic contrast enhanced ultrasound (DCE-US) is widely used to evaluate perfusion. This study describes a novel method of co-registering optoacoustic images (MSOT inVision 256-TF, iThera Medical) with DCE-US images (Aplio XG, Toshiba) to demonstrate, in preclinical cancer models, the value of combining the two imaging modalities.

Methods

OAI of subcutaneous tumours PDA-KPC-1-GEMM ($n=2$) and MIAPACA-2 ($n=3$) in nude mice was performed at wavelengths ranging from 710 nm to 900 nm. Spectral unmixing indicated the oxyhaemoglobin and deoxyhaemoglobin components. Neglecting optical fluence variations, total haemoglobin (HbT) and SO₂ images were calculated as described in [1]. Each animal was then transferred to a gantry, designed to reproduce and provide registration to the MSOT setup when imaging with a clinical ultrasound scanner. The tumour was scanned after an intravenous injection of 100 μ L SonazoidTM microbubbles. Regions of interest were selected on the registered images (Fig. 1D), to compare SO₂ and HbT with DCE-US parameters.

Results and conclusion

As seen in Fig. 1, there are tumour regions with no blood signal (Fig 1A), and yet DCE-US showed that they were perfused (Figs. 1E, black curve). For all tumours studied, a significant negative correlation was observed between SO₂ and microbubble time of arrival, time to peak and wash-in time (Fig. 1F), and a significant positive correlation was observed between HbT and area under the curve and peak contrast (Fig. 1G). Both SO₂ and HbT were positively correlated with the wash-in rate. This preliminary study has clearly demonstrated the potential of combining OAI and DCE-US to provide a better understanding of optoacoustic hypoxia images in pre-clinical tumours.

References

[1] Laufer et al, "In vitro measurements of absolute blood oxygen saturation using pulsed near-infrared photoacoustic spectroscopy: accuracy and resolution," *Phys Med*

ABSTRACTS

Assessing quality of experience for medical tele-assistance: Preliminary study with ultrasound exams,

L Lévêque¹, Y Cheng¹, P Parker², ¹University of Hull, ²Hull & East Yorkshire Hospitals

Introduction:

The increasing use of information and communication technologies to support clinical care at distance, defined as telemedicine [1], has stressed the need to assess the Quality of Experience (QoE), i.e. the degree of delight or annoyance of the user of an application or service [2]. QoE is therefore particularly important in tele-assistance, where a medical expert helps a remote operator during a procedure.

To define QoE, the system, contextual and human factors are the three aspects to consider [2]. Interviewing medical experts is a promising approach to explore these factors. Ultrasound exams were chosen for this preliminary study as they are dynamic exams.

Methods:

Two distinctive experiments were designed and carried out to investigate the QoE impact factors. Firstly, six sonographers were interviewed using Knowledge Management methods [3] with a view to elicit their expertise, representing the contextual and human factors. Secondly, nine sonographers had to rate the usability of four ultrasound videos distorted with seven bit rates using H.264/AVC and HEVC codecs, to represent the system factor.

Results:

The textures, contrasts and edges were identified as the most meaningful criteria for ultrasound exams during the first experiment. Statistical analyses on the quality assessment results showed a significant correlation between bit rates and usability scores given by the experts, with a threshold around 700 kbps for H.264/AVC and 500 kbps for HEVC. Consistent with literature [4], HEVC appeared to be better than H.264/AVC for a same bit rate. A lower bit rate implies a modification of the video characteristics, and thus a diminution of the perceived quality. Results also showed that content affects the perceived quality.

Are Radiologists aware of their boundaries?, M Spurr, E Hallett, S Berry, R Rhys, Royal Glamorgan Hospital, Llantrisant

Objective

To evaluate how accurately radiology can predict extra-capsular spread (ECS) in lymph nodes in head and neck cancer patients.

Methods

All neck dissections at The Royal Glamorgan Hospital were analysed retrospectively between February 2011 and November 2015. The radiology department used a combination of USS and CT to assess nodes; MRI was occasionally used if considered necessary. Pre-surgical radiological findings were compared with nodal histology obtained from neck dissection.

The radiologically false positive patients were mixed with 3 other patients from our study and blindly re-reported. The reasons for the false positives happening were then analysed.

Results

119 patients were included in the study. Specificity was calculated as 97.2%, sensitivity 100%. The positive and negative predictive values were 80% and 100% respectively.

There were 3 false positives. We believe these occurred as suspicious borders seen on CT and MRI were labeled as ECS even though the USS was negative.

Conclusion

Although ECS is not formally included in TNM staging, it is recognised to be associated with decreased survival (Puri et al. 2003) and can affect treatment (Mendenhall et al. 2006).

Our data suggests that radiology is able to accurately predict ECS with a negative predictive value of 100%. We found false positives occurred when suspicious borders seen on CT and MRI were labeled as ECS despite negative static USS images.

Our radiologists now always report on the presence or absence of ECS whilst they are actually performing the USS. If a suspicious border is seen on CT or MRI, we hope this information on the USS report will add significant context to how these borders are interpreted and reduce false positives.

Satellite Session: Therapy Ultrasound Group

Vapour bubble nucleation in boiling histotripsy, M de Andrade¹, S Haqshenas¹, K Joo Pakh², N Saffari¹, ¹University College London, ²Korea Institute of Science and Technology (KIST)

The development of ultrasound protocols capable of inducing repeatable bubble activity in soft tissue is an important shift in the way cavitation is regarded in biomedical ultrasound. Therefore, understanding the conditions under which bubbles nucleate in acoustic fields becomes a key aspect of designing appropriate protocols for specific surgical needs.

In this work, we modelled nonlinear acoustic wave propagation in liver, simulating shock pressure amplitudes at the transducer focus and the resulting temperature rise over 4 ms of insonation via the Khokhlov-Zabolotskaya-Kuznetsov and the Bioheat transfer equations.

Furthermore, a quasi-stationary approximation of the Classical Nucleation Theory (CNT) was used to analyse the resulting pressure and temperature fields in order to obtain nucleation properties in time and space for a boiling histotripsy protocol.

Results show a strong dependence of the nucleation pressure and nuclei critical radii on the liquid temperature, the latter ranging from 1-10 nm under typical therapeutic ultrasound pressure and temperature fields, nucleating preferentially at the regions of the focus where temperatures are higher.

For shockwaves with peak pressure values of $p^+ = 95$ MPa and $p^- = -16$ MPa at the focus, the first nuclei would form in less than 2 ms of insonation, at a temperature of 113 °C. For higher peak pressure values ($p^+ = 115$ MPa and $p^- = -17$ MPa) the onset of nucleation would happen earlier, right before 1 ms, at 99 °C.

Simulations suggest that milisecond nucleation is facilitated by high temperatures, but ultimately triggered by large negative pressures, producing bubbles that are inertially controlled at first and then thermally controlled as more nuclei are produced.

Such results are in both quantitative and qualitative agreement with numerical and experimental results in the literature, showing that CNT is a useful tool in simulating the onset of cavitation phenomena in ultrasound protocols.

References

1. Maxwell A, Sapozhnikov O, Bailey M, Crum LA, Xu Z, Fowlkes B, et al. Disintegration of Tissue Using High Intensity Focused Ultrasound: Two Approaches That Utilize Shock Waves. *Acoustics Today*. 2012;8(4):24.
2. Herbert E, Balibar S, Caupin F. Cavitation pressure in water. *Physical Review E [Internet]*. American Physical Society; 2006 Oct 16;74(4):041603. Available from: <http://journals.aps.org/pre/abstract/10.1103/PhysRevE.74.041603>
3. Pakh KJ, Dhar DK, Malago M, Saffari N. Ultrasonic Histotripsy for Tissue Therapy. *Journal of Physics: Conference Series*. IOP Publishing; 2015 Jan 29;581(1):012001.
4. Wagner W, Pruß A. The IAPWS formulation 1995 for the thermodynamic properties of ordinary water substance for general and scientific use. *AIP Publishing*; 2002 Jun 1;31(2):387-535.
5. Blander M, Katz JL. Bubble nucleation in liquids. *AIChE Journal*. American Institute of Chemical Engineers; 1975 Sep 1;21(5):833-

Experimental validation of simulated transcranial ultrasound propagation, L Robertson, E Martin, B Cox, B Treeby, University College London

Low intensity, transcranial application of ultrasound is under active research for opening of the blood brain barrier and ultrasonic neurostimulation. Accurate simulation of ultrasound propagation in the head is necessary for simulation based time-reversal focusing, and the prediction of intracranial fields during sonications.

In the present work, simulations of ultrasound propagation through skull like media were validated against measurements of the acoustic field of a single element spherically focused ultrasound transducer, following propagation through a skull phantom. Three different skull bone phantoms were created from VeroBlack 3D printing material and castable Araldite resin. Computer aided design, 3D printing, and laser cutting were used to exactly register the positions of the source and phantoms in the simulations and experiments. The acoustic properties of the phantoms were measured using a transmission-substitution method for input to simulations.

ABSTRACTS

Good agreement was observed between the measured and simulated peak positive pressure for both 3D printed and resin phantoms. The maximum difference in the peak positive pressure was 2.1%. The maximum difference in the focal position was 0.9 mm and the maximum difference in the -3dB focal volume was 11.6%. The

time-varying pressure at the focus of the field was also extracted. The simulated and measured data showed very good agreement, especially for the VeroBlack phantom, for which the uncertainty in the acoustic properties was lower. These results demonstrate that time-varying pressure fields can be simulated with high fidelity when an accurate map of acoustic medium properties is available.

Evaluation of the resonance frequency shift of ultrasound-driven microbubbles embedded in tissue-mimicking phantoms, A Jamburidze, A Huerre, M De Corato, V Garbin, Imperial College London

With the advent of a new generation of contrast agents that can extravasate, namely perfluorocarbon nanodroplets that are transformed into microbubbles by acoustic vaporisation, it has become possible to deliver microbubbles to tissues and to effectively target tumours. It is therefore becoming increasingly important to understand the behaviour of bubbles embedded in tissues, both for imaging and therapeutic purposes. We studied the behaviour of bubbles embedded in agarose hydrogels mimicking the viscoelastic properties of different tissues. The hydrogels were characterized by rotational rheometry and the values of shear modulus and shear viscosity were measured. Bubbles of 100-200 μm excited at 30-50 kHz were used for this study, since this enabled time-resolved optical imaging using a high speed-camera at 300,000 frames per second. Importantly, the results translate directly to ultrasound contrast agent microbubbles excited in the MHz range. The experimental results show that the shear modulus of the material causes a significant shift in the resonance frequency of the bubbles. We fitted the data using the Rayleigh-Plesset equation combined with the Kelvin-Voigt model, which describes the linear deformation of viscoelastic solids, and obtained independent measurements of the viscoelastic properties of the hydrogels. Ultimately, this knowledge will help develop optimal insonation protocols as a function of tissue properties following extravasation of contrast agents.

Microbubble trapping and destruction for targeted drug delivery, L Nie¹, S Harput^{1,2}, D Cowell¹, T Carpenter¹, J McLaughlan¹, S Freear¹, ¹University of Leeds, ²Imperial College London

Introduction

Ultrasound-assisted drug delivery and release by subjecting therapeutic microbubbles (MBs) to acoustic field proved beneficial for cancer therapy with reduced systemic side effects [1]. While the short lifetime and low concentration of ultrasound agents in the circulatory system place a basic limit on the expected drug efficacy improvement [2]. Therefore, manipulating and accumulating MBs at targeted site in clinically relevant flow rates is of great potential value to facilitate drug-loaded MBs for therapy [3, 4]. In this study, manipulation of MBs, fast imaging and destruction sequences were generated with a linear array medical ultrasound probe to deliver an ultrasound-activated therapeutic payload for cancer treatment.

Methods

A 128-element linear array probe is connected to the bespoke Leeds Ultrasound Array Research Platform II (UARP II) [5, 6] which undertakes arbitrary excitation generation and Plane Wave Imaging (PWI). Three different excitation schemes were interleaved at kilo-Hertz rates to achieve MB trapping, monitoring and destruction. The ability to quickly switch between different excitation schemes results in high efficacy targeted drug delivery and ultrasound imaging at 1000 frames per second.

For MBs manipulation, the probe is separated into two parts with equal 64 elements, out of phase pulses from two sub-apertures are transmitted simultaneously to destructively interfere along the center. Pressure null at the central line realizes an ultrasonic trap to stop MBs relying on steep pressure gradients [3]. The intensity of inlet beam is optimized by using aperture apodization and pulse width modulation [6] to attenuate MBs velocity and also ensure MBs inflow to the trap region. Fig.1 depicts the beam plot using Field II simulation and calibrated pressures in water at the depth of 35 mm used in experiments are detailed in Fig. 2.

Focused beam with mechanical index of 0.7 with 100 μs duration is prepared by transmitting 4.8 MHz sinusoidal excitations with the same transducer for destroying MBs. Imaging during trapping and destruction is achieved through single PWI pulse to retain MBs within the pressure null region when flow phantom is adopted.

Preliminary results and Discussions

Physiologically relevant mean flow velocity of 140 mm/s was used in a 3.5 mm wall-less flow phantom, pulse repetition frequency at 1 kHz for trapping and PWI imaging pulse switching. The 2D ultrasonic velocity map was encoded and superimposed on corresponding B-mode images (Fig.3). The trapping efficiency is refined by

lower MB velocity than 5 mm/s (green dots in Fig.3) at designed pressure null site which ultimately increases the concentration of MBs at central line of the transducer axis.

In conclusion, the ultrasonic trapping technique can increase the population of MBs at the target area. When coupled with destructive pulses, potentially they can circumvent the drug dose and minimize systematic adverse effects. During therapy, PWI can monitor the process continuously while retaining MBs in targeted site at high frame rates, which is crucial for analysing the MB behaviour and flow dynamics.

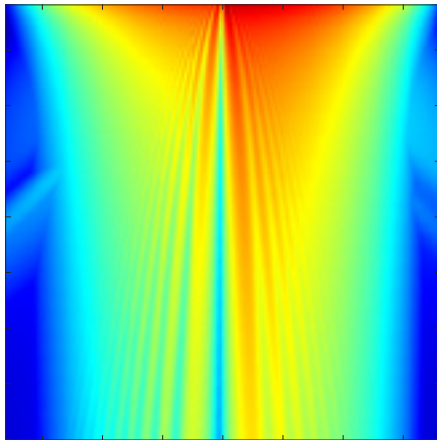


Fig.1. Beam plot simulation of the trapping beam using Field II.

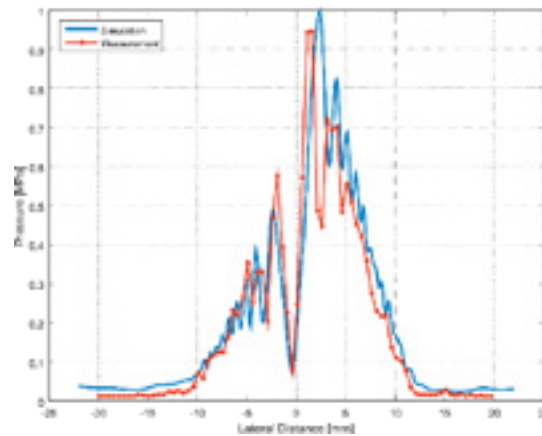


Fig.2. Beam profile of two plane wave trapping beams with π phase shift for tissue mimicking flow phantom at 35mm depth.




Fig.3. 2D encoded velocity map superimposed on corresponding B-mode image.

References

1. Frenkel, Victor. "Ultrasound mediated delivery of drugs and genes to solid tumors." *Advanced drug delivery reviews* 60.10 (2008): 1193-1208.
2. Owen, Joshua, et al. "Magnetic targeting of microbubbles against physiologically relevant flow conditions." *Interface focus* 5.5 (2015): 20150001.
3. Harput, Sevan, et al. "Simultaneous trapping and imaging of microbubbles at clinically relevant flow rates." *Ultrasonics Symposium (IUS), 2016 IEEE International*. IEEE, 2016.
4. Raiton, B., et al. "The capture of flowing microbubbles with an ultrasonic trap using acoustic radiation force." *Applied Physics Letters* 101.4 (2012): 044102.
5. Cowell, David MJ, Peter R. Smith, and Steven Freear. "Phase-inversion-based selective harmonic elimination (PI-SHE) in multi-level switched-mode tone-and frequency-modulated excitation." *IEEE transactions on ultrasonics, ferroelectrics, and frequency control* 60.6 (2013): 1084-1097.
6. Smith, Peter R., David MJ Cowell, and Steven Freear. "Width-modulated square-wave pulses for ultrasound applications." *IEEE transactions on ultrasonics, ferroelectrics, and frequency control* 60.11 (2013): 2244-2256.

ABSTRACTS

A hybrid multiscale model to simulate *in vitro* experiments of focused ultrasound mediated heating combined with radiotherapy, S Bruening¹, G Powathil², I Rivens¹, J Ijaz¹, U Oelfke¹, M Chaplain³, G. ter Haar¹, ¹Institute of Cancer Research, ²Swansea University, ³University of St Andrews, St Andrews

Combination treatments of radiotherapy and heat offer great potential to successfully treat radiation-resistant tumours by overcoming their resistance through thermo-radiosensitisation. Focused ultrasound (FUS) provides a potential treatment modality to locally apply hyperthermia at temperatures ranging from 45 to 50°C which would greatly reduce treatment times to deliver radio-sensitizing thermal doses. We present a multiscale simulation framework that models the cellular response to *in vitro* experiments of combination treatments of radiation and FUS mediated heating. A cell survival model (AlphaR model) designed to describe multimodality therapies is used to calculate cell surviving fractions, taking into account cell specific characteristics, such as the cell cycle stage. We calibrate important simulation parameters to reflect the treatment response of the colorectal carcinoma cell line HCT116, and verified this framework against experimental growth curves of these cells subjected to heat, irradiation and a combination of the two treatments. The model can easily be calibrated to describe various cell lines and therefore holds great potential for future studies on heterogeneous cell populations and their response to combination therapies.

Designing an ultrasound transducer for targeted cancer drug delivery by ultrasound-mediated large volume mild hyperthermia, B Chu, R Cleveland, C. Coussios, University of Oxford

Minimising the harmful side-effects of cancer therapy on healthy tissue, whilst delivering an effective lethal dosage to the target site is a fundamental challenge in the treatment of cancer. This work is motivated by the development of thermosensitive liposomes which encapsulate a chemotherapy agent which can be released by ultrasound-mediated hyperthermia. These liposomes provide a way of locally delivering chemotherapeutic drugs in target tissue while reducing the dose elsewhere in the body. Effective treatment requires mild hyperthermia over much large regions than is done in traditional ablative therapeutic ultrasound. In order to develop a source condition that will generate the desired heating an optimisation procedure for transducer design was developed using a Fresnel approximation for the ultrasound propagation and a 3D finite-difference thermal simulation. A finite element package (PZFlex) was then used to simulate the pressure fields of potential ultrasound transducer designs in non-homogeneous media, including different tissue layers such as skin and fat, as well as incorporating the effect of blood perfusion in thermal simulations.

[Work supported by the RCUK Digital Economy Programme, grant number EP/G036861/1 (Oxford Centre for Doctoral Training in Healthcare Innovation)]

Acceleration techniques for acoustic holography, D Sinden, P Miloro, S Chretien, A Shaw, National Physical Laboratory, Sutton

Acoustic holography is the acquisition of a set of phase and magnitude measurements at points located on a specific surface (called a hologram), to fully characterise an acoustic field. The hologram may be projected backwards or forwards in space. It can be used for quality assurance, to verify that the output of the device is as specified. It is also a robust and versatile input into simulations of acoustic fields, which may need to be performed in situations in which measurements cannot be made, such as at extremely high pressures, propagation in materials in which instrumentation cannot be embedded or when it is simply too time consuming to measure at every possible point in the field. However, acquiring the data may be a time-consuming process, in this talk two methods are presented, one of which is experimental, the other theoretical, which can shorten the time taken to construct acoustic holograms.

The first is the implementation of a system at NPL in which a continuous acquisitions of waveforms can be performed. This reduces acquisitions times significantly, typically, by up to twenty times. The data is free from artefacts associated with the motion of the hydrophone.

The second acceleration technique is to exploit the sparse, low-rank structure of the acoustic holography, to reconstruct, to within a high degree of accuracy, the complete acoustic field from partial or incomplete data [1]. It is important to note that data must still be sampled at the Nyquist limit, i.e. at half the wavelength, but significantly less data is required in order to reconstruct the hologram. An advantage of the reconstruction algorithm is that outliers can be identified and that it achieves exponential convergence, meaning that the algorithm takes a few minutes to run on a powerful desktop computer. A challenge is that the magnitude and phase data are fundamentally different: The phase data is bounded between $(0, 2\pi)$ and is not data-sparse, in contrast to the magnitude data. As such, using an algorithm which exploits the low-rank structure of the holography data, the reconstruction of the phase data is slower to converge, and, as such, sets a bound on the convergence criteria. This is significant in situations in which phase is important, i.e. when the convergence of the beam is modelled, for example when simulating focal pressures, but is not significant when back-projecting to verify the integrity of each element of a multi-element phased-array.

[1] "SpaRCS: Recovering low-rank and sparse matrices from compressive measurements", A. E. Waters, A.C. Sankaranarayanan and R. Baraniuk, in *Advances in Neural Information Processing Systems 24*, Eds. J. Shawe-Taylor et al., pp. 1089-1097, 2011.

Pre-clinical combination of focused ultrasound and radiotherapy, using Photoacoustic Imaging as planning and monitoring tool, M Costa, A Shah¹, I Rivens¹, T O'Shea, C Box, J Bamber¹, G ter Haar¹, ¹Joint Department of Physics, The Institute of Cancer Research, ²Royal Marsden NHS Foundation Trust

Tumour hypoxia can limit the success of cancer treatments involving radiotherapy, since the decreased oxygenation renders cells radioresistant. On the other hand, the efficacy of tissue ablation using high intensity focused ultrasound (HIFU) is independent of oxygen levels. In this paper, we suggest a combinatorial approach of HIFU and radiotherapy, using the first to target hypoxic tumour volumes, in order to improve treatment outcome.

Imaging blood oxygenation, which in part determines hypoxia, can be achieved non-invasively using photoacoustic imaging. The technique is based on the generation of acoustic waves by the tissue upon absorption of short pulses of light. These waves can be detected using a transducer and an image that shows contrast for the distribution of relative strength of optical absorption, is then reconstructed. Light is absorbed differently by oxy- and deoxy-haemoglobin, hence it is possible to calculate the relative proportion of both chromophores and, consequently, the oxygen saturation of blood distribution in tissue, in this case tumours.

This study used a subcutaneously implanted human head and neck tumour (CAL^R) in immunosuppressed mice. This is an in vivo model that recapitulates the hypoxia frequently seen in human disease. HIFU and radiotherapy treatments were guided by ultrasound and computed tomography imaging, and performed in dedicated small animal platforms: VIFU-2000 and SARRP (225KeV), respectively. Therapies were delivered to tumours with a mean volume of ~200 mm³. Photoacoustic imaging (Multispectral Optoacoustic Tomography (MSOT), iThera, Munich) was used to measure blood distribution and its oxygen saturation non-invasively with the aim of identifying the main hypoxic tumour regions to aid HIFU treatment planning. Uniform radiation exposures of 10, 20 or 30 Gy, in a single fraction, were used.

HIFU exposures alone, targeted on the most hypoxic tumour region, resulted in an ~4 day mean growth delay, without tumour regression. Ten Gy radiation alone achieved an average of 9.6% tumour growth inhibition in 33% of animals and 40% tumour regression in 22%; 20 Gy achieved an average of 80% tumour regression in 60% of the animals and 63% tumour growth inhibition in 20% of the animals; 30 Gy treatment resulted in 48% tumour regression in 67% of animals and 88% growth inhibition in 22% of the mice.

For the combined treatments, mice were irradiated with 10 Gy, with HIFU exposure 15 minutes before or after radiotherapy. This resulted in a tumour regression rate of 76%, a statistically significant improvement in the tumour control achieved with 10 Gy alone. No differences in outcome were observed between neoadjuvant and adjuvant HIFU.

This preliminary work has shown a therapeutic benefit from combining hypoxia targeted HIFU with whole tumour radiotherapy, in terms of improved outcome at lower doses. This could have a positive impact on the treatment of tumours that are characteristically hypoxic, such as those of head and neck, if translated to clinical practice.

FLIR thermography and optical spectroscopy for assessment of changes in ex vivo tissues exposed to high intensity focused ultrasound, J Raymond, E Edwards, R Cleveland, R Roy, University of Oxford

Real-time acousto-optic (AO) sensing has been shown to non-invasively detect changes in *ex vivo* tissue optical properties during high-intensity focused ultrasound (HIFU) exposures. Baseline changes in optical properties have been previously measured as a function of thermal-dose for tissues exposed to a temperature-controlled water bath (doi:10.1088/0031-9155/59/13/3249). In this work, the wavelength-dependent optical scattering and absorption of *ex vivo* tissues exposed to HIFU were measured using an integrating sphere spectrophotometric technique employed previously. HIFU-induced spatiotemporal temperature elevations were measured using an infrared camera and used to calculate the thermal dose delivered to a localized region of tissue. We consider the impact of thermal dose, temperature elevation, and heating rate on the formation of HIFU lesions and the resulting changes in tissue optical properties. Results will show how wavelength-dependent optical property changes in tissues can be used to improve the AO sensing of lesion formation during HIFU therapy as an alternative to thermometry. [Work supported by the University of Oxford Dept. of Engineering Science, F. V. Hunt Postdoctoral Fellowship of the Acoustical Society of America and EPSRC grant number EP/K02020X/1.]

An investigation into the biological and immunological effects of heat, P Mouratidis, G ter Haar, Joint Department of Physics, The Institute of Cancer Research, Royal Marsden NHS Foundation Trust

Tumour formation and proliferation is a dynamic process driven by mutated genes. Over time, mutations accumulate in the progeny, leading to successive waves of clonal expansion of the tumour cells and the eventual formation of subclones with differing abilities to metastasize. Cancer evolution continues during treatment and drug resistance develops over time. For these reasons treatment approaches which target multiple signalling pathways are necessary in order to attack cancer cells irrespective of their genetic heterogeneity. Therapeutic ultrasound and immunotherapy may provide this capability. We have investigated the activation of Immunogenic cell death (ICD) after thermal exposure of human colon cancer cells *in vitro*. Hallmarks of ICD such as exposure of Calreticulin on the outer surface of the plasma membrane and downregulation of CD47 were investigated using FACS analysis. ATP secretion was investigated using a colorimetric ATP detection kit. The activation of heat shock proteins, Hsp70 and Hsp90 was investigated using western blotting and a pharmacological inhibitor. Thermal exposure of human HCT116 colon cancer cells with EM₄₃s of 60 and 120 minutes resulted in an increase in Calreticulin exposure on the outer side of the plasma membrane, down regulation of CD47, increased levels of ATP in the medium and activation of Hsp70 and Hsp90. These data suggest that ICD is activated after thermal exposure of cancer cells and reinforces the rationale for the combination of Therapeutic ultrasound with current immunotherapeutic approaches to treat tumours.

Preliminary results of Synthetic Aperture Imaging using random phased arrays, M Zubair, R Dickinson, Imperial College London

Randomized phased arrays have been used for generating and steering single focus and multiple foci with low levels of grating lobes due to the breakage of periodicity of the elements and are considered as useful source of HIFU. However, the reliance of HIFU on MRI for real time visualization of the targeted tissue is a major constraint in its clinical use due to the high cost of MRI and its low temporal resolution.

Dual mode ultrasound phased arrays would have the advantage of using the same array for both therapy and imaging due to the inherent registration between imaging and therapeutic frames of reference. Since strong scattering objects in path of HIFU beam are also in path of imaging beam, such objects can be detected in real time and the HIFU beam can be adjusted accordingly. However, the random spherical array would have limited field of view due to the fact that the array is optimized for therapy only and has large, directive elements sparsely positioned on a spherical surface. Nevertheless, images obtained will be useful as they will be aligned with the therapy transducer.

In this paper, preliminary results of synthetic aperture imaging with the random phased array are shown. Sub-apertures are being used to image the field of interest, where each sub-aperture contains only those elements which has the pixel in the range of its main lobe. This not only improves the resolution but also significantly reduces the computation time.

Full-wave modelling of therapeutic ultrasound propagation to the kidney in CT based patient models, V Suomi¹, J Jaros², B Treeby³, R Cleveland¹. ¹University of Oxford, ²Brno University of Technology, Brno, Czech Republic, ³University College London

It has been suggested that variable outcomes in the treatment of kidney tumours with therapeutic ultrasound are due to the acoustic properties of fat layers in the path to the kidney (Ritchie et al, UMB 39:1758 (2013)). The effect of inhomogeneities was studied by carrying out nonlinear acoustic simulations using fully three-dimensional models derived from patient CT scans using k-wave with density, sound speed, attenuation and nonlinearity all allowed to vary. It was found that, relative to the intensity in water, the field in the kidney had an average drop in focal intensity of 11.1 dB. Furthermore the focal region was split into a number of child focal volumes. When the sound speed was held fixed the focal loss was reduced to 6.4 dB and no splitting was observed. This suggests that it is refraction and aberration, due to variations in sound speed, that dominate the loss of focusing in the kidney. Three dimensional thermal simulations were then carried out using finite-difference methods. When refraction effects were present the predicted temperature rise was less than 10°C with significant variation across the patients; and in one patient the thermal dose never exceeded 240 CEM. When sound speed was held fixed the temperature rises were almost 20°C and very similar in all three cases and the volume of tissue heated to 240 CEM was 30-fold larger than in the scenario with sound speed variation. Variation in other tissue properties were also considered but did not have a dramatic impact on the acoustic field or temperature. The results show that the efficacy of ultrasound therapy in the kidney could significantly be improved with aberration correction.

Day 3 Friday 9th December

Abdomen and General

The clinical value of ultrasound in assessing patients with chronic liver disease, L Corless, Hull and East Yorkshire Hospitals NHS Trust

Ultrasound is the cornerstone of radiological investigation in people with suspected liver disease. The talk will focus on the specific uses, and potential pitfalls, of ultrasound in 3 key areas of hepatology practice: persistently abnormal liver function tests, non-invasive assessment of liver fibrosis, and management of compensated and decompensated cirrhosis. Issues surrounding the delivery of ultrasound to an increasing patient population will also be discussed.

Pitfalls in hepatobiliary ultrasound, C Harvey, Imperial College Healthcare NHS Trust, London

Ultrasound is the initial modality of choice in the assessment of the hepatobiliary system. Ultrasound is highly sensitive and specific in the diagnosis of gallbladder pathology. However, there are many pitfalls that sonologists should be aware of. These include normal and pathological structures which may mimic the gallbladder and simulate pathologies including bowel and other adjacent pathologies. This talk will cover a wide spectrum of problems in the diagnosis and interpretation of gallstones, polyps, focal lesions, GB wall thickening, non-visualisation of the GB, biliary duct abnormalities, artefacts and focal liver lesions. This presentation describes the technical, anatomical and diagnostic pitfalls commonly encountered during sonography of the gallbladder, liver and biliary tree and how to recognise and avoid them. The role of other imaging as well as contrast-enhanced ultrasound will be discussed.

Comparative study of shear wave elastography systems on two ultrasound units in patients with known or suspected liver disease, P Parker, Hull and East Yorkshire Hospitals NHS Trust

Introduction

NICE guidance (MTG27) published in 2015 advocates the use of Shear Wave Elastography (SWE) in liver disease. In our population SWE is used in preference to performing liver biopsies to assess the presence and degree of fibrosis within the liver.

Up until 2014 only one ultrasound manufacturer was available for SWE. Since then alternative systems are available and a new machine was purchased locally in 2015. However, in this institution all the experience and previous data has been collected using the original manufacturer.

Aims

The aim of this study is to determine any level of variation in shear wave readings between two different ultrasound systems that are commercially available to undertake elastography assessment of the liver.

The secondary objective is to assess if the same correlation between the shear wave readings of the current machine in use and the clinical assessment can be determined using the new ultrasound system

Methods

70 patients have been recruited into this study. This represents 10% of the average number of referrals for this procedure received per year. All patients attended a one-stop hepatology clinic which includes clinical assessments, liver ultrasound imaging and Doppler assessment and SWE. All patients had a second SWE assessment performed on the new machine.

Statistical analysis

Data collection has been completed and is being analysed.

Analysis of the data includes:

- comparison of shear wave readings from both machines
- correlation of shear wave readings from both machines and the clinical assessment
- correlation of shear wave readings from both machines and the liver function tests

Results

Early preliminary results suggest that there is mild / weak correlation between the two machines ($R^2 = 0.259$ where a strong correlation exists if $R^2 > 0.6$)

The differences between the two machines are less if a correction factor is applied of Machine a = (Machine b - 1.05) / 0.35. Our statistical analysis continues.

Contrast enhanced ultrasound (CEUS) imaging of focal liver lesions at a single centre: Initial experience,

M Thyoka, J Wild, M Hood, C Clout, Sheffield Teaching Hospitals,

Background and purpose:

Contrast-enhanced ultrasound (CEUS) using sonovue microbubbles has been used in our unit to further characterise indeterminate focal liver lesions (FLL) since 2011.

The aims of our study were to

1. audit CEUS imaging against standards defined by NICE CEUS guidelines and
2. to optimise the clinical referral pathway for this service.

Materials and methods:

An audit (no. 7468) of all consecutive patients undergoing CEUS imaging (Sonovue microbubble) at Northern General Hospital between 2011 and 2016, using standards from national guidelines (NICE). Consent for CEUS examinations was obtained from patients prior to standard multiphase CEUS examination. Patients were eligible for CEUS to further characterise indeterminate focal liver lesion (FLL) seen on grey-scale sonographic imaging. CEUS findings were compared to reference imaging findings and in those lesions deemed benign, follow up imaging was advocated to confirm stability. Adverse contrast-related reactions were recorded.

Results:

38 (69%) out of 55 patients who were referred for CEUS examination underwent CEUS imaging. 20 (53%) of these were male and the median age at time of imaging was 56.5 (23.4 - 86.5) years. CEUS findings were benign in 79% (n=30), malignant in 13% (n=5) and inconclusive in 8% (n=3). Most of the FLLs were in the right lobe of the liver (n=20, 53%). The median size of the FLL was 1.7 (0.8-7.6) cm. Reference imaging (MRI or CT) was undertaken in 26/38 (68%) following CEUS, agreement was present in 17/18 (94%) benign and 5/5 (100%) malignant lesions. All inconclusive findings on CEUS were benign on reference imaging. CEUS imaging had sensitivity of 91%, specificity 50%, positive predictive value 95%, and negative predictive value 33%.

Conclusion:

CEUS is a highly sensitive adjunctive tool in the characterisation of indeterminate grey-scale sonography FLL potentially obviating the need for exposure to ionizing radiation in lesions characterised as benign.

Point of care ultrasound: Are we practicing safely?, A Weerasinghe¹, A McGuinness¹, P Tung¹, C Mapatuna², Z Ahmed³, ¹Mid Yorkshire Hospitals NHS Trust, ²Calderdale and Huddersfield NHS Foundation Trust, ³Airedale NHS Foundation Trust

Introduction

Clinicians increasingly use Point of Care Ultrasound (PoCUS) to facilitate clinical decision-making. However little is known about the scale of usage of PoCUS and its governance.

Methodology

We conducted a survey among Yorkshire and Humber region Emergency Departments (EDs) looking in to the above. The questionnaire comprised of questions related to usage and governance.

Results

72.22 % (13/18) EDs responded to the survey. All EDs have ultrasound machines with M & B modes with colour doppler. Every department uses PoCUS for FAST, AAA, ECHO in life support and Central & Peripheral vascular access. Around 50% utilise PoCUS for foreign body removal, shock assessment and DVT diagnosis while 30-40% use it for regional anaesthesia and hepato-biliary studies.

54% (7/13) of the departments have a dedicated PoCUS lead. Only 30% (4/13) of departments store the images in PACS and the rest, store them either on the ultrasound machine hard drive or as thermal prints. 77% (10/13) record the report directly on patient notes while 31% (4/13) record them on templates.

ABSTRACTS

70% (9/13) of the departments do not have built in “safety net” and 30% (4/13) have a safety net where non-signed off operators’ scans are supervised immediately or reviewed on a later date by a Level 1 or 2 accredited operator. Only 23% (3/10) have an audit process in place and only 38% (5/13) has a written policy/ guideline on governance on PoCUS in ED.

Conclusion

Our survey shows that PoCUS is widely used by Emergency Physicians in the region. It also highlights the deficiencies and inconsistencies around governance. We feel this need to be urgently addressed to ensure the safe use of PoCUS. Our ED has developed a Clinical Governance Policy for PoCUS and in the process of developing a Trust Policy to include all clinicians undertaking PoCUS in their clinical practice.

SMI in the GIT, N Grunshaw, University Hospital Morecambe Bay NHS Trust

Background

SMI (Superb Micro-vascular Imaging Toshiba Medical Systems) is an innovative ultrasound Doppler technique with the ability to visualise minute vessels with slow velocity without use of micro bubble contrast agent.

Case report

Over a 6 month period 30 gastrointestinal cases were examined using SMI. These included appendicitis, Crohns disease, Ulcerative and ischaemic colitis, infective ileitis and tumours. Comparison was made with conventional Doppler/ microbubble contrast examination and cross sectional imaging

Discussion

SMI appears to offer useful additional diagnostic information in a number of gastrointestinal conditions particularly in distinguishing active from fibrostenotic Crohns disease, ischaemic from other forms of acute colitides and offering useful additional diagnostic information in equivocal appendicitis. Its wider adoption may obviate the need for contrast microbubble examination in some cases.

Professional Issues

Sonographer workforce survey, S Morrissey, Mid Yorkshire Hospitals NHS Trust

Background and Purpose

There is currently a local, regional and national shortage of Sonographers with most hospitals experiencing vacancies which they cannot fill. (SoR: Society of Radiographers, 2011) There is an unfilled vacancy rate of 11% (Migration Advisory Committee: MAC, 2015) Increasingly hospitals are having to rely on agencies to provide Sonographers to maintain the ultrasound service.

The aim of this study is to ascertain the opinions of Advanced Practitioner Sonographers (APS) nationally, with the view to improve retention within NHS:

- Why do APS stay or leave?
- Views of Sonographers on NHS as employers
- What is important in their jobs,
- Comparing views of staff:
- that have or have not considered leaving their jobs within the last 6 months
- Individuals who have left the NHS to work in the private sector.

Methods used

Quantitative approach to collect primary data using a web based online survey completed by APS. Recruited into study via SCOR, BMUS, CASE accredited ultrasound course leads, mail shot to every ultrasound department in country enclosing a poster, contacting agencies also utilising social media LinkedIn, Twitter and Facebook.

Results

422 responses from APS nationally. 330 APS working for the NHS, 31 students and 61 non NHS Sonographers across all ages and stages of their career with a wide national distribution.

Conclusions

Dissatisfied APS being pushed away from NHS, rather than pulled by agencies.

Driving factor not more money in private sector, but other causes of dissatisfaction within departments and NHS which may require addressing.

Issues around; poor management, working hours, lack of support, RSI issues, workload, not feeling appreciated or valued, lack of training and CPD opportunities, lack of clinical career progression opportunities.

Look into ways to motivate and support staff to improve retention within the NHS.

Growing capacity for sonographer training: Rethinking clinical academic partnership, H Venables¹, A Ferguson²,
¹University of Derby, ²Derby Teaching Hospitals NHS Trust

Background

In response to the well-documented shortage of sonographers in the UK, it is clear that education providers need to increase student numbers. Multiple alternative models for sonographer training have been proposed. However, all are constrained by limited clinical placement capacity. It is therefore imperative that HEIs and clinical providers explore alternative ways of working that increase training capacity and reduce pressure on clinical departments, without compromising quality of patient care, student experience or outcome.

Case Report

The University of Derby and Derby Teaching Hospitals NHS Trust are working in partnership to establish a sustainable approach to sonographer recruitment and training. This will be evaluated as a possible model for adoption by other Trusts within the region.

Following successful validation and CASE accreditation of a full-time graduate entry MSc Ultrasound programme in 2016, the Derby Trust and University have worked closely to develop innovative systems for student recruitment, funding, induction and work based learning.

Key features include:

- Direct financial sponsorship of full-time students by the Trust
- A rigorous values based clinical-academic selection process
- Guaranteed employment for graduates on completion of training
- Increased on-campus support for practical skills development including:
- Extensive use of state of the art simulation
- Dedicated training lists through establishment of an on-campus satellite clinical ultrasound service
- Simulation using experts by experience

Discussion

Following extensive consultation with key regional stakeholders across the East Midlands, graduate entry emerged as a preferred option to meet regional training needs. Changes to funding arrangements mean that direct entrants to the programme will be full time students of the University. This shift in 'ownership' of future applicants changes fundamentally the relationship between HEIs and placement providers. The challenges and opportunities of this shifting relationship will be explored and local initiatives reviewed.

Vascular

Case Study; A leaking abdominal aortic aneurysm, S Dunne, Maidstone and Tunbridge Wells NHS Trust

Introduction

This is a case study of an 88 year old man with a known abdominal aortic aneurysm (AAA) who presented for a routine haematuria one stop clinic ultrasound examination. He had microscopic haematuria but was otherwise asymptomatic for a leaking AAA. On examination the aneurysm appeared to be leaking into the abdomen.

Method

The abdominal aorta and both kidneys are routinely scanned on haematuria one stop clinic patients. A curvilinear 5 MHz ultrasound probe was used to examine the patient's abdominal aorta and both kidneys following department protocol and guidelines.

ABSTRACTS

Results

On examination there was an abdominal aortic aneurysm measuring up to 6.7cm x 5.4cm. Posteriorly and to the left side there appeared to be an active leak with a 6 cm haematoma within the muscle. The patient was immediately taken for a contrast CT angiogram where the leak was considered to be contained but had the potential for catastrophic leak. The aneurysm was infrarenal with atheromatous narrowing of both renal arteries and the aneurysm extended to the bifurcation. This patient had a severe life threatening abnormality which required immediate action. The relevant on call emergency team were contacted and the patient was transferred for immediate surgery at a London Hospital.

Conclusion

The routine examination of the abdominal aorta with ultrasound has the potential to identify asymptomatic severe or life threatening aortic aneurysms. Ultrasound can detect a suspected leaking aortic aneurysm which can be confirmed with CT. The ultrasound images acquired on this patient demonstrate the potential of ultrasound to incidentally identify life threatening conditions in asymptomatic patients.

EVAR follow-up with ultrasound: 6 years of experience in York, M Nicholls, G Johnson, M Crowe, L Patrick, York Teaching Hospitals NHS Foundation Trust

Background and Purpose

Follow-up after Endovascular Aneurysm Repair (EVAR) has traditionally used annual contrast enhanced CT (CECT). With increasing concerns for cumulative radiation dose and potential ionic contrast induced renal impairment, alternate modalities have been sought and investigated. In 2010, York Hospital initiated a follow-up program to replace the annual CT with an annual ultrasound and plain radiograph (AXR) in suitable patients.

Methods

From January 2010, all patients undergoing EVAR have been followed-up with a CECT, AXR and abdominal ultrasound at 1 month following stent-graft implantation. If the results of these are satisfactory and there is no evidence of significant endoleak or other complication, a decision is made to convert to ultrasound and AXR for the examination at 1 year post implantation and annually thereafter. If there is a significant finding, the ultrasound can be complemented by contrast enhanced ultrasound (CEUS) before moving on to CT or catheter angiography if required. A retrospective review of the 6 years of data (up to January 2016) has been performed.

Results

- 215 EVAR stent-grafts have been implanted between Jan 2010 and Dec 2015.
- 44 have subsequently died (most unrelated to EVAR or subsequent complications).
- 3 have moved out of the region covered by the York Trust.
- 168 remain within the follow-up system to date.
- 83 (49%) receive ultrasound and AXR follow-up.
- 72 (43%) receive CT follow-up.
- 13 have not reached their annual follow-up yet.

Conclusion

Conversion of half of our follow-up to ultrasound has so far proved successful, exposing the patients to less radiation and less nephrotoxic risk. Close scrutiny of the ultrasound results is required as Type 2 endoleaks are often difficult to find on ultrasound alone but with the addition of CEUS for problem solving in the event of an increasing sac size, significant endoleaks can be diagnosed.

A strong arm leads to a weak point: The role of ultrasound in the diagnosis of upper extremity deep vein thrombosis, K Cronin^{1,2}, A Kelly², M Stanton¹, T Herlihy¹, ¹University College Dublin, ²St. Vincent's University Hospital, Dublin

Background

Paget-Schroetter syndrome is the spontaneous thrombosis of the axillary/subclavian vein. It is a rare disorder (2 per 100,000 persons per year). It occurs predominately in young, otherwise healthy and fit people who participate in repetitive upper extremity activity. The underlying mechanisms of such thrombosis are thought to be a venous compressive anomaly at the thoracic outlet or intimal damage due to a strain at the subclavian and axillary veins by retroversion or hyperabduction. Typical movements like this occur during sporting activities such as rowing, stick and racket sports or weight-lifting. In this case the patient, a 17 year old female who frequented the gym on a regular basis for weight lifting activities presented to the Emergency Department with a 3 day history of severe arm swelling. The patient had no history of trauma, was currently on no medication and had a negative history of venous thrombosis.

Ultrasound Findings

Colour Doppler ultrasound is a rapid, accurate, and non-invasive technique used in the evaluation of upper extremity deep vein thrombosis. Depending where the thrombus forms may require the sonographer to manipulate the arm and reproduce vascular compromise. In this case study, when the subclavian vein was augmented stasis was noted rather than an occluded vessel. The stasis prompted an examination of the vessel proximally. The sonographer asked the patient to elevate their arm resulting in thrombus moving from beneath the clavicle.

B-mode ultrasound illustrated a rouleaux formation indicating slow flow within the subclavian vein. When colour Doppler ultrasound was utilized it highlighted stasis rather than occlusion within the vessel. Once the patient elevated her arm, under B mode ultrasound, a fresh clot was seen moving from beneath the clavicle.

Discussion

Paget-Schroetter syndrome is rare venous condition. However it has potential for significant morbidity and can cause a potentially fatal complication. Timely, accurate clinical recognition of the signs and symptoms is crucial to facilitate an appropriate medical referral and treatment. Duplex ultrasound is the leading imaging tool in diagnosing and monitoring venous disease in the upper extremity and a skilled sonographer can play a vital role in the rapid diagnosis of Paget-Schroetter syndrome.

Reliability of Doppler velocities across a new vascular network, M McKenna, T Robinson, University Bristol Hospital Trust

Objective: To investigate the inter-machine and operator variability across a new vascular network and identify if this could have an impact on grading a carotid stenosis.

Methods:

Firstly, a calibrated string phantom was used to determine Doppler velocities from 13 machines across 4 hospital trusts in the Bristol, Bath and Weston network. The machines were tested at five different constant velocities with an insonation angle of 60°. Secondly, 15 vascular scientists across the network measured the peak systolic velocity (PSV) of the internal (ICA) and common carotid artery (CCA) in a controlled healthy subject, using the same portable machine. Thirdly, a retrospective study examined the velocity and grading agreement of diagnostic and pre-operative scans in 29 patients with an ICA stenosis of >50%.

Results:

On average the machines overestimated the string phantom velocity by 13% ± 2%. The inter-operator study revealed the subject's PSV varied significantly more than the operators' variability. Although the retrospective study showed some variability in velocity and grading agreement, there was 100% agreement that stenoses were >50%.

Conclusion:

Although the machines in the network overestimated the Doppler velocities by 13% ± 2%, this is actually lower than other published results (15-25%). This study also highlighted the difficulty in using a test subject to accurately determine the inter-operator variability. However, the retrospective study supported the conclusion that despite machine and operator variability the treatment decision was not affected.

ABSTRACTS

Early detection of atherosclerosis using non-invasive high-frequency preclinical ultrasound imaging, J Janus¹; B Kanber³; E Karamanavi^{1,2}, K Ramnarine³, N Samani^{1,2}, E Stringer^{1,2}, M Kelly¹, ¹University of Leicester, ²Glenfield General Hospital, Leicester, ³University Hospitals of Leicester NHS Trust

Purpose:

Early detection of vascular alterations associated with atherosclerosis can play a key role in diagnosis and evaluation of treatment strategies. The aim of this pilot study was to investigate the ability of in-vivo preclinical ultrasound to detect vascular alterations in transgenic mice predisposed to atherosclerosis.

Methods:

Male feline sarcoma wildtype (FES+/+) and null (FES-/-) mice were fed a high-fat western diet for 12 weeks in order to increase the degree of atherosclerosis formation for the study. B-mode ultrasound images of the aortic arch of 11 mice were acquired using a Vevo 2100 preclinical ultrasound scanner (VisualSonics Inc) equipped with a high-frequency transducer (20-30MHz). Arterial distension was assessed using an image processing algorithm developed in Matlab (Version 7.14, Mathworks) to track aortic wall motion over the cardiac cycle. Distension was calculated from the percent change in lumen diameter from peak systole to peak diastole and was used as a marker of the ability of vessels to expand and contract with cardiac pulsation. Additionally, micro-dissection of the heart and aorta tissues was performed for histological analysis.

Results:

The results from this preliminary study confirm that percent distension is inversely correlated with the degree of atherosclerotic plaque formation assessed post mortem. Mean arterial distension was significantly lower in FES-/- mice (26%) compared to FES +/+mice (31%).

Conclusions:

This pilot study demonstrates the potential of preclinical ultrasound to detect arterial stiffening due to atherosclerosis. This method can be applied in future studies aimed.

BMUS would like to express its grateful thanks to the following companies for their support of Ultrasound 2016

BK Ultrasound

MIS Healthcare

Bowen Therapy

Multi-Medix Ltd

Bracco UK Ltd

Nanosonics

Carestream

PFE Medical

Casmed International Ltd

Philips Healthcare

Diagnostic Healthcare

Physiological measurements

Esaote

RH Logistics

GE Healthcare

Rothband

Globe Locums

Sanctuary Health

Hitachi Medical Systems Ltd

Siemens Healthineers

Imaging First

Supersonic Imagine

InHealth

The College of Radiographers

Medaphor

TICCS Ultrasound Services

Mid Central Health Board

Toshiba Medical Systems Ltd

Mindray

Tristel

BMUS 

BMUS

Ultrasound 2017

6 - 8th December 2017
Cheltenham Racecourse

www.bmus.org



BMUS 2017 will have something for all ultrasound practitioners including;

- ❖ General Ultrasound
- ❖ Obstetric Ultrasound
- ❖ Gynaecological Ultrasound
- ❖ Musculo-skeletal ultrasound
- ❖ Vascular ultrasound
- ❖ Physics
- ❖ Professional Issues
- ❖ Current controversies in medical ultrasound
- ❖ Practical skills sessions



Mobility at your Fingertips

Performance | Operability | Compact Design

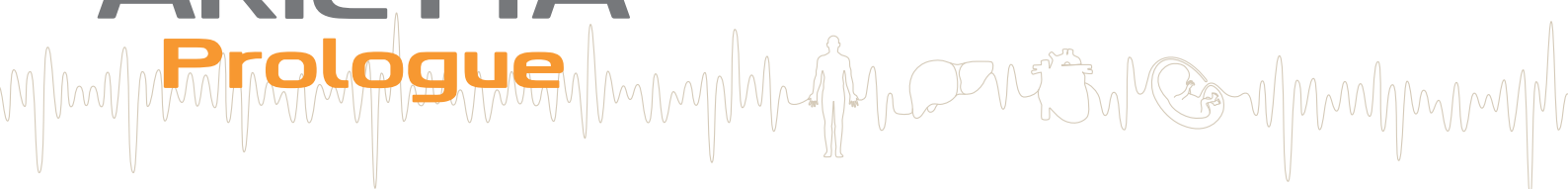

The new tablet-based ultrasound system

The ARIETTA Prologue provides fast access to high resolution ultrasound imaging for a broad range of applications.

ARIETTA

Prologue



Visit us at **BMUS ASM 2016, York**
7 - 9 December 2016
Hitachi Medical Systems Booth 1