

# BMUS

## ULTRASOUND 2022

53RD ANNUAL SCIENTIFIC MEETING OF THE  
BRITISH MEDICAL ULTRASOUND SOCIETY

**City Hall, Cardiff**

**6th - 8th December**



# WELCOME

We are delighted to welcome you to Cardiff for the 53rd British Medical Ultrasound Annual Scientific Meeting (BMUS ASM) at Cardiff City Hall. The capital of Wales, Caerdydd (Cardiff) is steeped in history dating back to 6000BC, while the BMUS ASM brings cutting edge technology and experts in medical ultrasound together to provide progressive medical ultrasound education.

The programme is built around the conference theme 'Leading Ultrasound into the future' with the aim of not only providing the established high quality ultrasound education but thinking about the changing landscape of ultrasound through technology, education and guidelines and our role in this.

The highlight of the conference is the Donald MacVicar Brown keynote lecture which this year will be delivered by the eminent Dr Simon Freeman, a Consultant Radiologist at University Hospitals Plymouth NHS Trust and former BMUS president, with expertise in the area of urology and ultrasound contrast agents.

There is plenty to see and do as always, with lectures, workshops and debates to get involved in. This year also sees the continuing appearance of the student and trainee stream and veterinary ultrasound. BMUS is excited to see the introduction of Sessions on Point of Care Ultrasound to the main educational streams.

The technical exhibition is always a highlight of the BMUS ASM. The ultrasound manufacturers/companies will be there in support of the ultrasound community with technology, products and education creating the infamous welcoming and lively atmosphere of the BMUS ASM conference.

There are many 'thank-you's' that should be given but firstly to the delegates for your continuing support and attendance which makes BMUS successful in its aims each year. To the stream leads and members of the Scientific and Education Committee whose dedication, enthusiasm and expertise ensures that BMUS continues year on year to deliver high quality ultrasound education. Finally, to Emma Tucker and the BMUS Office Team – their commitment to the BMUS education cause is unyielding and their exemplary event organisational skills ensure the meeting is a success.

**So, Welcome to Cardiff and the 2022 BMUS ASM – Enjoy the meeting!**

## Ben Stenberg

Chair, Annual Scientific Meeting Organising Committee 2022

BMUS would like to thank the following members of the BMUS Education Group, the 2022 Scientific Organising Committee and staff for their contribution and delivery of the 2022 education programmes.

Dr Peter Cantin, *Plymouth*  
 Dr Trish Chudleigh, *Cambridge*  
 Mr Mark Charnock, *Sheffield*  
 Mr Kevin Cronin, *Dublin*  
 Mrs Tanyah Ewen, *Peterborough*  
 Mrs Alison Hall, *Stafford*  
 Mrs Terry Humphrey, *Leeds*  
 Prof Robert Jarman, *Newcastle upon Tyne*  
 Mrs Catherine Kirkpatrick, *Lincoln*  
 Dr Jeannette Kraft, *Leeds*  
 Prof Adrian Lim, *London*  
 Mrs Angie Lloyd-Jones, *Runcorn*  
 Dr Carmel Moran, *Edinburgh*  
 Mrs Pamela Parker, *Hull*

Mrs Amanda Parry, *Derby*  
 Mrs Rita Philips, *Bristol*  
 Mrs Ruth Reeve, *Portchester*  
 Ms Alison Smith, *London*  
 Miss Shaunna Smith, *Hull*  
 Mrs Cathy Steward, *Marlow*  
 Prof Gail ter Haar, *London*  
 Dr Barry Ward, *Newcastle*  
 Mrs Patsy Amegabor (*Events Assistant*)  
 Mrs Tracey Clarke (*BMUS Office Administrator*)  
 Mrs Hazel Edwards (*BMUS Professional Officer*)  
 Miss Jane McNulty (*BMUS Events & Marketing Coordinator*)  
 Miss Emma Tucker (*BMUS Operations and Development Manager*)  
 Mrs Joy Whyte (*BMUS Finance Officer*)



# DEEPINSIGHT™ TECHNOLOGY

*Offering clarity at depth with ultimate image quality*



*Featuring*  
**ARIETTA 850™**  
*with NEW*  
**Noise Reduction**  
**Technology**

*Visit us at*  
**BMUS**   
**STAND 1**

**FUJIFILM**  
Value from Innovation

# CONTENTS



## Information

General Information	6 - 7
Ultrasound 2022 Conference App	8
CPD and Feedback	8

## Scientific Programme

Day 1 – Tuesday 6th December 2022	18 - 27
Day 2 – Wednesday 7th December 2022	30 - 39
Day 3 – Thursday 8th December 2022	42 - 50
2022 Keynote Lectures:	
• Donald MacVicar Brown – Tuesday 6th December 2022	13
2022 Young Investigator Session	15 - 16
Poster Exhibition	53 - 81
Proceedings	98 - 121

## Social Events

Welcome Reception – Tuesday 6th December 2022	21
Winter Ball and Awards Ceremony – Wednesday 7th December 2022	40
• Sonographer of the Year Award 2022	28

## Technical Exhibition

List of Exhibitors	10
Exhibition Plan	11
Education on the Stand	12
Exhibitor Profiles	83 - 96

## Future Events

BMUS Study Days 2022	80
Annual Scientific Meeting 2023	126



# GENERAL INFORMATION

## CONFERENCE TIMES

---

### Tuesday 6th December

09.15 President's Welcome

09:30 - 17:00 Scientific Sessions

17:00 Welcome Reception, Exhibition Hall, Lower Hall

### Wednesday 7th December

08.30 -16.30 Scientific Sessions

19.00 BMUS Winter Ball and Awards Ceremony, The Assembly Room, Cardiff City Hall, Cathays Park, Cardiff CF10 3ND

### Thursday 8th December

09:00 -16:00 Scientific Sessions

## DELEGATE BADGES

---

Attendees are required to wear their badges at all times to gain access to any part of the event. Access to the practical training sessions is via the appropriate wristband which will be in your delegate pack.

**NB.** Should you have booked to attend one of the specific education sessions i.e Student Focussed Day, ThUNDDAR Day or the Veterinary Day, your badge will not allow you to attend any of the main programme general education sessions.

*Please leave your badges at the registration desk at the end of your meeting attendance in order that these can be recycled*

## CONTINUING PROFESSIONAL DEVELOPMENT (CPD)

---

The meeting has been awarded the following BMUS CPD credits and Category I RCR CPD credits

All 3 days- 21 credits

Day 1 - 7 credits

Day 2 - 7 credits

Day 3 - 7 credits

CPD certificates will be provided in an e-format by 31st January on completion of the online feedback form.

## FEEDBACK

---

Feedback will be collected via completion of an electronic feedback form which will be sent to delegates at the end of their attendance at the meeting, the online feedback form will also be available on the 2022 Conference App to complete. BMUS would be grateful if delegates would take time to complete these forms, as the feedback forms helps the preparation of future meetings.

## CATERING AND REFRESHMENTS

---

Lunches and refreshments are included in the registration fee. Catering and coffee points are located in the Exhibition Hall

## CLOAKROOM

---

A manned cloakroom is located on the ground floor left of the foyer area. Please do not leave bags or personal items unattended whilst attending the conference. While every effort is made to keep your belongings secure, neither Cardiff City Hall or BMUS can be held liable for any loss of damage.

## WiFi

---

Free WiFi is available throughout the venue. Once inside the venue please connect to Cardiff free WiFi

## SOCIAL MEDIA

---

We will be updating our social media throughout the conference. Our hashtag is #Ultrasound2022 - feel free to get tweeting and posting!

Our Twitter handle is @BMUS\_Ultrasound

Our Facebook page is BMUS (British Medical Soc)

# GENERAL INFORMATION

## GENERAL DATA PROTECTION REGULATIONS

BMUS takes its responsibility in respect of your personal information seriously, and all information given at the time of registration is treated as confidential and will not be divulged to third parties without your permission.

However, the BMUS Event App offers the facility for data capture, this information is limited to the delegate's name, workplace and e-mail address. If you do not wish to share your personal information, you should NOT allow your QR code within the app to be scanned.

*It must be noted that by permitting your app QR code to be scanned, you are giving permission for your personal information to be accessed and processed.*

## PHOTOGRAPHY

Please be aware that during the event BMUS employs a photographer to take images for later publication in our BMUS newsletter, e-Newsletter Ultrapost and on the BMUS website.



# THE ULTRASOUND APP 2022

## Download the Ultrasound 2022 App to enhance your conference experience

The App is freely available and will help you get the most out of your time at Ultrasound 2022

### The Ultrasound 2022 App includes

- Interactive Scientific Programme
- Details on the exhibition and the companies in attendance
- Ability to create personalised agendas
- Ability to download electronic copies of the posters and abstracts
- An Exhibition floor plan
- Access to BMUS Twitter and Facebook feeds
- Access to the feedback survey

Scan here to download the app

Or go to <https://meetings.bmus.org/>



**IOS** - Once open tap the share icon at the bottom of the screen. Scroll down the list and tap *Add to Home Screen*.

**Android** - Once open tap the three dot menu option and select *Add to Homescreen*.

### BMUS Members Login

Log in using the email address of your BMUS membership and your password. Once you log in to the app it will retain your details so you can open it without logging in each time.

### Non-Members Login

Login using the email address you used to register and the password: **BmusASM2022**. Once you log in to the app it will retain your details so you can open it without logging in each time.

## ASM DELEGATE FEEDBACK AND CPD POINTS

This year BMUS will be collecting delegate feedback through the BMUS App. You can access this either through the BMUS conference app or via an email that will be sent to you during the conference. We are keen to collect feedback on all aspects of the Annual Scientific Meeting and have produced a comprehensive set of questions covering each session. Please take some time to complete this as it will be used to inform future events.

Once we have received your feedback survey your CPD certificate will be issued from the BMUS office. CPD certificates will only be issued to surveys that are fully complete. You should receive your CPD certificate by the end of January. The feedback survey will close midnight on 8th January 2022.

### The feedback we receive will help us to;

- Prepare future events
- Provide constructive feedback to our speakers
- Feedback to the venue
- Measure the success and value of the ASM

Thank you in advance for taking the time to complete the feedback questionnaire. If you have any problems please email [emma@bmus.org](mailto:emma@bmus.org).



**BMUS would like to express its grateful thanks to the following companies for their support of Ultrasound 2022**

**Advanced Ultrasound Electronics**

**Bowen Therapy**

**Bracco**

**Canon**

**Casmed**

**Celtic SMR Ltd**

**Diagnostic Healthcare**

**EasyPay**

**Esaote**

**Fujifilm**

**Focused Ultrasound Foundation**

**GE Healthcare**

**Germitec**

**Globe Locum**

**Imagex Medical**

**Intelligent Ultrasound**

**Lablogic**

**Lumicare**

**MIS Healthcare**

**Multi-Medix**

**Nanosonics**

**Peninsular Medical**

**Philips**

**Physiological Measurements**

**Probo Medical**

**RH Logistics Part of the Bomi Group**

**Siemens**

**The Society and College of Radiographers**

**UKAS**



# LIST OF EXHIBITORS

## 2022

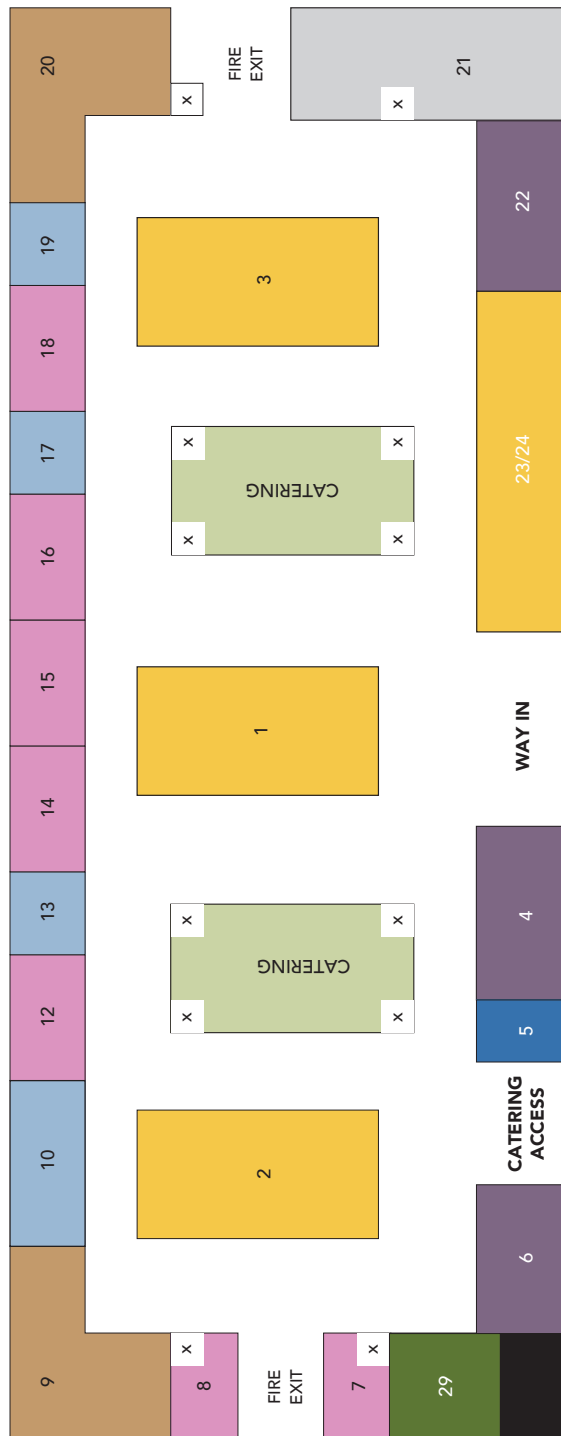
### Main Exhibition Hall

**STAND NUMBER      COMPANY**

1	FujiFilm
2	MIS Healthcare
3	Canon Medical Systems
4	Intelligent Ultrasound
5	Probo Medical
6	ImageXMedical
7	Diagnostic Healthcare
8	Nanosonics
9	Esaote
10 - 11	Lablogic
12	Tristel Solutions
13	Globe Locums
14	Multi-Medix
15	Lumicare
16	The Society and College of Radiographers
17	Penninsular Medical
18	Bracco
19	Germitec
20	Siemens
21	Philips
22	Physiological Measurements Ltd
23 - 24	GE Healthcare
25	AUE
26	EasyPay
27	UKAS
28	Celtic SMR Ltd
29	Casmed

# TECHNICAL EXHIBITION FLOOR PLAN 2022

53rd Annual Scientific Meeting of the British Medical Ultrasound Society









# EDUCATION ON THE STAND

## Main Exhibition Hall


### Tuesday 6th December

13:10 – 13.30	<p><b>Introducing Fujifilm's latest innovation in Ultrasound, DeepInsight, our new noise reduction technology</b></p> <p>Offering unrivalled clarity at depth, with eFocusing PLUS and Carving Imaging. Combining these technologies enhances the signal from the tissues, thus aiding the Practitioner throughout the examination to achieve optimum image quality. Learn about the five essential elements of DeepInsight and how it enables you to deliver optimal ultrasound imaging during our live session.</p>	
13.30 – 13.50	<p><b>User Ultrasound QA tests – A practical introduction</b></p> <p>See how quick and easy user Quality Assurance tests really are; a few minutes is really all it takes. Join Multi-Medix for our demonstration on how to check your probes &amp; systems are defect free, safe, and compliant. Includes a free Multi-Medix test tool too!</p> <p><b>Presenters:</b> <i>Daniel Wyatt, Darren Woolley, Nick Dudley, Multi-Medix</i></p>	

### Wednesday 7th December

12.10 – 12.30	<p><b>Ultrasound Guided Intervention of the Elbow</b></p> <p><i>Thomas Armstrong, Consultant Musculoskeletal Radiologist</i></p>	
12.30 – 12.50	<p><b>Fusion in Everyday Practice</b></p> <p>An overview of liver fusion and its clinical applications</p> <p><b>Presenters:</b> <i>Dr. Andrew McNeill - Consultant Radiologist, Freeman Hospital, Newcastle upon Tyne NHS Hospitals Trust</i></p>	

### Thursday 8th December

13:15 – 13.35	<p><b>How to Diagnose Endometriosis,</b></p> <p>This session is to give you an understanding of how to diagnose Endometriosis on Ultrasound</p> <p><b>Presenters:</b> <i>Dr Susanne Johnson, Princess Anne Hospital, University Hospital Southampton NHS Trust</i></p>	
---------------	--	---

# KEYNOTE LECTURE

## 2022

### Donald MacVicar Brown Lecture

The Donald MacVicar Brown Lecture has been a fixture of the Annual Scientific Meeting since 1996. This keynote Lecture commemorates and celebrates the origins of medical ultrasound.



Dr Simon Freeman

This plenary keynote lecture honours the 1958 publication of the Ian Donald, John MacVicar and Tom Brown paper in the British journal 'The Lancet'. Their paper - 'Investigation of Abdominal Masses by Pulsed Ultrasound' - is credited with transforming maternity care. The lecture is delivered by an invited speaker, recognised by BMUS for their inspirational work and contribution to medical ultrasound practice.

This year the lecture is delivered by Doctor Simon Freeman, and is entitled 'Only good for gallstones and gynaecology: Can we reverse the decline and fall of ultrasound in radiology?'

Dr Simon Freeman is a Consultant Radiologist at University Hospitals Plymouth NHS Trust and is one of the few remaining UK radiologists with a main subspecialist interest in non-obstetric ultrasound. He graduated from Middlesex Hospital Medical School and, after spending six years working in internal medicine, began his training in radiology in Bristol in 1991. Following a radiology fellowship in Leeds he was appointed to his current post in Plymouth in 1997. He has a varied ultrasound practice but with particular interests in uroradiology and ultrasound contrast agents.

Simon has been a BMUS member for 25 years and worked for BMUS in many roles ultimately becoming Society President during 2017 and 2018. He has been a subcommittee member for the European Society of Urogenital Radiology (ESUR) and guideline author for the European Federation of Societies for Ultrasound in Medicine and Biology (EFSUMB) and World Federation for Ultrasound in Medicine and Biology (WFUMB). His research interests are predominantly related to ultrasound and uroradiology with more than seventy publications in peer-review journals. He is a regularly invited speaker at national and international conferences.

When not at work Simon is an enthusiastic, and occasionally successful, baker of artisan bread, member of a male voice choir and entirely mediocre golfer.

**Sponsored by Canon Medical Systems Ltd**



# YOUNG INVESTIGATOR SESSION

---





# YOUNG INVESTIGATOR SESSION

## 2022

The young investigator session is a showcase of the best abstracts submitted by authors who are 39 years old or younger. The best presentation from this session wins the BMUS Young Investigator of the Year Award and is given the opportunity to present their work on behalf of BMUS at the 2023 Euroson Meeting being held in Latvia, Riga.

### Lauren Gilmour



**The effect of suspension medium on the ultrasound backscatter signature of microbubbles within a flow phantom**

Lauren is a PhD student at the University of Strathclyde in Glasgow. Her research is focused on the behaviour of microbubbles (aka ultrasound contrast agents) to better understand their potential as a drug delivery tool. She is interested in the use of 3D printing to develop more customisable lab-based experimental systems that allow ultrasound and microbubble interactions to be studied in a controlled environment. Lauren is also interested in the cellular compatibility of materials used in ultrasound research and in biomedical research more broadly.

### Catherine Lee



**Sonographer led discharge in a deep vein thrombosis clinic; a feasibility study**

After discovering Radiography during her work as a porter, Cat obtained her BSc in Diagnostic Radiography in 2005. She gained experience as a newly qualified Radiographer before deploying with the TA to Afghanistan to a field hospital. She then completed her PG Dip in Ultrasound and is now an Advanced Practice Sonographer in intervention. She has finished her MSc in Medical Ultrasound with UWE and is now completing a MSc Degree Apprenticeship in Advanced Clinical Practice at the University of Exeter. She is the Vice Chair of the Society of Radiographers' Ultrasound Advisory Group and an assessor for QSI. Also a Morris dancer, but don't hold that against her.

## Wael Faqihi



**Prediction of arteriovenous fistula maturation outcomes in end-stage renal disease patients, using invasive and non-invasive techniques: Pilot study**

---

My name is Wael Faqihi, a PhD candidate at Vascular Surgery Dept Imperial College London and Clinical Vascular Scientist Fellow at Hammersmith Hospital. My research work focuses on AVF surveillance. In 2013, I was awarded BSc in Radiology from the College of Medical applied Sciences - Najran University. Then I started working as a teaching assistant at the same college. Later, I was promoted to Medical Ultrasound Lecturer after I graduated from Imperial College London in 2017 with MSc&DIC in Medical Ultrasound..

## Adam Morell



**The first 5 targeted trans-perineal prostate biopsies diagnose the majority of PROMIS criteria cancer in patients with a Likert 4 or 5 score on mpMRI.**

---

Adam is a Consultant Sonographer at Leeds Teaching Hospitals with a specialist interest in education and interventional ultrasound.

Winner of 'Best Student Presentation' at BMUS 2019, he's hoping to rekindle that sort of form for this season.

Sponsored by Focused Ultrasound Foundation



# SCIENTIFIC PROGRAMME 2022

---

TUESDAY 6TH DECEMBER

WEDNESDAY 7TH DECEMBER


THURSDAY 8TH DECEMBER





# AT A GLANCE DAY ONE

Tuesday 6th December

Session Start Times	LECTURES				PRACTICAL SESSIONS
	Plenary 1	Plenary 2	Plenary 3	Satellite Session	
	Assembly Room	Ferrier Hall	Room L	Room B	Room C & D
09.15	President's Welcome				
09.30	General Medical and Paediatrics 1	Professional Issues 1	Medical Physics 1	Student and Trainee 1	
11.00	REFRESHMENT BREAK				
11.30	General Medical and Paediatrics 2	Professional Issues 2 BMUS Debate In the Council Chamber	Medical Physics 2	Student and Trainee 2	Bowel Master Class
13.00	LUNCH EDUCATION ON THE STAND 13.10 - FujiFilm 13.30 - Multi-Medix				
14.00	General Medical and Paediatrics 3	Professional Issues 3	Medical Physics 3	Student and Trainee 3	Obstetrics
15.30	REFRESHMENT BREAK				
16.00	<p><b>Donald MacVicar Brown Lecture</b>  <b>Doctor Simon Freeman</b>                      Only good for gallstones and gynaecology: Can we reverse the decline and fall of ultrasound in radiology?</p>  CANON MEDICAL				
17.00	END OF DAY 1				
17.00	Welcome Reception Main Exhibition				

# DAY ONE

Tuesday 6th December

## Plenary 1 - Assembly Hall

### OPENING AND PRESIDENTIAL ADDRESS

09.15 Mrs Pamela Parker, Hull University Teaching Hospitals

### ULTRASOUND IN BOWEL DISEASE

09.30 – 11.00 **Chairs:** Mrs Ruth Reeve, Portsmouth Hospitals NHS Trust, University of Southampton, Dr Jeannette Kraft, Leeds Children's Hospital

Ultrasound is becoming an increasing investigation of choice for bowel disease in both the adult and paediatric setting. This session intends on providing an overview on leading ways for the use of ultrasound in a variety of settings for bowel pathology including IBD and cancers.

- Demonstrate how ultrasound can help in the diagnosis of children with GI symptoms, discussing the ultrasound features of common pathology.
- Guide to using ultrasound in patients with IBD, principles of scanning and ultrasound features of IBD pathology.
- Guide to setting up a bowel ultrasound service in radiology departments
- Overview of ultrasound in bowel cancer, ultrasound features and the role of ultrasound in problem solving.

09.30 **Ultrasound of the acute abdomen in children**, Dr Tobi Aderotimi, Royal Alexandra Children's Hospital Brighton

09.50 **Ultrasound in Inflammatory Bowel Disease**, Dr Rose Pantan, Portsmouth Hospitals University NHS Trust

10.20 **Developing a local bowel ultrasound service**, Dr Nigel Grunshaw, Morecambe Bay NHS Trust

10.40 **Role of ultrasound in bowel cancer**, Dr Anmol Gangi, Cambridge University Hospitals

### ULTRASOUND IN RENAL DISEASE

11.30 – 13.00 **Chairs:** Dr Jeannette Kraft, Leeds Children's Hospital, Prof Adrian Lim, Imperial College London

This session provides insights into how ultrasound is used in diagnosing and managing renal disease, looking at advancing techniques and technology.

- Guide to ultrasound imaging of cystic renal disease in children and how to differentiate varying presentations.
- Guide to the types of renal diseases evaluated with ultrasound, with case reviews from multimodality assessments.
- How CEUS can be used as a first line investigation for renal cysts

11.30 **Ultrasound of paediatric cystic kidney disease**, Dr Sophie Swinson, Leeds Children's Hospital

11.55 **The role of ultrasound in a multimodality review of renal disease**, Dr Oliver Hulson, Leeds Teaching Hospitals NHS Trust

TUESDAY

WEDNESDAY

THURSDAY

# DAY ONE

Tuesday 6th December

## Plenary 1 - Assembly Hall

TUESDAY

- 12.25 **Place of ultrasound in renal cyst assessment**, Dr Roger Moshy, North West Anglia NHS Foundation Trust
- 12.40 **The first 5 targeted trans-perineal prostate biopsies diagnose the majority of PROMIS criteria cancer in patients with a Likert 4 or 5 score on mpMRI**, Adam Morrell, Leeds Teaching Hospitals NHS Trust
- 12.50 **Rare finding of occlusive thrombus of a testicular varicocele**, Amir Bennett, The Royal Free London NHS Foundation Trust and King's College London

WEDNESDAY

### ULTRASOUND IN LIVER DISEASE

- 14.00 – 15.30 **Chairs:** Mrs Ruth Reeve, Portsmouth Hospitals NHS Trust, University of Southampton, Prof Adrian Lim, Imperial College London

Liver disease is increasingly common in the adult and paediatric general population with ultrasound being the first line investigation of choice. This session provides insights into how developing technology and reporting is moving ultrasound of liver disease into the future.

- How advanced ultrasound imaging is used in paediatric liver disease.
- The role of ultrasound in screening and surveillance of liver disease.
- Radiological treatment for liver lesions, current practice and future developments.

THURSDAY

- 14.00 **Advanced ultrasound techniques in paediatric liver imaging**, Dr Annamaria Deganello, Kings College Hospital London
- 14.20 **Ultrasound in assessment of liver disease**, Dr Ed Godfrey, Cambridge University Hospitals NHS Trust
- 14.40 **HCC surveillance, the role of LIRADS**, Dr Jamie Franklin, University Hospitals Dorset
- 15.00 **Radiological liver lesion treatment options - current and future**, Dr Peter Littler, Newcastle Upon Tyne Hospitals NHS Trust
- 15.20 **Paediatric abdominal ultrasound appearances in acute hepatitis patients in a tertiary paediatric hospital**, Lorraine Walsh, Birmingham Children's Hospital

### DONALD MACVICAR BROWN LECTURE

- 16.00 – 17.00 **Chair:** Mrs Pamela Parker, Hull University Teaching Hospitals, Dr Benjamin Stenberg, Freeman Hospital

- 16.00 **Only good for gallstones and gynaecology: Can we reverse the decline and fall of ultrasound in radiology?**, Dr Simon Freeman, University Hospitals Plymouth NHS Trust

Non-obstetric ultrasound, undertaken in departments of radiology, has reached a defining moment. Although being second only to plain film radiography as the most frequently requested imaging investigation, the annual rate of growth of ultrasound is lower than for most other imaging modalities. CT, in particular, has seen unprecedented advances in technology and there is a clear trend away from ultrasound to CT as the imaging modality of choice in hospital care.

# DAY ONE

Tuesday 6th December

## Plenary 1 - Assembly Hall

The majority of the ultrasound workload is now outpatient and GP scanning where the yield of pathology is relatively low. Many referrers are suspicious of ultrasound and show a clear preference for cross-sectional imaging where they can see and understand the pathology with their own eyes. There is a danger of ultrasound becoming predominantly a niche technique in acute care and the future of ultrasound within the radiology department has never been more uncertain.

As interest in ultrasound declines in many radiology departments, and ultrasound fails to appeal to younger radiologists as a rewarding career, clinicians have abandoned their stethoscopes and turned enthusiastically to point of care ultrasound raising concerns over regulation, training and quality, potentially further undermining its reputation.

In this lecture we will review the current status of non-obstetric ultrasound, remind ourselves of the unique advantages that ultrasound possesses and consider how we can halt and reverse its decline. High quality ultrasound will be essential to deliver excellent medical care in the future NHS and it can become more important and relevant than it has ever been. All of us have the task of championing ultrasound, delivering clinically relevant reports and ensuring that we adapt to the changing needs of modern medicine. The sonographic workforce in particular must continue to step-up to the challenge presented by a declining contribution from radiologists. We must also fully embrace advances in ultrasound technology and form close collaborations with our clinical colleagues to ensure that we deliver the full potential of our chosen imaging technique.

Sponsored by Canon Medical Systems Limited

**Canon**  
CANON MEDICAL

TUESDAY

WEDNESDAY

THURSDAY

17.00

Welcome Drinks Reception in Exhibition Hall





# DAY ONE

Tuesday 6th December

## Plenary 2 - Ferrier Hall

### MAXIMISING ULTRASOUND SERVICES

- |           |               |   |
|-----------|---------------|---|
| TUESDAY   | 09.30 – 11.30 | <p><b>Chairs:</b> Mrs Catherine Kirkpatrick, United Lincolnshire Hospitals NHS Trust, Dr Peter Cantin, University Hospitals Plymouth NHS Trust</p> <p>Professional Issues sessions will focus on maximising ultrasound services. It will explore preceptorship and capability development and how it could become successfully embedded within departments. It will examine how department leaders can support more of their staff to achieve true Advanced Practitioner and Consultant level. In addition, the session will examine the practicalities of workload in addressing quantity vs quality – how do you decline the unjustified examination?</p> |
| WEDNESDAY | 09.30         | <p><b>Preceptorship and Capability Development - How do we make this a reality?</b> Dr Peter Cantin, University Hospitals Plymouth NHS Trust</p>  |
|           | 09.50         | <p><b>How can managers be supported to develop more of their staff to advanced and consultant level?</b> Mrs Pamela Parker, Hull University Teaching Hospitals</p>  |
| THURSDAY  | 10.10         | <p><b>How does the student researcher positively impact the clinical department?</b> Mrs Catriona Hynes, Sheffield Hallam University</p>  |
|           | 10.30         | <p><b>Quality versus quantity: Saying 'no' to unnecessary scans,</b> Miss Shauna Smith, Hull University Teaching Hospitals</p>  |
|           | 10.50         | <p><b>Question and Answer Session</b></p>   |

## Plenary 2 - Council Chamber

### BMUS DEBATE: WHO'S DOING YOUR SCAN? HOW DO MODELS OF ULTRASOUND SERVICE DELIVERY DIFFER IN THE UK, DENMARK AND GERMANY?

- |               |  |
|---------------|--|
| 11.30 – 13.00 | <p><b>Chair:</b> Mrs Hazel Edwards, British Medical Ultrasound Society</p> <p>The magnificent debating chamber of Cardiff City Hall provides an outstanding and perfect venue for the return of the BMUS debate.</p> |
| 11.30         | <p><b>Welcome and scene setting,</b> Mrs Hazel Edwards, British Medical Ultrasound Society</p>   |
| 11.35         | <p><b>The UK model of ultrasound service delivery, pros and cons,</b> Mrs Catherine Kirkpatrick, United Lincolnshire Hospitals NHS Trust and Prof Rhodri Evans, Withybush General Hospital</p>                       |
| 11.45         | <p><b>The Danish model of service delivery, pros and cons,</b> Dr Malene Pedersen, Vejle Hospital and Institute of Regional Health, University of Southern Denmark</p>   |
| 11.55         | <p><b>The German model of service delivery, pros and cons,</b> Dr Matthias Wüstner, Bruederkrankenhaus, Trier, Germany</p>   |
| 12.05         | <p><b>Debate</b></p>   |

# DAY ONE

Tuesday 6th December

## Plenary 2 - Ferrier Hall

### HOW DOES ULTRASOUND MOVE FORWARD IN A WORLD WITHOUT REGULATION?

- 14.00 – 15.30 **Chairs:** Mrs Hazel Edwards, British Medical Ultrasound Society, Mrs Pamela Parker, Hull University Teaching Hospitals
- 14.00 **Regulation for sonographers: What's been done so far?** Mrs Charlotte Beardmore, Society and College of Radiographers
- 14.15 **The role of the PSA in overseeing voluntary registration,** Ms Christine Braithwaite, Professional Standards Authority
- 14.30 **An ultrasound manager's perspective in employing unregulated ultrasound practitioners,** Mrs Suzanne Beattie-Jones, Royal Surrey County Hospital
- 14.50 **From concept to reality: BSc Medical Ultrasound Degree apprenticeships - a new route for sonographer education,** Catriona Hynes, Sheffield Hallam University
- 15.00 **How are BSc and apprenticeship courses affected in the absence of regulation?** Dr Trudy Sevens, Sheffield Hallam University
- 15.20 **Question and Answer: How does ultrasound move forward in a world without regulation?** Mrs Pamela Parker, Hull University Teaching Hospitals

TUESDAY

WEDNESDAY

THURSDAY

## Plenary 3 - Syndicate Room L

### NEW AND IMPROVED TECHNOLOGIES FOR MEDICAL ULTRASOUND IMAGING

- 09.30 – 11.00 **Chairs:** Dr Barry Ward, Freeman Hospital, Dr Heather Venables, University of Derby
- Over the last few years, medical ultrasound imaging has continued to develop at an astonishing rate, with exciting new technologies being introduced by start-up companies, and established technologies being further refined by the major manufacturers. This session explores some of these technologies, and explains how sonographers, radiologists and other clinicians can make use of them in their day-to-day scanning.
- 09.30 **Innovations and developments in vascular ultrasound,** Dr Kate Bryant, Cardiff and Vale University Health Board
- 10.00 **Ultrasound-mediated drug delivery - what can it offer and what progress has been made towards clinical adoption?** Dr Helen Mulvana, University of Strathclyde
- 10.30 **Ultrasound for medical therapies: From neuromodulation to thermal applications,** Dr Elly Martin, University College London

# DAY ONE

Tuesday 6th December

## Plenary 3 - Syndicate Room L

TUESDAY

WEDNESDAY

THURSDAY

### THE OLD AND THE NEW – THE PAST, PRESENT AND FUTURE OF ULTRASOUND IMAGING

11.30 – 13.00 **Chairs:** Dr Barry Ward, Freeman Hospital, Prof Carmel Moran, University of Edinburgh

Since the first ultrasonic devices were invented, over a hundred years ago, ultrasound technology has become the bedrock of an extremely wide range of medical and non-medical applications. This session looks at some of these applications, and considers what additional medical information may be available to sonographers in the very near future.

11.30 **Point-of-care ultrasound: A small revolution on a large scale**, Dr Heather Venables, University of Derby

12.00 **Ultrasound shear wave elastography: Basic physics, clinical application and performance assessment**, Dr Kumar Ramnarine, Guy's and St Thomas' NHS Foundation Trust

12.30 **Images of Langevin (1872 - 1946): Pioneer of ultrasound physics**, Dr Francis Duck, Retired

### IMAGING SAFELY AND EFFECTIVELY USING MODERN ULTRASOUND SCANNERS

14.00 – 15.30 **Chairs:** Dr Barry Ward, Freeman Hospital, Dr Kumar Ramnarine, Guy's and St Thomas' NHS Foundation Trust

As our understanding of subtle bioeffects improves and additional imaging features are integrated into new ultrasound equipment, it is vital that users have access to this information and are able to apply it during their routine daily scanning. This session provides an overview of our current knowledge of ultrasound safety, and shows how sonographers, radiologists and obstetricians can scan safely and effectively using the most up-to-date devices.

14.00 **Snap, Crackle and Pop - the safe use of ultrasonic contrast agents**, Prof Carmel Moran, University of Edinburgh

14.30 **Recent developments in ultrasound safety**, Dr Piero Miloro, National Physical Laboratory

15.00 **Modelling of diaphragm motion using 4D ultrasound**, Katy Szczepura, University of Salford

15.10 **Ultrasound QA - The good, the bad and the ugly**, Daniel Wyatt, Multi-Medix

15.20 **Development of image analysis software to enable objectivity in ultrasound quality assurance**, Guy Brown, Royal Berkshire NHS Foundation Trust

15.30 **The BMUS Historical Collection; what's in it and what's happening to it**, Prof Peter Hoskins, Retired

# DAY ONE

Tuesday 6th December

## Education On The Stand - Exhibition Hall

- 13.10** **Introducing Fujifilm's latest innovation in Ultrasound, DeepInsight, our new noise reduction technology** – Fujifilm Stand 1
- Offering unrivalled clarity at depth, with eFocusing PLUS and Carving Imaging. Combining these technologies enhances the signal from the tissues, thus aiding the Practitioner throughout the examination to achieve optimum image quality. Learn about the five essential elements of DeepInsight and how it enables you to deliver optimal ultrasound imaging during our live session.
- 13.30** **User Ultrasound QA tests – A practical introduction** – Multi-Medix Stand 14
- An overview of liver fusion and it's clinical applications
- Presented by Dr. Andrew McNeill - Consultant Radiologist, Freeman Hospital, Newcastle upon Tyne NHS Hospitals Trust

TUESDAY

WEDNESDAY

## Satellite Session - Syndicate Room B

### USING AI IN PRACTICE

- 09.30 – 11.00** **Chairs:** Dr Rita Philips, University of the West of England, Mr Antonio Sassano, University of the West of England
- 09.30** **The role of simulation in sonography education**, Mrs Catriona Hynes, Sheffield Hallam University
- 09.50** **The use of AI in clinical practice**, Dr Benjamin Stenberg, Freeman Hospital
- 10.10** **Can we really detect vulnerable carotid atherosclerotic plaques by routine ultrasound?** Rania Shahbaz, Sorbonne Universite, France
- 10.20** **Do patients enrolled within the iliofemoral venous stent surveillance programme continue to report increased quality of life and venous symptom resolution?** Alexander Pason, King's College London, Cambridge University Hospitals, Leicester University Hospitals
- 10.30** **Carotid atherosclerosis in people of European, South Asian and African Caribbean ethnicity in the Southall and Brent Revisited study SABRE**, Rayan Anbar, University College London

### DEVELOPING YOURSELF PROFESSIONALLY

- 11.30 – 13.00** **Chairs:** Dr Rita Philips. University of the West of England, Mrs Catriona Hynes, Sheffield Hallam University
- 11.30** **Tips to publishing: Pearls and pitfalls**, Mr Colin Griffin, Royal Liverpool University Hospital

THURSDAY



# DAY ONE

Tuesday 6th December

## Satellite Session - Syndicate Room B

TUESDAY

11.50 **Being a research sonographer**, Dr Ian Simcock, Great Ormond Street Hospital for Children NHS Foundation Trust

12.10 **NIHR research internship**, Ms Sharon Watty, Guy's and St Thomas' NHS Foundation Trust

12.20 **Ultrasound of Covid 19**, Laura Marsland - Kings College Hospital

12.30 **Ultrasound screening of non-alcoholic fatty liver disease (NAFLD) in children and adolescents: A critical review**, Basil Nnaemeka Ezenwuba, Sheffield Teaching Hospitals

WEDNESDAY

12.40 **The use of ultrasound elastography of the spleen in the investigation of human disease: a scoping review**, Alexander Ford, King's College London

12.50 **Use of ultrasound and computed tomography in the diagnosis and management of early-stage Fournier disease**, Ben Warner-Michel, Northern Care Alliance

12.55 **Diagnosis of a heterotopic pregnancy**, Gloria Guiteras Petitbo, University College Dublin

THURSDAY

### BECOMING A SONOGRAPHER

14.00 – 15.30 **Chairs:** Dr Rita Philips, University of the West of England, Mr Colin Griffin, Royal Liverpool University Hospital

14.00 **Preceptorship and beyond!!** Dr Rita Philips, University of the West of England, Dr Peter Cantin, University Hospitals Plymouth NHS Trust

14.20 **Understanding advanced clinical practice**, Mrs Catherine Kirkpatrick, Lincoln County Hospital

14.40 **Factors influencing a sonography led bowel ultrasound clinic**, Emmanuel Babington University of the West of England, University Hospitals of Leicester NHS Trust

14.50 **Implementation of point-of-care ultrasound (POCUS) following a new curriculum focusing on common pathologies encountered in Ghana: physician's first experiences and perspectives**, Anna Pathak, NHS Tayside

15.00 **Does performing the sliding sign technique on TVUS accurately identify deep infiltrating endometriosis?** Rubavathie Chellan, University of Derby

15.10 **Guidelines and coping mechanisms for obstetric sonographers delivering unexpected news via ultrasound**, Gary Hicks, AECC University College

# DAY ONE

Tuesday 6th December

## Practical Workshop Sessions - Syndicate Room C and D

### BOWEL MASTER CLASS

**11.30 – 13.00** **Led by** - Mrs Ruth Reeve, Portsmouth Hospitals NHS Trust, University of Southampton

Ultrasound is becoming an increasing investigation of choice for bowel disease. This session intends on providing a practical overview on the technique and use of ultrasound for imaging the bowel.

#### Faculty

Dr Elena Savoldi, Portsmouth Hospitals University NHS Trust  
Dr Rose Panton, Portsmouth Hospitals University NHS Trust  
Dr Richard Beable, Portsmouth Hospitals University NHS Trust  
Dr Nigel Grunshaw, Morecambe Bay NHS Trust  
Dr Anmol Gangi, Cambridge University Hospitals

### OBSTETRICS PRACTICAL

**14.00 – 15.30** **Led by** - Dr Trish Chudleigh, Addenbrooke's Hospital, Cambridge University Hospitals

A 30-minute guided simulation session during which you will work through cases looking at:

- The implications of caliper placement on measurement of the posterior horn
- Changing from ellipse to diameters in assessing fetal growth and EFW
- Deciding which Doppler trace is 'best'

#### Faculty

Mrs Ellen Dyer, Rosie Hospital, Cambridge  
Mrs Alison Smith, Guy's and St Thomas' Hospital  
Mrs Sally Holloway, Cambridge University Hospital NHS Trust

TUESDAY

WEDNESDAY

THURSDAY

# Sonographer of the Year Award 2022

Earlier this year the profession was asked to nominate inspirational sonographers who they considered had gone above and beyond on a day to day basis, were an utmost credit to their profession and deserved to be recognised for making a difference.

It was requested that the individuals nominated should:

- be champions of the profession
- promote excellence in the field of ultrasound
- provide leadership
- go the extra mile for patients and colleagues
- educate future generations with unyielding enthusiasm
- be a BMUS member



From the nominations received, BMUS has great pleasure introducing the five successful shortlisted nominees

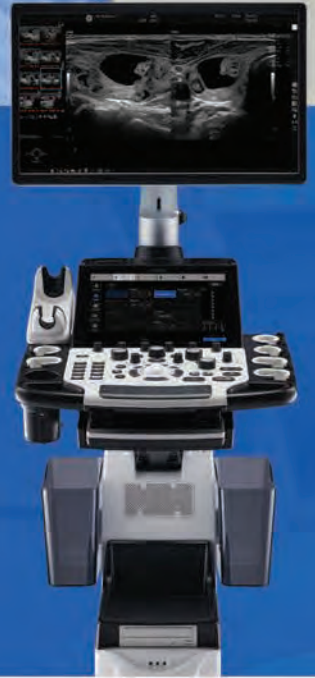Nominees	Institution	Nominated by
<b>Kate Smith</b>	Chapel Allerton Hospital, Leeds Teaching Hospitals NHS Trust	Borsha Sarker
<b>Alison McGuinness</b>	Mid Yorks NHS Trust	Melanie Harrison
<b>Angie Lloyd-Jones</b>	Northwest Veterinary Specialist and Aspire UCS	Aimee Bebbington and Julie Burnage
<b>Steve Savage</b>	Yeovil District Hospital	Andrea Gane
<b>Aaron Brereton</b>	Royal Devon University Healthcare NHS	Prince Ogenyi

The winner of the award for 2022 will be announced during the Winter Ball and Awards Ceremony at Cardiff City Hall, on Wednesday 7th December.



# Introducing GE LOGIQ Fortis—the next generation of LOGIQ ultrasound technology.

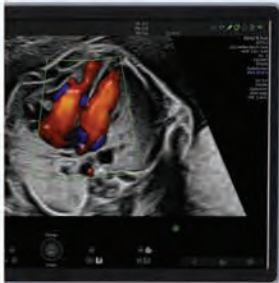LOGIQ Fortis—the LOGIQ platform’s newest member—provides a multi-purpose, all-in-one, ultra-secure ultrasound solution that can be easily scaled to fit your specific needs.



LOGIQ Fortis is characterized by both its **strength** and its **power**. It gives you the power to enhance your clinical capabilities and increase productivity exponentially.

## Everything you expect in a LOGIQ system—powerfully streamlined

With a sleek and compact design, LOGIQ Fortis can be used in almost any space. Its state-of-the-art features and technologies make it strong enough to conduct a full spectrum of ultrasound exams and procedures on any body type. It was specifically designed to optimize clinicians' productivity, exceed expectations regarding performance, and to maximize your investment.



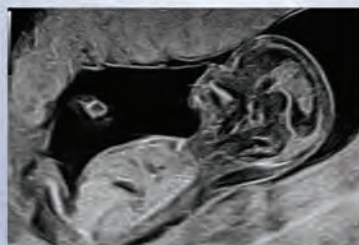## REVEAL THE INVISIBLE

Detailed imaging is essential and the Voluson Expert 22 is ready to show you more than you ever thought possible. We are taking innovation further, making it easier to collect more information at record speeds for even faster, sharper, and clearer imaging. The Voluson Expert 22 will help you see critical details required for a confident diagnosis.

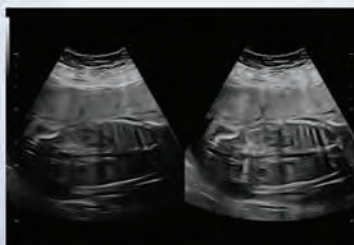How do you find a needle in a haystack? Build a powerful engine with the most progressive and adaptive capabilities yet. The **Lyrice Architecture** unlocks new imaging and processing power to achieve high resolution, detailed images – independent of body habitus and other difficult scanning conditions.

- Generates new levels of penetration, resolution, and frame rates to reveal fine anatomy in 2D/3D/4D with ease
- Delivers uniformity throughout the image with increased spatial and contrast resolution
- Works in harmony with our unique probe technology offering advanced imaging options
- Opens doors to unique Voluson imaging capabilities

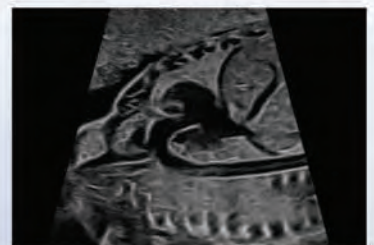The Lyrice Architecture allows you to set new standards in image quality for years to come.



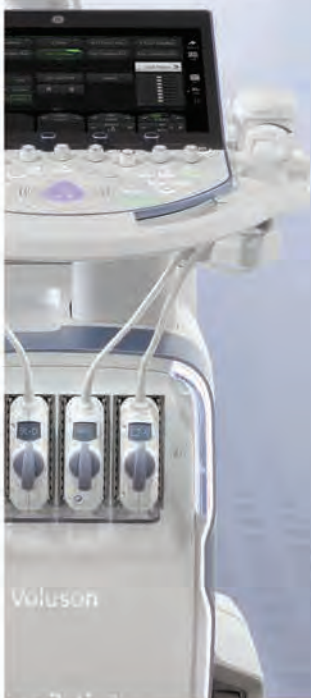Obtain super fine details with **UltraHD** – providing increased axial and lateral resolution.



Utilize **Augment** to reduce noise and increase penetration for a robust, cleaner image even in difficult to scan situations like high BMI.



Utilize **Radiant** for greater definition and clarity. Change the levels to enhance the 3D-like elevation effect for greater border visibility and sharpness.





# AT A GLANCE DAY TWO

Wednesday 7th December

Session Start Times	LECTURES				PRACTICAL SESSIONS
	Plenary 1	Plenary 2	Plenary 3	Satellite Session	
	Assembly Room	Ferrier Hall	Room L	Room B	Room C & D
08.30	Obstetrics 1	Head and Neck 1	Young Investigators 2022	ThUNDDAR 1	DVT Lower Limb
10.00	REFRESHMENT BREAK				
10.30	Obstetrics 2	Head and Neck 2	Extreme PoCUS	ThUNDDAR 2	DVT Upper Limb
12.00	LUNCH Education on the stand 12.10 MIS 12.30 Philips 12.45 BMUS Annual General Meeting				
13.00	Obstetrics 3	MSK 1	PoCUS 1	ThUNDDAR 3	Head and Neck
14.30	REFRESHMENT BREAK				
15.00	AXREM Debate	MSK 2	PoCUS 2	ThUNDDAR 4	
16.30	END OF DAY 2				
19.00	Winter Ball and Awards Ceremony Cardiff City Hall				

# DAY TWO

Wednesday 7th December

## Plenary 1 - Assembly Hall

### IMAGING ACROSS THE TRIMESTERS - AI, BIOCHEMISTRY AND GENOMICS

- 08.30 – 10.00 **Chairs:** Dr Trish Chudleigh, Cambridge University Hospitals NSH Foundation Trust, Mrs Ellen Dyer, Cambridge University Hospitals NSH Foundation Trust
- NT, anatomy, NIPT, exome sequencing – where is 1st trimester screening going?
  - Artificial intelligence and fetal biometry
  - Biochemical markers, imaging and outcomes
- 08.30 **Where is 1st trimester screening going?** Prof Aris Papageorgiou, University of Oxford
- 08.50 **Artificial Intelligence and fetal biometry,** Ms Jacqueline Matthew, St Thomas Hospital
- 09.10 **Combining ultrasound biomarkers to screen fetal growth,** Prof Gordon Smith, Cambridge University
- 09.30 **Round table discussion,** All Speakers
- 09.50 **Clinical value of 3D ultrasound at 11-14 weeks of gestation,** Jayne Lander, University of Oxford

### PUTTING GUIDELINES INTO PERSPECTIVE - HOW MANY DO WE NEED?

- 10.30 - 12.00 **Chairs:** Dr Trish Chudleigh, Cambridge University Hospitals NHS Foundation Trust, Miss Gill Harrison, Society and College of Radiographers
- The pitfalls of uterine artery Doppler – a practical guide
  - Capacity versus demand
  - Are the KPIs for SBLv2 working?
- 10.30 **The pitfalls of uterine artery doppler - a practical guide,** Mrs Ellen Dyer, Addenbrookes Hospital
- 10.50 **Capacity versus demand,** Miss Shaunna Smith, Hull Royal Infirmary
- 11.10 **Monitoring Saving babies' lives - is it working, for whom and how do we know?** Ms Sascha Wells, Deputy Chief Midwifery Officer - England and Prof Donald Peebles, University College London
- 11.30 **Round table discussion,** All Speakers
- 11.50 **How much extra time do sonographers really need to perform 20-week uterine artery Dopplers?,** Ellen Dyer, Cambridge University Hospitals NSH Foundation Trust

TUESDAY

WEDNESDAY

THURSDAY

# DAY TWO

Wednesday 7th Decemberr

## Plenary 2 - Ferrier Hall

### EDUCATING SONOGRAPHERS, THE PROFESSION AND THE SERVICE - TIME FOR A RETHINK

- 13.00- 14.30** **Chairs:** Mrs Ellen Dyer, Cambridge University Hospitals NSH Foundation Trust, Miss Shaunna Smith, Hull Royal Infirmary
- 13.00** **Those first two sentences - what, how & when? Getting it right when there's a problem,** Dr Judith Johnson, University of Leeds
- 13.20** **Routine screening, images, sonographers and barristers,** Dr Trish Chudleigh, Cambridge University Hospitals NSH Foundation Trust
- 13.40** **An obstetric sonographer career pathway - A vision through rose tinted glasses,** Miss Gill Harrison, Society and College of Radiographers
- 14.00** **Round table discussion,** All Speakers
- 14.20** **Assessing the introduction of the new BMUS 'Growth' guidelines into routine practice,** Sally Holloway, Cambridge University Hospitals NSH Foundation Trust

### AXREM DEBATE

- 15.00 - 16.30** **Hosted by** Prof Rhodri Evans, Withybush General Hospital

This is a debate where the future of ultrasound will be discussed and the AXREM Ultrasound manifesto will be the basis of discussions. Right first time.... Helping to improve Ultrasound pathways cost and resource management.

Mrs Pamela Parker, President of the British Medical Ultrasound Society (BMUS)  
 Prof Adrian Lim, MD, FRCR, President-Elect of the British Medical Ultrasound Society (BMUS)  
 Ms Francesca Rooke, NHS Supply Chain Coordination Limited  
 Mrs Ruth Graesser, Philips Healthcare  
 Mr Roy Tappin, GE Healthcare

## Plenary 2 - Ferrier Hall

### HEAD AND NECK 1

- 08.30 - 10.00** **Chairs:** Mrs Catherine Kirkpatrick, Lincoln County Hospital, Dr Chris Greenall, Cwm Taf Morgannwg University Health Board

There has been a hiatus in the presence of head and neck ultrasound on the BMUS programme but it's back and with aplomb! The head and neck sessions will as always aim to provide innovative and highly educational content to expand the knowledge of the ultrasound practitioner. Ultrasound of the oral cavity and pharynx – is it something we all should be doing? Head and neck masses – what are they and what should I be doing with them? Do ultrasound practitioners know what happens to their patients after the scan? This session will look at the prognosis and management of thyroid cancer following diagnosis and the importance of ultrasound in the journey. With innovations and advances in practice, the world of head and neck ultrasound is always moving forwards and evolving, these sessions will aim to take BMUS delegates on that journey.

# DAY TWO

Wednesday 7th December

## Plenary 2 - Ferrier Hall

- |       |  |
|-------|--|
| 08.30 | <b>Ultrasound of the oral cavity and pharynx</b> , Dr Susan Jawad, University College London Hospitals, Royal National ENT and Eastman Dental Hospital             |
| 08.50 | <b>Ultrasound of the larynx. What can ultrasound add?</b> , Dr Rhian Rhys, Ysbyty Brenhinol Morgannwg/Royal Glamorgan Hospital                                     |
| 09.10 | <b>Unusual head and neck masses. What are they and what should I do with them</b> , Dr Jagrit Shah, Nottingham University Hospitals NHS Trust                      |
| 09.30 | <b>Case studies and MDT panel discussion</b> , Mrs Catherine Kirkpatrick, Lincoln County Hospital and Dr Chris Greenall, Cwm Taf Morgannwg University Health Board |
| 09.50 | <b>Questions and Answer Session</b>  |

### HEAD AND NECK 2

- |               |   |
|---------------|---|
| 10.30 - 12.00 | <b>Chairs:</b> Mrs Catherine Kirkpatrick, Lincoln County Hospital, Prof Rhodri Evans, Withybush General Hospital  |
| 10.30         | <b>TNM8 staging. Is ultrasound useful?</b> , Dr Chris Greenall, Cwm Taf Morgannwg University Health Board   |
| 10.50         | <b>Thyroid cancer. Management and prognosis</b> , Dr Abigail Pascoe, Nottingham University Hospitals NHS Trust  |
| 11.10         | <b>Parathyroid Imaging: Lessons learned</b> , Prof Rhodri Evans, Withybush General Hospital   |
| 11.30         | <b>Salivary gland imaging - Where does ultrasound fit in? Paediatric head and neck scanning - Are they small adults or is there more to it?</b> , Dr Sumit Jagani, Nottingham University Hospital NHS Trust |
| 11.50         | <b>Questions and Answer Session</b>   |

### GUIDELINES AND PATHWAYS IN MSK ULTRASOUND

- |              |  |
|--------------|--|
| 13.00- 14.30 | <p><b>Chairs:</b> Mr Mark Charnock, Northern General Hospital, Mrs Alison Hall, Keele University/Cannock Chase Hospital</p> <p>The use of guidelines and clinical pathways are fundamental in the diagnosis and management of patients. This session looks at specific and complex areas of musculoskeletal ultrasound, including paediatrics, trauma and adult groin/hip. Presenters have extensive experience of using ultrasound in their fields and will discuss guidelines, ultrasound features and management of these patients.</p> |
| 13.00        | <b>Ultrasound of lumps and bumps in children</b> , Dr Jeannette Kraft, Leeds Teaching Hospitals NHS Trust  |
| 13.30        | <b>Overview of acute MSK ultrasound service at UHL</b> , Mrs Amanda Parry, University Hospitals of Leicester NHS Trust   |
| 14.00        | <b>An introduction to adult groin and hip scanning</b> , Mr Richard Brindley, Cannock Rheumatology MSKU Department   |

TUESDAY

WEDNESDAY

THURSDAY



# DAY TWO

Wednesday 7th December

## Plenary 2 - Ferrier Hall

### EMERGING ROLES IN MSK ULTRASOUND

**15.00 - 16.30** **Chairs:** Mr Mark Charnock, Northern General Hospital, Mrs Amanda Parry, University Hospitals Leicester NHS Trust

Musculoskeletal ultrasound is performed by a variety of healthcare practitioners, not just in radiology and within a dedicated scope of practice. Specific roles have been established for these practitioners who deliver specialised clinical services and interventions. Speakers will give their insight of these roles, service delivery and the use of ultrasound in their practice.

**15.00** **The use of ultrasound guided interventions in a community based chronic pain management service,** Mr Ashish Khiloshiya, Staffordshire and Stoke on Trent NHS Trust

**15.30** **MSK sonographer career progression; A new approach,** Ms Catharine Berry, University Hospitals Leicester

**16.00** **Ultrasound guided intervention for physiotherapists,** Mr Mike Bryant, Ilkley Physiotherapy

**16.20** **Semi-automated tracing of hamstring muscle architecture for B-mode ultrasound images,** Kevin Cronin, University College Dublin

TUESDAY

WEDNESDAY

THURSDAY

## Plenary 3 – Room L

### YOUNG INVESTIGATOR

**08.30 - 10.00** **Chairs:** Prof Carmel Moran, University of Edinburgh, Mrs Terry Humphrey, Leeds Teaching Hospitals

During this session, four short-listed oral papers from submitters under the age of 39 will battle it out to win the title of BMUS Young Investigator 2022 and the prize of representing the UK at the EUROSON 2023 Congress in Riga, Latvia.

**08.30** **The effect of suspension medium on the ultrasound backscatter signature of microbubbles within a flow phantom,** Lauren Gilmour, University of Strathclyde

**08.45** **Sonographer led discharge in a deep vein thrombosis clinic; a feasibility study,** Catherine Lee, Royal Devon University NHS Foundation Trust

**09.00** **Prediction of arteriovenous fistula maturation outcomes in end-stage renal disease patients, using invasive and non-invasive techniques: Pilot study,** Wael Faqih, Imperial College London

**09.15** **The first 5 targeted trans-perineal prostate biopsies diagnose the majority of PROMIS criteria cancer in patients with a Likert 4 or 5 score on mpMRI,** Adam Morell, Leeds Teaching Hospitals NHS Trust

**Sponsored by Focused Ultrasound Foundation**



# DAY TWO

Wednesday 7th December

## Plenary 3 - Room L

### ULTRASOUND TAKEN TO THE EXTREME

- 10.30 - 12.00** **Chairs:** Dr Benjamin Stenberg, Freeman Hospital, Prof Bob Jarman, Teesside University Middlesbrough
- This session is to look at the use of ultrasound in some of the more extreme settings. As ultrasound has grown as a modality it has exceeded the boundaries of radiology and obstetric departments or even hospital environments and now gets used in some of the most extreme environments on (and off) earth.
- We will look at examples of people using ultrasound on the battleground, in rare and endangered animal species, non-medical uses and even in space.
- 10.30** **Large mammal ultrasound and other imaging**, Dr Fieke Molenaar, Zoological Society of London
- 10.50** **Measuring ultrasound in challenging ocean environments**, Prof Bajram Zeqiri, National Physics Laboratory
- 11.10** **Wild whale sharks**, Dr Rui Matsumoto, Okinawa Churaumi Aquarium
- 11.20** **Innovation and development of pre-hospital military ultrasound**, Major Georgie Blenkinsop, Royal Army Medical Corps
- 11.30** **Space, the final frontier for ultrasound**, Mr Paul Muckelt, University of Southampton

### POCUS ENLIGHTENING SESSION 1 - GOVERNANCE

- 13.00 - 14.30** **Chairs:** Prof Bob Jarman, Teesside University Middlesbrough, Dr Ben Stenberg, Freeman Hospital, Newcastle
- 13.00** **Levels of entrustment in PoCUS training - time for a rethink**, Mr Simon Richards, Teesside University
- 13.13** **BMUS/RCR PoCUS Guidelines**, Mrs Hazel Edwards, British Medical ultrasound Society
- 13.26** **How can we accommodate the increasing number of PoCUS trainees in pressured clinical specialties?** Ms Florence Dupriez, Cliniques universitaires Saint-Luc, Brussels
- 13.39** **Developing PoCUS in AHP curricula**, Dr Mike Smith, Cardiff University
- 13.52** **PoCUS and PACS - never the twain shall meet**, Dr Chris Yap, Northern General Hospital, Sheffield Teaching Hospitals NHS Foundation Trust
- 14.05** **LogMyScan - development and evaluation of an innovative mobile phone-based log book**, Prof Bob Jarman, Teesside University Middlesbrough
- 14.18** **Using ultrasound to gain peripheral venous access: A local teaching programme**, Lakshya Soni, Queen Elizabeth Hospital

TUESDAY

WEDNESDAY

THURSDAY

# DAY TWO

Wednesday 7th December

## Plenary 3 - Room L

### PoCUS ENLIGHTENING SESSION 2 - CLINICAL PRACTICE

TUESDAY

WEDNESDAY

THURSDAY

- 15.00 - 16.30 **Chairs:** Prof Bob Jarman, Teesside University Middlesbrough, Mrs Hazel Edwards, British Medical Ultrasound Society
- 15.00 **Establishing international evidence-based guidelines for clinical practice - EFSUMB PoCUS clinical practice guidelines initiative**, Prof Bob Jarman, Teesside University Middlesbrough
- 15.13 **Essential PoCUS education and resources online**, Dr Cian McDermot, Mater Misericordiae University Hospital, Dublin, Ireland
- 15.26 **Improvements in haemodynamic fluid assessment**, Mr Justin Kirk-Bayley, Royal Surrey NHS Foundation Trust
- 15.39 **Can PoCUS reduce clinical demands on radiology?**, Dr Nicholas Smallwood, Hampshire Hospitals NHS Foundation Trust
- 15.52 **Are artificial intelligence features useful on PoCUS machines**, Dr Marcus Peck, Frimley Park Hospital
- 16.05 **Augmenting B-mode images for ultrasound guided procedures**, Dr James Bowness, Aneurin Bevan University Hospital Board
- 16.18 **'Ultrasound skills at ITU' teaching experience**, Tatyana Bolonenkova, Queen Elizabeth Hospital

## Education On The Stand - Exhibition Hall

### EDUCATION ON THE STAND - EXHIBITION HALL

- 12.10 **Ultrasound Guided Intervention of the Elbow** - MIS Stand 2  
Presented by Thomas Armstrong, Consultant Musculoskeletal Radiologist
- 12.30 **Fusion in Everyday Practice** - Philips Stand 21  
An overview of liver fusion and it's clinical applications  
Presented by Dr. Andrew McNeill - Consultant Radiologist, Freeman Hospital, Newcastle Upon Tyne NHS Hospitals Trust

# DAY TWO

Wednesday 7th December

## Satellite Session - Room B

### THERAPY ULTRASOUND NETWORK FOR DRUG DELIVERY AND ABLATION RESEARCH SESSION 1

- 10.45 – 12.40 **Chairs:** Mr Cyril Lafon, LabTAU INSERM, Lyon, Prof Gail ter Haar, The Institute of Cancer Research
- 10.45 **Welcome from Chairs,** Mr Cyril Lafon, INSERM, Lyon, Prof Gail ter Haar, The Institute of Cancer Research
- 11.00 **Sonoporation of cells to enhance the liberation of intracellular biomarkers,** Prof Carmel Moran, University of Edinburgh
- 11.20 **Detection of HIFU Lesions by Optical Coherence Tomography,** Jason Raymond, University of Oxford
- 11.40 **The effects of repeated histotripsy treatments on the viral delivery and growth of murine pancreatic tumours,** Petros Mouratidis, The Institute of Cancer Research
- 12.00 **Temperature measurements during high intensity focused ultrasound exposure,** Piero Miloro, National Physics Laboratory
- 12.20 **Ultrasonic cavitation for controlled Pancreatic cancer stroma Disruption,** Mr Cyril Lafon, LabTAU INSERM

### THERAPY ULTRASOUND NETWORK FOR DRUG DELIVERY AND ABLATION RESEARCH SESSION 2

- 14.00 – 15.40 **Chairs:** Prof Carmel Moran, University of Edinburgh, Dr Piero Miloro, National Physics Laboratory
- 14.00 **#Hope4Liver Trial-Phase I/II Image Guided Histotripsy in Primary/Metastatic Liver Cancers**  
Dr Tze Wah, The Leeds Teaching Hospital NHS Trust
- 14.20 **Preparation and characterisation of phase-changed nanodroplets for ultrasound BloodBrain Barrier permeability enhancement in vitro,** Stavros Vlatakis, Kings College London
- 14.40 **The potential of phase-change nanodroplets in generating reactive oxygen species for sonodynamic anticancer therapy,** Shazwan Abd Shukor, Kings College London
- 15.00 **Characterisation of cavitation threshold properties of selected hydrogels as tissue mimics for therapeutic ultrasound,** Lisa Braunstein The Institute of Cancer Research
- 15.20 **Using magnetic microbubbles to probe colorectal cancer lymph nodes,** Georgia Adam, University of Strathclyde

TUESDAY

WEDNESDAY

THURSDAY



# DAY TWO

Wednesday 7th December

## Practical Workshop Sessions - Syndicate Room C and D

TUESDAY

WEDNESDAY

THURSDAY

### DVT LOWER LIMB

**08.30 - 10.00** **Led by:** Mrs Tanyah Ewen, North West Anglia NHS Foundation Trust  
Upper Limb scanning technique/anatomy

#### Faculty

Mr Amine Turay, Imperial College  
Mrs Mari Wester, Royal United Hospitals Bath  
Miss Shannon Halliwell, University Hospitals Bristol and Weston  
Mrs Tracey Gall, Independent Vascular Services Ltd - Royal Oldham Hospital  
Mrs Lynne McRae, Royal Gwent Hospital  
Mrs Vikki Galgerud, Independent Vascular Services Ltd  
Mr David Muwanga, Barking Havering and Redbridge NHS Trust  
Miss Emily Morgan, University Hospital Wales

### DVT UPPER LIMB

**10.30 - 12.00** **Led by:** Mrs Tanyah Ewen, North West Anglia NHS Foundation Trust  
Lower Limb scanning technique/anatomy

#### Faculty

Ms Nazia Saeed, Institution is London Northwest University Hospital Trust  
Mrs Mari Wester, Royal United Hospitals Bath  
Miss Shannon Halliwell, University Hospitals Bristol and Weston  
Mrs Tracey Gall, Independent Vascular Services Ltd  
Mrs Lynne McRae, Royal Gwent Hospital  
Mrs Vikki Galgerud, Independent Vascular Services Ltd  
Mr David Muwanga, Barking Havering and Redbridge NHS Trust

### HEAD AND NECK PRACTICAL

**13.00 - 14.00** **Led by:** Mrs Catherine Kirkpatrick, Lincoln County Hospital

Following feedback from recent years, the ASM in Cardiff sees the return of the popular 'hands on' Head and Neck Workshop. Expert faculty will provide demonstrations and anatomy of the '7 sweep neck' technique, breaking into smaller groups to consolidate learning and have time to ask questions.

# DAY TWO

Wednesday 7th December

## Faculty

Dr Rhian Rhys, Ysbyty Brenhinol Morgannwg/Royal Glamorgan Hospital

Dr Jagrit Shah, Nottingham University Hospitals NHS Trust

Dr Lawrence Berman, Addenbrooke's Hospital

Dr Christopher Greenall, Cwm Taf Morgannwg University Health Board

Prof Rhodri Evans, Withybush General Hospital

Mrs Michelle Davies, Morriston Hospital, Swansea Bay University Health Board

TUESDAY

WEDNESDAY

THURSDAY



# BMUS Annual Winter Ball Ceremony & Awards

**7th December 2022**

Assembly Room, City Hall, Cardiff

**19.00** Pre-drinks

**19.45** Gala dinner and Awards Ceremony

The evening festivities will include a **three-course deluxe menu**, entertainment and a disco

An evening not to be missed we have the **Llantrisant Male Choir**, **Harpist Nia Evans** and a DJ to help you dance the night away.

*The winners of this years prizes will be announced after dinner*

Tickets are priced at **£39.90**

Carriages at 12.00

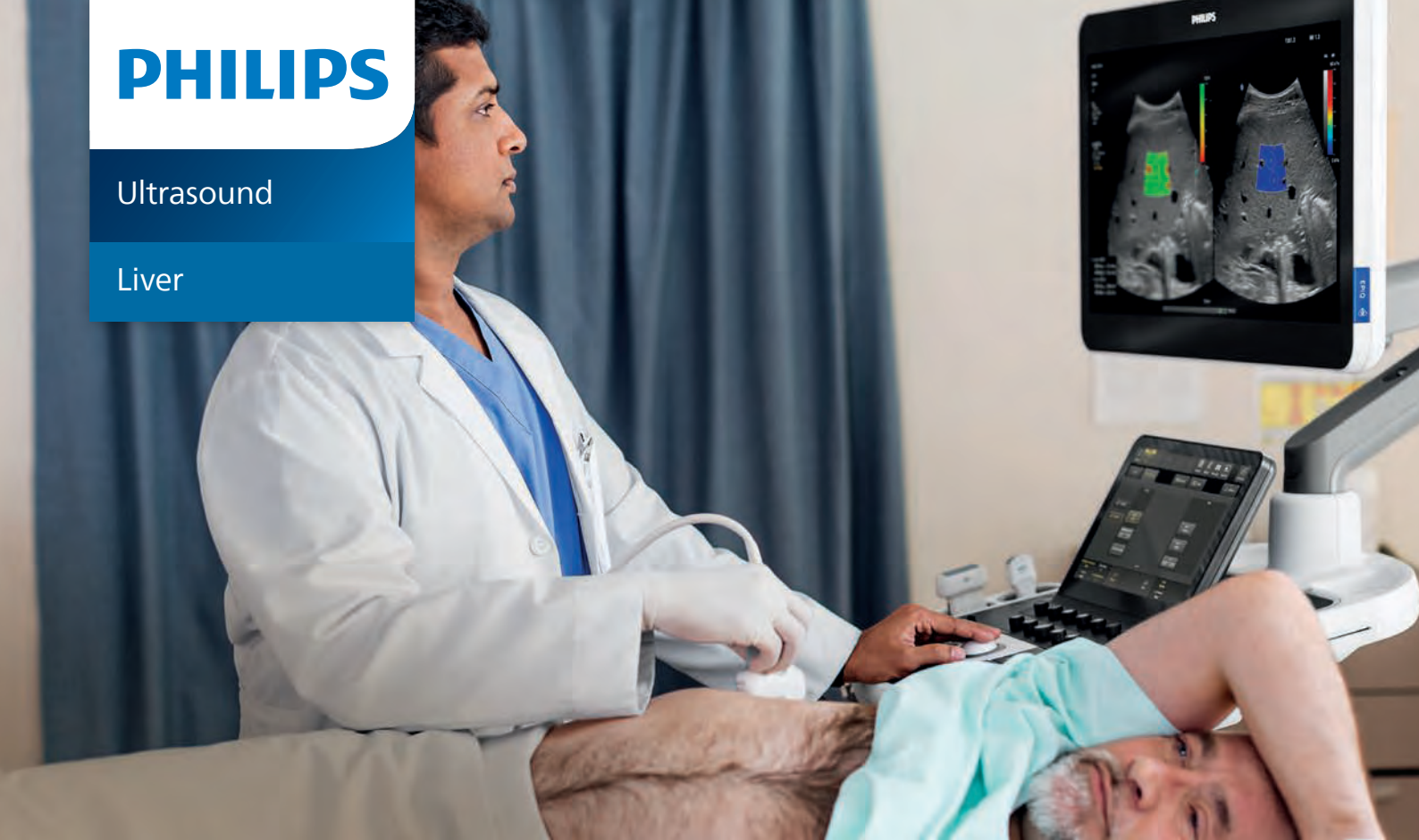A wonderful opportunity to begin your Christmas Festivities with old and new acquaintances, come and join us for yet another fun pack BMUS event



# PHILIPS

## Ultrasound

### Liver



# Manage liver conditions comprehensively and efficiently

## Philips ultimate solution for liver assessment

Offering an exceptional, easy-to-use and complete solution for liver disease assessment, treatment planning and monitoring, the Philips ultimate liver solution for liver assessment is available across a wide range of PureWave transducers to accommodate different body habitus. The quantifiable outcomes from the latest addition: liver fat quantification and shear wave elastography allow radiologists and hepatologists to complete screening, diagnosis and management with ultrasound only. The solution provides tools that maintain excellent detail resolution and Doppler sensitivity, and allows for high performance in elastography, quantification of liver fat, 3D/4D and contrast-enhanced ultrasound (CEUS), even in technically difficult-to-scan patients.

Together, we make life better.

innovation  you



## Quantitative parameters for assessment of steatosis

with Philips Liver Fat Quantification (LFQ) tools.



## Easy, fast and robust acquisition

with ElastQ imaging.\*



## 29% to 85% reduced pain and fatigue

from scanning with the C5-1 transducer, compared to conventional transducers.\*\*



Scan me!

## Philips keeps you ahead with innovative technologies

Philips first introduced single-crystal technology with its PureWave transducers, which provide exceptional tissue detail and resolution and a 76% increase in penetration.<sup>1</sup>

Come and visit the Philips stand at BMUS to find out more

\* Side-by-side view of unique imaging confidence and stiffness maps helps reduce workflow steps and allows for simultaneous map correlation during acquisition and measurement phases.\*\* Compared to conventional transducers.



# AT A GLANCE DAY THREE

Thursday 8th December

Session Start Times	LECTURES				PRACTICAL SESSIONS
	Plenary 1	Plenary 2	Plenary 3	Satellite Session	
	Assembly Room	Ferrier Hall	Room L	Room B	Room C & D
09.00	Gynaecology and Early Pregnancy 1	Interventional Session	Vascular Session 1	8.30 Start Veterinary Sessions 1	MSK Workshop 1
10.50	REFRESHMENT BREAK				
11.20	Gynaecology 2	Artificial Intelligence in Ultrasound	Vascular Session 2	Veterinary Sessions 2	MSK Workshop 1
13.10	LUNCH Education on the stand 13:15 GE				
14.00	Gynaecology 3	MSK 3	Professional Issues 4	Veterinary Sessions 3	
16.00	End of Day 3				

# DAY THREE

Thursday 8th December

## Plenary 1 - Assembly Hall

### MULTIPLE PREGNANCY - THERE IS MORE TO IT THAN A COUPLE OF GESTATION SACS

09.00 – 10.50 **Chairs:** Dr Trish Chudleigh, Cambridge University Hospitals NHS Foundation Trust, Ms Roxanne Sicklen, Royal Free London NHS Trust

#### Multiple pregnancy

- Twinning in early pregnancy - understanding the embryology
- Twinning in early pregnancy - ultrasound (tips and pitfalls)

#### Early pregnancy communication

- Using scenarios encountered whilst scanning in the early pregnancy unit. What to say and what not to say.

09.00 **Twining in early pregnancy - understanding the embryology,** Dr Sian Mitchell, Guy's and St Thomas NHS Trust

09.30 **Twining in early pregnancy - ultrasound (tips & pitfalls),** Miss Alison Smith, Guy's and St Thomas NHS Trust

10.00 **Early Pregnancy communication - are we getting it right?,** Ms Roxanne Sicklen, Royal Free London NHS Trust, Mrs Ruth Bender Atik, The Miscarriage Association

10.30 **Question and Answer Session**

### TIME TO EMBRACE NEW TECHNOLOGIES

11.20 – 13.10 **Chairs:** Mrs Alison Smith, Guy's and St Thomas NHS Trust, Mr Jonathan Gaughran, Guy's and St Thomas NHS Trust

#### Fertility ultrasound

- What should we be looking for?
- How to do 3D scans and classify congenital uterine anomalies

#### Gynae sonographer

- Addressing the skills, time for a rethink

11.20 **Fertility Scan - what should we be looking for?,** Mr Gidon Lieberman, Whittington Health NHS Trust

11.50 **3D Ultrasound Scans - how to do and classify uterine congenital anomalies,** Ms Angela Clough, Derriford Hospital, University Hospitals of Plymouth NHS Trust

12.20 **Addressing the skills of the gynae sonographer - time for a rethink?,** Dr Peter Cantin, Derriford Hospital, University Hospitals of Plymouth NHS Trust

12.50 **Question and Answer Session**

TUESDAY

WEDNESDAY

THURSDAY

# DAY THREE

Thursday 8th December

## Plenary 1 - Assembly Hall

### MASTERCLASS IN ENDOMETRIOSIS

**14.00 – 16.00** **Chairs:** Dr Trish Chudleigh, Cambridge University Hospitals NHS Foundation Trust, Miss Alison Smith, Guy's and St Thomas NHS Trust

#### Masterclass in Endometriosis

- Diagnosing endometriosis – the patient's perspective
- The ultrasound diagnosis of endometriosis – the sonographer's perspective
- What the clinician needs to know – a gynaecologist's perspective

**14.00** **Reconsidering the ultrasound diagnosis of endometriosis**, Miss Alison Smith, Guy's and St Thomas NHS Trust

**14.30** **What the clinician needs to know - A gynaecologist's perspective**, Mr Jonathan Gaughran, Guy's and St Thomas NHS Trust

**14.00** **Diagnosing endometriosis - What this means for the patient**, Ms Claudia Tye, Guy's and St Thomas NHS Trust

**15.30** **Questions and Answer Session**

TUESDAY

WEDNESDAY

THURSDAY

## Plenary 2 - Ferrier Hall

### INTERVENTIONAL ULTRASOUND

**09.00 – 10.50** **Chairs:** Dr Peter Cantin, Derriford Hospital, University Hospitals of Plymouth NHS Trust, Prof Adrian Lim, Charing Cross Hospital

Image guidance is becoming standard practice for most interventional procedures. Ultrasound has a crucial role in ensuring that many interventional procedures are undertaken safely and effectively. This session will look at some of the applications where ultrasound image guidance adds value. It will also examine the scope of practice and governance frameworks for those looking to extend their practice into ultrasound guided interventions.

**09.00** **The sonographer and interventional procedures - A quality and governance framework**, Ms Kerry Green, University Hospitals Plymouth NHS Trust

**09.25** **Abdominal interventional procedures - Principles and practice**, Dr Michael McNeill, The Newcastle Upon Tyne Hospitals NHS Foundation Trust

**09.50** **Intervention in the head and neck**, Ms Sarah Martyn, Royal Cornwall Hospitals NHS Trust

**10.10** **Interventional ultrasound and the prostate gland**, Mrs Pamela Parker, Hull University Teaching Hospitals NHS Trust

**10.30** **The role of interventional advanced practice sonographer**, Ms Catherine Lee, Royal Devon University Healthcare NHS Foundation Trust

# DAY THREE

Thursday 8th December

## Plenary 2 - Ferrier Hall

### THE USE OF ARTIFICIAL INTELLIGENCE IN ULTRASOUND

11.20 – 13.10 **Chairs:** Dr Benjamin Stenberg, Freeman Hospital, Dr Barry Ward, Freeman Hospital

We are surrounded by artificial intelligence in our daily life and these principles are making their way into medicine. Radiology and ultrasound are prime candidates for the integration of AI deep learning as it relies on high volume, pattern recognition and risk stratification. It is almost certainly on the ultrasound machine you are already using but where will it go from here?

This session explores the principles behind artificial intelligence technology, how it is being currently applied to obstetrics, gynaecology and general imaging in the clinical environment and how it is being used in teaching the next generation of sonographers. We shall also look at how the future of AI in ultrasound might look and how NHS Improvement are looking to incorporate AI into the radiology department.

11.20 **How does AI work and how can it be incorporated into ultrasound imaging?**, Prof Alison Noble, University of Oxford

11.45 **Utilising current and emerging AI technologies in the obstetric examination**, Prof Aris Papageorgiou, University of Oxford and St George's University Hospital

12.10 **Integrating AI in non-obstetric ultrasound and education**, Mr Chris Edwards, Queensland University of Technology, Australia

12.35 **AI and the future of ultrasound (and sonographers)**, Dr Ken Sutherland, Canon Medical Research

### SPECIALISED MSK

14.00 – 16.00 **Chairs:** Mrs Alison Hall, Keele University and Cannock Chase Hospital, Ms Amanda Parry, University Hospitals of Leicester NHS Trust

This session is focused on specific areas of complex MSK ultrasound and is aimed at healthcare professionals who wish to broaden their knowledge and practice. Speakers in this session reflect the diversity of professionals using ultrasound in sports injuries, sarcoma MDT and rheumatology.

14.00 **Psoriatic arthritis and the typical features not to miss on ultrasound scan**, Dr Muhamad Jasim, University Hospital Coventry & Warwickshire

14.30 **Sarcoma MDT and the role of Ultrasound**, Dr Ibrahim Azam, Sheffield Teaching Hospital NHS Foundation Trust

15.00 **The use of ultrasound in athlete care**, Dr Harjinder Singh, University Hospitals Leicester

15.30 **Appropriateness of musculoskeletal soft tissue swelling ultrasound scans**, Rameesha Anwar, University Hospitals North Midlands

TUESDAY

WEDNESDAY

THURSDAY

# DAY THREE

Thursday 8th December

## Plenary 3 - Syndicate Room L

TUESDAY

WEDNESDAY

THURSDAY

### VASCULAR SCIENCE 1

09.00 – 10.40 **Chairs:** Mrs Lynne McRae, Royal Gwent Hospitals, Mrs Tracey Gall, Independent Vascular Services

The first session will look at how duplex ultrasound is moving into the future, including the current grading criteria for carotid duplex along a potentially new topic around the uncertainty of measurements in vascular ultrasound. The use of 3D ultrasound in the assessment of carotid plaque.

This session will also cover the topic of venous stenting and the assessment of venous stents, the pitfalls in assessing the venous system post venous ablation, and the role of venous duplex in the assessment of leg ulcers.

09.00 **The importance of accurate Carotid Velocity Measurements**, Mr Osian Llwyd, John Radcliffe Hospital

09.20 **Deep Venous Intervention**, Mrs Vikki Galgerud, Independent Vascular Services

09.40 **The training and future role of interventional scientists**, Mr Gurdeep Jandu, Independent Vascular Services

10.10 **DVT the aftermath**, Mrs Jane Todhunter, North Cumbria Integrated Care NHS Foundation Trust

10.20 **Quality and accuracy of vascular ultrasound equipment**, Dr Nick Dudley, Lincoln County Hospital

### VASCULAR SCIENCE 2

11.20 – 13.10 **Chairs:** Mrs Tanya Ewan, Peterborough City Hospital, Mrs Gail Curran, North West Anglia NHS Foundation Trust

The second vascular session will look at the role of vascular ultrasound in assessing pathologies or the SMA and sciatic artery. Whether the iliac and calf veins should be scanned routinely as part of the assessment for deep vein thrombosis and the pitfalls in assessing the DVT patient. Also, the role of vascular ultrasound in endo-AVF screening, creation and surveillance.

11.20 **Should Iliac veins and the veins below the knee be scanned routinely as part of the protocol in ultrasound scanning for DVT diagnosis**, Mr Amine Turay, Imperial College London

11.40 **SMA Syndrome**, Miss Helen Dixon, Imperial College London

12.00 **Recurrent Sciatic Artery**, Mrs Lynne McRae, Royal Gwent Hospitals

12.20 **Endovenous AVF Creation**, Miss Amy Bosworth, Barts Health NHS Trust

12.40 **Practical tips for difficult DVT examinations**, Ms Mari Wester, Royal United Hospitals Bath



# DAY THREE

Thursday 8th December

## Plenary 3 - Syndicate Room L

### COLLABORATIONS AND INNOVATIONS - HOW TO TAKE ULTRASOUND INTO THE FUTURE

- 14.00 – 16.00 **Chairs:** Mrs Catherine Kirkpatrick, Lincoln County Hospital, Mrs Hazel Edwards, British Medical Ultrasound Society
- Collaboration and innovation take many forms within ultrasound and BMUS explores how these can be maximised to ensure high value to all stakeholders and the profession. This session will explore the safety of practitioners in an increasingly litigious world and how understanding the pearls and pitfalls of medico-legal issues could make you a better, safer practitioner of the future. Is the future here now? We consider the use of artificial intelligence in ultrasound and explore whether practitioners feel ready for it or nervous of it.
- 14.00 **Maximising the value of professional collaboration**, Dr William Ramsden, Royal Collage of Radiologists
- 14.20 **Maximising the value of multi-professional training in imaging academies**, Mrs Samantha Anderson, East of England Imaging Academy, Norwich
- 14.40 **Patient experience of imaging reports - A systematic literature review**, Charlie Rogers, University Hospitals Dorset
- 14.50 **Professional supervision - How could this support the sonographer workforce?**, Gillian Coleman, University of Derby
- 15.00 **Ultrasound practitioners' perceptions and attitudes towards AI**, Mr Felix Beacher, Informa Tech, London
- 15.15 **The future direction of litigation in Ultrasound: pitfalls and tips for practitioners**, Mrs Alison Hall, Keele University and Cannock Chase Hospital, Mrs Hazel Edwards, British Medical Ultrasound Society, Mr David Howe, Princess Anne Hospital

TUESDAY

WEDNESDAY

THURSDAY

## Education On The Stand - Exhibition Hall

- 13.15 **How to Diagnose Endometriosis - GE Stand 23 and 24**
- Presented by  
Dr Susanne Johnson, Princess Anne Hospital, University Hospital Southampton NHS Trust
- This session is to give you an understanding of how to diagnose Endometriosis on Ultrasound

# DAY THREE

Thursday 8th December

## Satellite Session – Syndicate Room B

### VETERINARY SESSION 1

**08.30 – 10.50** **Chairs:** Mrs Angie Lloyd-Jones, Northwest Veterinary Specialist Hospital, Dr Nuala Summerfield, Virtual Veterinary Specialists

Cover a range of interesting topics and case studies, which promote the use of diagnostic ultrasound as a necessary adjunct to effective patient management.

Continue to promote high standards of clinical ultrasound practice and diagnostic confidence by inviting thought-provoking speakers from a multitude of clinical veterinary ultrasound backgrounds, including expert veterinary specialists, to share their experiences and invaluable clinical knowledge.

Empower multi-disciplinary professionals from both the Veterinary and Medical professions to work better together, improving the quality and standards of small animal ultrasound practice.

Provide an overview of ultrasound governance – how the veterinary field can benefit from lessons learnt within the NHS

Abdominal point-of-care and basic cardiac ultrasound – those all important considerations for proper ultrasound practice!

**08.30** **Welcome and introduction from the Chair and Co-chair,** Mrs Angie Lloyd-Jones, Northwest Veterinary Specialist Hospital

**08.35** **Transducer care,** Dr Nick Dudley, Lincoln County Hospital

**09.05** **The Future of education: Using video, storytelling, and technology to advance veterinary ultrasound education,** Mr Toby Trimble, Trimble Productions

**09.25** **Case study on Mullerian duct abnormality,** Ms Wiktorija Jamont, Northwest Veterinary Specialists

**09.40** **The limitations and merits of having a nurse-led FAST Scan Service at a SA Specialist Hospital,** Ms Annabel Kerr, Wear Referrals

**10.00** **Emergency ultrasound of the abdomen- beyond AFAST,** Dr Emilie Paran, Lanford Vets

**10.30** **Choosing the right ultrasound machine for your needs and post-purchase perks,** Dr Caroline Taylor, Celtic SMR

### VETERINARY SESSION 2

**11.20 – 13.10** **Chairs:** Mrs Angie Lloyd-Jones, Northwest Veterinary Specialist Hospital, Dr Nuala Summerfield, Virtual Veterinary Specialists

**11.20** **Developing decent Doppler skills - tips and tricks,** Miss Borsha Sarker, Leeds Teaching Hospital Trust

**11.45** **Live demonstration of basic cardiac views,** Dr Nuala Summerfield, Virtual Veterinary Specialists with Lille and Bonnie

TUESDAY

WEDNESDAY

THURSDAY

# DAY THREE

Thursday 8th December

## Satellite Session – Syndicate Room B

12.30	<b>Interesting cardiac case studies</b> , Mrs Gaynor Jones, Royal College of Veterinary Surgeons	TUESDAY
12.50	<b>Ultrasound governance and what the veterinary profession can learn from the NHS</b> , Mrs Julie Burnage, Aspire Ultrasound Consultancy Service	
<b>VETERINARY SESSION 3</b>		
14.00 – 16.00	<b>Chairs:</b> Mrs Angie Lloyd-Jones, Northwest Veterinary Specialist Hospital, Dr Nuala Summerfield, Virtual Veterinary Specialists	WEDNESDAY
14.00	<b>An update on BMUS Veterinary Ultrasound Practice Standards Guidelines and ECVDI support</b> , Mr Chris Warren-Smith, Bristol University Veterinary School	
14.40	<b>The urogenital tract</b> , Mr Ian David Jones, European Association of Veterinary Diagnostic Imaging	THURSDAY
15.20	<b>Debate: Is there now a need for a dedicated European Veterinary Ultrasound Society and a BMUS Veterinary Clinical Interest Group to support non-specialist multi-disciplinary veterinary ultrasound users?</b>	
	<b>Faculty for:</b> Mr Chris Warren Smith, Bristol University Veterinary School and Mrs Angie Lloyd-Jones, Northwest Veterinary Specialist Hospital <b>Faculty against:</b> Mr Ian David Jones, European Association of Veterinary Diagnostic Imaging and Mrs Julie Burnage, Aspire Ultrasound Consultancy Service	

## Practical Workshop Session - Syndicate Room C and D

### MSK 1 - UPPER LIMB

**9.00 – 10.50** **Led by** Mr Mark Charnock, Northern General Hospital, and Mrs Amanda Parry, University Hospitals of Leicester NHS Trust

The practical workshops are aimed at those practitioners with MSK ultrasound experience wishing to improve their knowledge and skills in advanced techniques. The areas covered include shoulder and elbow, hip/groin, foot and ankle, complex hand and ultrasound-guided MSK intervention. Delegates will receive maximum benefit from small group tutoring and lots of hands-on practice with an experienced physiotherapist, radiologist and MSK sonographers and facilitating the stations.

### Faculty

Mrs Alison Hall, Keele University and Cannock Chase Hospital  
Mr Richard Brindley, Cannock Chase Hospital  
Mrs Catharine Berry, University Hospitals Leicester  
Dr Harjinder Singh, University Hospitals Leicester  
Dr Ibrahim Azam, Sheffield Teaching Hospital NHS Foundation Trust  
Mr Mike Bryant, Ilkley Physiotherapy.

# DAY THREE

Thursday 8th December

## Practical Workshop Session - Syndicate Room C and D

### MSK 2 - LOWER LIMB

---

**11.20 – 13.10** **Led by** Mr Mark Charnock, Northern General Hospital, Mrs Amanda Parry, University Hospitals of Leicester NHS Trust

The practical workshops are aimed at those practitioners with MSK Ultrasound experience, wishing to improve their knowledge and skills in advanced techniques. The areas covered include shoulder and elbow, hip/groin, foot and ankle, complex hand and Ultrasound guided MSK intervention. Delegates will receive maximum benefit from small group tutoring and lots of hands-on practice with an experienced physiotherapist, radiologist and MSK sonographers and facilitating the stations.

### FACULTY

---

Mrs Alison Hall, Keele University and Cannock Chase Hospital  
Mr Richard Brindley, Cannock Chase Hospital  
Mrs Catharine Berry, University Hospitals Leicester  
Dr Harjinder Singh, University Hospitals Leicester  
Dr Ibrahim Azam, Sheffield Teaching Hospital NHS Foundation Trust  
Mr Mike Bryant, Ilkley Physiotherapy.

TUESDAY

WEDNESDAY

THURSDAY



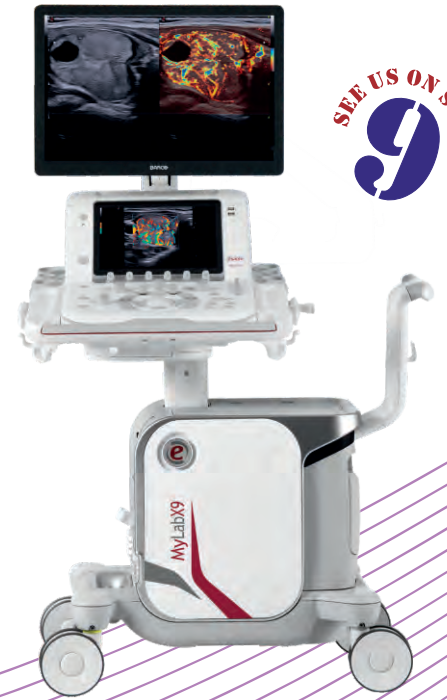# Opening infinite horizons

# MyLab™ X9

Powerful and innovative, the new Esaote MyLab™ X9 with X ULTRA™ platform combines advanced technology with outstanding image quality to explore the infinite horizons of ultrasound imaging.

By combining Artificial Intelligence with insightful workflow and multimodality functionality, MyLab™ X9 steers the Radiologist and Sonographer to new diagnostic frontiers.

Intelligent architecture, benchmark design and premium ergonomics elevate everyday clinical applications to new levels.



INNOVATION



IMAGE QUALITY



CLINICAL EXPERIENCE



CONNECTIVITY



CUSTOMER CARE

# esaote

[www.esaote.com](http://www.esaote.com)





# POSTER EXHIBITION 2022

---



# POSTER EXHIBITION

## 2022

### General Medical

#### 1. **Audit of ultrasound guided percutaneous renal biopsies performed in a large teaching hospital**, Lois Scoffield, Leeds Teaching Hospitals NHS Trust

##### Aims

This audit was undertaken to assess the sample diagnostic adequacy and safety/complication rates of ultrasound guided percutaneous renal biopsies performed in a teaching hospital.

##### Methods

Data were collected retrospectively from a six-month period (September 2020-February 2021) from the trust's electronic patient records and RIS. The sample adequacy for native renal kidneys was set at the presence of 10 or more glomeruli in the core biopsy which was based on a previous audit cycle and Royal College of Radiologists audit template. The Banff Criteria – presence of 10 or more glomeruli and two or more arteries in the core biopsy - formed the standards for the transplant biopsies. Any subsequent complications or repeat biopsies were recorded.

##### Results

Data from 179 patients were included. 30 biopsies were targeted (at a focal lesion), 92 were native (non-targeted) and 57 were transplant biopsies. Operators included Radiology Registrars, Consultant Radiologists and Sonographers. 89% of the targeted biopsies were diagnostic. 66% of the native biopsies were adequate (57% in the previous audit), with a 4% repeat biopsy rate (3% previously). 72% of the transplant biopsies were adequate (67% previously), with a 4% repeat biopsy rate (3% previously). There was a 4% minor complication rate (not previously assessed). One patient (0.6%) had a major complication of active renal bleeding requiring interventional radiological embolization.

##### Conclusion

This audit cycle demonstrated that ultrasound guided percutaneous renal biopsies is a safe and effective procedure with a very low major complication rate and a high chance of obtaining a diagnostic sample for histopathological analysis.

#### 2. **The Hull and East Yorkshire Teaching Hospitals NHS Trust Rapid Diagnostic Service (RDS): Initial evaluation**, Matthew Hiles, The Hull and East Yorkshire Teaching Hospitals NHS Trust

##### Aim

In 2021 The Hull and East Yorkshire Teaching Hospitals NHS Trust (HUTH) introduced a Rapid Diagnostic Service (RDS) pathway in line with NHS England's faster diagnosis standard (FDS) to enable accelerated diagnosis for primary care patients experiencing nonspecific symptoms (NSS) concerning for cancer. Performance evaluations of NSS RDS pathways remain few and the efficacy of this model remains incompletely understood.

##### Method

Retrospective analyses of the electronic patient records (EPRs) of all patients referred onto the HUTH (NSS) RDS pathway between January 2021 and June 2023 is underway. Clinical history, patient demographics, prior laboratory work-up, cancer type and benign serious diagnoses are recorded to evaluate the initial performance of the service.

##### Results

Patient outcomes are being analysed and the distribution of new benign and malignant conditions and those with no significant findings will be presented. Particular attention will be made to reviewing mean referral to cancer diagnosis time, the range of cancers detected, staging and alternative benign but serious conditions identified.

### Conclusions

UK cancer survival rates are lower than some European countries. Almost half of cancer patients are diagnosed as late stage due to the lack of obvious red-flags and difficult to manage vague symptoms. In response to the long-term NHS plan, rapid diagnostic (NSS) services are expanding nationwide with full coverage expected by 2024. This study is focused on one of the largest NSS RDS services in the UK and these data illustrate its effectiveness through providing GPs with accelerated direct access to a tailored diagnostic service for patients experiencing vague symptoms that previously would not fit a traditional two week wait pathway.

### 3. **Rectus abdominis muscle haematoma – Rare cause for acute right iliac fossa pain**, Emma Smith, Torbay and South Devon NHS Foundation Trust

The objective of the investigation was to explain the cause for a young woman experiencing acute right iliac fossa pain of uncertain origin. Pain level was increasing and inflammatory markers nonspecific for likely cause however, as with most female investigations in acute ultrasound, a cyst accident or appendix abnormality was suspected. Examination with ultrasound of the female pelvis will use a curvilinear low frequency transducer and vaginal transducer for gynaecological investigation. More detail of structures require examination with a 14MHz linear transducer where bowel, lymph nodes and superficial tissue can be examined.

Closer examination with the high frequency transducer reveals a rare cause for acute pain where a right rectus sheath haematoma had developed subsequent to a recent gym session. Rectus sheath haematoma is an uncommon cause of acute abdominal pain and is an accumulation of blood in the sheath of the rectus abdominis muscle secondary to rupture of an epigastric vessel or muscle tear often occurring spontaneously or perhaps after muscle trauma.

Ultrasound report protocol defines a follow-up period and on this examination the haematoma was fully resolved at three months. Follow-up scan is essential to rule out other sinister pathologies requiring investigation and all scanning professionals should be aware of this safety strategy.

This case shows that sonographers require enhanced skills to widen their expertise in musculoskeletal anatomy and common pathologies. Expect the unexpected pathologies and utilise specialist trained sonography education to widen skill mix in departments.

### 4. **Scrotal ultrasound; it's not all about the testes! Pictorial review of common (and some uncommon) extra-testicular ultrasound findings**, Justin Davies, Nick Ridley, Radiology, Great Western Hospitals Foundation Trust

Ultrasound is used as the primary imaging modality to assess the scrotum for both acute and chronic conditions. NICE (2022) recommends that patients be referred for ultrasound scans of the scrotum where there are unexplained testicular symptoms or for scrotal swelling which cannot be determined whether it is intra- or extra-testicular; this is often when a patient has incidentally found something abnormal during self-examination or have experienced scrotal pain. These symptoms can often be extra-testicular in origin.

A variety of appropriate extra-testicular scrotal ultrasound cases were identified such as spermatocele, haematocele, scrotal hernia, scrotoliths and scrotal oedema. All cases were seen and assessed during 2021 to 2022 at the Great Western Hospital, Swindon.

This poster aims to demonstrate a wide range of extra-testicular scrotal pathology and can be viewed as a guide for sonographers and clinicians with an interest in scrotal ultrasound showing some of the common extra-testicular findings that may be found.

### 5. **High frequency ultrasound – Use in the Photo Dynamic Therapy Clinic**, Colin Swift, Laura Foster, The Christie NHS Foundation Trust

Basal cell carcinomas (BCC) are the most common form of skin cancer and make up more than 80% of skin cancers seen in the UK. They are primarily caused by exposure to ultraviolet light from the sun or sunbeds but also seen in individuals with certain genetic disorders such as Gorlin syndrome. Several treatment options for this condition are available including surgery, cryotherapy, radiotherapy, and Photodynamic Therapy (PDT). PDT has been shown to be an effective treatment having high clearance rates and excellent cosmetic outcomes. For PDT to be successful the depth of the tumour should ideally be less than approximately 3mm, to ensure both sufficient penetration of the photosensitizing drug, and penetration of the activating light. High frequency ultrasound (HFUS) at 35MHz has been used extensively within the PDT clinic to determine the extent of such tumours. BCCs are clearly defined on such scans having a different echogenicity to the normal

surrounding tissue. Depth measurements of BCCs to be determined are an important factor as it will influence clinical decisions as to whether PDT is a suitable mode of treatment or if other treatment options may be more suitable.

HFUS scans have been undertaken in multiple sites (up to 11) on 213 patients in the last year. The majority (184) were treated for BCCs, 18 for Bowen's disease and 11 for actinic keratosis. The HFUS scans have proven to be very useful in the monitoring of the effectiveness of the treatment and additionally tumour shrinkage should repeat treatments be required. Its use in further applications in skin oncology in the Christie clinic is being explored.

**6. A rare occurrence of Acute Lymphoblastic Leukaemia breast metastasis – sonography's role,** Ciara Maguire<sup>1,2</sup>, Kevin Cronin<sup>2</sup>, Therese Herlihy<sup>2</sup>, Mary Moran<sup>2</sup> Eimear Bourke<sup>1</sup>, <sup>1</sup>St James' Hospital, Ireland, <sup>2</sup>University College Dublin, Ireland

### Background

Medullary and osseous metastases of haematological malignancies are common, however mammary infiltration is extremely rare. Mammary manifestation in acute lymphoblastic leukaemia (ALL), is exceptionally rare with <200 reported cases. ALL typically has high relapse rates and a young presentation thus precluding mammographic investigation. Therefore, sonography plays an important role in lesion detection and characterisation. Sonographic findings are non-specific requiring biopsy to consolidate findings. However, ultrasound can demonstrate both typically benign and malignant image features from which decisions to biopsy can be determined. It can also safely guide any subsequent biopsies, reducing post-biopsy complications. This poster discusses ultrasound's application in a case of leukemic mammary metastasis in a 34-year-old female with a solitary non-tender breast lump on a background of ALL. It highlights ultrasound's strengths and weaknesses in lesion assessment and demonstrates common yet non-specific sonographic appearances of leukemic deposits.

### Ultrasound findings

Sonographic investigation revealed multiple bilateral lesions demonstrating hypoechogenicity with significant solid, echogenic components. Both irregular and well-defined lesion outlines were demonstrated. Heterogenous echotextures of cystic and solid appearances were identified with individual lesions demonstrating capsulation, acoustic shadowing and varied Doppler patterns. Variation in lesion appearances highlighted the non-specificity of this pathological process sonographically. While image findings were inconclusive, ultrasound permits its use to guide tissue sampling to accurately categorise lesions. The lesions were found to have leukemic infiltration attributable to ALL relapse. The patient underwent multiple multiagent chemotherapy cycles to no avail and sadly passed away.

### Conclusion

The incidence of this case presentation is rare while literature and research are sparse and common sonographic findings are non-specific, ultrasound remains a valuable modality in the assessment leukemic mammary infiltration. It allows lesion evaluation especially in young and mammographically occult cases and guides biopsies for conclusive lesion diagnosis.

**7. Passive hepatic congestion - A forgotten cause of abnormal LFTs?,** Jamie Wild, Sheffield Teaching Hospitals

Ultrasound practitioners are often faced with requests where the clinician is trying to determine the cause of abnormal liver function tests (LFTs). The most common pathology encountered in practice which can result in abnormal LFTs is that of fatty liver disease relating to either alcohol use or non-alcoholic fatty liver disease (NAFLD) (Malakouti et al, 2017). Ultrasound has been shown to demonstrate a good sensitivity and specificity (84.8% and 93.6%) in the diagnosis of fatty liver disease (Hernaes et al, 2011). Given the prevalence of fatty liver disease in the population and ultrasound's ability to diagnose fatty infiltration relatively easily, it is vital that ultrasound practitioners do not become complacent, and that other pathological processes are considered, especially when no clear cause for the abnormal LFTs is initially identified during the ultrasound examination.

While there are a host of other causes of abnormal LFTs, passive hepatic congestion (PHC) is one cause of abnormal LFTs which can be overlooked in the pursuit for the more obvious and common fatty liver. PHC may be asymptomatic for a prolonged period of time with the only clue to suspect its presence being abnormalities in the LFTs (Fortea et al, 2020). If not recognised, chronic congestion leads to hepatic injury, eventually



resulting in fibrosis and cirrhosis (Hilscher and Sanchez, 2016). As with any pathology, proper understanding and recognition of the clinical presentation and imaging features are vital to a conclusive diagnosis.

The poster aims to highlight a differential diagnosis for abnormal LFTs and provide information relating to the aetiology, pathophysiology and ultrasound features of PHC so that ultrasound practitioners are better equipped to recognise the pathology and be confident in their diagnosis, which can impact on the follow-up and treatment of a patient.

**8. Early experience of micro-ultrasound prostate imaging,** Pamela Parker, Hull University Teaching Hospitals NHS Trust

Technological advances within the last two to five years have potentially revolutionised the imaging assessment of the prostate gland. There is limited published evidence that the use of ultrasound may, indeed, have a useful role in the identification of prostate cancer (PCa)<sup>1,2,3</sup>. A meta-analysis by Zhang et al<sup>4</sup> in 2019 assessed the sensitivity and specificity of micro-ultrasound detection of PCa. Micro-ultrasound (micro-US) utilises a transducer emitting a scanning frequency of 29MHz compared to the 7 – 9 MHz employed in most standard frequency endorectal ultrasound probes. This provides exquisite imaging of the prostate that traditionally ultrasound has failed to deliver.

Micro-US supplied by ExactVuTM is gaining traction within North America and Europe but there is limited real world practice within the UK. The first micro-US endocavity imaging unit was installed in Radiology at Hull Teaching Hospitals in September 2021. This poster provides a pictorial review of our early experience of this novel, and hopefully ground-breaking, technology and its use within the prostate cancer pathway.

**References**

1. Bevilacqua, G., et al (2019) Diagnostic performance of micro-ultrasound in a contemporary cohort of patients in active surveillance for localized prostate cancer: A single-institutional experience. *European Urology, Supplements*, 18.
2. Eure, G., et al (2019) Comparison of conventional transrectal ultrasound, magnetic resonance imaging, and micro-ultrasound for visualizing prostate cancer in an active surveillance population: A feasibility study. *Canadian Urological Association Journal*, 13.
3. Maffei, D., et al (2019) Diagnostic performance of micro-ultrasound in patients under active surveillance for low-risk prostate cancer. *European Urology, Supplements*, 18
4. Zhang, M., et al (2019) Micro-ultrasound imaging for accuracy of diagnosis in clinically significant prostate cancer: A meta-analysis. *Frontiers in Oncology*,

**9. Can ultrasound simulation practice enhance practical skills and academic knowledge?,** Mohammad Haroon Qarib, London North West University Healthcare NHS Trust Ultrasound Academy

**Introduction**

The use of ultrasound simulator is becoming more popular in ultrasound training centres, it is important to evaluate if ultrasound simulator practice can enhance practical skills and academic knowledge of ultrasound trainees.

**Objectives**

The aim of this study was to evaluate the views of ultrasound trainees who were using the ultrasound simulator at the London North West University Healthcare NHS Trust Ultrasound Academy during their training programme and to determine if using an ultrasound simulator enhanced their practical skills and academic knowledge.

**Method**

A questionnaire was designed to explore the views of 32 trainees who were using the Scan Trainer ultrasound simulator during their training. The completed questionnaires from 23 respondents were used for data analysis to evaluate if using the ultrasound simulator enhanced their practical and academic knowledge.



## Results

The results showed that 100% of respondents thought that the ultrasound simulator enhanced their practical skills and academic knowledge at the beginning of their training, 43% agreed that ultrasound simulator practice enhanced their practical skills and academic knowledge at the middle of their training while only 13% thought it enhanced their practical skills and academic knowledge at the end of their training. This study also found that 20% agreed that trainees should use the ultrasound simulator on a daily basis for an average of 1.8 hours/day, 40% agreed an average usage of 3.5 hours/week and 40% agreed an average usage of 10 hours/month. The majority (96%) agreed that ultrasound simulator practice cannot replace patient-based ultrasound practice.

## Conclusions

Using the ultrasound simulator can enhance practical skills and academic knowledge, it should be used regularly by all trainees who have access to an ultrasound simulator at the beginning and middle stages of their training. The majority of respondents agreed that simulation training cannot replace patient-based scanning.

### 10. **Ultrasound past, present and exciting future**, Richard Beese, Queen Elizabeth Hospital and Kings College Hospital London.

The author dedicates the talk to Prof Cosgrove and Dr Hylton Meire who have recently passed. Their contribution to ultrasound cannot be understated, taking ultrasound in its infancy from the bench to the patient. Both doctors researched, pioneered, published books and papers, and taught ultrasound.

The talk will concentrate on the history and evolution of ultrasound imaging and technology and will look to the future of this exciting versatile imaging modality. Different clinical settings of the use of ultrasound will be discussed from a perspective of austere and global locations.

### 11. **Incidental finding of a peripheral nerve sheath sarcoma**, Sadie Dunne, Ultrasound, Benenden Hospital, Kent

A 30 year old female presented with six month history of calf pain with foot drop and a recent intense calf pain and swelling. No history of trauma. Initial referral for MRI scan of her foot and ankle reported suggested myopathic changes in several muscles. No follow-up treatment given. Patient experienced difficulty walking and developed localised severe calf pain and was referred by her GP for an ultrasound of her leg veins to exclude DVT.

On ultrasound examination there was no evidence of a DVT, however, in the popliteal fossa a well-defined, heterogeneous, intramuscular mass was visualised extending down the posterior calf with abnormal vascularity measuring 20 cm in length with a diameter of 6 x 6 cm. Images were reviewed immediately by a radiologist and referred for urgent MRI calf.

MRI reported a well-defined elongated intermuscular soft tissue mass lesion in the calf closely related to the neurovascular bundle, suspicious for a tumour of neurogenic origin, possibly a malignant peripheral nerve sheath tumour or given its close relationship to neurovascular bundle possibly a leiomyosarcoma. The previous signal changes on the MRI foot could be due to denervation/compression of the posterior tibial nerve.

Patient was referred to the specialist sarcoma team and underwent amputation and is undergoing chemotherapy. She has been hospitalized with sepsis twice since surgery.

Malignant peripheral nerve sheath tumours (MPNST), also known as neurofibrosarcomas, can occur anywhere throughout the body, mainly in adults.

MPNST is a rare malignant mesenchymal lesion that accounts for 5% to 10% of all soft tissue sarcomas. They are extremely aggressive with high local recurrence rate and poor survival. Early diagnosis of sarcoma increases the chance of successful treatment. Resection surgery with a margin is the main therapy for MPNST, radiation and systemic chemotherapy are also widely used despite their uncertain effect.

## Gynaecology

### 12. **Granulosa cell tumour of the ovary**, Deirdre Murphy, University Hospital Southampton NHS Trust

#### Background

A 48 year-old patient was referred by her GP to the Ultrasound Department for an urgent pelvic ultrasound scan querying ovarian pathology. The patient presented with abdominal distension and pain. Blood tests revealed suppressed FSH/LH but normal oestrogen levels. She also had been experiencing irregular heavy bleeding over the past six months which she believed was associated with the menopause.

#### Case Report

Her ultrasound report revealed a thickened (23mm), inhomogeneous endometrium with multiple, interspersed cystic spaces. The endocervix also had an unusual appearance with evidence of multi-cystic change and endocervical expansion. A 162 x 102 x 116mm avascular, multilocular ovarian cyst with appearances suggestive of a mucinous cystadenoma was identified in the left adnexa. A mixed solid and cystic vascular mass measuring 107 x 81 x 86mm was identified in the right adnexa. Appearances suggested an ovarian malignancy.

A CT scan was performed and reported a suspicious 113mm solid right ovarian mass, marked endometrial thickening and an unusual cervical appearance. This raised the possibility of a secreting sex cord stromal ovarian tumour. A 170mm multilocular minimally complex left adnexal cystic mass was also noted. No measurable lymphadenopathy or evidence of metastatic disease.

#### Discussion

The patient was admitted and had an emergency hysterectomy, bilateral salpingo-oophorectomy and omentectomy. It was later confirmed that she had a granulosa cell tumour of the ovary, which secretes the female hormone oestrogen. This causes symptoms such as abnormal vaginal bleeding and endometrial hyperplasia, which was this patient's original presentation.

Adult granulosa cell tumours are diagnosed in middle-aged and older women; typically occurring during the perimenopausal or postmenopausal years. They are slow growing malignant tumours that can spread locally within the peritoneum and may recur in 25% of patients.

### 13. **How accurate is ultrasound in diagnosing molar pregnancy?**, Alex Rourke, Nottingham University Hospitals

#### Background

Diagnosing molar pregnancy with ultrasound is challenging. The project aim was to assess the accuracy of Trust A's ultrasound service in diagnosing molar pregnancy.

#### The objectives were to

Find how many histologically proven cases of molar pregnancy were suspected after ultrasound examination.

Analyse the data collected to determine whether current practice at Trust A needs to be adapted.

#### Method

This project is a retrospective single centre study with a descriptive design. A literature review, including critical appraisal of literature, demonstrated the relevant previous research and provided a clear rationale for the project.

Data were collected from 1 January 2015 to 31 December 2021. All cases of histologically diagnosed molar pregnancy at Trust A were found. The ultrasound report for these cases was accessed to determine if a molar pregnancy was suspected after ultrasound examination.

An image review was performed to assess whether pre-determined sonographic features of molar pregnancy were demonstrated in cases of partial molar pregnancy (PMP) where a molar pregnancy was not diagnosed on ultrasound examination.

## Results

Data collection found 108 participants with a histologically proven molar pregnancy. 34% were complete molar pregnancy (CMP) while 66% were PMP. 92% of CMP were diagnosed at the ultrasound examination while 27% of PMP were detected on ultrasound.

The image review found that 84% of the cases where a PMP was undiagnosed by ultrasound had sonographic features of the condition.

## Conclusions

The results showed that Trust A's ultrasound detection rates are consistent with the studies found in the literature. However, the diagnoses of PMP were at the lower end of the range when compared to previous research. This suggests that diagnosing a PMP with ultrasound could be operator dependent, an argument supported by the image review, and that practice at Trust A could be adapted to improve detection rates.

### 14. **Interesting cases of the three-dimensional (3D) uterus/endometrium in patients with suspected infertility**, Farrah Elshahir, Pamela Norbury, Royal United Hospital, Bath

#### Background

NICE (2014) identifies 1 in 7 heterosexual couples are affected by infertility, furthermore, WHO (2020) estimates that globally, between 48 million couples and 186 million individuals live with infertility. It is imperative that infertility is addressed, as individuals and couples have the right to a family. Although sometimes unexplained, multiple factors can affect fertility including uterine disorders and endometrial pathology. Two-dimensional (2D) ultrasound is one of the first diagnostic tests to be requested in suspected infertility. Assessing the uterus/endometrium with the addition of 3D ultrasound gives further detail and accuracy, aiding the ultrasound practitioner to make a diagnosis.

#### Case Report

A pictorial review identifies multiple pathologies including an endometrial polyp, submucosal fibroid, septate uterus, arcuate uterus and adhesions. All patients included in the review attended the ultrasound department for a pelvic ultrasound examination (transabdominal and transvaginal) due to primary/secondary infertility. After initially suspecting pathology by 2D ultrasound, the uterus and endometrium were further assessed using 3D ultrasound. The review makes a comparison of the 2D and 3D images, technique of obtaining the optimal image including settings and knobology is also discussed.

#### Discussion

Ultrasound is one of the first tests requested in patients with suspected primary/secondary infertility. Its role in assessing the uterus and endometrium is crucial. The addition of 3D ultrasound provides further detail and accuracy when an initial anomaly or pathology is suspected by 2D ultrasound. An ultrasound practitioner must recognise the appearances of pathology/anomalies on 3D assessment to give further information to the referring clinician. Appropriate training should be given by application specialists or from senior staff who are proficient in this technique.

### 15. **Is three-dimensional ultrasound or magnetic resonance imaging more effective in the diagnosis of congenital uterine anomalies?**, Manjit Bual, University Hospitals of Derby and Burton NHS Foundation Trust

#### Introduction

Congenital uterine anomalies (CUAs) are embryological malformations of the uterus. Infertility, recurring miscarriage, and fetal intrauterine growth restriction are common symptoms of CUAs. Accurate diagnosis of the type of CUA is vital for patient management. The Royal College of Obstetrics and Gynaecologists (RCOG) considers three-dimensional transvaginal ultrasound (3D TVS) to be the gold standard for diagnosing and classifying CUAs because it is more reproducible and less invasive than other imaging and surgical diagnostic modalities (RCOG, 2019).

Trust A currently only indicates Magnetic Resonance Imaging (MRI) when diagnosing CUAs. However, 3D TVS may provide a more accessible and cost-effective pathway for patients.

### Method

A systematic literature search has been conducted using the seven most relevant healthcare databases: Cinahl Complete, Directory of Open Access Journals (DOAJ), EBSCO Medical Databases, Embase, Medline, Science Direct and Scopus. Boolean search operators were utilised and results were refined to the past six years (2016-2022) to increase relevance to practice and generalizability. This resulted in three primary articles.

### Results

Three-dimensional ultrasound is a viable alternative to pelvic MRI, it is less expensive than MRI and patients tolerate it better. 3DTVS has been reported to have strong diagnostic agreement with MRI. With one study suggesting that 3D ultrasound is superior in identifying and categorising CUAs. The literature review demonstrated that the RCOG's recommended practice is substantiated by current research.

### Relevance to practice

By utilising 3DTVS, local gynaecology services can assist, manage and share the workload of the imaging department, making these services more beneficial for both the patient and the practitioner. Sonographer progression would be aided by increased work responsibilities.

### Conclusion

Trust A should integrate 3D ultrasound into the CUA patient pathway to improve patient care by supplying more accurate diagnostic equipment. More research on larger cohorts with more challenging CUAs is still required.

## 16. **The role of a standardised ultrasound reporting template to report and diagnose deep infiltrative endometriosis**, Rebecca Bird, Cambridge University Hospitals NHS Foundation Trust

### Background

Endometriosis affects up to 1 in 9 females and can take on average 8 years to diagnose. The most common symptoms of endometriosis include chronic pelvic pain, painful bowel movements and infertility. Whilst NICE guidelines advise an ultrasound scan for when symptoms become severe or when intervention is unsuccessful, there is no national guidance on how practitioners should scan for endometriosis.

### Aim

This study aimed to evaluate the use of a structured investigation and reporting template when diagnosing patients for potential endometriosis with ultrasound.

### Methods

Diagnostic yields of both pre- and post-template assessments for sonographers and consultant radiologists were compared and analysed. Their experiences of using the template were recorded and discussed. In total, 355 patients were included in the study and statistical analysis calculated to evaluate reliability of the results.

### Results

Diagnostic yields were improved following the implementation of the template. There was no statistical correlation between age and prevalence of endometriosis without or with template ( $P = 0.166$  and  $0.58$  respectively). There was statistical correlation between increased age and prevalence of adenomyosis either without or with a template ( $P = 0.00069$  and  $P = 0.000074$  respectively). Template increased confidence in diagnosing endometriosis, however, caused time pressures.

### Conclusion

Sonographers' diagnostic yields increased with the use of a structured scan method and report template. They did however feel time pressure in using these, so adjustments would need to be made to scanning lists, further training, and familiarisation with the template.

### References

Deslandes, A., Parange, N., Childs, J.T., Osborne, B. And Bezak, E., 2020. Current status of transvaginal ultrasound accuracy in the diagnosis of deep infiltrating endometriosis before surgery: A systematic review of the literature. *Journal of Ultrasound in Medicine*, 39(8), pp. 1477-1490.

NICE, 2017, Algorithm for diagnosing and managing endometriosis. Available: <https://www.nice.org.uk/guidance/ng73/resources/algorithm-for-diagnosing-and-managing-endometriosis-pdf-4595719645>

Young, S.W., Groszmann, T., Dahiya, N., Caserta, M., Wasson, M. and Patel, M.D., 2020. Sonographer-acquired ultrasound protocol for deep endometriosis. *Abdominal Radiology*, 45(6), pp. 1659-1669.

- 17. Pelvic phleboliths as a diagnostic challenge for the ultrasound specialist**, Olga Pushkarenko<sup>1</sup>, Olexandr Telehuz<sup>2</sup>, Olesya Horlenko<sup>1</sup>, Olena Ustych<sup>1</sup>, Vasyl Kaliy<sup>1</sup>, Viktor Pushkarenko<sup>1</sup>, <sup>1</sup>Uzhhorod National University, Poland, <sup>2</sup>Diagnosics Central District Hospital, Poland

### Objectives

Phleboliths are calcified intravenous blood clots that may result from changes in coagulation or fibrinolytic activity, from local venous damage, or a combination of these factors. They may mimic ureteric calculi, and are also encountered frequently in venous malformations. The purpose of our presentation of the clinical case is to highlight the value of ultrasound in the differential diagnosis of pelvic phleboliths.

### Methods

Ultrasound examination was performed on a Canon Aplio machine using B-mode, Doppler, convex, linear and endocavitary probes.

### Results

A 72-year-old woman was admitted to hospital with suspected stones in the distal left ureter. There were no significant medical conditions. History of varicose veins of the lower extremities, post thrombophlebotic syndrome, analysis of urine without changes. Transabdominal examination using a convex probe did not identify dilatation of the urinary collecting system, and urine was present in the bladder. Transvaginal examination showed both distal ureters were empty, but the pelvic venous plexus on the left contained several hyperechoic round inclusions (ring-calcified lesion) with acoustic shadowing and approximate diameters of 3 to 7 mm. Polypositional scanning and Doppler examination allowed us to reliably verify the presence of phleboliths.

According to the literature, such a finding is diagnosed incidentally and does not require treatment. These lumps are more common in women aged over 40 and are associated with constipation and straining, which can damage pelvic veins, diverticulosis, varicose veins, and pregnancy. Histologically, phleboliths are composed of small blood clots in a vein that harden over time due to formation of laminated fibrous tissue and calcification.

### Conclusions

There are many cases of diagnostic errors and repeated examinations for the differential diagnosis of phleboliths and stones in the urinary tract. Transvaginal or transrectal visualisation is a highly specific method for clarification and a good alternative to X-ray, MRI and CT examination.

- 18. Adenomyosis: What the sonographer needs to know**, Kelly Foley-Friel, Medica Diagnostics, Ireland

### Background

Adenomyosis is a benign gynaecological condition defined as growth of endometrial tissue within the myometrium (Chapron et al, 2020). It is a condition with varying symptoms resulting in a challenging clinical and imaging diagnosis. Ultrasound is the first line imaging modality for adenomyosis. Technological advances within ultrasound have led to an increase in diagnosis compared with the formerly invasive diagnosis based on histopathology. Whilst transabdominal ultrasound has a limited role to play, transvaginal ultrasound (TVUS) has the capability in the hands of an experienced operator (Chapron et al, 2020).

### Clinical presentation

There is no consensus amongst published literature regarding the pathogenesis of adenomyosis (Chapron et al, 2020). Patients can present with abnormal uterine bleeding, infertility and pelvic pain, however in a small proportion it can be asymptomatic. The clinical bimanual examination accompanied with a detailed history raises suspicion of adenomyosis. Most physicians subsequently look to confirm their suspicions with ultrasound.

### Sonographic signs of adenomyosis

TVUS allows for a dynamic scan assessing organ mobility and patient pain. Sonographic appearances suggestive of adenomyosis are the following: globular uterus, myometrial cysts, myometrium thickening (focal or diffuse), "venetian blind shadowing", heterogenous myometrium, echogenic striations and poor



endometrial-myometrial junctional zone. The presence of increased vascularity of the myometrium and translesional vascularity can be seen in patients with adenomyosis. Adenomyosis can also be evident with comorbidities such as endometriosis or fibroids (Van Den Bosch et al, 2015).

### Discussion

MUSA's (Morphological Uterus Sonographic Assessment) goal was to provide standardisation for assessing and reporting adenomyosis. Whilst, there is still no consensus regarding the most specific sonographic sign for adenomyosis, there is agreement the more sonographic signs evident increases the predictive value (Chapron et al, 2020). There is a need for continued awareness of the condition amongst sonographers and its associated sonographic signs.

## 19. **Imaging of urethral and sub-urethral masses - The University Hospitals of North Midlands NHS Trust experience,** Rameesha Anwar, University Hospital North Midlands NHS Trust

Swelling around the urethra and vagina is a common clinical presentation in females and can represent a range of differentials including female urethral diverticulum and periurethral masses. Patients often present with non-specific signs and symptoms and physical examination can be unreliable. Although distinguishing between urethral and vaginal wall masses can be clinically challenging, it impacts on whether a gynaecology or urology referral is indicated and hence completely alters the patient's future management. Therefore, being familiar with optimal imaging techniques as well as identifying the key imaging features of urethral and periurethral disease in female patients is an increasing requirement for radiologists.

Imaging the female urethra with magnetic resonance imaging has improved greatly and provides high resolution multiplanar images, allowing for greater diagnostic accuracy. However, there is currently emerging technology using 3D endovaginal ultrasound (EVUS) to assess and evaluate the structures of the pelvic floor and related pathology. In our centre, 3D EVUS is used with a high-frequency (12-16 MHz ) endocavity transducer that provides automatic 360° image acquisition. Providing high 3D resolution and diagnostic ability, we have found that it has, at times, negated the need for costly and time consuming MRI. As the use of 3D EVUS is poorly documented in the literature, the objective of this presentation is to discuss ultrasonographic techniques and its advantages in imaging females with sub-urethral masses.

## 20. **Haematocolpos,** Deirdre Murphy, Ultrasound Training Academy, University Hospital Southampton NHS Trust

### Background

A 17-year-old patient was referred to the Ultrasound Department by her GP because despite starting normal puberty development several years previously, she had not yet had a period. The patient did not suffer from any pelvic pain but occasionally noticed a painless swelling that would disappear after a few days. She had been investigated for an eating disorder despite having stable weight and normal BMI. The GP requested an ultrasound scan for primary amenorrhea.

### Case Report

A transabdominal pelvic ultrasound scan was performed, and demonstrated a distended vagina, containing diffuse low-level echoes measuring approximately 18 x 10 x 11cm. Appearances suggested a haematocolpos.

An MRI scan was also performed and reported that the vagina was grossly distended measuring approximately 20 x 10 x 10cm. The report confirmed a haematocolpos showing good agreement with the ultrasound scan.

### Discussion

The patient was admitted for a procedure to open the hymen or hymenotomy in order to allow normal menstruation. Examination under general anaesthetic revealed a thick transverse vaginal septum. This was excised and approximately 1000mls of old retained menstrual blood was drained. The consultant reported the reconstruction went well. This resulted in a complete resolution of her symptoms. Further management advised follow up with physiotherapy for vaginal dilation consideration if needed to maintain the vaginal entrance.

Haematocolpos is a rare medical condition where the vagina is filled with menstrual blood. It is usually caused by a combination of menstruation with an imperforate hymen. Abnormalities in the development of the Müllerian ducts result in imperforate hymen.

## Head and Neck

- 21. Sonographer led one-stop neck lump clinic – 3 year review**, Nicola Davidson, Worcestershire Acute NHS Trust

### Objective

A sonographer led one-stop neck lump clinic was introduced three years ago to support patient flow, improve two week wait times and provide quicker access to fine needle aspiration (FNA). The clinic was designed with a biomedical scientist support to provide immediate results regarding FNA adequacy. The objective of the audit was to provide an overview of the service and to identify any further areas of development.

### Methods

A retrospective audit was performed, of all patients who attended the one-stop neck lump clinic within the 3-year period. CRIS records were used to obtain details of the scan type, any pathology identified, who performed the scan and whether FNA was performed. Histology of all FNAs was reviewed to form part of the final diagnosis and provide results on adequacy. Each 12-month period was reviewed and compared, special consideration was made to see if the service had been affected by COVID-19.

### Results

Numbers attending the clinic over the 3-year period have remained similar with no impact due to COVID-19 other than the initial reduction in the first two weeks of the first 'lockdown'. The number of patients attending who had significant/malignant pathology also remained stable over the three years (approx. 20% of all attendees) although there seems to have been a shift with more thyroid pathology in year 3.

### Conclusions

Clinic was not significantly impacted by COVID-19 and is continuing to provide a good level of service to support the ENT team with quick access to FNA and also enabling discharge of patients with benign findings at the same appointment.

- 22. Can a sonographer be trained to be proficient in head and neck ultrasound with fine needle aspiration cytology? The implementation of a head and neck sonographer and the impact on the service**, Roma Dave, Portsmouth Hospitals University NHS Trust

### Aim

Ultrasound-guided fine-needle aspiration cytology (FNAC) is a commonly performed procedure and often the first line of diagnostic testing for patients presenting with a head and neck swelling. This technique yields a high accuracy rate and is recommended by NICE guidance. The head and neck ultrasound waiting list consequently, has always highlighted capacity issues and this became more pronounced during Covid-19 due to the temporary cancellation of clinics. The aim of training a sonographer was to reduce the ultrasound waiting list and allow the radiologists more time in other areas, such as reporting cross-sectional imaging. The aim of this study was to document how training was undertaken, and whether FNAC success rates were comparable to those performed by radiologists.

### Method

In-house training was undertaken over a 12-month period, by three consultants, in an acute and outpatient setting. A retrospect audit was performed of FNAC outcomes, comparing sonographer and radiologist non-diagnostic rates, over an 18-month period. Statistics of the ultrasound waiting list were also analysed over this period.

### Findings

250 FNAs performed by a sonographer were analysed. Results showed a 71% conclusive rate. This was compared to a previous 4-year audit, undertaken by radiologists within the department. The comparison study analysed 1222 FNAC samples and demonstrated a non-diagnostic sample of 27.2%. This was compared with the RCR live audit, which expects a 70% diagnostic rate for FNAC samples of the thyroid. This study demonstrated comparable FNAC results between a sonographer and consultant radiologist. Statistics also showed a decrease in the ultrasound waiting list, from 310 patients to 114 patients in the past 18 months.

### Conclusion

It is possible to train a sonographer to become proficient in head and neck scanning with FNAC and for cytology rates to be comparable to that of a radiologist. The study showed a positive impact on the ultrasound waiting list.

## 23. **Thyroid U-scoring and subsequent fine needle aspiration cytology: A quality improvement project,** Jordan Ng Cheong Chung, Queen Elizabeth Hospital

### Background

The British Thyroid Association (BTA) 2014 guidelines recommend assigning a U-score to thyroid nodules based on their sonographic characteristics and advise which nodules require ultrasound-guided fine needle aspiration cytology (FNAC) based on the U-score. They also recommend which sampled nodules require further management, including repeat FNAC, based on their cytology results (Thy-score). This has implications in terms of time, cost and on the two-week rule pathway. This quality improvement project assessed compliance with these guidelines.

### Methods

Thyroid ultrasound reports were reviewed for a U-score and whether FNAC was subsequently performed in the appropriate patients based on the U-score in line with the current BTA 2014 guidelines. A change was proposed by educating sonographers and placing laminated educational U-scoring guidelines with corresponding ultrasound examples in all ultrasound rooms to increase compliance with the guidelines with a target of 100% of ultrasound reports to include a U-score and FNAC to be performed in U3-U5 nodules only.

### Results

Before the intervention, 61 out of 132 scans (45%) included a U-score and 9 out of 12 patients had FNAC when radiologically indicated. Three patients who did not have FNAC died or were needle phobic. After the intervention, 44 out of 78 scans (56%) included a U-score. 11 out of 11 patients either had or were referred for FNAC when radiologically indicated.

### Conclusion

The 100% target was not met but there was an increase in reports with U-score suggesting more compliance with the BTA 2014 guidelines. FNAC are performed in appropriate patients.

## 24. **The role of ultrasound in a radiolucent ingested fish bone- A case report,** Ketan Vadhavania, N.Tyagi, S. Rice, R.Lingam, London North West University Healthcare NHS Trust

### Background

A 56 year old man presented to A&E two weeks after the ingestion of a fish bone with throat pain, swelling and systemically unwell. He underwent a CT neck and chest which did not demonstrate any radiopaque FB but did show an infrahyoid collection, inseparable from the left thyroid lobe. An ultrasound performed at the time also did not demonstrate a FB but showed a large organised collection within the thyroid, and suppurative thyroiditis was confirmed on cytology.

### Management

The patient was managed conservatively and improved; however a follow-up ultrasound demonstrated a linear hyperechoic lesion within the left thyroid lobe, thought to be a fish bone. A fish bone sitting on top of the left thyroid lobe adjacent to the left vagus nerve was confirmed during surgery.

### Discussion

Traditionally plain film radiography and cross-sectional imaging is the choice of investigation for ingested foreign bodies, but we are able to demonstrate how the use of ultrasound can help in complex cases where the ingested foreign body is radiolucent. We would also like to discuss the relative radiopacity of common UK fish bones and why there is a difference in radiopacity.

## Musculoskeletal

- 25. Hamstring muscle architecture using wide field of view ultrasound: A reliability study,** Kevin Cronin<sup>1</sup>, Shane Foley<sup>1</sup>, Sean Cournane<sup>1</sup>, Giuseppe de Vito<sup>2</sup>, Eamonn Delahunt<sup>1</sup>, <sup>1</sup>University College Dublin, Ireland, <sup>2</sup>Department of Biomedical Sciences, University of Padova, Italy

### Introduction

The prevalence of hamstring strain re-injury is high among field sport athletes, and ranges from 14%-34% within the same competitive season. Ultrasound is the most commonly used medical imaging modality to assess the architectural characteristics of skeletal muscle. However, acquisition of hamstring muscle architecture is challenging and operator dependent.

### Aim of investigation

To assess the reliability of wide field of view (WFOV) ultrasound (US) to quantify the muscle architecture of the hamstring muscles.

### Methods

Twenty male athletes were sonographically assessed on two separate occasions. Static ultrasound images were collected by a single sonographer using a 92mm linear transducer to assess the architectural characteristics (muscle length, fascicle length, pennation angle and muscle thickness) from two distinct locations of the BF<sub>lh</sub> and SM of the left limb. Muscle length and thickness were assessed in the BF<sub>sh</sub> and ST muscle of the left limb. Intraclass correlation assessed intra-rater reliability.

### Results

Both muscle (ICC = 0.99; SEM = 4.3-6.6mm) and fascicle (ICC = 0.92-0.98; SEM = 1.1-2.4mm) length were measured with excellent intra-rater reliability. Muscle thickness was measured with excellent reliability (ICC = 0.9-0.96; SEM = 0.91mm-1.4mm) for all hamstring muscles except for the proximal segments of the BF<sub>sh</sub> (ICC = 0.85; SEM = 0.84mm) and ST (ICC = 0.88; SEM = 0.82mm) which measured good reliability. Pennation angle was measured with good reliability (ICC = 0.77 - 0.87; SEM = 1-1.6).

### Conclusions

Static WFOV is a reliable ultrasound technique to quantify the architectural characteristics of the hamstring muscles.

## Obstetrics

- 26. Live interstitial ectopic pregnancy,** Carol Green, Bradford Teaching Hospital Foundation Trust

### Background

An ectopic pregnancy occurs when a fertilised ovum implants outside the uterine cavity. 96% of all ectopic pregnancies will be located in the fallopian tube. Rarely, 3-5% of ectopic pregnancies may present in other locations such as abdominal, cervical, interstitial or ovarian.

An interstitial ectopic pregnancy occurs when the fertilised ovum implants in the proximal portion of the fallopian tube located within the myometrium. Transvaginal ultrasound scanning (TVUS) is a good method for early pregnancy assessment due to the increased image quality. Three-dimensional transvaginal ultrasound (3DUS) may be of benefit and aid diagnosis due to its increased image resolution.

### Case report

37-year-old pregnant patient was referred to early pregnancy assessment unit with vaginal bleeding and back ache. Ultrasound revealed a normal endometrial thickness measuring 4mm, with no evidence of an intrauterine or ectopic pregnancy.

In view of the ultrasound findings and the positive hCG levels the patient underwent a diagnostic laparoscopy to assess for an ectopic pregnancy, which showed no evidence of an ectopic pregnancy.

The patient re-presented four weeks later as her pregnancy test remained positive. TVUS again revealed a normal endometrial thickness, however at the right lateral border of the uterus a live ectopic pregnancy was identified.

### Discussion

Due to the rarity of interstitial pregnancies, this form of ectopic pregnancy can be misdiagnosed as a viable intrauterine pregnancy. Having highly trained sonographers scanning the patient will help reduce misdiagnosis. 3DUS can improve general diagnosis due to the increased image quality. However, in this case there was no sign of pregnancy at the initial ultrasound scan, therefore at this stage using 3DUS would not change the clinical diagnosis.

On follow up TVUS, the pregnancy had developed thus was visible and demonstrated classical signs of an interstitial ectopic pregnancy. Using 3DUS would not have added to the clinical diagnosis.

## 27. **POPS2 Patient and Public Involvement (PII): Avoiding tokenism and gathering meaningful feedback to shape research delivery**, Ellen Dyer, Amy Sutton-Cole, Department of Obstetrics and Gynaecology, University of Cambridge

### Background

The importance of PPI (public and participant input) is widely recognised and enables participants to shape research. Continuous PPI is often a requirement of funders and ethical bodies. The challenge for study delivery is finding a way to undertake PPI in a meaningful way.

### Aim

To collate the views of POPS2 (Pregnancy Outcome Prediction Study 2) participants to identify areas of good practice, and those requiring improvement to enhance the participant experience. POPS2 is a prospective study of nulliparous women with a singleton pregnancy which uses ultrasound scans and biochemistry to determine whether screening and intervention for preeclampsia or fetal growth restriction at term can correctly identify women at increased risk of complications and improve the outcome for mother and infant.

### Methods

Feedback from participants was collected by a participant experience survey. The survey was given to 50 consecutive participants following their final study visit in late 2021.

Views on waiting times, environment, ease of access and interactions with sonographers were sought.

### Findings

Responses were overwhelmingly complimentary; however, the following learning points were identified:

- Women needed reassurance that reporting of third trimester growth is not indicated in low-risk pregnancies
- Research scans should be co-ordinated with clinical scans
- Communication about upcoming appointments should be improved

### Outputs/organisational learning

The findings of the survey were disseminated to study staff. In response to the learning points identified additional staff training, as well as changes to consent messaging and pre-appointment text messages were implemented in 2022. The survey will be repeated in the summer 2022 to monitor the impact of these changes and identify any new issues that may have arisen. By adopting a cyclical approach, it is anticipated the study PPI will remain meaningful for both participants and study team throughout the study and avoid it becoming a tokenistic exercise.



## Paediatrics

- 28. Audit of patients for right iliac fossa pain with clinical concern for appendicitis referred for ultrasound, do the ultrasound findings correlate with surgical findings?**, T.J. Wilson, Hull Royal Infirmary

### Aims

To determine whether ultrasound findings correlated with surgical findings comparing to contemporary research findings.

### Introduction

Abdominal pain is a common complaint in children with multiple pathologies ranging from malrotation to Meckel's diverticulum. Appendicitis is a common surgical complaint with 8%<sup>1</sup> of all people having lifetime risk, and one peak occurs aged between 10 and 30 years old<sup>2</sup>. Accurate diagnosis can be challenging<sup>3</sup>, first line investigation in children other than blood tests include ultrasound. Many research studies show varying sensitivity and specificity, however, many of these research studies include adult patients.

### Methodology

This was a retrospective audit carried out between 1st January 2020 to 31st December 2021. The sample comprised 132 patients aged between 0 and 16 years old. These children all had an ultrasound scan and were then followed up by a surgical review which consisted of clinical correlation to determine to proceed to surgery.

### Findings

Of the 132 children, 29 children had surgical findings of appendicitis. 21 of these patients also were reported as having ultrasound findings of appendicitis (true positive). 8 patients had a negative ultrasound, i.e. not having imaging appearances suggesting appendicitis, but were found to have surgical findings of appendicitis (false negative). There was one false positive and 102 true negatives. Sensitivity 95% and specificity of 93%.

### Conclusion

This audit has shown that there is a high specificity (93%) for diagnosis of appendicitis on ultrasound and a sensitivity of 95%. This range corresponds to studies ranging from specificity of 85 – 98% and sensitivity between 55 – 96%<sup>4,5,6</sup>. Over a 12 month period 29 children were found to have appendicitis.

1. Bethell GS., Rees CM., Sutcliffe JR. Hall NJ et al Management and early outcomes of children with appendicitis in the UK and Ireland during the COVID-19 pandemic: a survey of surgeons and observational study *BMJ Paediatr Open*. 2020; 4(1): e000831. Published online 2020 Oct 22. doi: 10.1136/bmjpo-2020-000831
2. Di Saverio et al 2020 Diagnosis and treatment of acute appendicitis: 2020 update of the WSES Jerusalem guidelines *World Journal of Emergency Surgery* 2020 Apr 15;15(1):27. doi: 10.1186/s13017-020-00306-3.
3. Howell EC., Dubina ED. and Lee SL Perforation risk in pediatric appendicitis: assessment and management *Pediatric Health Med Ther*. 2018 Oct 26;9:135-145. doi: 10.2147/PHMT.S155302.
4. Yabunaka K, Katsuda T, Sanada S, Fukutomi T. Sonographic appearance of the normal appendix in adults. *J Ultrasound Med*. 2007;26(1):37-43; quiz 45-6.
5. Heller MT, Hattoum A. Imaging of acute right lower quadrant abdominal pain: differential diagnoses beyond appendicitis. *Emerg Radiol*. 2012;19(1):61-73.
6. Quillin SP, Siegel M. Appendicitis in children: color Doppler sonography. *Radiology*. 1992;184(3):745-7.

- 29. Give it a whirl: Sonographic signs to look out for in intermittent testicular torsion**, Kelly Foley-Friel, Ultrasound Medica Diagnostics, Ireland

### Background

Testicular torsion is a medical urological emergency and one of the most common causes of acute paediatric scrotal pain. Testicular torsion is defined as twisting of the spermatic cord resulting in testicular perfusion

disruption. There are different types of torsion: complete, partial or intermittent (Munden et al, 2013). For intermittent testicular torsion, clinical presentation includes acute unilateral scrotal pain with spontaneous resolution.

### Pathophysiology

The cause of intermittent testicular torsion is usually intravaginal and caused by the bell clapper deformity. The bell clapper deformity is a condition where the tunica vaginalis envelopes the testicle, epididymis and distal spermatic cord. As a result, there is no posterolateral attachment of the testicle to the scrotal wall allowing the testicle to freely twist (Esposito et al, 2014).

### Sonographic signs

Sonographic diagnosis of intermittent testicular torsion using colour Doppler proves very difficult as a patient may have preserved or only subtly decreased intratesticular blood flow. Sonographic appearances that are suggestive include the “whirlpool sign” (a spiral twist of the spermatic cord) and presence of a pseudomass. This sign is highly suggestive even in a testicle with normal blood flow. It can also be seen in complete torsion. A testicular volume discrepancy or abnormal horizontal lie of the testicle along with the patient’s clinical history can additionally raise suspicions.

### Discussion

The probability of salvaging the testicle and sonographic appearances are directly proportional to the onset of clinical symptoms (Esposito et al, 2014). Ultrasound diagnosis is very useful in the differential diagnosis of acute paediatric scrotal pain. When a diagnosis of intermittent testicular torsion is made, patients undergo surgical exploration for detorsion and orchiopexy (Nishizawa et al, 2021). It is important to identify any type of testicular torsion as rapidly as possible due to ischemic changes and associated testicular damage.

## Physics

30. **A modified Edinburgh Pipe Phantom to quantify the effect of slice thickness on the imaging performance of curvilinear probes**, Carmel Moran, Centre for Cardiovascular Science, University of Edinburgh

### Background

We have previously demonstrated the usefulness of the Edinburgh Pipe Phantom (EPP) to measure the imaging performance of over 350 clinical and preclinical ultrasound transducers over a frequency range from 2.5-55MHz using the concept of the resolution integral (R). Recently, we have demonstrated the impact of slice thickness on the imaging performance of linear and matrix arrays and shown that R increased by a factor greater than 2.5 when slice thickness effects were removed. This study describes the manufacture and testing of a modified EPP to quantify the effect of slice thickness on R for curvilinear probes.

### Methods

A phantom was constructed of two identical wedges of tissue-mimicking material (TMM) of height 250mm and width 100mm. The incline of the face of each of the wedges was at 40 degrees. The wedges were placed in a plastic box of degassed water and separated from each other using strips of polypropylene at distances between 0.42mm and 2.5mm creating water-filled slots of these dimensions (insert Fig1). Since the width of the wedges (100mm) was greater than the probe slice thickness the ability to image the slots was dependent primarily on the probe’s axial and lateral resolution. For each probe, the measurement of R obtained from the wedge phantom was compared to that obtained from the EPP. Two curvilinear probes were tested: Siemens Acuson S2000 6C1 HD (1-6MHz) and 4C1(1-4MHz).

### Results/Discussion

R increased by a factor of 3.3(6C1) and 3.5(4C1) when measured using the wedge phantom compared to the EPP. This increase illustrates the impact of slice thickness on the imaging performance of curvilinear ultrasound transducers and highlights the need for elevational focusing of transducers to improve imaging performance.

## Point of Care Ultrasound

### 31. **How to use ultrasound for vascular access**, Richard Beese, Queen Elizabeth Hospital

NICE guidelines state that wherever possible ultrasound should be used to guide vascular access when there is no visible vein for access. We present how to use ultrasound to guide vascular access.

Special reference is made to the needle, probe, and image orientation.

A reference to homemade phantoms and models for practice will be made.

### 32. **Point of care Echo**, Divya Priya<sup>1</sup>, Richard Beese<sup>2</sup>, <sup>1</sup>York Hospital, London, <sup>2</sup>Queen Elizabeth Hospital

Ultrasound is excellent at examining the heart. We present how to use ultrasound in an acute setting such as ITU and resus A&E.

Point of care ultrasound echo can quickly and accurately determine left ventricular function, right heart dilatation for pulmonary emboli and the presence of a pericardial effusion. In an acute setting this information adds to the clinical picture and is of great benefit to the doctor and patient.

### 33. **Ultrasound in A/E resuscitation**, Richard Beese, Queen Elizabeth Hospital

We present the use of ultrasound in the resuscitation room, we have found ultrasound useful to examine acute medical patients. Imaging the heart for left ventricular function, right heart dilatation and pericardial effusion, imaging the abdominal aorta and imaging the chest in the relevant patients.

#### **We present case examples**

Also, at our hospital we have taught A/E doctors to use ultrasound having regular teaching sessions and mentoring. We have found ultrasound useful to give important information and improve patient care in the acute setting.

## Professional Issues

### 34. **Acoustic Times or “scan you believe it!” A quality publication ultrasound governance and communicating standards during a pandemic**, Helen Brown, Shrewsbury and Telford Hospitals NHS Trust

#### **Objective**

Introducing new governance processes into a multi-site ultrasound department during a pandemic led to the re-thinking of the models of communication used to share governance objectives.

The introduction of peer review audit can be challenging for staff. Clear communication is vital to ensure staff are not threatened by the process and are able to use it as a learning opportunity to shape their practice and development, thereby improving patient safety.

#### **Method**

A monthly newsletter “Acoustic Times” was introduced to explain the processes and changes giving the opportunity to provide the evidence base and links to national guidance. Peer review audit and learning meetings were introduced and held virtually across sites to identify and share any individual or group learning points.

Processes and documents were either re-designed or introduced, with supporting rationale and evidence provided through the newsletter including; evidence based protocols, standard setting, peer review audit including supporting learning outcomes and CPD; actionable reporting; preceptorship; service user feedback and equipment QA. Further supported learning was provided on critical reflection, specific focus on technical aspects of clinical examinations, sharing of external learning events, CPD and in-house ultrasound training.

### Results

Benefits of the newsletter include more focus on improving consistency of practice and setting standards; faster reporting of audit findings and reaudits; and improved engagement with consultant colleagues. It also provides an accessible record of the development of governance processes which has been shared with sonographers in other organisations.

### Conclusion

Setting and communicating clearly defined quality standards and protocols is key to the design of safe working practices and patient safety in healthcare environments.<sup>1</sup> Open and honest governance processes with clear, accessible and useable documentation are key in staff engagement and ownership of quality improvement.

### References

1. Royal College of Radiologists. Standards for the Provision of an Ultrasound Service. 2017 Available from: [https://www.rcr.ac.uk/system/files/publication/field\\_publication\\_files/BFCR%2814%2917\\_Standards\\_ultrasound.pdf](https://www.rcr.ac.uk/system/files/publication/field_publication_files/BFCR%2814%2917_Standards_ultrasound.pdf) [Accessed 29/07/2022]

## 35. **The role of ultrasound simulation in increasing clinical placement capacity for BSc Radiography students. – How did the students feel?**, Donna Holdcroft, University of Liverpool

### Introduction

A radical reform of diagnostic services has been recognised in both the NHS Long Term Plan (2019) and the Richards report (2020). Subsequently, a recommendation was made to train an additional 4,000 radiographers above those training posts already facilitated.

Radiography training requires minimum clinical placement hours (1300) to meet the criteria for Health and Care Professions Council registration to facilitate employment in the NHS.

With a limited number of clinical placements available and demand for radiographers increasing, educational establishments need innovative practical training to meet these requirements. Simulation can assist with this challenge. The advent of reasonably priced handheld transducers makes ultrasound a suitable area for simulation, freeing up placement time in the hospital environment and potentially increasing student capacity. This study examines student perceptions of ultrasound simulation.

### Methods

This was a quantitative and qualitative study using Likert scales and open-ended questions to demonstrate the impressions of second and third year radiography students at Keele University, examining the role of ultrasound simulation to complement or potentially replace ultrasound training in the hospital environment.

### Results

Following simulation training, 100% of students considered simulation training met expectations, increased knowledge and would recommend to their peers. 80% of students responded with training complementing placements with 50% of students considering university ultrasound training could replace this provision in hospital environments.

### Conclusion

Ultrasound simulation training within the university has the potential to partially replace current clinical training in the hospital environment. With increased demand for clinical placements, this could be an option to increase capacity.

## 36. **Integrating flipped/blended learning into the ultrasound clinical governance session**, Farrah Elsaghir, AECC University College

### Background

Education and training is one of the pillars of clinical governance that helps to maintain and improve the quality of patient care within the NHS. The impact of COVID-19 has disrupted the delivery of governance sessions, original large departmental face-to-face sessions have changed because of social distancing, staff sickness or staff having to isolate. Furthermore, part-time staff often miss clinical governance sessions and do not have the opportunity to maintain training compared to full time staff. The need to deliver education and training is still crucial for staff development and optimising patient care and safety. This poster explores how

flipped learning combined with blended learning that is used within academic institutions can also be used to deliver clinical governance within the ultrasound department.

### Case report

Considering the IMPALA framework and its components, the following format is an alternative provision that could be used to deliver governance:

- Online presentation including a video/audio clip
- Self-directed study/activity
- Face to face or online session

The format would ideally suit new guidelines being introduced into a department, for example the applying O-RADS to images. Similarly, the format would suit education and training in case studies, protocols and even departmental quizzes or discussion forums. Including video/audio allows staff to feel in touch and be included with their peers despite circumstances potentially not allowing all to be present.

### Discussion

Pillars of governance are crucial to deliver optimal patient care. The education component is also very important to ultrasound practitioners. CPD is continuous and staff should be provided with equal opportunities despite working patterns or absence. Alternative methods to deliver governance sessions should be used as well as the traditional departmental/face to face session. The given format allows the ultrasound department to give education and training to all staff maintaining staff CPD and optimal patient care.

## 37. **Everybody hurts - What can physical health professionals learn about how mental health professionals support their own emotional resilience and mental health?**, Melanie Burton<sup>1</sup>, Benjamin Stenberg<sup>2</sup>, <sup>1</sup>Avon and Wiltshire Mental Health Partnership NHS Trust, <sup>2</sup>The Newcastle upon Tyne Hospitals Foundation NHS Trust

The physical aspects of ultrasonography, difficult posture with prolonged pressure exertion, have been extensively researched and addressed with advances in machine ergonomics, operator awareness of posture and positioning and workplace tools to identify musculoskeletal problems. The mental stresses are less well recognized and have only recently started getting investigated.

Ultrasonography is a mentally challenging activity requiring long periods of intense concentration, empathy and communication of complex and often difficult information to patients and clinicians, all of which carries an emotional toll. Practitioners are also under increasing time and caseload pressures exacerbated by COVID recovery and chronic fatigue from two years of pandemic. A survey of UK obstetric sonographers showed 92.1% and 91.0% met the burnout thresholds for exhaustion and disengagement, respectively (Skelton et al, 2022).

While many Trusts provide training to support physical health, few radiology departments educate their staff on emotional resilience or offer regular support to either promote or maintain mental wellbeing. Training, when available, is often focused on the receiver and not on the impact of vicarious traumas experienced as a result of repeatedly discovering/delivering difficult outcomes to patients on a regular and prolonged basis. Few health professionals are face-to-face with their patient at point of significant discovery whether that information is imparted to the patient or not.

Mental health professionals have adopted a trauma-informed stance into their working practices. This has not only informed the direct clinical work with patients but is also evident in the way the workforce is supported by the trust. Regular supervision, reflective practice and debriefs are required and monitored by the trust, based on research in Clinical Psychology to inform best practice. Some of these practices could be applied to physical health professionals to address some of the emotional burdens experienced as part of day-to-day delivery of care.



- 38. The impact of the COVID-19 pandemic on clinical guidance, risk assessment and support for UK obstetric sonographers**, Emily Skelton<sup>1</sup>, Christina Malamateniou<sup>1</sup>, Gill Harrison<sup>2</sup>, <sup>1</sup>University of London, <sup>2</sup>Society of Radiographers

#### Aim

UK obstetric sonographers adapted their working practices during the COVID-19 pandemic in response to new guidance issued by professional organisations, and requirements for on-going departmental risk assessments. This study aimed to provide an insight into to the implementation of this guidance, completion of risk assessments and perception of support within UK obstetric ultrasound departments during the pandemic period.

#### Methods

Obstetric sonographers working in the UK (n=138) used the Qualtrics XMTM platform to complete an anonymous, online, cross-sectional survey about their working experiences during the pandemic. Participants responded to closed questions about national guidance, risk assessments and their perception of support whilst providing fetal ultrasound screening services. Respondents provided additional detail about their experiences in these areas via free-text boxes.

#### Results

Over 90% of respondents were aware of, or had read guidance issued by professional organisations, although sonographers rated the overall usefulness of new guidelines at an average of 5.2/10 (where 0 = not useful at all, and 10 = extremely useful). Challenges for the implementation of guidance in departments were also identified, mostly related to the clinical working environment, including limitations of physical space (76.3%), time constraints (67.5%) and ventilation (61.3%). Most sonographers (77.2%) were aware that a departmental risk assessment had been undertaken, with waiting areas, scan rooms and clinically vulnerable staff highlighted as the most concerning factors. Sonographers felt most supported by their ultrasound colleagues (83.5%) and line managers (41.2%). They felt least supported by senior management and leadership personnel (60.8%), other antenatal colleagues (51.5%) and professional organisations (41.2%).

#### Conclusion

Whilst most sonographers were aware of published COVID-19 guidance, challenges for its implementation in clinical departments were identified. Local risk mitigation strategies often did not prioritise the scan room environment, despite it being highlighted as a concern. Support from the wider, senior service team and professional organisations will be essential to facilitate post-pandemic recovery of the workforce.

- 39. Our Journey from the Peripatetic Ultrasound Trainers to the Ultrasound Training Academy – HEE (South East)**, Famida Sadak, Ultrasound Training Academy, HEE (South East) University Hospital Southampton NHS Foundation Trust

In 2016, an innovative project of three ultrasound trainers evolved to support multi-professional trainees in Obstetric and Gynaecology ultrasound across the Wessex region. The aim of the project was to deliver a high-quality ultrasound training programme. One of the project's successes resulted in establishing the Sonographer Training Network Forum which allowed ultrasound leads from seven Trusts to meet and share ideas, which ultimately led to the development of regional ultrasound guidelines. From 2016 to early 2020, we have supported 75 trainees in O&G ultrasound.

The vision was to create a dedicated ultrasound training centre to support trainees in a safe environment. Late 2019, with the support and funding from Health Education England South-East, the plans were set in motion to create the first Ultrasound Training Academy in the South-East Region.

A briefing paper was submitted to the Trust Investment Group for approval. Approval from TIG acknowledged the Trust's support in the project as well as supporting the sonography workforce. This began the search for space that would accommodate the academy.

Frustratingly, COVID stopped all activities, however, with reflection, COVID gave us the time to plan accordingly for the Ultrasound Training Academy. Without the normal pressure of a time frame, it was an opportunity to find an ideal location as well as purchasing the required equipment befitting the academy.

The Ultrasound Training Academy – HEE (South-East) is based in the Princess Anne Hospital (University Hospital Southampton NHS FT). The advantages based within a hospital setting allowed the academy to follow the Trust's governance as well as absorbing some of the capacity from the ultrasound department.

We have two ultrasound rooms and a dedicated space for simulation training. We have plans to create a third ultrasound room.

### Conclusion

We have supported 24 trainees since opening in April 2021.

- 40. Education and mentoring - Increasing and improving student throughput**, Shaunna Smith, Hull University Teaching Hospitals NHS Trust

Tips to maximize student training capacity. Tips to aid student training outside of having a hand on a probe. Training Hubs - facilities and benefits

- 41. The value of participatory ergonomics in reducing work related pain in sonographers**, Kristie Sweeney<sup>1</sup>, Karen Ginn<sup>2</sup>, Jacqueline Spurway<sup>3</sup>, Jillian Clarke<sup>2</sup>, Martin Mackey<sup>2</sup>, <sup>1</sup>Bathurst Health Service Medical Imaging NSW Health, <sup>2</sup>Faculty of Medicine and Health, The University of Sydney, <sup>3</sup>Orange Health Service Medical Imaging NSW Health, Australia

### Background

Work related musculoskeletal disease (WMSD) has a high prevalence in sonographers globally. In the Western New South Wales Local Health District, Australia (WNSWLHD), which has a geographical area of 246,676 square kilometres, similar to the size of Britain, sonographers reported a musculoskeletal pain prevalence of 95%. Sonographers in five departments across the district collaborated to identify high risk practices in the workplace and implement potential solutions.

### Objectives

The aim of this study was to compare the prevalence of WMSD in a cohort of sonographers before and after implementation of ergonomic changes that were driven by recommendations from the sonographers themselves, using a participatory ergonomics approach.

### Methods

This observational mixed methods study analysed the impact of ergonomic changes on musculoskeletal pain in a small cohort of sonographers employed within the WNSWLHD. Ergonomic changes were made in five workplaces based on identified risks. Pre- and post-intervention musculoskeletal pain surveys were completed by ten sonographers over a period of 18 months and short interviews were conducted to ascertain their perception of the changes in their musculoskeletal pain.

### Results

Several interventions including job rotation, installation of patient monitors and use of ergonomic scanning techniques were perceived responsible for reported decreases in musculoskeletal pain in the right shoulder and the neck. No interventions were believed responsible for reported increases in pain in the wrists. This was attributed to several work practices including increasing workload and scanning immobile and obese patients.

### Conclusion

The use of participatory ergonomics was a valuable process to identify high risk work practices and possible solutions. Use of ergonomic scanning techniques is a change which sonographers can implement individually, whereas job rotation and installation of patient monitors would require management support. Participatory ergonomics should be utilised to create a safer work environment for sonographers.

- 42. Optimisation of ultrasound equipment using a phantom as part of the Annual Quality Assurance Program (QA)**, Justyna Janus, Joanne Walker, University Hospitals of Leicester NHS Trust

### Introduction:

The UHL Ultrasound Physics Quality Assurance (QA) Annual Program performs a complete set of tests using a test phantom to check for deterioration of equipment performance. However, this testing does not optimise the probes pre-set for its clinical applications. Here, we present a different QA approach where an ultrasound phantom was used to optimise and measure the performance of ultrasound probes used for vascular applications, enabling the best resolution required for its clinical use and providing measurements to inform uncertainty of measurement parameters.

## Materials and Methods

Several probes and machines were tested individually. Settings including pre-set application, gain, focus, TGC and probe working frequency were optimised to achieve the best quality image. The resolution testing was undertaken by the UHL Medical Physics staff for ultrasound QA, with pre-set optimisation and consensus from three AVS clinical vascular scientists using a tissue-mimicking ultrasound phantom (CIRS Multi-Purpose Multi-Tissue Ultrasound Phantom Model 040GSE). The testing was performed under normal ultrasound room conditions with dimmed lighting and reference images saved to PACS. The caliper accuracy routinely checked at annual QA was determined with specific attention to the most detailed measurements performed clinically for temporal artery imaging using the L8-18 hockey-stick probe.

## Result

Optimised settings for each ultrasound machine and probe were recorded and saved for routine clinical use. Recording the specific axial and lateral resolutions enabled the definition of the smallest structures that can be visualised as a separate individual structure and therefore measurable. This assures that clinically significant small measurements fall within an achievable resolution range.

## Conclusion

An ultrasound phantom can be a useful tool helping to achieve the best performance of the ultrasound system and ensure that units in clinical measurements are achievable, with a known value for the uncertainty of measurement, therefore improving the quality of the diagnostic service provided to patients.

43. **Pitfall in ultrasound scanning of the abdominal aorta**, Jonathan Dube<sup>1,2</sup>, Catherine Tierney<sup>2</sup>, Mary Moran<sup>1</sup>, Kevin Cronin<sup>1</sup>, Therese Herlihy<sup>1</sup>, <sup>1</sup>University College Dublin, <sup>2</sup>University Hospital Kerry,

## Introduction

Atherosclerosis is a potential cause of abdominal aortic stenosis, which is typically linked to hypertension. The abdominal aortic atheroma, which is frequently calcified, appears echogenic with posterior acoustic shadowing. Some studies have identified that a significant portion of the abdominal aorta is inadequately visualized during the ultrasound scan due to elevated BMI or bowel gas.

## Patient background

A 49-year-old female presented with left iliac fossa pain radiating to the flanks. The patient was a smoker. The patient had a raised white blood cell count of 13.7 and was hypertensive. In the previous ultrasound examination, it was concluded that the aorta was obscured by bowel gas. However, a subsequent Computed Tomography scan showed atherosclerosis with calcified plaques and stenosis of the infrarenal aorta. An ultrasound examination was ordered for further evaluation of the abdominal aorta.

## Ultrasound findings

Atheroma and calcification were noted from the origin of the superior mesenteric artery down to the distal abdominal aorta. High-grade stenosis greater than 90% with increased peak systolic velocity of 258 cm/s and 305 cm/s were observed in the mid-abdominal aorta and superior mesenteric junction respectively. Both common iliac arteries appeared atheromatous with increased peak systolic velocities of 157 and 140 cm/s respectively. Referral to the vascular surgeon was organized.

## Discussion

The calcified aortic atheroma has a strong echogenic appearance with posterior acoustic shadowing, simulating the presence of bowel gas. Furthermore, Doppler ultrasound may assist to assess the vascular lumen and the presence of atherosclerotic plaques which may result in abdominal aortic stenosis, hence evaluating the haemodynamic parameters. With the advancements in contrast-enhanced sonography techniques, microbubbles can now clearly display the adventitia that feeds atherosclerotic arteries and intraplaque neovascularization.

## Conclusion

Before concluding that the aorta cannot be demonstrated, it is crucial to distinguish between posterior acoustic shadowing and bowel gas.

## Vascular

- 44. A service evaluation to assess whether referrals into the community deep vein thrombosis ultrasound service meet the agreed criteria and local guidelines,** Emma Mitchell, Hull University Teaching Trust Hospitals

### Background

The purpose of this service evaluation was to gain a greater understanding of the community deep vein thrombosis pathway. The three aims were to evaluate whether incoming referrals met the agreed criteria in the local pathway, to determine the positive detection rate of deep vein thrombosis in referrals that did and did not meet the agreed referral criteria and to determine the positive pick-up rate of causative pathology in cases of unprovoked deep vein thrombosis. The referrals were compared against the local agreed criteria which are derived from National Institute for Health and Care Excellence guidelines.

### Methods

Retrospective data were collected from a radiology database of lower limb venous ultrasound examinations performed in the community setting from March 2019 to March 2020. A sample size of 500 was collected from a database of 1800 examinations. Data analysis was performed to calculate difference in percentages, 95% confidence intervals and significance level.

### Results

76.2% of referrals met the agreed criteria and 23.8% did not. In 28.5% of cases, rescans were performed. Positive detection rate of deep vein thrombosis was 9.9% in the referrals that met the criteria and 5.0% in referrals that did not. There was found to be no significant difference between the referrals that did and did not meet the agreed criteria in terms of positive detection rate of deep vein thrombosis. In cases of unprovoked deep vein thrombosis, all patients received an abdominal and pelvis ultrasound however no causative pathology was found.

### Conclusion

This service evaluation found almost a quarter of incoming referrals did not meet the agreed criteria therefore sonographers involved in the vetting process require training to reduce poor quality referrals. No causative pathology was identified by performing an abdominal and pelvis ultrasound in cases of unprovoked deep vein thrombosis and this guideline may need review.

- 45. Validation of a standardised duplex ultrasound classification system for the reporting and grading of peripheral arterial disease,** Samuel Huthart, Leeds Teaching Hospitals Trust

### Introduction

Duplex ultrasound (DUS), a non-invasive means of arterial mapping, allows for reliable diagnosis of peripheral arterial disease (PAD). One of our authors (CPO), developed a standardised DUS-based scoring system, devised for rapid detection and reporting of PAD. The purpose of this study is to validate this system, determining diagnostic performance both overall, and per disease severity.

### Methods

250 participants were recruited, based on diagnosis (N = 125), or absence of PAD (N = 125) from GP registers. Right and left legs per subject were handled as independent readings, determining actual PAD status via ABPI <0.9, and then further grading disease severity using suggested ABPI ranges. Data were excluded if no corresponding ABPI value was obtained per DUS-determination, or if the ABPI reading was >1.4, owing to risk of false negatives due to incompressible vessels. Diagnostic sensitivity and specificity were obtained overall, and per severity classification. Furthermore, interrater agreement between ABPI- and DUS-determined PAD severity was determined by linear weighted Cohen's Kappa.

### Results

The sensitivity and specificity in the detection of disease overall was 81.0% (95% CI 73.4 - 87.2%) and 86.3% (95% CI 82.3 - 89.8%), respectively. From mild to severe PAD, sensitivity increased from 71.1% (95% CI 55.7 - 83.6%) to 89.3% (95% CI 71.8 - 97.7%). Furthermore, a Cohen's Kappa value of 0.63 (95% CI 0.57 - 0.69) was obtained, indicating moderate agreement between the two diagnostic methods.



### Conclusions

Findings in this study validate the diagnostic performance of the standardised DUS scoring system, as well as its capacity to grade severity of disease, offering a potential tool for the identification of PAD in the community / research settings following initial screening methods. Confirmatory work could include a comparison of DUS-determined disease with gold-standard methods of non-invasive angiography, and novel tools such as toe-flex NIRS and multi-site photoplethysmography.

## Veterinary

### 46. **A case of canine large cell alimentary lymphoma; ultrasound appearances,** Aimee Bebbington, Imaging North West Veterinary Specialists and Wirral University Teaching Hospital

Canine lymphoma is the malignant transformation of the lymphocyte population and is the most common malignancy observed in dogs. Lymphoma is classified into anatomic forms including multicentric, alimentary, mediastinal, and cutaneous forms. Lymphoma is a systemic disease and therefore chemotherapy is the most appropriate modality for its treatment. Lymphoma cells are sensitive to chemotherapy and complete remission rates are high when patients are administered conventional chemotherapy. Dogs that are treated and achieve full remission can go on to maintain a good quality of life, long term.

This case study looks at a 3-year-old neutered male, dachshund who presented at his GP surgery with a history of diarrhoea for a couple of weeks with some occasional mucous and fresh blood noted. Demeanor was normal and he was bright, with no reported vomiting, coughing or any weight loss demonstrated. Upon abdominal palpation, a caudal abdominal mass was identified, and radiographs and a full abdominal ultrasound were undertaken.

Ultrasound examination revealed a mass in the ileum measuring 35 x 31mm in overall diameter with loss of normal wall layering, and a very narrow intestinal lumen was demonstrated through the mass. The mass was predominantly hypoechoic and mildly heterogenous in echotexture. Chemotherapy was started and full remission was achieved after receiving a combination of cyclophosphamide, doxorubicin, vincristine and prednisone (CHOP-25 protocol). He has now been in remission for over a year. He still receives regular focal ultrasound scans of the gastrointestinal tract to ensure there is no ultrasonic evidence of relapse.





## Student Stream

### 47. **The impact of occupational stress and burnout on retention of sonographers – a scoping review**, Hannah Bishop, King's College London University

#### Introduction

Within the National Health Service (NHS), sonography is associated with staff shortages, which appear to have worsened since 2013. There is substantial literature assessing the impact occupational stress/burnout has on professions such as nursing, however, literature investigating ultrasound is limited. With vacant ultrasound posts estimated to be as high as 25% in England, sonographers are facing increasing pressure to cover shifts to cope with staff sickness, contributing to exhaustion.

#### Objectives

This scoping review aims to explore whether occupational stress/burnout contributes to poor sonographer retention. Establishing why staff retention is poor, may identify reoccurring themes to inform targeted improvement.

#### Methods

A systematic search was carried out using keywords and Boolean searches to identify relevant literature published between 2012 and 2021. Eligible papers discussed levels of occupational stress, burnout, and professional disengagement. Articles that could not be accessed through King's College London institutional credentials were excluded due to time restrictions.

#### Results

Twenty-three papers were retrieved. Five peer-reviewed articles met the eligibility criteria. The largest of these studies conducted an online survey with 121 participants in Australasia. The remaining four articles were of United Kingdom origin and smaller sample groups. Three key themes were apparent throughout these five papers: 1) professional exhaustion due to increasing demand on services, 2) Increasing work-related anxiety because of patient expectations and exposure to bad news in obstetrics, 3) Increase in professional burnout due to insufficient training and poor communication from management.

#### Discussion

Identifying key themes influencing poor retention may improve services and understand the effects occupational stress has on disengagement and job satisfaction. Current literature only considers smaller sample sizes and mostly obstetric sonographers. No study has assessed opinions across the entire profession; therefore, further primary research is required.

### 48. **Testicular torsion with secondary suture granuloma**, Maeve Forde, University College Dublin

Testicular torsion is a medical emergency caused by twisting of the testicle on its spermatic cord leading to a compromised vascular supply. If left untreated necrosis of testicular parenchyma will ensue. Failure to untwist the testis within six hours can result in loss of testicular viability, often leading to orchiectomy. Sonographic features of testicular torsion include increased testicular size and heterogeneous echotexture. Absence of intra-testicular flow may be a key sonographic feature to yield a diagnosis for testicular torsion. Suture granuloma is a rare benign complication of orchiectomy. On ultrasound, hyperechoic suture material is seen within a hypoechoic inflammatory capsule.

#### Background

A 26-year-old male presented to an emergency department with severe right scrotal swelling and raised C-reactive protein. He was treated with intravenous antibiotics for suspected epididymo-orchitis. One day later, as his inflammatory markers continued to rise, ultrasound of the testis was performed.

#### Ultrasound findings

The right testicle appeared enlarged with a heterogeneous echotexture throughout the testicular architecture. Intratesticular vascularity was absent on colour Doppler, which was suspicious for testicular torsion. The patient underwent a right orchiectomy.

At a follow-up appointment, a small lump at the surgical site was scanned using ultrasound. The lesion appeared hypoechoic with a hyperechoic capsule surrounding it. Echogenic material was visualised within the hypoechoic capsule, indicative of remnants of suture material from surgery. The lesion later increased in size causing discomfort.

### Discussion

This case describes classical sonographic appearances of testicular torsion and subsequent suture granuloma secondary to orchiectomy, which was later confirmed using histology. Ultrasound diagnosis of suture granuloma can prevent unnecessary excision of benign lesions.

### Conclusion

Sonographer's knowledge of the sonographic features of both torsion and suture granulomas is significant for a prompt detection and an accurate diagnosis. Ultrasound is an integral diagnostic imaging tool in confirming suture granuloma preventing unnecessary surgical intervention.

## 49. **Paget-Schroetter syndrome in athletes,** Niamh O'Shea, University College Dublin

### Introduction

Paget-Schroetter syndrome (PSS) is a self-induced deep-vein thrombosis (DVT) of the subclavian and axillary veins. The subclavian vein passes through a narrow space between the clavicle and the first rib. Repetitive over-the-head exercise compresses the vein and causes microtrauma to the endothelial layer of the vessel. This can result in thrombus formation and it is commonly seen in athletes.

A 21-year-old male presented to the accident and emergency department with a two-week history of pain and swelling in his (dominant) right upper limb. The patient had a Wells score of 3 and his D-dimers were 1.28. This patient was an avid basketball player.

### Ultrasound findings

B-mode imaging revealed a small amount of mural thrombus within the brachiocephalic vein and an occlusive thrombus within the right subclavian and axillary vein. Both veins did not compress when pressure was applied confirming a thrombus was lodged within. Colour Doppler revealed no flow in the right subclavian and axillary vein despite a reduced PRF and increased colour gain. This confirmed that the thrombus was occlusive.

### Discussion

This patient was positive for a right DVT. The subsequent computed tomography examination revealed that the patient had no abnormal anatomy or a mass that was causing this DVT. Considering that this patient was an avid basketball player and the dominant arm was affected, PSS was diagnosed. Treatment varies depending on the presentation time of symptoms. This patient underwent heparinization as he presented two weeks after the first onset of symptoms. He was advised rib resection which he refused. The patient was put on anticoagulation for six months and was advised not to play basketball during this time.

### Conclusion

Paget-Schroetter syndrome is a rare venous condition. However, it has the potential for significant morbidity and can cause a potentially fatal complication. Timely, accurate clinical recognition of the sign is vital.

## 50. **Musculoskeletal trouble: A rare case of quadriceps tendon rupture,** Aoibheann McConville, University College Dublin, Ireland

### Introduction

The quadriceps tendon (QT) is a large composite tendon of the quadriceps muscles (vastus medialis, vastus intermedius, rectus femoris and vastus lateralis) that attaches to the patella. Quadriceps tendon rupture is an uncommon acute injury, accounting for approximately 1.3% of all musculoskeletal injuries. If not diagnosed promptly, changes to the tendon can manifest as irreversible and have serious consequences on normal locomotion. Ultrasound is an efficient imaging modality to detect and diagnose quadriceps tendon rupture.

### Patient background

A 54-year-old male presented to the emergency department with a history of a fall on a flexed knee. The patient had an elevated body mass index and a history of type II diabetes. Ultrasound was the radiological modality of choice to evaluate the injury.

### Ultrasound findings

The ultrasound examination revealed a transverse hypoechoic intratendinous defect to the quadriceps tendon. This hypoechoic defect was located at the quadriceps tendon's insertion point at the patella. On dynamic scanning the entire quadriceps tendon's architecture was not fully disturbed, sonographically confirming a partial thickness tear. The associated myotendinous junction and muscle architecture of the quadriceps muscle complex group were unremarkable.

### Discussion

Quadriceps tendon rupture can often be a clinical diagnosis in the emergency department, however ultrasound is an effective tool to determine partial tears from full thickness tears. Dynamic sonographic evaluation of the quadriceps tendon is paramount to permit prompt and accurate diagnosis.

### Conclusion

Ultrasound is an accurate imaging modality to diagnose quadriceps tendon tears that contributes to the pathway for a return to normal locomotion.

## 51. **Ultrasound appearance of a retroperitoneal endometrioma complicated by haemorrhage**, Alexander Ford, Faculty of Life Sciences and Medicine, King's College London

### Introduction

Endometriosis is an inflammatory gynaecological disorder where functional endometrial tissue is deposited outside of the uterus, producing adhesions and fibrotic scarring. Ultrasound is the first-line imaging modality for investigating endometriosis, due to its cost-effectiveness, accessibility and non-invasiveness. When presenting with certain "classical" features – a well-defined cystic structure with low-level homogenous echogenic contents, often deposited on an ovary – endometriosis is diagnosable on ultrasound. However, a spectrum of alternative appearances can confound diagnosis. In the case presented below, the appearances were uncharacteristic, preventing a diagnosis by means of ultrasound alone.

### Case Report

An 18-year-old female presented to the emergency department with acute abdominal pain and vomiting post-pareunia. Initial ultrasound identified free fluid in the pelvis; a CT scan revealed a large pelvic mass, suspected to be a torsed ovary. Laparoscopy identified what was believed to be a large, ruptured haematoma.

Further ultrasound scans also identified what appeared to be a haematoma, which did not reduce in size over time, which was noted to be unusual. Histology of samples removed during initial laparoscopy later revealed endometrial tissue. The patient has been referred to the endometriosis MDT for evaluation.

### Discussion

Endometriosis may present with a variety of non-specific clinical symptoms, significantly delaying diagnosis. Laparoscopy combined with histology remains the gold standard for diagnosis, but the spectrum of non-specific presentations also means a lot of women are subjected to this invasive surgical procedure unnecessarily. Ultrasound provides a non-invasive alternative preliminary investigation, as endometriosis can have a characteristic, readily-distinguishable appearance. However, some presentations can be diagnostically confounding. For example, in cases of substantial internal haemorrhage (as in this case), retroperitoneal endometriomas can present as a large haematoma.

It is hoped that an awareness of the spectrum of possible presentations of endometriosis on ultrasound may assist in future identification of the disease and hasten correct diagnosis.

# Education Programme 2023

**24th February 2023**

Liver Ultrasound Study Day

---

**17th March 2023**

General Medical Study Day

---

**21st April 2023**

Gynaecology Study Day

---

**13th-14th May 2023**

MSK Study Weekend

**5th July 2023**

Uterine Doppler Study Day

---

**29th September 2023**

Paediatric Study Day

---

**21st October 2023**

BMUS and UCD Study Day

---

Additionally we will have digital content such as Ask the Expert, new webinars and Journal Club returning in 2023, which will be free to watch for members

If you have missed any webinar lectures throughout the year, these are available in our 'Webinar Library' under CPD Resources.

Remember to check the BMUS website or the BMUS weekly e-newsletter, Ultrapost, regularly to see what is coming up!

Scan the QR code to check out all of our study days and events.






ACUSON Family

# Expanding the vision of ultrasound

Visit stand 37 to find out more.

[siemens-healthineers.co.uk/ultrasound](http://siemens-healthineers.co.uk/ultrasound)



**SIEMENS**  
Healthineers

The clinical overlay is not that of the individual pictured. It was modified for better visualization.





# EXHIBITORPROFILE2022

---



# EXHIBITOR PROFILE

## Stand 1



### FUJIFILM – GOLD SPONSOR

Fujifilm UK Ltd is a leading provider of innovative medical imaging systems and healthcare solutions. Our portfolio covers digital x-ray, mammography, ultrasound, CT, MRI, enterprise imaging solutions (including PACS, VNA, Clinical Workflow Management and 3D surgical planning tools), AI, digital pathology and near patient IVD testing analysers for dry chemistry.

With a history of manufacturing x-ray film since the 1930s, for decades we have been using our heritage in photography and film to bring exciting new solutions to the healthcare market. By leveraging advanced technology from across a broad business, we have developed new ways of meeting the needs of modern healthcare by providing value through innovation.

Company Email Address: [medicalmarketing\\_uk@fujifilm.com](mailto:medicalmarketing_uk@fujifilm.com)

Company Web Address: [www.fujimed.co.uk](http://www.fujimed.co.uk)

## Stand 2



### MIS HEALTHCARE – GOLD SPONSOR

Delivering world-class medical imaging solutions, MIS Healthcare has built its reputation for excellence by providing high end imaging equipment, supplied by renowned manufacturers. Samsung's Ultrasound systems offer advanced intellectual technologies to help you confirm with confidence for challenging cases, while the easy-to-use system supports your effort involved in the routine scanning.

At MIS Healthcare we remain driven by our passion for providing high quality imaging solutions in the interest of accurate diagnosis.

Website: [www.mishealthcare.co.uk](http://www.mishealthcare.co.uk)

## Stand 3



### **CANON - GOLD SPONSOR**

---

Canon Medical Systems Corporation develops and manufactures diagnostic imaging systems including CT, MRI, Ultrasound, X-ray systems and clinical laboratory systems and provides them to around 140 countries and regions around the world, offering technology that provides faster diagnosis and early treatment.

Under the slogan "Made for Life" (Made for Partnerships, Made for Patients, Made for You.), Canon Medical Systems is making positive contributions toward hospital management, and provides a range of patient-friendly healthcare systems and services.

<https://uk.medical.canon>

## Stand 4



### **INTELLIGENT ULTRASOUND**

---

Intelligent Ultrasound is a leading 'classroom to clinic' ultrasound company, specialising in providing real-time, virtual reality simulation for the ultrasound training market ('classroom') and artificial intelligence-based clinical image analysis software tools for the diagnostic medical ultrasound market ('clinic').

**Ultrasound Simulation:** We deliver world-class, high-fidelity ultrasound simulation technologies (including ScanTrainer, BodyWorks and BabyWorks) to make ultrasound simpler to use, and easier to learn.

**Artificial Intelligence:** Our clinical-AI products harness the power of AI to improve the accuracy and standardisation of ultrasound procedures in clinical practice.

Today we support over 1,400 systems in more than 700 institutions worldwide.

[www.intelligentultrasound.com](http://www.intelligentultrasound.com)

## Stand 5



### PROBO MEDICAL

---

Probo Medical is a leading diagnostic imaging equipment product and service provider in Europe. We empower medical professionals to make smarter purchasing decisions without sacrificing patient care by offering new and fully refurbished quality diagnostic imaging products and services for top brands. From beginning to end, we offer the personal touch as your dedicated partner.

## Stand 6



### IMAGEXMEDICAL

---

ImageX Medical is an Ultrasound Service and Probe repair provider. Offering nationwide coverage and the only fully functional probe repair facility in the UK. We offer full machine maintenance contracts and also a free probe evaluation should your probe need repairing. We are also the UK distributor for the Clarius Hand Held Ultrasound Scanner, offering Affordable, Quick, HD images. This works with IOS or Android Devices. This will be showcasing at the conference.

Please come and see us at Stand 6 or contact us at [simon.rhodes@imagexmedical.com](mailto:simon.rhodes@imagexmedical.com)

## Stand 7



### DIAGNOSTIC HEALTHCARE

---

Diagnostic Healthcare was established in 2004 and is one of the UK's largest independent providers of imaging services to both NHS and private patients. We are a key partner to the NHS with substantial experience of working across both primary and secondary care sectors, supporting with imaging, reporting and staffing solutions.

We have established over 75 community clinics in the UK across more than 15 Integrated Care Boards (ICBs).

Provision of Ultrasound in the community and for Secondary Care is one of our largest services and we are actively recruiting additional, highly experienced Sonographers to both Senior Clinical and Leadership roles.

We are creating multiple new opportunities within the company, across the UK to join an outstanding team undertaking a wide range of examinations, engage with training and development and advancing into new and exciting territories.

With innovative service models and investment in the latest equipment we provide value for money services. An exceptional level of care, attention to detail and the very best patient experience is at the forefront of all our service provision. We deliver services with full IT integration to both NHS and private systems and our rigorous Clinical Governance processes, enabling the highest standards of quality and safety.

**Our Vision** - To deliver outstanding healthcare services as a technology focused leading provider

**Our Mission** - To provide first class patient care on every occasion with a world class workforce

## Stand 8



### NANOSONICS

---

trophon® is the safe, versatile, and simple way to high level disinfect your ultrasound probes and prevent patient cross contamination.

trophon® was invented and manufactured by Nanosonics, a leader in the development of innovative technology for infection control.

Nanosonics' mission is to improve the safety of patients, clinics, their staff, and the environment by transforming the way infection prevention practices are understood and conducted and introducing innovative technologies that deliver improved standards of care.

<https://www.nanosonics.co.uk>



## Stand 9



### ESAOTE - BRONZE SPONSOR

**Esaote:** Celebrating 40 years of experience & innovation as a world leading Italian based manufacturer of ultrasound and dedicated MRI.

Esaote's MyLab series of ultrasound systems offer integrated cutting-edge technologies, ergonomics and ease-of-use for improved patient outcomes.

With advanced tools for a complete assessment of liver disease, dedicated UroFusion for real-time prostate biopsy support and our unique A.I. assisted BreastNav™MRI for improved accuracy in the fusion of breast MRI with real-time ultrasound, Esaote offers the perfect solution for all needs in General Imaging and Woman's Health.

Visit stand 9 for our flagship MyLab™X9 & MyLab™X75. New for 2022, the MyLab™X1.

## Stand 10 and 11



### LABLOGIC

Knight Imaging is a supplier of ultrasound and medical couches, specialist patient chairs and X-ray imaging accessories.

From purpose-built products such as our Cardiff Chair - specially developed for breast imaging, biopsy, and stereotactic procedures – to bariatric, critical care chairs and diagnostic imaging tables, we pride ourselves on delivering quality products which will not only enhance your medical department, but also provide the comfort and security your patients expect.

<https://www.knightimaging.co.uk/>

## Stand 12



### TRISTEL

The Society and College of Radiographers is committed to developing and promoting the science and practice of all fUltrasound is changing. Is your decontamination process able to keep up?

With the rise in mobile ultrasound requirements, the ultrasound probe now travels to the patient whenever and wherever care is needed. Today, ultrasound can be delivered via an app and smart device technology: a mobile companion to the traditional console.

Tristel's decontamination systems enable you to keep up to date with innovation in ultrasound. Utilising proprietary ClO2 chemistry, Tristel products provide decontamination of entire ultrasound probes, no matter their size or shape. They are mobile, adaptable, validated and complete.

Visit the team on stand 12 to find out more.

## Stand 13



### GLOBE LOCUMS

Since our formation in 2011, Globe Locums has become one of the preeminent specialist Sonography recruitment firms in the UK. Our Global reach encompasses UK, Ireland, Australia, New Zealand & Asia Pacific, allowing Globe Locums to source both locum and permanent Sonographers of the highest calibre. Globe Locums is clinician owned and run allowing our ethical focus to grow with our company, making us unique in a very bust marketplace.

We are always available on [sono@globelocums.co.uk](mailto:sono@globelocums.co.uk) and 02072292620 for an informal chat.

## Stand 14



### MULTI-MEDIX

Over the years, our research into ultrasound performance has enabled Multi-Medix to become the leading independent provider of specialised ultrasound quality assurance (QA) services.

Multi-Medix empowers organisations to implement & perform robust ultrasound QA programmes. Thereby improving image quality, patient safety and meeting the ultrasound QA guidance from BMUS, IPEM and SCoR.

We are independent, with friendly staff that can provide you with ultrasound QA training and practical help, on or off-site.

For more information visit [www.multi-medix.com](http://www.multi-medix.com), where you will also find our free "Ultrasound QA Knowledge Portal". Launched in 2019, it provides access to the "Diagnostic Ultrasound QA Manual" and videos.

## Stand 15



### LUMICARE

Lumicare is on a mission to deliver High-Level Disinfection of ultrasound probes more effectively and safer than ever before. Cutting edge LED technology enables control of UVC dose, temperature, wavelength and distribution, achieving optimal germicidal efficacy that's better for clinicians and better for patients. The Lumicare ONE is an automated, low temperature, chemical-free high level disinfection system for ultrasound probes.

## Stand 16



### THE SOCIETY AND COLLEGE OF RADIOGRAPHERS

---

The Society of Radiographers is the trade union and professional body for those working in clinical imaging, ultrasound, nuclear medicine, radiotherapy and oncology in the UK. The College of Radiographers is a registered charity which promotes imaging and radiotherapy education and innovation.

Together, we are The Society and College of Radiographers.

As a professional body we set the standards for the profession. In the workplace, we ensure imaging professionals work in a safe and fair environment. As a charity, we ensure patients are at the heart of everything we do.

To learn more, please visit our stand.

## Stand 17



### PENINSULA MEDICAL

---

Based in Peninsula Medical School, Diagnostic Radiography at the University of Plymouth is a unique and exciting Programme encompassing both Diagnostic Radiography and Foundation Ultrasound Skills. To best fit student needs and the needs of tomorrows' workforce the programme has been developed with stakeholder engagement to recognise the increased demand for Diagnostic Medical Sonographers.

Combing both a theoretical and hands-on approach, students will attain the necessary skills to become an HCPC registered Diagnostic Radiographer but will also receive additional ultrasound training. Students that graduate from this programme will have experienced ultrasound simulation, placement, and modality specific academic learning. This unique skill set aims to fast track them into ultrasound training posts upon graduation.

## Stand 18



### BRACCO

Bracco UK Limited is the UK subsidiary of Bracco Imaging Spa, a multinational group active in the global healthcare sector with a specific focus on imaging agents including microbubbles for Contrast Enhanced Ultrasound. Bracco is committed to innovative specialised research in diagnostic imaging agents alongside the further development of advanced injection systems for radiology and cardiology.

For more information, please visit [www.bracco.com](http://www.bracco.com)

## Stand 19



### GERMITEC

Germitec is an award-winning manufacturer of Chemical-free and sustainable high-level disinfection systems for ultrasound probes. With an automated and traceable UVC disinfection cycle lasting only 90 seconds, the Germitec 'Chronos' is the perfect solution for any department looking to improve standards of patient care and prevent infection transmission during any ultrasound examinations. Our Chronos system requires no ongoing consumables and can help streamline disinfection workflow. Our patented UVC disinfection technology is independently proven to completely kill a full spectrum of micro-organisms, including VRE, HPV & spores!

Contact our team to book in a free-trial and learn further information. [www.Germitec.co.uk](http://www.Germitec.co.uk) Email: [Contact@Germitec.com](mailto:Contact@Germitec.com)



## Stand 20



### **SIEMENS HEALTHINEERS - BRONZE SPONSOR**

---

Siemens Healthineers pioneers breakthroughs in healthcare. For everyone. Everywhere.

As a leading medical technology company, Siemens Healthineers is continuously developing its product and service portfolio, with AI-supported applications and digital offerings that play an increasingly important role in the next generation of medical technology

## Stand 21



### **PHILIPS - SILVER SPONSOR**

---

At Philips, we look beyond technology to the experiences of consumers, patients, providers and caregivers across the health continuum – from healthy living and prevention to diagnosis, treatment and home care. We unlock insights leading to innovative solutions that address the Quadruple Aim: improved patient experience, better health outcomes, improved staff experience, and lower cost of care. With leading research, design and innovation capabilities, we partner with our customers to transform the delivery of healthcare.

## Stand 22



### PHYSIOLOGICAL MEASUREMENTS

PML are an award-winning, provider of non-invasive diagnostic services for NHS patients. We have numerous services nationwide delivered from our own diagnostic centre and GP practices.

We are always looking for qualified staff come and visit us on stand No 22 to discuss opportunities how we can work together.

[www.physiologicalmeasurements.com](http://www.physiologicalmeasurements.com)

## Stand 23-24



### GE HEALTHCARE - GOLD SPONSOR

GE Healthcare is a leading global medical technology and digital solutions innovator, GE Healthcare enables clinicians to make faster, more informed decisions through intelligent devices, data analytics, applications and services, supported by its Edison intelligence platform. With over 100 years of healthcare industry experience and around 50,000 employees globally, the company operates at the center of an ecosystem working toward precision health, digitizing healthcare, helping drive productivity and improve outcomes for patients, providers, health systems and researchers around the world.

Follow us on Facebook, LinkedIn, Twitter and Insights , or visit our website [www.gehealthcare.co.uk](http://www.gehealthcare.co.uk) for more information.

## Stand 25



### ADVANCED ULTRASOUND ELECTRONICS

For over 20 years, Advanced Ultrasound Electronics (AUE) has defined the standard in multi-brand ultrasound service and repair. AUE specialise in ultrasound. We have the UK's only advanced probe testing laboratory, which underpins our Quality Assurance offering. Quality is at the heart of what we do – whether we service your system onsite or offer a “Back to Base” system repair. Our unrivalled technical capability provides a seamless solution for all your ultrasound needs – whilst ensuring your scanning time is maximised and your costs are reduced. Pop to our stand (No. 25) to see our technical capability and our commitment to helping you meet your sustainability targets.

Contact us at [info@aueltd.co.uk](mailto:info@aueltd.co.uk) or visit [www.aueltd.co.uk](http://www.aueltd.co.uk)

## Stand 26



### EASYPAY NETWORK

EasyPay Network is the UK's leading touchscreen kiosk provider, delivering 24/7 payment solutions for maternity departments. Our self-service kiosks provide you with a secure means of collecting payments for ultrasound scans, prescriptions, and more. Our bespoke solutions are designed to help you cut costs, increase income, and improve efficiency.

<https://easypaynetwork.com>

## Stand 27



### UKAS

The United Kingdom Accreditation Service (UKAS) is the sole National Accreditation Body for the UK. Its role is to check that organisations providing conformity assessment services such as certification, testing, inspection and calibration services, are meeting a required standard of performance. The assessment criteria used by UKAS are internationally recognised as being the best indicators of accurate, impartial and consistent performance. UKAS accreditation demonstrates an organisation's competence, integrity and performance capability against internationally recognised standards.

For further information about UKAS accreditation please visit [www.ukas.com](http://www.ukas.com)

## Stand 28

### CELTIC SMR LTD

CelticSMR Ltd is a rapidly growing imaging company with 30 years of experience in the Veterinary and Healthcare markets; distributing leading Ultrasound X-ray and therapeutic laser equipment throughout the UK and Ireland. We pride ourselves on developing strong and long-lasting relationships with our customers and are committed to providing excellent customer service, training and support. With our small and friendly team of equipment specialists, engineers and account managers, we are able to offer a very personal service, empowering customers to maximise the use of their imaging equipment and provide the best possible care to their patients. Our equipment portfolio includes the latest technology from leading manufacturers:

**SonoScape portable and cart-based Ultrasound**

**Clarius handheld Ultrasound**

**OR Technology Digital X-ray**

**ASA Class 4 Therapeutic Laser**

Stand 29



**CASMED**

At Casmed International we stock a wide range of covers designed to fit all makes of ultrasound probes. These are manufactured to the highest quality and are fully compliant with strict European standards which allows traceability throughout the entire manufacturing process.

Come and see us on Stand No 29



**SONOGRAPHERS - Full Time & Part Time**

**Requirements:**

- Minimum 2 years experience
  - HCPC Registered
- 6 Olympic Gold Medals
  - Superpowers

... no, but seriously, we're hiring full & part time Sonographers, locations nation wide. (Olympic gold medals optional!)

**For more information**

**COME AND FIND US AT BMUS STAND 7**

or contact Isabella or Hannah on 0161 929 5679  
or email [careers@dhc.uk.com](mailto:careers@dhc.uk.com) for a confidential chat.









# PROCEEDINGS OF THE BRITISH MEDICAL ULTRASOUND SOCIETY 53RD ANNUAL SCIENTIFIC MEETING

---

6TH - 8TH DECEMBER 2022



# DAY ONE

Tuesday 6th December

## General Imaging and Paediatrics

**The first 5 targeted trans-perineal prostate biopsies diagnose the majority of PROMIS criteria cancer in patients with a Likert 4 or 5 score on mpMRI**, William Stevens, Ese Adiotomre, Oliver Hulson, Atif Khan, Roger Lapham, Philip Melling, Adam Morrell, Sacha Pierre, Jonathan Smith, Leeds Teaching Hospitals NHS Trust

### Purpose or learning objective

To see if the first five transperineal (TP) biopsies give a diagnosis of PROMIS criteria cancer in patients with a likely prostate cancer on mpMRI.

### Methods or background

NICE guidelines suggest multiple prostate biopsies for histological diagnosis of cancer in those patients with a Likert 4 or 5 score on their mpMRI scan. Depending on the treatment planned, some patients need systematic TP biopsy, but in frail patients, those with limited treatment options or extensive disease, a cancer diagnosis may be all that is required.

375 patients had mpMRI for suspected prostate cancer between January and June 2021 in a large volume quaternary centre. 367 were given a Likert score of which 108 were scored Likert 4 or 5. Of these, 94 patients were sent for biopsy. 70 of the biopsied patients were ultimately diagnosed with PROMIS criteria cancer. A separate pot was sent containing the first 2-5 targeted biopsies in 69 of the 70.

### Results or findings

The median number of biopsies in all patients sent for biopsy was 12 (range 3-19). The first 2-5 targeted biopsies showed PROMIS criteria cancer in 65 of the 69 (94.2%) Likert 4 and 5 patients diagnosed with cancer. 62/69 (89.9%) showed the maximum length or grade of cancer in the first 2-5 targeted biopsies. All 4 of the missed cancers were ISUP 2 or less and located in the apex of the gland.

### Conclusion

A cancer diagnosis is usually obtained in the first 2-5 targeted biopsies in patients with a Likert score of 4 or 5. Further biopsies may be required for treatment planning or for lesions in the apex of the gland where cancers can be missed.

**Rare Finding of Occlusive Thrombus of a Testicular Varicocele**, Amir Bennett, The Royal Free London NHS Foundation Trust and King's College London

### Background

Acute scrotal pain has a variety of possible causes. Among the most common causes include epididymo-orchitis and torsion. Thrombosis of a varicocele, however, is a very rare clinical finding and therefore not a common cause of acute scrotal pain.

### Case Presentation

A 57-year-old male inpatient presented to ultrasound department with new acute left scrotal pain following hospital admission for acute urinary retention due to enlarged prostate. Clinically, the left testicle was assumed undescended. In view to patient's pain, an ultrasound scan of the scrotum was requested to check for undescended left testis, exclude malignancy/confirm cause of pain.

The left testicle was located within the left scrotum but was avascular and atrophic measuring only 12 x 7 x 6 mm (volume 0.2 cc). Atrophy secondary to previous trauma.

The left epididymal head contains a 3.6 mm simple cyst. The left epididymis appears otherwise unremarkable.

A thrombosed varicocele was noted on the left which appeared to be abutting the midpole region of the left epididymis and extending into the left groin. No vascularity was evident on Doppler imaging, suggestive of occlusive thrombus. The thrombosed vessel measures at least 66 mm in length.

The right testis (volume of 11.3 cc) and epididymis were unremarkable.

### Conclusion

A thrombosed varicocele is a very rare cause of acute scrotal pain, and the condition is nearly impossible to diagnose clinically. Therefore, diagnostic imaging is necessary to ensure correct diagnosis. Ultrasound is the modality of choice for assessing the scrotum and Doppler ultrasound can be used to evaluate vascularity. Ultrasound imaging was vital in this case as not only confirm the atrophic left testicle to be correctly located, but ruled out malignancy and infection as the cause of patient's symptoms but also identified a thrombosed varicocele which is a very rare cause for acute scrotal pain.

### **Paediatric abdominal ultrasound appearances in acute hepatitis patients in a tertiary paediatric hospital**, Lorraine Walsh, Zishan Sheikh, Chayarani Kelgari, Birmingham Children's Hospital

#### Objectives

There has been an increase in reports of acute hepatitis of unknown cause in children. Abdominal ultrasound including Doppler assessment (UABDO) is the first line imaging modality for paediatric patients with acute liver pathology. We aim to present our UABDO findings in a series of children with hepatitis referred to a single paediatric liver-transplantation centre between January 1st and July 24th 2022.

#### Methods

A retrospective cohort of children (< 16 years old) with hepatitis meeting the UK Health Security Agency case definition for acute non-A-E hepatitis were identified from a local hepatology case list<sup>1</sup>. Further blood tests enabled differentiation of acute hepatitis (AH) from cases of acute on chronic hepatitis (ACH). The images and reports from admission US exams of each patient were reviewed by a consultant sonographer and radiologist.

#### Results

A total of 24 children were included, of which 17 had AH and 7 had ACH. The median age was 5 years and male to female ratio was 1:4. The most common findings seen were a heterogenous liver echotexture in 75% (82.3% AH v 57.1% ACH), gallbladder wall thickening in 54% (70.5% AH v 14.2% ACH), splenomegaly in 45.8% (29.4% AH v 85% ACH) and hepatomegaly in 41.6% (41.1% AH v 42.8% ACH).

#### Conclusion

US findings in cases of acute hepatitis are described to assist clinical teams assessing children with AH and ACH.

## Professional Issues

### **From concept to reality: BSc Medical Ultrasound Degree apprenticeships – a new route for sonographer education**, Catriona Hynes<sup>1</sup>, Trudy Sevens<sup>1</sup>, Michelle Hood<sup>2</sup>, Elizabeth Bullivant<sup>2</sup>, <sup>1</sup>NHS South Yorkshire Integrated Care Board, <sup>2</sup>Sheffield Hallam University

#### Background

Increasing demand for UK ultrasound services is currently reliant on an Agenda for Change band 7 and above workforce, with few sonographers employed at lower bands (Sevens&Reeves, 2018). Longstanding national workforce deficits (SCoR,2019; CFWI,2017) are further compounded by current postgraduate training unable to meet demand for sonographers and service delivery.

In order to meet the needs of patients and NHS services, recent work has proposed solutions to workforce shortages through new models of education and the introduction of an attractive and rewarding career path for Sonographer. This includes the development of a career framework, which incorporates graduate level qualifications for practitioner level skills in medical ultrasound (HEE,2019).



### Case report

Following extensive consultations by the Trailblazer group established in 2017, the Sonographer degree apprenticeship (integrated degree) was approved in August 2019. Sheffield Hallam University is among the first to offer this degree apprenticeship, supporting the implementation of this vision through the education of sonographer practitioners (career level 5) to work alongside the current workforce.

### Discussion

Chronic workforce deficits and increasing demand for imaging services are detrimental to NHS services and delivery of effective patient centred care. Future forecasting predicts further increases in demand (NHS,2019) requiring significant workforce growth. Degree Apprenticeships (DA) offer a new route in sonography education, widening participation and facilitating career progression for the whole workforce. The introduction of this new model, expands the existing portfolio of AHP degree apprenticeship routes at Sheffield Hallam University.

The BSc Medical Ultrasound Degree Apprenticeship programme provides an innovative and coordinated approach to learning. Extensive stakeholder consultation and collaboration has enabled the generation of ideas with a high degree of originality, improved knowledge of workplace requirements and future workforce transformation. The shared enthusiasm for innovation and change ensures we situate apprenticeships in the current context whilst anticipating future workforce needs.

## Physics

**Modelling of diaphragm motion using 4D ultrasound**, Katy Szczepura, Phil Tresadern, Niamh Gill, Adam Handley, Steve Preece, University of Salford

### Introduction

Recent work undertaken at the University of Salford has used 4D Ultrasound acquisition, with post-acquisition modelling in an attempt to provide a reproducible, accurate 4D model of diaphragm motion and excursion.

The ultrasound modelling will be combined with other external models, such as point cloud data with marker tracking (image 1). The combined data set will then be used to create a multimodal biofeedback system for people who suffer with dysfunctional breathing. The main aim is to deliver a real-time system to show underlying muscle function to patients integrated into new intervention tool.

### Method

Pilot data have been collected using a GE Voluson e10 using a RAB6-RS probe. The probe is positioned between the lower ribs and steered to ensure the diaphragm is within the field of view. Maximum depth is selected, with a 0.5mm slice thickness capturing the widest field of view as possible. This results in a frame rate of 2.6Hz. Images are acquired to capture 10 breath cycles. In-house analysis software has been developed using the .vol image sets, outputs are CVS datasets of surface plots of the diaphragm over time.

### Results

The work is still at pilot stage. Imaging protocols have been developed, and reproducibility data have been collected. 4D modelling is being developed, with initial findings looking positive (image 2). Current issues are due to noise within the image, and automatic detection of the diaphragm vs other structural objects within the field. Examples of current data outputs can be seen here: <https://youtu.be/ClxOTxxK4RE>

### Conclusion

Next steps are to further develop the post-acquisition modelling, acquire point cloud data sets and correlate findings to develop feedback mechanism.

The work presented here will be a proof-of-concept, with current status of the project and findings.



### **Ultrasound QA – The good, the bad and the ugly**, Daniel Wyatt, Multi-Medix

The requirement for quality assurance (QA) of ultrasound equipment in the UK has been brought to the foreground in recent years. Because of this, many ultrasound managers and lead sonographers have been implementing or updating their QA programmes. The aim of this study was to investigate which methods have been used to implement ultrasound quality assurance within the NHS. In the years 2021-2022, Multi-Medix (an ultrasound QA specialist) spoke to more than 20 NHS sonographers who have begun the process of implementing QA. The approaches taken by each of the relevant departments have been sorted into 6 generic categories which describe what QA is being performed, and which staff are undertaking it. The results shows that there is significant variability in how sonographers have attempted to implement their QA. But are all of these approaches efficient and do they ensure patient safety? The potential flaws in some of the methods include a single point of failure when one person performs all of the QA, lengthy procedures which take up valuable sonographer time or infrequent checks which fail to capture transducer faults in a timely manner. The conclusions of this study consider the options for successful QA implementation which minimises the time taken for sonographers to perform checks and maximises scanner availability.

### **Development of image analysis software to enable objectivity in ultrasound quality assurance**, Guy Brown, Royal Berkshire NHS Foundation Trust

Since the inception of medical ultrasound scanning, ultrasound image quality parameters have been difficult to measure accurately with the aim of extracting absolute quantitative information. Consequently, it is common for the results of ultrasound quality assurance tests to be assessed qualitatively, typically by visual assessment and expert opinion of the professional (observer) performing the test. This approach is problematic, as the assessment of qualitative performance is highly subjective. Consequently, the repeatability of ultrasound quality assurance is compromised.

Consistent assessment of performance on an annual basis is difficult since the observer is highly likely to change during the lifetime of an ultrasound system. Additionally, subjective assessments to are vulnerable intra-observer inconsistencies. Other factors such as ambient lighting in the room where the assessment is taking place further reduce the repeatability of qualitative assessments.

The aim of this project is to develop a software application that will enable the objective and repeatable assessment of image quality parameters used in a routine ultrasound quality assurance programme. The application will not be designed to measure the absolute values of performance parameters, but rather to provide a consistent assessment metric. Various image quality parameters will be monitored by the application, including but not limited to axial and lateral resolution, contrast, uniformity and penetration depth.

The application will ultimately be used to objectively advise whether ultrasound system performance has deteriorated. The project aim will be tested against the following hypothesis: Implementation of image analysis software significantly increases the repeatability of ultrasound image quality assessments; in comparison to qualitative and subjective methods. The following secondary hypothesis will also be tested: Objective assessments have the capacity to identify equipment faults at an earlier stage than subjective assessments.

## Student Stream

**Can we really detect vulnerable carotid atherosclerotic plaques by routine ultrasound?**, Rania Shahbaz<sup>1</sup>, Fabien Koskas<sup>1</sup>, Jean-Michele Davaine<sup>2</sup>, Etienne Charpentier<sup>2</sup>, <sup>1</sup>Sorbonne Université, Paris, France  
<sup>2</sup>CHU Pitié-Salpêtrière, Paris, France

Can we really detect vulnerable carotid atherosclerotic plaques from stable ones by routine ultrasound? Can the vascular surgeon trust those answers and operate on an asymptomatic patient with less than 70% stenosis? And why are the European guidelines not clear on the topic? In this study, we tried to find validated markers in vascular ultrasound that can be used in day-to-day exams to characterise carotid artery plaques. Thirty-four asymptomatic patients were scanned using ultrasound and CT before carotid endarterectomy, and their plaques were categorised using Gray-Weale classification and Hounsfield unit (HU), respectively. The plaques extracted were then analysed histopathologically and grouped accordingly.

Histology was considered the gold standard for identifying vulnerable plaques (VP). Quantitatively, these VP had a large content of lipidic-necrotic material (48%), a low amount of calcification (2%) and fibrosis (42%) as opposed to non-vulnerable plaques (NVP), which were less lipidic-necrotic (8%), more calcified (13%) and fibrotic (65%) ( $P < 0.05$ ). Doppler ultrasound analysis showed that VP was more frequently type 2/3 plaques (70.6%) as opposed to NVP that mainly were type 4/5 plaques (56%) ( $P < 0.001$ ). Ultrasound showed better correlation with histology than HU analysis in CT.

Ultrasound is a valuable tool that can almost acknowledge vulnerable plaques; however not sufficiently to be a decision-making marker. How to improve that?

**Do patients enrolled within the iliofemoral venous stent surveillance programme continue to report increased quality of life and venous symptom resolution?**, Alexander Pason, King's College London, Cambridge University Hospitals, Leicester University Hospitals

### Objective

Currently iliofemoral venous stent patients undergo regular ultrasound surveillance for the foreseeable future to help preserve stent patency. A service evaluation at Cambridge University Hospitals was conducted to see if stent patency is related to venous symptom resolution and quality of life.

### Methods

Questionnaires were sent to 49 eligible patients to measure residual venous symptoms (VEINES-Sym score), quality of life in respect to venous symptoms (VEINES-Qol score) and overall quality of life as determined by the patient (EQ-VAS score). Of the 23 returned questionnaires 11 patients had an occlusion or a  $>50\%$  in-stent stenosis on their last ultrasound scan and were categorised as diseased while 12 patients had mild or no disease and were categorised as non-diseased.

### Results

Significant correlations existed between VEINES-Qol and EQ-VAS scores (0.63,  $P = .002$ , CI=95%), and VEINES-Sym and VEINES-Qol scores (0.90,  $P = < .001$ , CI=95%). No significant difference was seen (independent samples t-test) between non-diseased and diseased groups for VEINES-Sym score ( $P = .996$ , CI 95%), VEINES-Qol score ( $P = .400$  CI 95%), and EQ-VAS score ( $P = .151$  CI 95%).

### Conclusion

In-stent disease was not a predictor of either venous symptoms or quality of life.

**Carotid atherosclerosis in people of European, South Asian and African Caribbean ethnicity in the Southall and Brent Revisited study (SABRE)**, Rayan Anbar, University College London

### Background

Atherosclerotic cardiovascular disease (CVD) risk differs by ethnicity(1). In comparison with Europeans (EA), South Asian (SA) people in the UK experience higher risk of coronary heart disease and stroke, while African Caribbean (AC) people have a lower risk of coronary heart disease but a higher risk of stroke(2,3).

### Methods

Cardiovascular risk factors were measured, and carotid ultrasound was performed in 985 individuals. Carotid plaques, and intima-media thickness (cIMT) were measured. Associations of carotid atherosclerosis with ethnicity were investigated using regression analyses, with and without adjustment for potential confounders (age, sex) and mediators (education, diabetes, hypertension, total cholesterol, HDL-C, alcohol consumption, current smoking).

### Results

Prevalence of any plaque was similar in EA and SA, and lower in AC (17%, 17%, and 6% respectively;  $p < 0.001$  by ANOVA). Total plaque area was also similar in EA and SA but reduced in AC, but there were no major differences in the maximum height or length of plaques in people with plaques by ethnic group. These ethnic differences were unaffected by adjustment for potential confounders or mediators. After adjustment for age and sex cIMT was higher in AC but this difference was attenuated by adjustment for CVD risk factors.

### Conclusion

Prevalence of carotid artery atherosclerotic plaques varies by ethnicity, independent of risk factors. The similarity of plaque burden in SA and EA despite established differences in CVD risk in these ethnic groups casts some doubt on the utility of carotid ultrasound as a means of assessing risk across ethnic groups.

### Ultrasound of Covid 19, Laura Marsden, Kings College Hospital

We present how we used ultrasound to improve our diagnosis of lung Covid 19 and use ultrasound to diagnose the complications of Covid 19. Ultrasound was more sensitive in detecting early Covid 19 than chest radiograph.

The complications of Covid 19 include renal impairment, liver impairment and vascular complications, mainly large vessel venous thrombosis, including renal vein thrombosis.

We are all suffering from post-viral fatigue but lessons can be learnt from this pandemic and the use of ultrasound.

### Ultrasound screening of non-alcoholic fatty liver disease (NAFLD) in children and adolescents: A critical review, Basil Nnaemeka Ezenwuba, Ultrasound Sheffield Teaching Hospitals

#### Background

Paediatric NAFLD is a global health concern, which can be effectively managed with early detection. Screening, using accurate and affordable/accessible tests, is recommended. However, there is currently no consensus on which tests are most appropriate. Although ultrasound is widely used, the performance against reference tests have not been fully assessed.

#### Aims

To critically evaluate the performances and potentials of ultrasound-based techniques for paediatric NAFLD screening.

#### Method

A systematic literature search of related databases/journals for peer-reviewed original articles published from January 2010 – July 2021 was conducted. PRISMA guidance was used to systematise and document the search/selection process. NIH quality assessment tool was used to critically appraise selected studies. The data extracted were subjected to thematic analysis and narrative synthesis.

#### Results

Eleven studies, with 774 participants, met the inclusion criteria. More studies included higher risk participants. B-mode and quantitative ultrasound techniques were compared against MR spectroscopy, MRI-PDFF and liver biopsy.

Ultrasound effectively detected steatosis, but performed better with moderate-severe steatosis.

#### Discussion

While B-mode methods - liver echogenicity and steato-scores - are commonly used, with a reported sensitivity of 70%, the former is not very effective. The latter reached up to 100% sensitivity, and greater than 80% specificity, hence recommendable for screening.

Quantitative (QUS) methods performed better than B-mode methods. Although QUS generally demonstrated excellent performance, with sensitivity/specificity of up to 100%, they will require further verification with more studies for effective use in screening.

## Conclusion

Ultrasound techniques can effectively be used for paediatric NAFLD screening, especially in higher-risk subjects. The steato-scores method is recommendable for routine use. QUS may potentially replace B-mode ultrasound for this purpose, however, non-standardised cut-off values are needed.

## The use of ultrasound elastography of the spleen in the investigation of human disease: a scoping review, Alexander Ford, King's College London

### Introduction

Ultrasound elastography is an emerging technology increasingly utilised for clinical evaluation of patients. This review examined the available literature to assess the potential value elastography has in investigating pathologies of the spleen.

### Method

Given the broadness and open-endedness of the topic, a narrative scoping review was performed. The online databases PubMed and Web of Science were searched for original clinical research published between January 2012 and November 2021 using key terms selected by the author. The inclusion criteria were: original studies (reviews and meta-analyses were excluded), published in the last ten years (2012 – 2021 inclusive), in English, conducted on human adults, examining disease in spleens.

### Results

203 reports were obtained, of which 26 met the inclusion criteria for the scoping review. Reports that met the inclusion criteria were tabled, detailing the author, title, publication date, sample size, population, and key research findings.

The research findings of these reports were then scrutinised, and common themes were identified. This allowed a narrative overview to be produced on the usefulness of elastography in the assessment of the spleen for the purpose of diagnosing and monitoring diseases.

### Conclusion

Elastography can assist in diagnosing cirrhosis, diagnose and monitor portal hypertension, predict oesophageal varices in hepatitis-induced cirrhosis, and monitor the patency of Transjugular Intrahepatic Portosystemic Shunts (TIPSs). Spleen elastography is sensitive enough that it can also distinguish between different causes of splenomegaly – namely hepatoportal, myeloproliferative and infectious diseases. This adds a wealth of diagnostic detail that cannot be determined by grey-scale ultrasound alone.

Given the tool's sensitivity in assessing the spleen and discriminating between different causes of splenic stiffness, research into the use of splenic elastography should expand beyond investigations of hepatoportal diseases, into other diseases that may alter splenic stiffness.

## Use of ultrasound and computed tomography in the diagnosis and management of early-stage Fournier's disease, Ben Warner-Michel, Syahminan Suut, Diagnostics and Pharmacy Group Northern Care Alliance

### Background

In this study I will discuss a confirmed case of early-stage Fournier's disease in a 46 year old male, with the aim of increasing awareness of clinical symptoms and radiographic appearances upon initial presentation.

### Case report

The patient presented to accident and emergency with painful bilateral hemiscrotal swelling and temperature of 38.8°C. The patient reported 'banging' his scrotum a few days prior, with the swelling initially beginning in the right hemiscrotum before spreading to the left side. Upon examination there was no evidence of bleeding, dysuria, or discharge, and the skin was intact with no other infective symptoms. The pain seemed inconsistent with the level and duration of inflammation, and erythema was noted with dark areas on midline. Working diagnosis was necrotising fasciitis.

Patient commenced vancomycin, clindamycin and meropenem. A subsequent ultrasound scan showed a distended and thickened scrotum with a 71mm echogenic right extratesticular collection suggestive of a hemiscrotal pyocele. Both testes were grossly unremarkable in size, shape and echotexture with mild right-sided hyperaemia. Subsequent contrast computed tomography demonstrated similar findings, with satisfactory appearances of the remaining pelvis.

The patient was listed for an urgent scrotal exploration and debridement; the necrotic tissue was debrided and both testes shown to be healthy and spared. Following wash-out the testes were placed into the ischiorectal pouch to await skin grafting. Follow-up monitoring showed regression of the erythema post-surgery suggesting resolution of infection.

### Discussion

This case demonstrates an early presentation of Fournier's disease with clear symptoms, clinical findings and radiographic appearances on US and CT. The appearance of the right-sided extratesticular pyocele and scrotal thickening is a useful ultrasonic indicator for Fournier's disease, highlighting the importance of rapid radiological imaging and good communication with the clinical team to facilitate prompt surgical management, prevent the spread of infection and improve clinical outcome.

**Diagnosis of a heterotopic pregnancy,** Gloria Guiteras Petitbo, University College Dublin

### Background

Heterotopic pregnancy (HP) is described as the coexistence of an intrauterine pregnancy (IUP) and an ectopic pregnancy. The diagnosis can be difficult due to the simultaneous presence of a viable intrauterine pregnancy and the lack of symptoms. Diagnosis of HP is important as it is potentially life-threatening.

The case involves a 29-years-old female, gravida 2 para 1 who was referred by her general practitioner to the early pregnancy unit with a light vaginal bleed. The initial visit was at 5+6 weeks gestation. She was sure about her last menstrual period and reported having regular periods every 28 days.

### Ultrasound findings

A transvaginal ultrasound scan (TVS) at 5+6 weeks showed an intrauterine gestational sac (IUGS). No yolk sac or foetal pole (FP) were seen. Both ovaries were examined and contained a cystic structure suggestive of bilateral corpus luteum. At 6+6 weeks a transabdominal ultrasound (TAS) identified the IUGS containing a FP with slow cardiac pulsations, however neither of the adnexa were assessed. TVS was not performed, and a plan was made for the patient to come back in 7 days as pregnancy was of uncertain viability. At 7+6 weeks a TAS and a TVS were performed. The intrauterine pregnancy (IUP) was seen containing a FP with no cardiac activity. The left adnexa was assessed and an ectopic gestational sac containing a FP was noted adjacent to the left ovary. No cardiac pulsations were seen. The right adnexa appeared normal.

### Discussion

HP is rare in spontaneous pregnancy. TVS is an effective tool for the diagnosis of ectopic pregnancy. The aim of the TVS is to assess both adnexa as well as the presence of an IUD.

### Conclusion

Even in the presence of IUP both adnexa should be assessed as an IUP does not eliminate the possibility of HP.

**Factors influencing sonographer-led bowel ultrasound service,** Emmanuel Babington, Ultrasound, University Hospitals of Leicester NHS Trust

### Aim

To investigate factors influencing UK sonographers' practice of adult bowel ultrasound.

### Method

A mixed-method online questionnaire was designed and shared on social media platforms in April 2021. Research restrictions due to COVID19 limited the sample size permitted. Convenience sampling recruited thirty UK sonographers performing adult abdominal ultrasound in their practice. Quantitative data were analysed using descriptive statistics, and qualitative data were analysed using inductive thematic analysis.

### Results

Quantitative data revealed that 53% (n= 16) of the participants expressed a lack of confidence in scanning the bowel, while 77% (n = 23) indicated a high level of interest in training in bowel ultrasound. Although 63.3% (n = 19) of the participants reported a high level of confidence in scanning the bowel for suspected appendicitis, the majority (70%, n = 21) expressed lack of confidence in examining the bowel for other pathologies like inflammatory bowel disease (IBD).

Inductive thematic analysis of qualitative data revealed that the participants had varying opinions on this topic. Emerging themes included training opportunities, preference of other imaging modalities, management challenges, sonographers, and radiologists' influence.



Qualitative results suggested that factors influencing sonographer evaluation of the bowel include advanced levels of training, a high degree of support from radiologists, regular bowel ultrasound lists, audits, and feedback from clinicians.

### Conclusion

Based on the findings of this study, most sonographers are not confident in practising bowel ultrasound beyond the evaluation of suspected appendicitis. Surveyed sonographers were interested in expanding their roles into other areas of bowel ultrasound like examining for Crohn's and ulcerative colitis. Sonographer role extension into this area of practice is limited by various factors like chronic shortage of sonographers, increasing workload, limited training, and the perception of diminishing support from radiologists. We recommend a future study that is not limited by a small sample size.

### Implementation of point of care ultrasound (POCUS) following a new curriculum focussing on common pathologies encountered in Ghana: physician's first experiences and perspectives,

Anna Pathak<sup>1</sup>, Elizabeth Joeekes<sup>2</sup>, Felix Limbani<sup>3</sup>, Yaw Asante Awuku<sup>4</sup>, Angela Booth<sup>5</sup>, <sup>1</sup>General Medicine NHS Tayside, <sup>2</sup>Radiology Liverpool School of Tropical Medicine and Worldwide Radiology, <sup>3</sup>Malawi-Liverpool-Wellcome Trust, Blantyre, Malawi, <sup>4</sup>University of Cape Coast, Ghana, <sup>5</sup>School of Health and Society University of Salford

Point of care ultrasound is increasingly recognised as an important tool, especially in countries like Ghana, where imaging services are scarce. Which indications are helpful for general physicians and how they impact patient outcomes remain largely unknown. Similarly, more information is needed on how implementation is perceived and can be made sustainable.

Our objective was to evaluate POCUS in daily practice, following delivery of a new broad POCUS curriculum targeted to pathology that is most common in Ghana.

We retrospectively performed a mixed methods study to evaluate the experience of 8 participants in their first 6 months of work after the pilot course. Questionnaires collected quantitative data, including physician's background, type and frequency of scans performed, level of difficulty, cases referred to radiology and results. Semi-qualitative interviews explored 5 domains affecting implementation of interventions: characteristics of the intervention, outer setting, inner setting, individual characteristics and process.

Results: 50% of participants applied 14/34 indications 2-6 times/week, mainly chest, cardiac and DVT scans. More complex scans (liver/female pelvis) were performed more frequently than anticipated (2-3/week by 25-60% participants). For referred cases, confirmation of diagnosis varied by indication (0-100%). Interviews revealed that POCUS was seen as a low complexity/cost, advantageous tool that improved patient diagnosis and management. They reported barriers to upscaling implementation such as a lack of quality assurance and difficulty acquiring portable probes in Ghana. POCUS was seen as a duplication of radiology by few hospital administrators and hospital radiologists. There was generally a lack of dedicated clinical space and staff trained in POCUS in the participants' hospitals.

In conclusion, overall uptake of scanning was excellent and implementation reported as beneficial to patients, supporting investment in further training and wider implementation. We will adapt the curriculum guided by these results and call for high quality, prospective implementation research.

### Does performing the sliding sign technique on TVUS accurately identify deep infiltrating endometriosis?, Rubavathie Chellan, Medical Ultrasound, University of Derby

#### Introduction

Endometriosis is a common gynaecological condition that may cause cyclical pain, dyspareunia, dyschezia, affects fertility and impacts patients' psychological and social wellbeing. Endometriosis often remains undiagnosed for years as symptoms also overlap with other conditions. Deep infiltrating endometriosis (DIE) is the most aggressive phenotype, affecting around 20% of women of reproductive age with endometriosis. NICE guidelines recommend using ultrasound as the initial imaging method to identify DIE. Subsequently, the IDEA consensus group suggests integrating the sliding sign technique for the same.

#### Method

PubMed and LibraryPlus were searched using the terms: "sliding sign technique", "endometriosis", "deep infiltrating endometriosis". Other imaging modalities and autopsy results were excluded. Peer-reviewed, international studies and quantitative results were used to reflect robust research.

### Results

Guerriero et al. (2020) followed 333 patients with suspected deep endometriosis; of these, 106 were found to have rectosigmoid involvement when using the sliding sign technique during TVUS. Hudelist et al. (2013) studied 117 patients before laparoscopy and accurately identified 34 patients with DIE. Additionally, Reid et al. (2013) surveyed 100 patients to compare pouches of Douglas obliteration using the sliding sign technique against laparoscopy and yielded 93% accuracy.

Relevance to practice: Incorporating the sliding sign technique with TVUS may improve detection and localisation of DIE in patients with suspected endometriosis. It may also expedite diagnosis thus allowing women to access treatment sooner. However, incorporating this technique into practice will require further sonographer training along with protocol updates.

### Conclusion

The sliding sign technique helps identify DIE in women with suspected endometriosis and demonstrates high sensitivity and specificity. However, extra training provision for sonographers and changes in local protocols to include the sliding sign during TVUS need to be addressed first.

### Guidelines and coping mechanisms for obstetric sonographers delivering unexpected news via ultrasound, Gary Hicks, School of Radiology AECC University College

#### Aims

The delivery of difficult news is a commonly cited stressor of those working in obstetric ultrasound, contributing to a high rate of burnout in the sonography workforce. Whilst the impact of occupational and musculoskeletal aspects of sonographer duties are recognised, the emotional challenge and coping mechanisms facing sonographer workforce delivering bad news in obstetric ultrasound are less understood. This poster reviews guidelines and recommendations for sonographers and departments delivering difficult news, ensuring the highest quality of care, staff and patient wellbeing.

#### Methods

A systematic literature search included the National Institute for Health and Care Excellence (NICE), British Medical Ultrasound Society (BMUS), Society of Radiographers (SoR), Royal College of Obstetricians and Gynaecologists (RCOG), academic databases Google Scholar, PubMed, PsycINFO, Cochrane and the Stillbirth and Neonatal Death Charity (Sands). Inclusion criteria included studies of workforce census, empirical qualitative or mixed methods design. Three blocks of MESH terms comprised 'ultrasound,' 'experiences,' and 'foetal abnormalities.' An exclusion criterion removed grey literature and studies not written in English.

#### Results

Guidance for delivering unexpected bad news in ultrasound has been advanced significantly by the systematic review and meta-ethnographic synthesis of expectant parent and staff experiences (Johnson et al., 2020), leading to the Consensus Guidelines on the Communication of Unexpected News via Ultrasound: The ASCKS framework. Furthermore, in 2018, the National Bereavement Care Pathway (NBCP) began rolling out to NHS Trusts, as of July 2021, 63% of NHS England trusts have committed to the NBCP standards.

#### Conclusion

Delivering difficult news is a commonly cited stressor for those working in obstetric ultrasound. This study has shown that common themes beneficial to staff and patient wellbeing are prevalent; benefits of observational training; MDT or team-based debriefs; appointment times allowing for unexpected news, not determined by oversaturated worklists; it is imperative staff are fully supported by their department.

# DAY TWO

Wednesday 7th December

## Obstetrics

**Clinical value of 3D ultrasound at 11-14 weeks of gestation**, Jayne Lander, Jehan Karim, Aris T Papageorghiou, University of Oxford

Early fetal anatomical assessment can detect a large proportion of congenital abnormalities but requires significant operator skill. In this study we aimed to understand the clinical value of using 3D ultrasound as an adjunct to standard examination.

Prospective observational study of pregnant people presenting for routine first trimester ultrasound between November 2021 and April 2022. Those recruited and agreed to participate to the study underwent a standard first trimester 2D scan. A 3D volume in an anterior coronal view was then attempted and when successful, uploaded to GE 4D view software. Each 3D volume was examined both as a surface image and in multiplanar view to determine which of the following anatomical views were visible: head, facial profile, heart, abdomen, cord insertion, bladder, upper and lower limbs, CRL and NT.

We prospectively recruited 81 participants. In five (6%), it was not possible to obtain a good quality 3D volume. For the remaining 76 patients (94%) at least one 3D volume was stored. Based on each 3D volume, a diagnostic CRL (88%) and NT image (72%) was obtainable in most cases. In addition, it was possible to adequately visualize the following anatomical fetal structures: head (93%), facial profile (80%), bilateral hands (92%), bilateral feet (80%), cord insertion (80%), stomach (62%), bladder (22%) and heart (4CV) (13%).

Adding 3D ultrasound is of clinical value when examining the first trimester fetus. With appropriate training, a 3D volume can be obtained within minutes, allowing the visualization of major anatomical structures in the first trimester without adding significant time pressures on ultrasound departments. Future studies should examine if it could be a useful alternative to 2D imaging rather than an adjunct, particularly in cases where a fetal anomaly is suspected.

**How much extra time do sonographers really need to perform 20-week uterine artery Dopplers?**, Ellen Dyer, University of Cambridge

### Background

Obstetric ultrasound departments across England have seen an increase in demand for growth scans associated with the implementation of the original Saving Babies' Lives care bundle in 2016. Version 2 of the care bundle saw the introduction of 20-week uterine arteries screening for women with risk factors for fetal growth restriction (element 2).

The time taken to perform and report uterine artery Doppler at 20 weeks has been overlooked in the planning of version 2 of the care bundle, and although it might seem trivial to policy makers, on a practical level it is an important factor to consider and one this study aims to answer.

### Method

The scans from 276 consecutive participants recruited to the Pregnancy Outcome Prediction Study 2 (REC reference 19/EE/0331) for combined 20-week FASP and research scan were reviewed retrospectively. Scans were performed by sonographers with experience of working in both a research and NHS setting; all had undertaken in-house uterine artery Doppler training.

The time taken to perform the uterine artery Doppler for each scan was defined as the time of final uterine artery image minus the time of the image taken before the first uterine artery image.

### Results

Preliminary results suggest that uterine artery Dopplers can be performed to a high standard in less than five minutes.

### Discussion

This study suggests uterine Doppler measurements can be required in less than five minutes by sonographers. Clinically however, sonographers will also need additional time to report the measurements, explain the findings to potentially anxious parents and arrange appropriate onward referral when required. The addition of 15 minutes to the 30-minute FASP 20-week scan can therefore be easily justified.

**Assessing the introduction of the new BMUS 'Growth' guidelines into routine practice**, Sally Holloway, Trish Chudleigh, Ellen Dyer, University of Cambridge

### Aim

To identify any differences between measuring the fetal abdominal circumference using two methods.

### Introduction

The 2022 BMUS 'growth' guidelines recommend the two diameters method for measuring abdominal circumferences (AC). This study investigates the potential impact of changing from the ellipse method to the two diameters method.

### Method

Two 28-week and 36-week scans were randomly selected and the reported AC measurement was removed from each image. The AC section in the two 28-week images and in one 36-week image were reasonably circular and considered potentially 'straightforward'. The second 36-week image was considered potentially 'difficult' owing to the proximity of a fetal knee. Eight sonographers 'blindly' measured each image using the two diameters method followed by the ellipse method.

The intra-operator and inter-operator variabilities for both methods were calculated for each of the four images.

### Results

Thirty sets of paired measurements were analysed. The ellipse measurement was bigger in 27 cases. The intra-operator variability between the two methods varied, with the largest differences of 0.1-18.4mm resulting from the 'difficult 36-week image'. The inter-operator variability varied from 11.6-12.1mm, equivalent to 4.1-6.1% of the reported AC, for the two diameter measurements and 4.3-16.5mm, equivalent to 1.7-5.6% of the reported AC, for the ellipse.

### Conclusion

The large intra-operator variability when applying the two methods to the same image emphasises the potential clinical implications of introducing a new working method into routine practice. The fact that the inter-operator variability was less for the ellipse method than for the two diameters method in the three 'straightforward' AC images underlines the importance of training before a new method is introduced. The benefits of using the two diameters method in difficult cases is supported from the data from image 4.

## MSK

**Semi-automated tracing of hamstring muscle architecture for B-mode ultrasound images**, Kevin Cronin<sup>1</sup>, Eamonn Delahuint<sup>1</sup>, Shane Foley<sup>1</sup>, Giuseppe de Vito<sup>2</sup>, Conor McCarthy<sup>3</sup>, Sean Cournane<sup>1</sup>, <sup>1</sup>University College Dublin, Ireland, <sup>2</sup>University of Padova, Padova, Italy <sup>3</sup>Mater Private, Ireland

### Introduction

Hamstring strains are the most prevalent injury sustained by field-sport athletes. Insufficiencies in the architectural characteristics of the hamstring muscles can heighten an athlete's risk of incurring a hamstring strain. To evaluate the influence of hamstring muscle architectural characteristics (i.e., fascicle length, pennation angle, muscle thickness) on injury risk, it is necessary to precisely evaluate these characteristics.

### Aim of Investigation

The purpose of this study was to develop a novel semi-automated tracing software for measuring the architectural characteristics of the hamstring muscles, and to quantify its accuracy and precision.

## Methods

Static sonograms of the Biceps Femoris long head (BFH) muscle were acquired from ten different healthy male athletes, with their respective architectural characteristics (fascicle length (Lf), pennation angle (PA) and muscle thickness (MT)) analysed ten times using the tracing software, in order to determine the measurement precision. The precision of the PA was evaluated for distances of 2.5mm, 25%, 50%, 75% along the total fascicle length from the insert into the aponeurosis.

## Results

Excellent precision was found for the BFH muscle architectural characteristic measurements: Lf (%CV: 0.64-1.12), PA (%CV: 2.58-10.70) and muscle thickness (%CV: 0.48-2.04).

## Conclusions

We have developed an accurate and precise semi-automated skeletal muscle tracing algorithm for quantifying fascicle length, pennation angle and muscle thickness on static B-mode ultrasound images.

## Young Investigators

### **The effect of suspension medium on the ultrasound backscatter signature of microbubbles within a flow phantom**, Lauren Gilmour, Roger Domingo-Roca, Jake Miller, Joe Jackson-Camargo, Helen Mulvana, University of Strathclyde, Scotland

Systemically circulating microbubbles (MBs) are used as an ultrasound contrast agent and have more recently been investigated as a drug delivery tool. When MBs oscillate within an ultrasound field, they scatter the signals which can then be detected and analysed. We previously showed that non-linear content within MB backscatter signals is influenced by the flow rate and mechanical index when investigated in tissue-mimicking flow phantoms. Here, we investigate the effect that the fluid medium (blood vs saline) has on backscatter signals and consider implications for in vivo drug delivery and contrast enhanced ultrasound imaging.

A 200  $\mu\text{m}$  cellulose fibre was positioned at the coaxial focal point of two matched, single element transducers within a tank of outgassed water. A MBs (Sonovue) suspension was added to PBS or blood and drawn through the fibre using a syringe pump (flow rates; 30, 50, 70  $\mu\text{L}/\text{min}$ ). The transmit transducer was driven at 3.5 MHz with a 10 cycle burst, PRF 100 Hz, and mechanical index: 0.1, 0.2, 0.3, 0.4, 0.5. Signals scattered by MBs were amplified and acquired to a PC for post processing in MATLAB to reveal peak spectral energy and peak amplitude for the first (fundamental), second and third harmonic frequencies under each condition.

Harmonics of the fundamental driving frequency appeared in the backscattered signals acquired, confirming that signals originated from MBs travelling through the flow phantom. Spectral energy at each harmonic increased with MI, while spectral energy overall was reduced in blood as compared with saline. The proportion of energy carried within the higher harmonics was greater at lower flow rates for higher MI, which is likely due to the MBs having spent longer in the focal zone. Experiments are ongoing to perform these tests in 3D printed tissue mimicking flow phantoms containing complex geometries which will produce more varied flow.

### **Sonographer led discharge in a deep vein thrombosis clinic; a feasibility study**, Catherine Lee, Royal Devon University NHS Foundation Trust

## Background

Radiographer-led discharge is not a new concept, but there is a lack of evidence exploring the role of sonographers in improving patient flow through hospitals. NHS Improvement and NHS England (2018) promote utilising Allied Health Professionals (AHPs) in care pathways to increase efficiency. We establish if sonographer-led discharge could be employed in a deep vein thrombosis clinic to improve efficiency without detrimental effect on patient satisfaction and safety.

## Method

A prospective mixed methods service evaluation was completed. Length of appointment times between the control group who see an advanced clinical practitioner and a sonographer, and the intervention group who see a sonographer only were compared. Patient views were collected in a survey. Discharge summaries were assessed blindly for quality by acute medical consultants.



### Results

Patients in the sonographer group had a statistically significant shorter appointment time than those in the control group. Patients did not have a preference about which professional group cared for them, provided the staff were competent to do so. There was no impact on patient satisfaction or safety when seen by a sonographer alone.

### Conclusion

This study has confirmed that sonographer-led discharge is feasible, efficient and has no detrimental effect on patient safety or satisfaction. It also has the possibility to enhance professional practice of sonographers. Work such as this is in line with national initiatives to improve patient flow through hospitals by incorporating the skill mix of AHPs into new patient pathways. Role extension such as sonographer-led discharge could provide supporting evidence for advanced practice portfolios for sonographers.

### References

NHS Improvement and NHS England (2018) Allied health professions supporting patient flow: a quick guide. Available at: [https://nhsicorporatesite.blob.core.windows.net/green/uploads/documents/AHPs\\_supporting\\_patient\\_flow\\_FINAL\\_.pdf](https://nhsicorporatesite.blob.core.windows.net/green/uploads/documents/AHPs_supporting_patient_flow_FINAL_.pdf) (Accessed 22 September 2021).

### **Prediction of arteriovenous fistula maturation outcomes in end-stage renal disease patients, using invasive and non-invasive techniques: Pilot study, Wael Faqihi, Imperial College London**

#### Aim

Predicting arteriovenous fistula (AVF) remains challenging. This study investigates the role of arterial stiffness and endothelial dysfunction on AVF maturation outcomes in end-stage renal disease (ESRD) patients using advanced ultrasound applications.

#### Method

A prospective observational cohort pilot study. Seventeen patients with ESRD who underwent AVF surgery were recruited. AVF native artery and vein were scanned and assessed pre- and post-surgery using ultrasound B-mode, 2D shear wave elastography (2DSWE), 2D strain speckle tracking (2DSST) and laser Doppler flowmetry (LDF). During the surgery, blood volume flow (BVF) was measured intraoperatively using a transonic vascular probe. Patients were then followed for six weeks.

#### Results

Seventeen fistulas were created and four failed to mature. Patients' average age was  $56.3 \pm 14.1$  years, 80.4% males. BMI average was  $28 \pm 5.3$  kg/m<sup>2</sup>, hypertension (100%), diabetes (41.2%), and CVD (35.3%). 2DSWE readings among the failure group were higher than patent group  $4.23 \pm 0.43$  m/s,  $3.90 \pm 0.42$  m/s respectively. 2DSST readings were similar between both groups, failure  $2.65 \pm 0.52\%$  and patent  $2.12 \pm 0.70\%$ . LDF significantly correlated with AVF maturation outcome,  $p < 0.001$ , failure  $17.3 \pm 0.50$  a.u., patency  $22.2 \pm 2.24$  a.u. BVF in the failure group was lower than patency group  $164.8 \pm 135$  ml/min,  $434.5 \pm 209.5$  ml/min respectively,  $p < 0.057$ .

#### Conclusion

2DSST and 2DSWE are promising tools to study arterial wall properties but were not correlated with AVF maturation outcomes, possibly due to the small sample size. LDF and BVF measurements showed a strong indicator for predicting AVF maturation outcomes.

### **The first 5 targeted trans-perineal prostate biopsies diagnose the majority of PROMIS criteria cancer in patients with a Likert 4 or 5 score on mpMRI, William Stevens, Ese Adiotomre, Oliver Hulson, Atif Khan, Roger Lapham, Philip Melling, Adam Morrell, Sacha Pierre, Jonathan Smith, Leeds Teaching Hospitals NHS Trust**

#### Purpose or learning objective

To see if the first five transperineal (TP) biopsies give a diagnosis of PROMIS criteria cancer in patients with a likely prostate cancer on mpMRI.

#### Methods or background

NICE guidelines suggest multiple prostate biopsies for histological diagnosis of cancer in those patients with a Likert 4 or 5 score on their mpMRI scan. Depending on the treatment planned, some patients need systematic TP biopsy, but in frail patients, those with limited treatment options or extensive disease, a cancer diagnosis may be all that is required.

375 patients had mpMRI for suspected prostate cancer between January and June 2021 in a large volume quaternary centre. 367 were given a Likert score of which 108 were scored Likert 4 or 5. Of these, 94 patients were sent for biopsy. 70 of the biopsied patients were ultimately diagnosed with PROMIS criteria cancer. A separate pot was sent containing the first 2-5 targeted biopsies in 69 of the 70.

### Results or findings

The median number of biopsies in all patients sent for biopsy was 12 (range 3-19). The first 2-5 targeted biopsies showed PROMIS criteria cancer in 65 of the 69 (94.2%) Likert 4 and 5 patients diagnosed with cancer. 62/69 (89.9%) showed the maximum length or grade of cancer in the first 2-5 targeted biopsies. All 4 of the missed cancers were ISUP 2 or less and located in the apex of the gland.

### Conclusion

A cancer diagnosis is usually obtained in the first 2-5 targeted biopsies in patients with a Likert score of 4 or 5. Further biopsies may be required for treatment planning or for lesions in the apex of the gland where cancers can be missed.

## Point of Care Ultrasound

**Using ultrasound to gain peripheral venous access: A local teaching programme,** Lakshya Soni, Eri Aung, Richard Beese, Queen Elizabeth Hospital, Woolwich, London

### Aim

Ultrasound-guided peripheral intravenous cannulation is not regularly taught during medical training in the United Kingdom, leading to a reliance on specialty anaesthetic trainees and intravenous access teams for more challenging venous access. Delays in establishing access lead to worse patient outcomes, due to delayed administration of intravenous medications and fluids. This study aimed to investigate the efficacy of a local teaching session on doctors' perceived confidence and difficulty in performing ultrasound-guided cannulation.

### Methods

A local teaching session was delivered on the principles of ultrasound, including a model demonstration, and supervised individual attempts with personalised feedback. Pre- and post-session surveys were distributed to measure perceived confidence and difficulty scores using the Likert scale. Microsoft Excel and GraphPad were used for statistical analysis.

### Results

There were 13 participants, with a mean age of 28.8 years, and a gender ratio of 1:6 (F:M). 23% of participants had received previous formal training on ultrasound-guided cannulation. 69% of participants had self-reported minimal previous experience with ultrasound-guided cannulation.

Confidence scores significantly increased from 2.46 to 3.76, ( $p=0.00032$ , 95%CI=0.74-1.88). Perceived difficulty scores significantly decreased from 6.54 to 3.15, ( $p<0.00001$ , 95%CI=2.41-4.36). Previous formal teaching did not significantly affect the change in perceived confidence nor difficulty. The increase in confidence scores was significantly higher for participants with minimal previous experience, with a mean increase of 1.67, compared to 0.50 ( $p=0.01885$ ). Previous experience did not significantly affect the change in perceived difficulty.

### Conclusion

A workforce trained in ultrasound-guided cannulation would lead to improved patient outcomes by reducing delays in treatment and improved staff outcomes by reducing specialty team workload. This local teaching programme is a low-cost, effective measure to improve doctor confidence and ability in performing ultrasound-guided cannulation.

**Ultrasound skills at ITU teaching experience**, Tatyana Bolonenkova, Richard Beese, Queen Elizabeth Hospital, Woolwich, London

### Objective

Our project was to teach doctors how to perform and interpret point-of-care ultrasound in intensive care settings, and to learn about ultrasound for vascular access, chest ultrasound, echo, renal failure, liver failure and jaundice, and DVT diagnosis.

### Method

The teaching has been running weekly at Critical Care and in the Radiology Department on a simulation manikin with provided images of different pathologies. After each session, a questionnaire was offered to assess doctors' feedback.

### Results

During the ultrasound hands-on sessions, a diverse group of the doctors were involved. The doctors' feedback has shown a high interest in learning about ultrasound. The majority had either no or little experience in performing the ultrasound prior to those sessions.

The teaching has improved the understanding about the different types of ultrasounds probes, scanning positions and obtaining good images. Anonymised ultrasound images have been uploaded on the cloud storage, and shared with the supervising consultant radiologist to review and discuss.

While running the programme there were some pros and cons about ultrasound on Intensive care noted. The pros were: It saves time, because you do not need to wait for the radiology department. It can be performed as many times as needed. It is relatively easy to learn and acquire competencies. The ultrasound findings can direct the treatment.

However, learning ultrasound requires supervision and mentoring by an ultrasound competent professional. It needs regular practice and determination. You have to be aware of limitations and ask for an official scan earlier.

### Conclusion

To summarise, looking into the future of managing the most complex patient, an ultrasound is a simple, portable investigation which can be widely used at Critical Care.

Learning ultrasound skills are the achievable up-to-date competencies for ITU doctors, which can become a routine tool for assessing critically ill patients.

## THERAPEUTIC ULTRASOUND NETWORK FOR DRUG DELIVERY AND ABLATION RESEARCH

**Sonoporation of cells to enhance the liberation of intracellular biomarkers**, Carmel M Moran<sup>1</sup>, Oliver Teenan<sup>1</sup>, Vishal Sahni<sup>3</sup>, Henderson RB<sup>3</sup>, Bryan Conway<sup>1</sup>, Jeremy Hughes<sup>2</sup>, Laura Denby<sup>1</sup>, <sup>1</sup>Centre for Cardiovascular Science, University of Edinburgh, <sup>2</sup>Centre for Inflammation Research, University of Edinburgh, <sup>3</sup>GlaxoSmithKline, Medical Research Centre, Stevenage, UK

Contrast microbubbles when insonated with ultrasound have the potential to cause cell membrane permeability. This has been shown to be potentially beneficial in techniques such as targeted drug delivery or opening of the blood-brain barrier. Research we are undertaking seeks to establish whether cavitating microbubbles adjacent to cells have the potential to liberate cell-specific biomarkers for non-invasive liquid biopsies.

For our in vitro studies, human polarized Renal Proximal Tubular Epithelial Cells (RPTECs) were grown on ThinCert membranes. Membranes were suspended in a beaker with an acoustic absorber and insonated in the presence of SonoVue microbubbles or a sodium chloride vehicle. Ultrasound was applied using a Vevo Sonigene with a 1MHz unfocussed transducer with treatment times of 5, 10, 15 or 30 s at a 50% duty cycle and 2W/cm<sup>2</sup> nominal output power and at microbubble concentrations ranging from 0.1-10%. Expression of different micro RNA (miRNAs) biomarkers and cell viability were determined.

For our in vivo studies, a mouse model of unilateral ureteral obstruction (UUO) was used to explore the detection of injury-specific biomarkers. Both Micromarker and SonoVue microbubbles were infused and insonation took place using a Sonidel SP100 (Sonidel, Ireland) 1MHz transducer.

The in vitro studies demonstrated that cell-specific biomarkers can be released from RPTECs in the presence of microbubbles without significant cell-death. In vivo studies demonstrated that tissue-specific biomarkers can be liberated but at higher acoustic output settings and duty cycles.

This work was carried out under a PhD studentship held by Oliver Teenan, University of Edinburgh and funded by a BBSRC:National Productivity Investment Fund PhD scholarship co-funded by GSK.

**Detection of HIFU Lesions by Optical Coherence Tomography**, Jason Raymond<sup>1</sup>, Manuel Marques<sup>2</sup>, E. Carr Everbach<sup>1,3</sup>, Michael Hughes<sup>2</sup>, Ronald A. Roy<sup>1</sup>, Adrian Podoleanu<sup>2,1</sup> Dept. of Engineering Science, University of Oxford, <sup>2</sup>Dept. of Engineering, Swarthmore College, United States, <sup>3</sup>School of Physical Sciences, University of Kent

The use of high-intensity focused ultrasound (HIFU) to induce irreversible changes in tissue due to heating is well established. We have shown that changes in tissue optical properties (scattering and absorption coefficients) could be used as a proxy to improve sensing and imaging of HIFU lesion formation, as an alternative to conventional methods such as thermometry. Optical coherence tomography (OCT) is a non-invasive optical imaging method which relies on low-coherence interferometry to determine the depth of individual scattering centres within the tissue. Previous studies have demonstrated that OCT signals are sensitive to morphological changes in heated tissue, likely due to denaturation of proteins concomitant with formation of crosslinked structures. The goal of this study was to assess the use of OCT for sensing and imaging HIFU lesions. We demonstrate the feasibility of imaging near-surface lesions in ex vivo chicken breast tissue exposed to HIFU. This technique has potential for detecting changes in optical properties corresponding to the progression of surface lesion formation which are antecedents of skin burn during HIFU exposures, thereby increasing safety and reducing treatment times.

**The effects of repeated histotripsy treatments on the viral delivery and growth of murine pancreatic tumours**, Petros Mouratidis, The Institute of Cancer Research, Therapeutic ultrasound group, Division of Radiotherapy and Imaging

Pancreatic ductal adenocarcinoma (PDAC) is a disease with dismal prognosis and 5-year survival rates < 1%. No treatment options exist for advanced PDAC patients, and treatments including immunotherapy have failed to extend survival. Boiling histotripsy can induce cavitation and emulsify solid tumours. These exposures would be particularly suitable for treating pancreatic tumours to interfere with their dense regulatory stroma. In this study boiling histotripsy was used to improve the delivery of viruses and survival of murine PDAC models. The induction of the immune response has also been investigated.

Syngeneic orthotopic pancreatic KPC tumours (Kras<sup>LSL.G12D/+</sup>; p53<sup>R172H/+</sup>; PdxCre tg<sup>+/+</sup>) were grown in immune-competent murine C57BL/6 subjects. Tumours were exposed to histotripsy (P = 17 MPa, duty cycle = 1 %, PRF = 1 Hz, 15 repeats, f = 1.5 MHz, lesions every 1mm) with the small animal Alpinion VIFU 2000 platform in the presence or absence of intravenously (IV) injected reovirus (107 pfu/injection). Acoustic cavitation was monitored using 2D high frequency (14 MHz) B-mode ultrasound imaging during treatment and was quantified using a weakly focused polyvinylidene fluoride, broadband (0.1 to 20 MHz) passive cavitation detector after treatment. Reovirus infection of tumours was histologically assessed, and immune effects were determined using single cell RNA-sequencing. Two histotripsy treatment sessions were delivered to the animals 1 week apart. No side effects were seen. These treatments induced cavitation and approximately doubled the survival of subjects compared to sham-exposed subjects. Histotripsy treatments also increased viral delivery in the pancreatic tumours. Single-cell sequencing of tumours of sham-exposed subjects and those treated with histotripsy with or without reovirus were performed, and results will be presented.

The use of multiple histotripsy treatments significantly improves the survival of subjects carrying orthotopic pancreatic KPC tumours. Enhanced viral delivery in histotripsy-treated tumours was also demonstrated.

**Temperature measurements during high intensity focused ultrasound exposure**, Raphaela Baesso, Aoife M. Ivory, Piero Miloro, Srinath Rajagopal, Ultrasound and Underwater Acoustics, National Physical Laboratory, Teddington

### Introduction

Ultrasound-based therapies continue to develop and show promise as non-invasive tools for cancer treatments. High-intensity focused ultrasound (HIFU) can be used for both thermal ablation and hyperthermia. However, the accurate measurement of temperature during HIFU exposure remains a challenge, especially in case of hyperthermia where maintaining a defined temperature is critical for successful treatment outcomes.

### Objectives

The aim of this work was comparing measurements performed using a fine wire thermocouple with thermo-acoustic simulations performed using k-wave. The comparison between measurements and simulations is expected to improve the knowledge of artifacts such as viscous heating and validate simulation against controlled laboratory measurements.

**Materials and methods**

A HIFU transducer (H-101, Sonic Concepts, Washington, USA) was characterised (acoustic power and pressure). The transducer was driven at 1.06 MHz using different acoustic powers (1 W, 2 W, 3 W and 4 W) and exposure time (2 min, 3 min and 4 min). The sine wave was triggered using a gate with a period of 4.1 s and 97.6% duty cycle. The time off was added to evaluate the effects of viscous heating. The measurements were performed at the focal distance and 20 mm from the front surface of the tissue mimicking material (TMM). Four K-type thermocouples (T0, T1, T2 and T3) were placed in parallel, 2.5 mm apart from each other. The TMM was prepared according to Annex DD of IEC 60601-2-37:2007/AMD1:2015 and acoustically characterised.

**Results**

The table below reports the comparison for the final temperature after 2 minutes exposure at different power levels, similar results are available for 3 and 4 minutes.

Power (W)	Measurements (°C)	Model (°C)	Difference (%)
1	4.3	3.9	8.8
2	8.5	7.7	9.8
3	12.6	11.4	9.4
4	16.7	15.1	9.3

**Conclusion**

There is good agreement between simulations and measurements, with the measurements always reading around 9% higher than simulations. This value can be an indication of the order of magnitude for viscous heating artifact. Further investigations will provide additional insight into the source of the differences.

**Acknowledgment**

The activities here presented were partly developed in the framework of the EURAMET, European Association of National Metrology Institutes, 18HLT06 RaChY Project that received funding from the EMPIR program, European Metrology Programme for Innovation and Research (funder ID: 10.13039/100014132) co-financed by the participating States and from the European Union’s Horizon 2020 research and innovation program.

**Preparation and characterisation of phase-changed nanodroplets for ultrasound blood-brain barrier permeability enhancement in vitro**, Stavros Vlatakis<sup>1</sup>, Weiqi Zhang<sup>1</sup>, Alexandru Moldovan<sup>2</sup>, Hilde Metzger<sup>2</sup>, Sarah Thomas<sup>1</sup>, Sandy Cochran<sup>2</sup>, Paul Prentice<sup>2</sup>, Maya Thanou<sup>1</sup>, <sup>1</sup>King’s College London, Institute of Pharmaceutical Sciences, London, UK, <sup>2</sup>University of Glasgow, James Watt School of Engineering, Glasgow, UK

Phase-change nanodroplets (NDs) have a perfluorocarbon (PFC) core that undergoes acoustic vaporisation and makes them respond to ultrasound (US). This event is called cavitation and potentially causes a reversible permeability to increase the blood-brain barrier (BBB) for a short period. This study analyses the preparation of lipid-based NDs to create a targeted drug delivery method. The NDs were prepared using the thin-film hydration method, followed by the PFC addition, and were characterised for size, cavitation (high-speed camera) and PFC encapsulation (using FT-IR). BEND3 (mouse brain endothelial) cells were seeded onto transwell inserts. NDs and microbubbles were applied on the BEND3 with and without US, and fluorescein permeability was measured. The Live/Dead assay was used to assess the BBB integrity. Size and PFC content analysis indicated that the NDs were stable while stored. High-speed camera imaging showed cavitation after US exposure of 0.12 MPa. The BBB cell model experiments revealed a 4-fold increase in cell membrane permeation after the combined application of US and NDs. The Live/Dead assay displayed some damage to BBB membrane integrity but less when compared to the one caused by microbubbles. Nanodroplets have the potential to be a safer alternative to microbubbles for BBB opening.



**The potential of phase-change nanodroplets in generating reactive oxygen species for sonodynamic anticancer therapy**, Shazwan Abd Shukor, Hasti Seyed Zonouzi, Abu Bokor Osmani, Maya Thanou, King's College London, Institute of Pharmaceutical Sciences

Sonodynamic therapy (SDT) is a mode of therapy based on the non-invasive ultrasound treatment, that aims at generating reactive oxygen species (ROS) through the activation of molecules with sensitizer properties. In this study, two potential sensitizers namely, curcumin and IR780 are introduced as solutes or as in nanodroplets to assess their effect in generating ROS. Solutions consisting of either curcumin/IR780 mixture or curcumin/IR780-loaded phase-change nanodroplets (PCND) were treated with ultrasound and the ROS levels were assessed. Two ROS assays, one with potassium iodide (KI) and one with terephthalic acid (TA) were used to detect and quantify the production of ROS particularly, hydrogen peroxides ( $H_2O_2$ ) and hydroxyl radicals (OH). Two sets of ultrasound settings were used, a continuous and a pulsed mode with a frequency and acoustic pressures of 1MHz and 0.9/1.3MPa, respectively. A duty cycle of 20% was applied in the pulsed mode whereas the continuous mode should possess a duty cycle of 100%. The experiments were run under ultrasound applications in the dark for 5 minutes. The continuous mode ultrasound application showed that both curcumin/IR780 mixture and curcumin/IR780-loaded PCND generated significantly higher ROS in comparison to their corresponding groups that were not treated by ultrasound. This was observed for both lower and higher acoustic pressures of 0.9MPa and 1.3MPa. However, there was almost no ROS production in the 20% pulsed mode irradiations at lower acoustic pressure of 0.9MPa, which was chosen to comply with the safe mechanical index (MI) requirement used in the clinic. Subsequently, three different concentrations of curcumin/IR780 mixtures i.e. 7.5, 12.5 and 25 $\mu$ M for each curcumin and IR780 with the same ultrasound settings were used in pulsed mode. Increasing each component concentration to 25 $\mu$ M resulted in a two-fold increase of ROS production when a 20% pulsed ultrasound was applied. Then, 25 $\mu$ M curcumin/25 $\mu$ M IR780 mixture was loaded in PCND to further assess ROS production. Results showed that the production of ROS was higher in the dual-load curcumin/IR780 PCND compared to single-load PCNDs. Hence, 25 $\mu$ M of curcumin/25 $\mu$ M IR780-loaded PCND with ultrasound settings i.e. frequency, acoustic pressure and duty cycle of 1MHz, 0.9MPa and 20% respectively were the optimal conditions for the highest ROS production in solution.

In summary, both curcumin and IR780 and their dual-load form in PCND have been shown to generate ROS upon ultrasound irradiation which can be further evaluated to promote sonodynamic anticancer therapy.

### References

Li Q, Lin X, Fan Y, Rao M, Wang Y, Wang M, Wang Z, Hao L, Yuan G. Dual-sonosensitizer loaded phase-transition nanoparticles with tumor-targeting for synergistically enhanced sonodynamic therapy. *Biomater Sci.* 2021 Sep 14;9(18):6126-6141.

Zhang W, Shi Y, Abd Shukor S, Vijayakumaran A, Vlatakis S, Wright M, Thanou M. Phase-shift nanodroplets as an emerging sonoresponsive nanomaterial for imaging and drug delivery applications. *Nanoscale.* 2022 Feb 24;14(8):2943-2965

**Characterisation of cavitation threshold properties of selected hydrogels as tissue mimics for therapeutic ultrasound**, Lisa Braunstein, Ian Rivens, John Civale, Sarah Brueningk, Gail ter Haar, The Institute of Cancer Research, Therapeutic ultrasound group, Division of Radiotherapy and Imaging

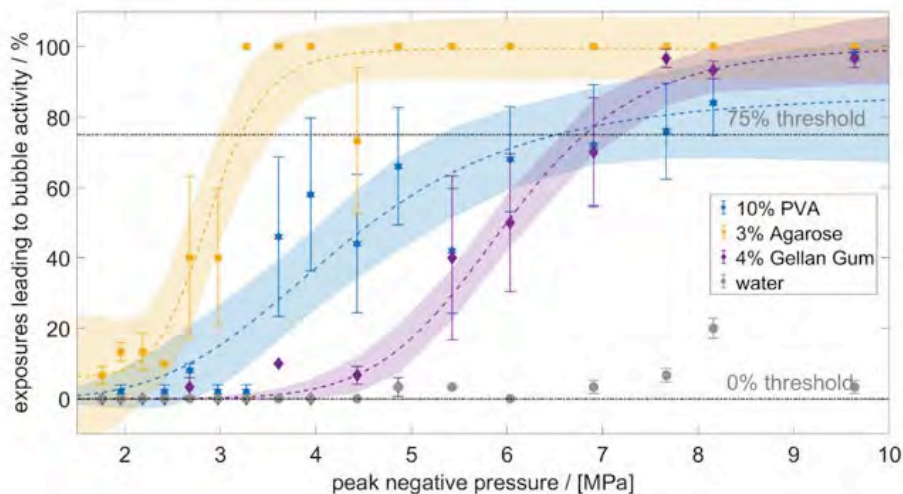
When ultrasound travels through tissue the mechanical effects induced to tissue, especially ultrasonic cavitation, can be harnessed for therapeutic purposes. For the evaluation of their potential, tissue mimicking materials have been characterised.

Polu(vinyl alcohol) (PVA) hydrogels (10-20% w/w  $\pm$ 5-10% w/w cellulose), agarose hydrogels (1.25-3% w/w  $\pm$ 3% cellulose) and gellan gum gels (concentration 2-4% w/w  $\pm$ silicone oxide scatterer (2%)) were characterised acoustically and for their cavitation thresholds. The finite amplitude insertion substitution method (frequency range 1.8-3MHz) was used to gather sound speed (cs) and attenuation coefficient ( $\alpha$ ). A passive cavitation detector was used to investigate cavitation thresholds were investigated at peak negative pressures of 1.76-9.64MPa.

PVA (cs:1532-1590m/s,  $\alpha$ :0.08-0.37dB/cmMHz) and gellan gum (cs:1493-1503m/s,  $\alpha$ :0.19-0.37dB/cmMHz) hydrogels had higher acoustic parameters than those measured in agarose hydrogels (cs:1493-1500m/s,  $\alpha$ :0.03-0.22dB/cmMHz). Cavitation thresholds for all materials followed a sigmoidal trend in probability of occurrence as a function of negative acoustic pressure, with agarose showing the lowest (2.9-3.5MPa for 75% probability). While gellan gum showed cavitation later than the other gels (6.6-7.2MPa), the increase in cavitation was steeper (slope: 8.7 $\pm$ 2.9, Figure 1). Addition of scatterers caused cavitation at lower pressures, with the 75% probability cavitation threshold in PVA gels: 5.4-8.2MPa (no cellulose) lowering to 3.8-4.3MPa (+10% cellulose w/w), and to in gellan gum silicone dioxide gels: 3.4-4MPa).

The acoustic properties (attenuation and sound speed) of PVA hydrogels were close to those of published tissue data. Gellan gum and PVA gels show cavitation thresholds properties that appear more suitable than agarose gels for mimicking tissues for these applications.

This project has received funding from the European Union's Horizon 2020 research and innovation programme under the Marie Skłodowska-Curie grant agreement No. 813766.



**Figure 1:** percentages of exposures from broadband signal representing signals from bubble collapse for 10% PVA hydrogels, 3% agarose hydrogels and 4% gellan gum hydrogels as a function of peak negative pressure. The 0% (no cavitation) and 75% cavitation thresholds are indicated as horizontal lines, measurements in water are given as a reference. All data points correspond to mean values and standard deviations of at least three independent experiments. Sigmoidal fits (dashed lines) of the function  $f(x) = -c/(1+(x/b)^a)+c$  are shown with 95% confidence bands (shaded).

**Using magnetic microbubbles to probe colorectal cancer lymph nodes,** Georgia Adam<sup>1</sup>, M Bacou<sup>2</sup>, S Sjöstrand<sup>1</sup>, Adrian Thomson<sup>3</sup>, Tomas Jansson<sup>4,5</sup>, Susan Farrington<sup>2</sup>, Susan Moug<sup>6</sup>, Carmel Moran<sup>3</sup>, Helen Mulvana<sup>1</sup>, <sup>1</sup>Department of Biomedical Engineering, University of Strathclyde, <sup>2</sup>Cancer Research UK Edinburgh Centre, Institute of Genetics and Cancer, University of Edinburgh, <sup>3</sup>Centre for Cardiovascular Science, University of Edinburgh, <sup>4</sup>Department of Clinical Sciences Lund, Biomedical Engineering, Lund University, Sweden; <sup>5</sup>Clinical Engineering Skåne, Digitalising IT/MT, Skåne Regional Council, Sweden; <sup>6</sup>Department of Surgery, Royal Alexandra Hospital

The localisation and characterisation of lymph nodes in colorectal cancer (CRC) is integral to cancer staging, treatment planning, resection surgery and therefore patient outcomes. However, appropriate imaging technologies capable of providing detailed information to the oncologist or surgeon to inform these processes remain severely limited.

To help address this diagnostic challenge, we are investigating the use of magnetic microbubbles, to be employed in both contrast enhanced ultrasound (CEUS) imaging and magneto-motive ultrasound (MMUS) imaging. Our aim is to combine the benefits of two ultrasound contrast agents to deliver contrast-enhanced magneto-motive ultrasound imaging; microbubbles will enable standard perfusion imaging; magnetic nanoparticles that accumulate in the lymph node allow local tissue structures to be displaced with an externally applied magnetic field. The resulting tissue displacement can be recovered with high-resolution ultrasound imaging supporting lymph node delineation and the possibility to interrogate tissue stiffness.

Contrast enhanced ultrasound imaging was performed (18MHz, Vevo 3100, Fujifilm VisualSonics) in a wild type mouse to assess lymphatic drainage of magnetic microbubbles after bolus injection, with peak enhancement occurring at 3.7s. Preliminary MMUS data were acquired as proof of concept and used to inform a finite-element model to assess magneto-mechanical interactions of a magnetic microbubble with an elastic solid.<sup>1</sup> The tissue displacement that could be generated and recovered via MMUS in our pre-clinical CRC model using magnetic microbubbles was investigated. Separately to this, CEUS was investigated as a method to recover lymph node information capable of indicating metastatic involvement, in the absence of deformation imaging.<sup>2</sup>

We will present an overview of our progress seeking to demonstrate the utility of multi-modal contrast agents to (1) determine lymph node metastatic involvement in a pre-clinical model of colorectal cancer, and (2) to probe lymph node stiffness as a potential indicator of disease involvement



**Figure 1.** (a) An example magneto-motive ultrasound image showing tissue displacement with sub-micron amplitude range as overlay on a B-mode image when magnetic nanoparticles are used alone, and (b) the root mean square tissue displacement recorded in the left (magnetic nanoparticle injected) inguinal lymph node and right (control) inguinal lymph node of our colorectal cancer mouse model under varying magneto-motive conditions (20Hz): MMUS - magnetic nanoparticles alone, CE-MMUS – magnetic-microbubbles, CE-MMUS PM L – magnetic-microbubbles, tissue displacement recorded post mortem, CE-MMUS PM R – tissue displacement recorded in the (right) control hind limb post mortem.

## References

1. S Sjöstrand, K Kaczmarek, M Bacou, M Evertsson, I Svensson, S Farrington, S Moug, T Jansson, C Moran, H Mulvana, 'Modelling of magnetic microbubbles to evaluate contrast enhanced magneto-motive ultrasound in lymph nodes – a pre-clinical', *British Journal of Radiology* 95: 20211128, 2022 <https://doi.org/10.1259/bjr.20211128>
2. M. Bacou, V. Rajasekaran-Sutherland, K. Kaczmarek K, A. Thomson, S. Moug, T. Jansson, C. Moran\*, S. Farrington\*, H. Mulvana\*, (\*Joint last author) 'Development of ultrasound imaging techniques to identify and image sentinel lymph nodes in a preclinical cancer model', *Cancers*, 14(3): 561, 2022 <https://doi.org/10.3390/cancers14030561>

# DAY THREE

Thursday 8th December

## MSK

**Appropriateness of musculoskeletal soft tissue swelling ultrasound scans**, Rameesha Anwar, University Hospitals North Midlands

### Objectives

This audit's purpose was to assess the appropriateness of referrals from primary and secondary care for soft tissue lumps and bumps ultrasounds (US) that are being performed in a University Teaching Hospital imaging department and compare against the British Sarcoma Group (BSG) national guidelines. This is on the background of increasing referrals for ultrasound scans of soft tissue lumps with limited clinical information in the face of increasing workload in the imaging department.

### Methods

A retrospective study, analysing data for all US performed for soft tissue swelling – over a one-month period. We focused on all US undertaken in the imaging department for June 2019 (pre-COVID) allowing for a 24 month follow-up period. Indications and findings were recorded. The requests were assessed regarding appropriateness by comparing to NICE and BSG guidelines.

### Results

200 ultrasound scans were undertaken during the month period; 14 paediatric patients were excluded from the data. The majority of referrals were from primary care (92%). Of the 186 cases analysed, 102 cases (54%) did not contain any appropriate clinical information as per the guidelines and no descriptive features were mentioned. Of the 81 cases (44%) that did contain relevant clinical information, 14 cases (17%) mentioned clinical features that, according to the guidelines, did not require ultrasound imaging and hence were also inappropriate.

### Conclusion

This audit shows the significant proportion of inappropriate requests from primary care. There was a lack of relevant clinical information on requests for US soft tissue, making it difficult to ascertain which patients need to be offered a direct access US in the required two-week time frame. Considerations for improving the quality of referrals include presenting the audit within primary care teams to enhance referrer education and ratifying an US request system with a flowsheet proforma to ameliorate the referral process.

## Professional Issues

**Patient experience of imaging reports – A systematic literature review**, Charlie Rogers<sup>1</sup>, Jane Chudleigh<sup>2</sup>, Sophie Willis<sup>3</sup>, Steven Gillard<sup>4</sup>, <sup>1</sup>University Hospitals Dorset, <sup>2</sup>Cicely Saunders Institute of Palliative Care, Kings College London, <sup>3</sup>Health Education England, <sup>4</sup>School of Health and Psychological Sciences City, University of London

### Background

Written reports are often the sole form of communication from diagnostic imaging. These reports are increasingly being accessed by patients as a part of their electronic record. Experiencing medical terminology can be confusing and lead to miscommunication, a decrease in involvement and increased anxiety. To better understand how patients experience imaging reports, a systematic review of the literature was undertaken.

### Objectives

To: (i) Understand patients' experiences of imaging reports. (ii) Determine key areas of importance when communicating imaging findings to patients. (iii) Use this information to inform further research and influence service delivery.

## Methods

This systematic review was designed to include predefined study selection criteria and was registered prospectively on PROSPERO (CRD42020221734). MEDLINE, CINAHL, Academic Search Complete (EBSCOhost), EMBASE, Scopus, and ETHOS were searched to identify articles meeting the inclusion criteria. All studies were assessed against the Mixed Methods Appraisal Tool (MMAT) version 2018 for quality. A segregated approach was used to synthesize the data. This method included a thematic synthesis of the qualitative data and a narrative review of the quantitative data. The findings of both syntheses were then integrated.

## Results

Twelve articles reporting 13 studies were included. This review found that patients' experiences of imaging reports were related with both positive and negative aspects. The study identified two main themes which encompass both qualitative and quantitative findings. These themes reveal that patients reported their experiences regarding their i) understanding of reports and regarding ii) self-management.

## Discussion

Patient understanding of imaging reports is multi-factorial including imaging modality, medical terminology, communication aids and errors. Self-management through direct access is important to patients. Whilst receiving bad news is a concern, responsibility for accessing this is accepted. A patient-centred approach to writing imaging reports may help to improve the quality of service, patient experience and wider health outcomes.

**Professional Supervision – How could this support the sonographer workforce?**, Gillian Coleman, Emma Hyde, University of Derby

## Objective

Increasing pressure is being felt by the sonographer workforce in the UK due to staff shortages and increasing clinical demands. With both the Society and College of Radiographers (SCoR) and the Health and Care Professions Council (HCPC) advocating the use of professional supervision to support the health and social care workforce, this review explores the evidence around the use of professional supervision and how this may be beneficial to support sonographers.

## Methods

A literature search was conducted to identify research exploring professional supervision in the Radiographer and Sonographer workforce. No papers were identified therefore search parameters were expanded to include allied health professionals. A literature review was conducted to explore the use of professional supervision in the allied health profession workforce.

## Results

Professional supervision can be beneficial in providing support for emotional wellbeing, which can contribute to reduced levels of burnout and increased job satisfaction. Alongside positive wellbeing aspects, professional supervision can contribute to improved quality of care, professional development and discussion of evidence-based care.

Whilst benefits are identified, there can be challenges to implementation of effective professional supervision including clinical pressures impacting on time available to conduct the professional supervision. This could impact the ability to implement it in the sonography workforce. Organisational pressures and the supervisory relationship can also have a negative impact.

## Conclusion

The literature demonstrates that there are clear benefits to professional supervision which could have a positive impact on the sonographer workforce however there can be significant challenges to implementation. Whilst there is clear identification of the benefits and the SCoR advocate the use of professional supervision, the guidance does not provide a clear structured framework. Further research is needed to explore the use of professional supervision in Sonography practice in the UK due to the unique nature of the role.



# Join BMUS NOW

## And Support Your Profession!

Did you know that it costs less than £1.85\* a week to be a member of BMUS and that you can pay quarterly for your subscription?

### Benefits of being a BMUS member

- Membership of a truly multi-disciplinary society fostering the exchange of information and ideas between its members.
- The quarterly 'Ultrasound' journal - the official journal of the British Medical Ultrasound Society - Ultrasound covers all aspects of medical ultrasound, from the theoretical through to clinical applications and their impact on both workforce and patients. The journal fulfils both an educational and a scientific research role and publishes a mixture of invited review articles, current research and descriptions of new techniques and equipment.
- Access to over 70 Webinar recordings in the BMUS Webinar Library
- Free online access to the full back catalogue of the 'Ultrasound' journal and 'BMUS Bulletin'.
- Ultrapost, the society's weekly e-newsletter.
- Opportunity to gain 'continuing professional development' opportunities via our online CPD portal.
- Access to the diagnosis for 'Interesting Cases' published on the BMUS webpages.
- Reduced registration fees at the BMUS Annual Scientific Meeting and the special topic meetings run by the society.
- As a member of BMUS you will also be a member of EFSUMB and WFUMB, and can enjoy the benefits of both societies including reduced registration fees at meetings organised by WFUMB and EFSUMB.
- Discounts on BMUS publications and Ultrasound in Medicine and Biology, the official journal of WFUMB.
- Eligibility to apply to become a member of BMUS Council or a member of one of the Society's Committees.
- Eligibility to apply for the society's scholarships and to influence the Society's affairs by voting at the AGM





FRUIT & VEG

The Salad Togen

THE WOOLPACK

WEST LONDON FLOWERS







# MAKE 2023 A QUALITY YEAR



ULTRASOUND  
QA SPECIALISTS

Improve patient safety through implementing  
an Ultrasound Quality Assurance Programme

“Ultrasound QA has never been easier to do.”

Ask our friendly staff for more information  
on “QA Everyday” – the beginning of  
your route to compliance.



Join us for **FREE training sessions** on **Stand 14** and  
receive a **QA Probe Test Tool**

Come and see us at **Stand 14**

+44 (0)333 011 0550 | [QA@multi-medix.com](mailto:QA@multi-medix.com) | [multi-medix.com](http://multi-medix.com)

# MEMBER BENEFIT

BMUS WEBINAR LIBRARY  
OVER 70 EDUCATION LECTURES

Paediatric Testicular  
Ultrasound

Giant  
Cell  
Arteritis

Bosniak and beyond:  
Renal cyst classification

Advanced Ultrasound  
in Hand Trauma

The Groin - Pain and Pathology

RSI and WRULD in  
Sonographers

Cross-sectional Imaging Correlation for Sonographers

A Gynaecologist  
Tale

Imaging of Salivary  
Glands Ultrasound  
and Beyond

RIF Pain is it  
appendicitis

Point-of-Care  
Ultrasound Imaging of  
the Heart and IVC

Placenta  
Accreta  
Spectrum

Unexpected Findings in  
Pregnancy; How to Manage the  
Patient AND Yourself

Scan the QR  
code to visit  
the BMUS  
Webinar  
Library



Sonographer  
Wellbeing  
and support

CT or Ultrasound in  
Patients with macro and  
microscopic Haematuria

Disentangling the Cardiac Outflow Tracts  
and Beyond Obstetric Ultrasound

The Diagnosis of Endometriosis  
The-Transition-to-Expert

The Hip Joint in Children – Neonate to Teenager

Common Diffuse  
Conditions of the Liver

Bowel Ultrasound

To FNA or not to FNA?

Scan the QR code  
to become a  
BMUS Member



The Ever-Changing  
Face Of The  
Sonographer

Sarcoma cannot  
be Excluded

Everything you  
need to know  
about the  
Endometrium

Urgent Assessment  
of Patients  
Presenting with  
TIA

Advanced  
Practice

How to manage the incidental non-  
palpable testicular mass

Physics and Safety in Ultrasound





# BMUS 2023

