

Professional Guidance for Fetal Growth Scans Performed After 23 weeks of Gestation

BMUS 

BMUS 3rd Trimester Special Interest Group

January 2022

British Medical Ultrasound Society 3rd Trimester Special Interest Group

Membership

Umber Agarwal	Consultant in Maternal & Fetal Medicine, Liverpool Womens Hospital
Trish Chudleigh	Research Sonographer, Department of Obstetrics & Gynaecology, The Rosie Hospital, Cambridge Biomedical Campus
Anne Marie Coady	Consultant Radiologist, Hull University Hospitals NHS Trust
Alexandra Drought	Consultant Sonographer, Obstetrics & Gynaecology Ultrasound, West Middlesex University Hospital (Chelsea & Westminster NHS Foundation Trust)
Nick Dudley	Principal Physicist, United Lincolnshire Hospitals NHS Trust
Gill Harrison	Professional Officer for Ultrasound. Society of Radiographers
Christoph Lees	Professor of Obstetrics, Imperial College London
Rita Phillips	Joint Programme Lead MSc Medical Ultrasound, School of Health & Social Wellbeing, University of the West of England
Emily Skelton	Research Sonographer, Kings College London

With special thanks to Emma Tucker, Development Manager, and colleagues at the BMUS office for their support in the preparation of this document

January 2022

CONTENTS	Page
1. Introduction	4
2. Summary including good practice points	6
3. Assessment of fetal size and growth	8
3.1 Appointment length and interval	8
3.2 Fetal biometry & estimated fetal weight	8
3.3 Reference charts	9
3.4 Sections required for measurement	10
3.5 Estimation of fetal weight	12
3.6 Reporting of HC, AC, FL measurements & EFW	13
3.7 Fetal anatomical assessment	16
4. Amniotic fluid assessment	18
4.1 Assessment by DVP	18
4.2 Assessment by AFI	20
5. Placental site	21
5.1 Definitions	21
5.2 Assessment	21
5.3 Reporting	22
6. Doppler assessment	23
6.1 Uterine artery Doppler	23
6.2 Umbilical artery Doppler	24
6.3 Middle cerebral artery Doppler	25
6.4 Umbilical artery and middle cerebral artery ratios	29
7. The Growth Scan Audit Tool	30
8. References	34
9. Appendices	37
1 Recommended reference datasets	37
2 Equations for recommended reference datasets	38
3 Reference charts	39
4 Rationale for using diameters in the calculation of HC & AC	50
5 Growth Scan Audit Tool templates	51
6 Guidance on Doppler examinations	54

1 INTRODUCTION

Since 2010 all pregnant women in England have been offered two ultrasound examinations during their pregnancies, namely a 1st trimester dating scan combined with Trisomy screening and a 20-week screening scan, the completion of which is required by 23⁺⁰ weeks of gestation. The policy, requirements, standards and governance of these two screening programmes are provided by the Fetal Anomaly Screening Programme (FASP)¹. Although guidance on aspects of the ultrasound assessment of fetal growth and size is provided via published literature and various national and international bodies^{2,3}, there are no national recommendations for how best to use ultrasound in the assessment of pregnancies over 23 weeks of gestation.

The BMUS 3rd Trimester Special Interest Group was therefore set up in 2020 to provide guidance on ultrasound examinations undertaken after the mid trimester routine anomaly scan. In this document these examinations will be described as 'growth' scans.

This document addresses:

- a) fetal biometry measurements of head circumference (HC), biparietal diameter (BPD), abdominal circumference (AC), femur length (FL) and estimation of fetal weight (EFW)
- b) fetal anatomical assessment
- c) amniotic fluid assessment
- d) placental site assessment
- e) Doppler assessment of the uterine arteries (UtA), umbilical artery (UA) and middle cerebral artery (MCA)
- f) image review

and provides guidance on:

- the reference literature for the measurements and/or assessments
- how the measurements and/or assessments should be performed
- how they should be reported
- how the quality of the obstetric ultrasound growth scan service should be audited and maintained.

Whilst it is acknowledged that not every growth scan will include all the measurements and assessments described below, we have included what we consider to be the appropriate range of fetal biometry, fetal anatomical assessment, amniotic fluid assessment, placental site assessment and Doppler investigations which can be performed during 'routine' ultrasound examination in the late second and third trimesters of pregnancy. The references for recommended charts, their related equations and the reference charts are shown in the Appendices.

A routine growth scan does **not** currently include assessment of:

- the fetal anatomy other than that included whilst seeking or assessing the sections required for measurement
- umbilical or middle cerebral artery Doppler unless indicated by local guidelines
- the ductus venosus Doppler assessment
- the cord insertion into the placenta
- the lower uterus for exclusion of vasa praevia and/or marginal cord insertion.

It is acknowledged that extending the content of a routine growth scan to include some or all of the above is an advance on the current situation that departments may wish to consider.

This document provides practical guidance that relates principally to the taking and interpretation of ultrasound measurements in singleton pregnancies. The principles presented are equally valid in the assessment of twin pregnancies. The document assumes that the reader already has sufficient ultrasound skills to perform growth scans and therefore this document does not address the scanning techniques necessary to obtain the various ultrasound images required for fetal biometry. This practical guidance can be obtained from a number of sources²⁻⁶

As not all departments currently perform UtA and/or MCA Doppler examinations, practical advice as how best to perform these examinations, and examination of the UA, is included in the Appendices.

This document does not provide guidance as to how the measurements and visual assessments described should be managed clinically in either singleton or twin pregnancies. The reader is referred to local and/or national guidelines for appropriate guidance and current management^{7,8}.

A clinically effective obstetric ultrasound growth scan service should include robust quality assurance (QA) of the images taken, their measurement(s) and/or interpretation and the report generated from the examination. We have therefore included recommendations for departmental QA in the form of the Growth Scan Audit Tool.

2 SUMMARY INCLUDING GOOD PRACTICE POINTS

1. In order to fulfil this document's recommendations, growth scan appointments should be 30 minutes in length for singleton pregnancies and 45 minutes in length for twin pregnancies.
2. Three separate images should be obtained, measured and stored for each measurement and waveform taken.
3. The two diameters method should be used to estimate the HC and AC in preference to the ellipse method.
4. The reported measurement should be obtained from the correct caliper placement on the image which best demonstrates the required criteria for the section.
5. The HC, AC and FL should be measured, plotted on their appropriate Chitty size charts and reported at every growth scan, irrespective of whether or not customised EFW charts are also used.
6. The EFW should be calculated, plotted and reported at every growth scan. The Hadlock criteria for estimating fetal weight and the Hadlock EFW chart should be used.
7. The anatomy demonstrated in all the sections obtained whilst undertaking fetal biometry should be assessed, thus providing a limited anatomical assessment at each growth scan. The extent of the anatomical assessment and the abnormalities potentially excluded by this process should be determined and, if adopted, included in the local departmental guidelines.
8. The amniotic fluid should be assessed at each growth scan and the deepest vertical pool (DVP) measured and reported.
9. Where the DVP measurement approaches the limits of, or is outside, the normal range, the amniotic fluid index (AFI) should also be calculated and reported.
10. The position of the leading edge of the placenta relative to the internal os should be assessed and reported at every growth scan.
11. Where the appearances on transabdominal imaging indicate a low-lying placenta or placenta praevia, the distance between the leading edge of the placenta and the internal os should be reported after transvaginal assessment and measurement.

12. The pulsatility index (PI) from the left and the right uterine arteries should be measured and the mean PI reported.
13. Undue pressure of the probe on the fetal head can affect the accuracy of MCA measurements. It is preferable not to measure or report the MCA when the position of the fetal head requires such pressure for Doppler sampling. This is because the inaccurate value obtained may contribute to inappropriate clinical decisions being made.
14. Angle correction should be applied when MCA peak systolic velocity (PSV) measurements are made unless the angle of insonation is close to zero. The degree of angle correction applied should be included in the report.
15. Pre agreed time should be allocated, on a regular basis, within the departmental service provision, for the structured audit of images from each member of staff who performs routine growth scans to be undertaken. Feedback to each member of staff is an essential part of the audit process. Image audit should be conducted on a 3-monthly basis for each member of staff.
16. Pre agreed time should be allocated, on a regular basis, within the departmental service provision for the summarised findings from each staff member's image audit to be discussed with the ultrasound team in order that quality benchmarks for the team may be agreed, reviewed and refined over time. These team discussions should be conducted on a 3-monthly basis.

3 ASSESSMENT OF FETAL SIZE AND GROWTH

3.1 Appointment length and interval

We recommend that the length of appointments for all growth scans should be 30 minutes for singleton pregnancies and 45 minutes for twin pregnancies.

The time interval between growth scans will vary depending on the growth velocity of individual fetal parameters measured and the resulting estimated fetal weight. We recommend that measurements should normally be three or more weeks apart to minimise false positive rates for fetal growth restriction but appreciate that more frequent measurements may be indicated in certain clinical situations^{3,7}.

3.2 Fetal biometry & estimated fetal weight

Fetal size and growth should be assessed at each examination, using the transabdominal route, by measurement of the following:

- head circumference (HC)
- abdominal circumference (AC)
- femur length (FL)

Three separate images should be obtained, measured and stored for each of the above.

The reported HC, AC or FL measurement should be obtained from the correct caliper placement on the image which best demonstrates the required criteria for the section.

- Estimated fetal weight (EFW)

We recommend that EFW should normally be calculated using HC, AC and FL and is discussed in section 3.5.

The FASP does not recommend the use of the biparietal diameter (BPD) either for dating or in the assessment of fetal size and growth at the time of the 20-week screening scan¹. This is because the BPD measurement is influenced by fetal position and head shape in the later 2nd and 3rd trimesters whilst that of the HC is not.

We recognise that some units may wish to incorporate BPD measurement into calculation of EFW. The BPD is therefore included here for completeness.

The recommended reference datasets for HC, BPD, AC, FL and EFW are shown in Appendix 1. The correct equations relating to these datasets are shown in Appendix 2. The recommended reference charts are shown in Appendix 3.

3.2.1 Customised EFW charts

We acknowledge that many departments use customised fetal weight charts. The majority of these departments evaluate only the absolute EFW value and/or the change in the EFW over time, rather than the fetal biometry measurements from which the EFW has been calculated.

The same EFW value can be derived from a large variety of different combinations of HC, AC and FL. Some of these combinations are of important clinical significance but the potential to identify such size and/or growth patterns is lost if the ultrasound interpretation of the scan findings relies on the EFW alone. In addition, and as importantly from the viewpoint of the individual operator's long-term skills, the expertise and experience in recognising and distinguishing between various abnormal growth and/or size patterns is removed when the departmental requirement is to obtain, plot and report the EFW only.

We therefore recommend that, in addition to the EFW, the HC, AC and FL measurements used to generate the EFW are plotted at every growth scan. This is in order that the absolute size of each of the three measurements, together with its growth rate since the 20-week screening scan and/or subsequent growth scans, can be evaluated and reported.

3.3 Reference charts

In accordance with the current recommendations from the FASP the Chitty et al. reference charts for fetal size should be used⁹⁻¹¹. The currently recommended Chitty size charts are shown in Appendix 3.

The HC and AC equations describe the circumference measurements obtained using two orthogonal diameters rather than fitting an ellipse. The rationale for this recommendation is provided in Appendix 4.

Head circumference

We recommend that the HC should be calculated by measuring:

- the 'outer to outer' biparietal diameter (BPD) and
- the occipitofrontal diameter (OFD)

Abdominal circumference

We recommend that the AC should be calculated by measuring:

- the anteroposterior diameter (APAD) of the abdomen and
- the transverse abdominal diameter (TAD)

3.4 Sections required for measurement

The section required for each of the four measurements should be obtained as described by the authors, Chitty et al. They based their criteria for HC and BPD on the transventricular plane described by Campbell & Thoms (1977)¹², for AC on those described by Campbell & Wilkin (1975)¹³ and for FL as described by themselves (1994)¹¹. The interpretation of the classic landmarks for HC, AC and FL was reiterated by BMUS in 2009 by Loughna et al¹⁴.

3.4.1 Head circumference

The criteria required for the correct transventricular section for measurement of the HC are shown below.

<i>Criteria required for the transventricular section of the fetal head</i>	
i)	Magnification such that HC occupies 60% or more of ultrasound image
ii)	Rugby football shape
iii)	Midline less than 20° to the horizontal
iv)	Midline centrally placed
v)	Presence of cavum septum pellucidum (CSP)*
vi)	Medial walls of the anterior and posterior horns of the lateral ventricles centrally placed around the midline

* Where difficulty is experienced in imaging the CSP, it is important that its normal appearance on the saved HC and TCD images from the 20-week screening scan is confirmed.

3.4.1.1 Caliper placement for HC

The HC should be derived using the two diameters method of measuring the BPD and the OFD, and not the fitted ellipse method.

The BPD and OFD should be measured using the 'outer to outer' method of caliper placement as below.

<i>Caliper placement required for measurement of the HC</i>	
BPD	Linear caliper placed across the widest diameter of the HC section
	At 90° to the midline
	Intersection of the cross of the calipers placed on the outer border of the upper and of the lower parietal bones respectively
OFD	Linear caliper placed along the midline echo
	Intersection of the cross of one caliper placed on the outer border of the frontal bone and of the other caliper on the outer border of the occipital bone

3.4.1.2. Caliper placement for BPD

Measurement of the BPD is not recommended for assessment of fetal growth owing to its variance with fetal position. Where it is being included in the estimation of fetal weight the 'outer to outer' measurement should be used, as described in 3.4.1.1.

3.4.2 Abdominal circumference

The criteria required for the correct section for measurement of the AC are shown below.

<i>Criteria required for the abdominal circumference section</i>	
i)	Magnification such that AC occupies 60% or more of ultrasound image
ii)	As close as possible to circular in shape
iii)	The spine appears as three ossification centres
iv)	A single rib, of equal length, on both sides
v)	Short section of the umbilical vein, in the middle one third of the abdomen
vi)	Stomach present
vii)	No lung base(s) visible
viii)	No kidney(s) visible

3.4.2.1 Caliper placement for AC

The AC should be derived using the two diameters method of measuring the APAD and the TAD, and not the fitted ellipse method.

The APAD and TAD and should be measured using the 'outer to outer' method of caliper placement as below.

<i>AC caliper placement</i>	
APAD	Linear caliper placed across the widest diameter of the AC section from the skin covering behind the spine to the outer border of the abdominal wall opposite it, in line with the umbilical vein
	Intersection of the cross of the calipers placed on the outer border of the skin line behind the spine and the outer border of the anterior abdominal wall respectively
TAD	Linear caliper placed across the widest diameter of the AC section at 90° to the APAD
	Intersection of the cross of the calipers placed on the outer border of the skin line of the left abdominal wall and of the right abdominal wall respectively

Where the fetal position is such that the TAD lies in the vertical plane (i.e. fetal spine at ~3 o'clock or ~9 o'clock), particular care should be taken to ensure that the lower

caliper is placed correctly so that the thickness of the skin line of the upper and lower abdominal walls is similar. Inspection of the skin line will frequently show a difference in their relative thickness, with the lower skin line appearing significantly thicker than the upper. This is likely to be due to increased reverberation artefact posteriorly. Unless this artefactual difference is appreciated, and the lower caliper placed on the outer border of the skin line rather than this lower line, an over-measurement of the AC will result.

3.4.3 Femur length

The criteria required for the correct section for measurement of the FL are shown below.

<i>Criteria required for the FL section</i>
i) The full femoral diaphysis is seen, lying no more than 15° to the horizontal ²
ii) Care should be taken to ensure that the full length of the bone is visualised and that the view is not obscured by shadowing from adjacent bony parts

3.4.3.1 Caliper placement for FL

The FL should be measured using linear calipers with their placement as below.

<i>FL caliper placement</i>
i) Magnification such that FL occupies 60% or more of ultrasound screen
ii) Linear caliper placed along, and parallel to, the maximum length of the femoral diaphysis
iii) Intersection of each caliper cross placed at the end of the ossified diaphysis, excluding the distal femoral epiphysis if it is visible and any end plate irregularity/'femoral spur' at either end
iv) The curvature of the bone should be disregarded

3.5 Estimation of fetal weight (EFW)

Fetal weight can be estimated using a combination of BPD, HC, AC and FL¹⁵. We recommend the Hadlock formula which combines HC, AC and FL ('Hadlock 3') is used unless accurate measurement of the HC cannot be obtained due to fetal position. In this situation we recommend using the Hadlock formula which combines AC and FL ('Hadlock 2').

We do not recommend incorporating the BPD into the EFW calculation due to its dependence on fetal position. We appreciate some units may prefer to include the

BPD in estimating fetal weight and therefore include reference to the Hadlock formula which combines BPD, HC, AC and FL ('Hadlock 4'), for completeness.

It should be appreciated that there is likely to be a difference between EFW calculated using HC, AC and FL results and EFW calculated using AC and FL results only, depending on fetal proportions¹⁶. Thus, changing formula during growth monitoring can lead to an artefactual change in growth trajectory.

In cases where measurement of the HC is not possible at one or more scans, and the EFW has therefore been calculated using the AC and FL formula, the most accurate method of assessing change in EFW is to recalculate all the EFW values using the AC and FL formula and then plot all the recalculated values on the Hadlock EFW chart. This will avoid potential inaccuracies of EFW, and a possible misdiagnosis of fetal growth restriction due to the artefactual change(s) in EFW trajectory when the EFW has been calculated from two different datasets¹⁶. We recognise that translating this ideal into clinical practice may be considered unrealistic in terms of time management, and therefore not practical, in the majority of situations. It is important however that the principle outlined above is understood, and the resulting potential source of error acknowledged when interpreting the resulting fetal growth trajectory.

3.6 Reporting of HC, AC, FL measurements and EFW

3.6.1 Deciding on the correct criteria

The principal aim of taking fetal measurements and calculating fetal weight is to determine whether fetal size, growth and weight respectively are within their acceptable limits. There are currently no internationally agreed criteria as to what constitutes such limits, nor what defines 'normal' growth, 'normal' weight increase, suboptimal fetal growth (SFG), small for gestational age (SGA), fetal growth restriction (FGR), accelerated fetal growth, or large for gestational age. In addition, there is no agreed guidance on the time intervals across which sequential criteria should be assessed.

The majority of the literature relates to identifying the small and/or poorly grown fetus rather than the large and/or macrosomic fetus. The former literature provides various definitions of SFG, SGA, and FGR, with the Delphi consensus being widely adopted for the defining of, and distinguishing between, SGA and FGR¹⁷. Examples of such definitions relating to AC and EFW are shown below^{8,17,18}.

AC criteria	Definition
AC less than 3 rd percentile	FGR ¹⁷
AC above 5 th percentile but dropping by 30 percentiles or more	SFG ¹⁸
AC on or below 5 th percentile & smaller than HC by 30 percentiles or more	SFG ¹⁸

AC less than 10 th percentile with umbilical artery PI above 95 th percentile before 32 weeks (early FGR)	FGR ¹⁷
AC less than 10 th percentile with AC crossing more than 50 percentiles at or after 32 weeks (late FGR)	FGR ¹⁷
Change in AC of less than 5mm over 14 days	SFG ¹⁸
EFW criteria	
EFW less than 3 rd percentile	FGR ¹⁷
EFW less than 10 th percentile on customised chart	SFG ¹⁸
EFW dropping by 30 percentiles on customised chart	SFG ¹⁸
EFW less than 10 th percentile with umbilical artery PI above 95 th percentile	FGR ¹⁷
EFW less than 10 th percentile with EFW crossing more than 50 percentiles at or after 32 weeks (late FGR)	FGR ¹⁷
Increase in EFW of less than 280g over 14 days from 34 weeks	SFG ⁸

Independent of the EFW chart used, the Delphi consensus uses the following definitions¹⁷.

SGA

- i) AC or EFW less than the 10th percentile but above the 3rd percentile, and with normal umbilical artery Doppler

FGR:

- i) AC or EFW less than 3rd percentile, irrespective of umbilical and/or middle cerebral artery Doppler findings
- or**
- ii) AC or EFW less than the 10th percentile and with abnormal umbilical and/or middle cerebral artery Doppler

The fall in EFW percentiles may play a part in the diagnosis of FGR depending on local protocols, with the commonly accepted definition being a fall of 50 percentiles - which is the same as two quartiles^{17,18}

As there is a lack of good quality evidence on how best to interpret fetal growth, individual units may wish to adopt specific management algorithms based on the above Delphi consensus definitions for SGA and/or FGR, and their own protocols.

3.6.2 Fetal biometry

Fetal biometry measurements should be numerically reported in millimetres corrected to the first decimal point (e.g. 290.3mm or 290.7mm). They should not be rounded up to the nearest millimetre (e.g. 290mm or 291mm).

The HC, AC and FL should be plotted at every scan on their respective Chitty size reference charts. These are shown in Appendix 3.

The Chitty charts for HC, BPD, AC and FL are commonly displayed with ‘three lines’ corresponding to the 50th, 3rd and 97th percentiles rather than with the ‘five lines’ corresponding to the 50th, 3rd, 10th, 90th and 97th percentiles provided in the original datasets⁸⁻¹⁰.

It should be remembered that the 3rd and 10th percentiles and the 90th and 97th percentiles for the measurements of fetal size frequently provide important watersheds for clinical management of the small and/or growth restricted fetus and the large for gestational age fetus respectively. It should also be remembered, and as discussed in **3.6.1**, that the percentile used to identify a particular at-risk group may vary depending on national and/or local guidelines.

We recommend that individual departments consider, in the first instance, the size and growth of not only the AC but also of the HC and FL and, in addition, the contribution that each measurement makes to the resulting EFW. This is because different management strategies may be required depending on which of the three measurements is, or are, potentially concerning. Interpreting the clinical significance of the resulting EFW may also vary therefore, depending on the spectrum of the measurements obtained.

All plotted charts should form part of the report issued at each examination.

3.6.3 Estimated fetal weight

Estimated fetal weight should be numerically reported in grams.

The EFW should be plotted at every scan on the Hadlock EFW reference chart¹⁹. This is shown in Appendix 3.

The same Hadlock formula should, ideally, be used for all calculations plotted on the EFW chart (see section **3.5**).

The Hadlock chart for EFW is commonly displayed with the 3rd, 10th, 50th, 90th and 97th percentile ranges, and between 10 and 40 weeks of gestation. We question the benefit of plotting EFW values on this chart in the late first and early second trimesters and recommend that plotting of EFW for singleton pregnancies on this chart is not useful before 24 weeks of gestation.

It should be remembered that the 3rd, 10th and 90th percentiles for EFW frequently provide important watersheds for clinical management of the small and/or growth restricted fetus and the large for gestational age fetus respectively.

For example:

- less than 10th percentile commonly defines SGA^{17,18}

- <3rd percentile commonly defines FGR^{17,18}
- greater than 90th percentile commonly defines large for gestational age (LGA)

The percentile of the EFW should be reported.

The plotted EFW chart should form part of the report issued at each examination.

3.7 Fetal anatomical assessment

The detailed routine assessment of the fetal anatomy should be undertaken during the 20-week screening scan. Although the main purpose of growth scans is not to repeat this anatomical screening, these examinations do provide an opportunity to assess those parts of the fetal anatomy visualised during the obtaining of the HC, AC and FL measurements.

Confirmation of the normal appearance, size and/or position of the structures present in the required sections for fetal biometry therefore has the potential to exclude a limited number of fetal abnormalities, in addition to those associated with abnormal size of one or more of the biometry measurements. Furthermore, adopting the technique of obtaining the correct section for measurement of the FL by sliding in the transverse plane from the AC section down the fetal body to the fetal pelvis to locate the femur, will allow assessment of the fetal anatomy of the lower fetal abdomen and pelvis to be made.

Where ultrasound departments incorporate this guidance into their protocols, we recommend that growth scans should include the limited anatomical assessment provided by using the techniques described above to perform the required fetal biometry.

The limited fetal anatomical examination, together with the recommended structures to assess and conditions that can therefore be excluded during the growth scan are shown below.

Section/measurement	Structure (<i>normal appearance of</i>)	Condition commonly considered to be low likelihood based on normal appearance
Head circumference (HC)	cavum septum pellucidum (as opposed to the columns of the fornix)	agenesis of the corpus callosum
	anterior & posterior horns of lateral ventricle	moderate/severe ventriculomegaly
	3 rd ventricle not visible	moderate/severe ventriculomegaly

Abdominal circumference (AC)	stomach	<ul style="list-style-type: none"> • left sided diaphragmatic hernia* • duodenal atresia • oesophageal atresia
Sliding through lower abdomen & pelvis to locate femur	left and right kidney & renal pelvis**	<ul style="list-style-type: none"> • moderate/severe renal pelvic dilatation • unilateral/bilateral renal cystic dysplasia (multicystic kidney) • infantile polycystic kidney disease
	bladder	low moderate/severe urinary tract obstruction

*It should be noted that the ultrasound appearances of left sided diaphragmatic hernia are not necessarily constant across gestation.

**Visualising both kidneys adequately will be dependent on fetal lie and, unless the fetal spine is directly anterior or posterior, it is likely that only the kidney and pelvis nearer the probe will be adequately visualised while sliding through the lower abdomen and pelvis to measure the FL.

Unexpected appearances in the sections obtained for measurement and/or unexpected appearances noted in the additional assessment of the fetal anatomy should be recognised, imaged and referred for more detailed ultrasound examination, according to local guidelines.

Individual units may wish to incorporate assessment of other parts of the fetal anatomy, such as the heart, into the growth scan. If this assessment is to be included, it should be remembered that the range of its expected appearances does not remain constant across gestation.

4 AMNIOTIC FLUID ASSESSMENT

Amniotic fluid volume is usually quantitatively assessed in singleton pregnancies using either measurement of the largest vertical pocket or of the amniotic fluid index (AFI). The largest vertical pocket is described interchangeably as the deepest vertical pocket or pool (DVP) or the maximum vertical pocket (MVP).

It is accepted practice that only DVP should be used in amniotic fluid assessment in twin pregnancies²⁰.

There is no evidence that either the DVP method or the AFI is superior to the other in its association with adverse perinatal outcomes in singleton pregnancies⁷. Compared to AFI, measurement of the DVP may result in fewer interventions without increasing the rate of adverse perinatal outcome^{21,22}.

We recommend that quantitative surveillance of amniotic fluid in both singleton and twin pregnancies should be made initially by measurement of the DVP. Where the DVP measurement is approaching, or is outside, the upper or lower limit of the normal range, we recommend measurement of AFI to assess the amniotic fluid.

A commonly used reference dataset for DVP and for AFI respectively are shown in Appendix 1. The correct equations relating to these datasets are shown in Appendix 2. The reference charts are shown in Appendix 3.

4.1 Assessment by DVP

As the DVP assessment technique suggests, the uterus should be surveyed thoroughly to identify the deepest vertical pocket of amniotic fluid. No fetal parts or umbilical cord should be visible in the selected pocket. The reason for the latter is to avoid the mistake of interpreting loops of cord as a pool of amniotic fluid. This is usually more problematic when the fluid volume is reduced. It is helpful to use colour Doppler to distinguish between a pool of fluid which will produce no colour signals, and one or more loops of cord which will produce colour signals, to ensure that the measurement taken is of the DVP.

Having located the deepest pocket of fluid, it is important to ensure that its vertical measurement is taken. Traditional teaching requires the calipers to be placed at 90° to the floor, rather than to the axis of the uterus. It is noted that more recent literature states that there is no statistically significant difference between the two methods²³. Care must be taken to ensure that the upper caliper is placed at the anterior uterine wall and not at the posterior border of any reverberation artefact. This artefact is frequently visible within the amniotic fluid directly below the anterior uterine wall, except where the placenta is anterior.

The measurement can be taken from a longitudinal or transverse section of the uterus as the depth of the pocket should be the same irrespective of which vertical section of the pocket is measured.

Three separate measurements of the DVP should be taken, evaluated and stored. The DVP measurement that should be reported is that obtained from the correct measurement of the image which best demonstrates the required criteria for the DVP.

4.1.1 Reference range for DVP

There is international acceptance that normal amniotic fluid is described by a DVP of 2.0cm to 8.0cm.

There are a number of reference ranges for DVP. The Magann reference range for DVP is commonly used²⁴. It is provided as an example in Appendix 3.

It will be noted that the 5th percentile of the Magann chart is defined by a DVP that varies from 3.0cm at 24 weeks to 1.8cm at 41 weeks. Similarly, the 95th percentile is defined by a DVP that varies between 6.8cm at 24 weeks and 7.2cm at 34 weeks.

A DVP of 2.8cm, for example, will therefore fall below the 5th percentile of the Magann reference range between 24 and 32 weeks of gestation. Similarly, a DVP of 7.3cm will fall above the 95th percentile from 24 weeks to 41 weeks of gestation.

The plotting of DVP values on the reference chart may lead to confusion as measurements such as the examples given above will lie outside the accepted normal range of 2.0cm to 8.0cm. They will therefore, quite reasonably, be interpreted as abnormal and thus suggestive of oligohydramnios or polyhydramnios respectively. This in turn may contribute to inappropriate clinical decisions being made.

We therefore recommend that DVP measurements are interpreted using the numerical cut-offs of 2.0cm and 8.0cm across the gestational age range from 24 weeks to 41 weeks.

4.1.2 Reporting of amniotic fluid DVP

The amniotic fluid DVP should be numerically reported only, in centimetres, to one decimal place. We recommend that it is not plotted on the reference chart.

The report should include reference to whether the measurement is within or outside the normal range.

A DVP measurement between 2.0cm and 8.0cm indicates *normal* amniotic fluid.

Abnormal findings are:

- DVP measurement of less than 2.0cm indicates *oligohydramnios*.

- DVP measurement of greater than 8.0cm indicates *polyhydramnios*.

The measured DVP and its interpretation should form part of the growth report issued at each examination.

4.2 Assessment by AFI

The AFI assessment technique requires the uterus to be divided into four quadrants using the umbilicus as the centre point from which the four quadrants are derived. The deepest vertical pocket in each of the four quadrants is measured, as described in section 4.1. The AFI is the sum of the four measurements²⁵.

Measurements for the AFI can be taken from longitudinal or transverse sections of the uterus as the depth of each of the four pockets should be the same irrespective of which vertical section of the pocket is measured.

Three separate measurements of the AFI should be taken, evaluated and stored. The AFI measurement that should be reported is that obtained from the correct set of four images which best demonstrate the required criteria for the AFI.

4.2.1 Reference range for AFI

Historically normal amniotic fluid was described by an AFI of between 10.0cm and 24.0cm. More recent publications describe the normal range as between 10.0cm and 25.0cm. We therefore recommend using 10.0cm to 25.0cm as the normal range between 20 and 42 weeks of gestation.

4.2.2 Reporting of AFI

The AFI value should be numerically reported only, in centimetres, to one decimal place. We do not recommend that it is plotted graphically for reasons similar to those discussed for DVP in section 4.1.1.

The report should include reference to whether the AFI value is normal or abnormal.

An AFI value between 10.0cm and 25.0cm indicates '*normal*' amniotic fluid.

Abnormal findings are:

- AFI measurement of less than 10.0cm indicates *oligohydramnios*.
- AFI measurement of greater than 25.0cm indicates *polyhydramnios*.

The AFI value and its interpretation should form part of the growth report issued at each examination in which it is calculated.

5 PLACENTAL SITE

5.1 Definitions

A placenta is reported as 'low lying' when the placental edge is less than 20.0mm from the internal os as imaged either transabdominally or transvaginally from 16 weeks of gestation. The term 'placenta praevia' should only be used when the placenta lies directly over the internal os. Where a placenta is found to be low lying or praevia at the 20-week screening scan, a follow-up ultrasound should be recommended at 32 weeks to diagnose a persistent low lying or praevia placenta. Such cases in which the placenta is still low lying or praevia at 32 weeks should have further transvaginal imaging assessment at 36 weeks to determine whether or not the placental site indicates that delivery by elective Caesarean section should be considered²⁶.

Assessment of the placental site during the 20-week screening scan will have already determined whether or not further scans are required in later pregnancy to exclude a low lying placenta or a placenta praevia. According to local guidance, the risk of placenta accreta spectrum will also have been determined during the 20-week screening scan in those women who have had a previous Caesarean section and in whom the lower margin of the anterior placenta is within 20.0 mm of the internal os.

Low lying placenta has a recognised association with vasa praevia. At the current time, screening for vasa praevia is not recommended at the 20-week screening scan as the balance of benefit versus harm for its introduction remains undetermined²⁷. Individual departments, however, may wish to incorporate such assessment into their local guidelines.

Although it is reasonable to assume that the placental site as reported in earlier gestation is correct, this should always be reconfirmed during later scans irrespective of their primary purpose.

5.2 Assessment

Placental site is assessed by identifying the position of the leading edge of the placenta, the position of the internal os and evaluating the distance between the two. This assessment should be carried out transabdominally in the first instance. When scanning transabdominally, care should be taken to ensure that the fullness of the maternal bladder is sufficient to identify the required landmarks correctly, but that it is not so full as to produce a false impression of the distance between the landmarks.

We recommend that where transabdominal imaging indicates that the placental edge is 20.0mm or less from the internal os, a transvaginal scan should be performed in order that the distance between the leading edge and the internal os can be accurately measured and reported.

Three separate images of the relationship between the leading edge of the placenta and the internal os, including the measured distance where indicated, should be taken, evaluated and stored. The measurement that should be reported is that which best demonstrates these required landmarks and the correct measurement between them.

5.3 Reporting

We recommend the following:

- a placenta should be reported as '*upper*' or '*not low lying*' when its leading edge is more than 20.0mm from the internal os. It is appreciated that the descriptor used is likely to be governed by the software available. The definition of descriptors other than these described above should be included in the departmental guidelines. The route, namely transabdominal or transvaginal, used to make this assessment should be included in the report.
- where the leading edge of a placenta is less than 20.0mm from the internal os, but does not cover the os as assessed by transvaginal imaging, the distance, in millimetres, between the leading edge and the internal os should be included in the report. Such a placenta should be reported as '*low lying*'.
- where the leading edge of a placenta covers the internal os, as assessed by transvaginal imaging, the distance, in millimetres, by which the placental margin overlaps the internal os should be included in the report. Such a placenta should be reported as '*placenta praevia*'.

6 DOPPLER ASSESSMENT

It is the responsibility of the operator to ensure that any examination, including spectral (pulsed wave or PW) Doppler examination, is performed within safety guidelines²⁸.

General recommendations that are applicable to the Doppler assessment of the UtA, UA and MCA are given in Appendix 6.

6.1 Uterine artery Doppler

Doppler assessment of the uterine arteries is carried out transabdominally, ideally at 22-23 weeks of gestation although may, when used as a screening tool, be performed prior to this gestation. At the present time, UtA Doppler assessment is only offered to women at increased risk of fetal growth restriction as determined by criteria set locally and/or nationally^{7,8}. There are limited data to support the clinical benefit of routine UtA in the third trimester of pregnancy.

6.1.1 Assessment

Guidance relating to obtaining, displaying and measuring the UtA is given in Appendix 6.

Doppler assessment of both left and right uterine arteries should be performed.

Three separate spectral traces of both the left and right uterine arteries should be obtained, measured, evaluated and stored.

Diastolic notching is defined qualitatively as reduced early diastolic velocities before the maximum diastolic velocity⁵. We do not recommend incorporating diastolic notching into UtA assessment of pregnancies being managed within the routine service.

6.1.2 Reference chart

The Kaminopetros reference chart for mean UtA PI, should be used²⁹. The recommended reference dataset is shown in Appendix 1. The correct equation relating to this dataset is shown in Appendix 2. The reference chart is shown in Appendix 3.

6.1.3 Reporting of UtA

The UtA PI measurement reported for uterine arteries should be the mean value obtained from the correct maximum velocity envelope (MVE) measurement of the waveform which best demonstrates the required criteria for the left UtA and for the right UtA.

The UtA PI of both left and right uterine arteries should be numerically reported separately, to two decimal places.

The final Doppler value which is to be reported is the mean UtA PI. This should be calculated from the reported left and right UtA PIs. The mean PI should be plotted on the Kaminopetros mean UtA PI reference chart.

The plotted mean UtA PI chart should form part of the report issued with the examination

The report should include reference as to whether the mean UtA PI measurement is within or outside the normal range.

A mean UtA PI below the 95th percentile indicates a *normal* mean PI.

The abnormal finding of the UtA is:

- mean UtA PI *above* the 95th percentile

6.2 Umbilical artery Doppler

Guidance for obtaining, displaying and measuring the UA is given in Appendix 6.

A loop of cord freely floating within the amniotic fluid should be sought for assessment of the UA.

6.2.1 Assessment

Local practice will determine whether Doppler assessment of the UA should be performed during each examination for fetal growth, or only in those pregnancies at increased risk of fetal growth restriction.

Do not attempt to assess the UA when the fetus is actively moving or breathing as the resulting trace and its measurement will be inaccurate.

Doppler assessment of the UA should include:

- measurement of the UA PI
- evaluation of end diastolic flow (EDF).

Three separate spectral traces of the UA should be obtained, measured, evaluated and stored.

6.2.2 Reference chart

The Parra-Cordero reference chart for PI should be used³⁰. The recommended reference dataset is shown in Appendix 1. The correct equation relating to this dataset is shown in Appendix 2. The reference chart is shown in Appendix 3.

6.2.3 Reporting of UA

The UA PI measurement reported should be that obtained from the correct MVE measurement of the waveform which best demonstrates the required criteria for the UA.

The UA PI should be numerically reported to two decimal places and plotted on the Parra-Cordero UA PI reference chart.

The plotted UA PI chart should form part of the report issued with the examination

The report should include reference as to whether the measurement is within or outside the normal range.

The EDF should be reported as '*present*', '*absent*' or '*reversed*'. Where abnormal flow is intermittent, this should also be reported, as '*intermittent absent EDF*' or '*intermittent reversed EDF*'.

A UAPI below the 95th percentile indicates a *normal* UAPI.

Abnormal findings of the UA are:

- PI *above* the 95th percentile
- *absent* or *reversed EDF*

The findings in a two vessel cord should be interpreted with caution (see Appendix 6).

6.3 Middle cerebral artery Doppler

Two different measurements of the MCA can be taken, namely the PI and the peak systolic velocity (PSV) or maximum velocity (Vmax).

Guidance relating to obtaining, displaying and measuring the MCA PI and PSV is given in Appendix 6.

The MCA is best imaged from a transverse section of the fetal head at the level of the thalami, with the midline in the horizontal plane.

6.3.1 MCA PI

6.3.1.1 Assessment

Do not attempt to assess the MCA PI when the fetus is actively moving or breathing as the resulting trace and its measurement will be inaccurate.

It is advised not to apply undue pressure on the probe as doing so can cause a decrease, or a disappearance, in end diastolic velocities in the MCA. This will result in a falsely increased PI measurement and therefore a false negative result.

Three separate spectral traces of the MCA PI should be obtained, measured, evaluated and stored.

6.3.1.2 Reference chart

The Parra-Cordero reference chart for MCA PI should be used³⁰. The recommended reference dataset is shown in Appendix 1. The correct equation relating to this dataset is shown in Appendix 2. The reference chart is shown in Appendix 3.

6.3.1.3 Reporting of MCA PI

The MCA PI measurement reported should be that obtained from the correct MVE measurement of the waveform which best demonstrates the required criteria for the MCA. There is no requirement to apply angle correction when measuring the MCA PI.

The MCA PI should be numerically reported to two decimal places and plotted on the Parra-Cordero MCA PI reference chart.

The plotted MCA PI chart should form part of the report issued with the examination.

The report should include reference to whether the measurement is within or outside the normal range.

An MCA PI above the 5th percentile indicates a *normal* MCA PI.

The abnormal finding of the MCA PI is:

- MCA PI below the normal range (i.e. below the 5th percentile)

As stated above, note that undue pressure of the probe may result in a false negative result due to its effect of increasing the MCA PI.

6.3.2 MCA PSV

We acknowledge that measurement of the MCA PSV is not currently part of routine growth assessment in either singleton or twin pregnancies. It is included here as departments may wish to consider this if advanced imaging is undertaken.

The PSV is used in the evaluation of fetal anaemia in singleton or multiple pregnancies and in the evaluation of twin anaemia polycythaemia sequence (TAPS) in monochorionic diamniotic (MCDA) twin pregnancies^{20,31}.

6.3.2.1 Assessment

Do not attempt to assess the MCA PSV when the fetus is actively moving or breathing as the resulting trace and its measurement will be inaccurate.

Applying undue pressure on the probe can cause a decrease in end diastolic velocities but overall increased flow in the MCA. This will result in a falsely increased MCA PSV measurement and therefore a potentially false positive result in both the assessment of fetal anaemia and of TAPS.

Assessment of PSV uses multiples of the median rather than percentiles.

All measurements of PSV require manual angle correction of the Doppler beam in order to obtain the correct velocity in cm/s. The angle between the ultrasound beam and the direction of blood flow should be kept as close as possible to 0°. This can be easily achieved by moving probe across the maternal abdomen. The distal vessel may be chosen if obtaining an insonation angle of 0° is easier for the distal MCA than for the proximal MCA. Angle correction can be used in difficult circumstances. It is reasonable to use up to 30 degrees of angle correction if the MCA-PSV cannot be assessed at a 0° angle of insonation.

Three separate spectral traces of the MCA PSV should be obtained, measured, evaluated and stored. The MCA PSV measurement reported should be that obtained from the correct measurement of the waveform which best demonstrates the required criteria for the MCA.

6.3.2.2 Reference chart

The Mari reference chart for MCA PSV should be used³¹. The recommended reference dataset is shown in Appendix 1. The correct equation relating to this dataset is shown in Appendix 2. The reference chart is shown in Appendix 3.

6.3.2.3 Reporting of MCA PSV in assessment of fetal anaemia

The MCA should be insonated at an angle that is as close to zero degrees as possible. Where this is not possible, angle correction should be applied when estimating

velocity. This is because cosine Θ (the angle between the ultrasound beam and the direction of the target velocity) forms part of the velocity calculation.

Angle correction can be applied to the MCA vessel in real time or to the frozen image of the MCA vessel after the correct trace has been obtained. It must be carried out **before** the PSV measurement is made. Failure to angle correct may result in an erroneously lower MCA PSV being obtained.

The angle corrected MCA PSV should be numerically reported in cm/s, corrected to one decimal place and plotted on the Mari MCA PSV reference chart.

The plotted MCA PSV chart should form part of the report issued with the examination.

It is good practice to state in the report the degree of angle correction applied.

The report should include reference to whether the velocity is normal or abnormal. It will be noted that the normal range for MCA PSV is described by Multiples of the Median (MoMs) rather than percentiles.

A 'normal' measurement is therefore one which is 1.0MoM for gestation.

Abnormal findings are:

- MCA PSV greater than 1.5MoM, suggestive of *fetal anaemia*^{20,31}

6.3.2.4 Reporting of MCA PSV in assessment of MCDA twins for TAPS

Where the MCA PSV is being performed in a MCDA twin pregnancy for assessment of TAPS, the report should include reference to the MCA velocity for each twin, whether it is:

- normal in both twins, that is between 1.0MoM and 1.5MoM for both fetuses
- abnormal in one twin only, that is either above 1.5MoM or below 1.0MoM in one fetus only
- abnormal in both twins, that is above 1.5MoM in one fetus and below 1.0MoM in the other fetus, therefore suggestive of TAPS²⁰.

These combinations, and suggestions for their reporting, are shown below.

MCA PSV in MCDA twin pair	MCA PSV MoM			Suggested report of findings
	<1.0	1.0-1.5	>1.5	
Normal x 2		xx		PSV within normal limits for both fetuses, therefore no indication of TAPS
Normal x 1 Increased x 1		x	x	PSV within normal limits for fetus 1 but above 1.5MoM for fetus 2. Referral for discussion of further management arranged
Normal x 1 Decreased x 1	x	x		PSV within normal limits for fetus 1 but below 1.0 MoM for fetus 2. Referral for discussion of further management arranged
Increased x 1 Decreased x 1	x		x	Fetus 1 - PSV above 1.5MoM Fetus 2 - PSV below 1.0MoM. These findings are suggestive of TAPS. Referral for discussion of further management arranged

The MCA PSV for both fetuses, plotted on the same chart, should form part of the report issued at the examination.

6.4 UA and MCA ratios

In addition to measuring the PI in the UA and the MCA, the ratio of the two values can be calculated. This potentially provides a more sensitive indicator of fetal hypoxia than the two values individually.

The cerebroplacental ratio (CPR) is calculated by dividing the MCA PI by the UA PI.

The umbilicocerebral ratio (UCR) is calculated by dividing the UA PI by the MCA PI.

Both ratios can be used in the management of pregnancies at increased risk of FGR with the CPR currently being more commonly used than the UCR.

A number of reference charts have been published for both ratios but at the current time there is a lack of consensus as to which of the reference charts for either ratio is recommended. There is similarly a lack of consensus as to which ratio is preferable in the management of pre-eclampsia and/or FGR or indeed whether both may be clinically useful, but in different scenarios.

We therefore do not recommend the use of either ratio in the assessment of growth at the current time but rather recommend that the PI of both vessels is reported separately.

7 THE GROWTH SCAN AUDIT TOOL

7.1 Introduction

Accuracy and consistency of biometry and Doppler assessment is essential to provide effective monitoring of a fetus in the third trimester. In fetal growth studies, standardised anatomical landmarks are identified, calipers are placed at predefined points and fetal biometric measurements are plotted on graphs against expected values for gestational age. Auditing against a set of standardised criteria, using a specifically designed tool, can help to:

- improve the quality of sections and images
- develop consistency of measurements locally and nationally
- increase the accuracy of fetal growth velocity assessment
- improve fetal outcomes.

The Growth Scan Audit tools included within this document in Appendix 5 gives users reproducible mechanisms with which quality factors can be measured reliably and repeatedly. The tools are designed to be used by individuals to review their own and their peers' practice.

7.2 Timing and frequency of image audits

We recommend that all staff performing 3rd trimester growth scans and Doppler assessment, including agency and newly qualified staff, are involved in 3rd trimester audit. This includes the taking, selecting and auditing of one or more reported measurements or sets of measurements and the feeding back of the findings to the individual and the team.

In keeping with the BMUS Recommended Audit Tool we recommend that the service should aim, as soon as practically possible, for a review of 5% of all 3rd trimester growth scan images and 5% of all the various Doppler assessment images³⁰. We accept that this may be an ambitious target especially for departments which do not currently have audit programmes other than the 3-monthly audit of paired crown rump length and nuchal translucency images required for combined screening. However, it is important that the need to balance the number of scans reviewed against obtaining sufficient meaningful data to be able to identify trends, provide feedback and thereby improve service delivery is acknowledged.

There are benefits from both auditing a small number of sets of measurements, for example EFW measurements (i.e. HC, AC and FL) or Doppler measurements (i.e. UA, UtA and MCA) and from auditing a larger number of one measurement (i.e. AC or UtA).

We therefore recommend combining both audits as below.

3 monthly audit cycles

All staff participate in the following audit cycles of measurement, audit and feedback every 3 months:

- a minimum of 3 randomly selected sets of the reported HC, AC, FL and DVP images, together with their accompanying reported Doppler images
- a minimum of 3 randomly selected reported images of UA, UtA and MCA if not included in the above
- 25 images of one of the above measurements, on a rotational basis, with the recommendation that the AC is the first to be chosen.

It is appreciated that the time taken to collect, collate and feedback the data from the three audit cycles is likely to vary depending on both the numbers of staff participating and the types of measurements delivered within the service.

7.3 Resources

We recommend that pre-agreed time for regular, 3 monthly, audit of the growth scan service should be allocated within the department's overall service delivery plan.

Departments may wish to allocate time on a daily, weekly or monthly basis. Access to image and report storage facilities is required. Assistance from IT departments or PACS system managers may also be required to retrieve retrospective data of examinations performed³².

Individual services will need to agree who within the team will perform the image audits. It is recommended that the review is carried out by one or two experienced members of the team initially, with a view to all staff being involved with peer review for subsequent audits.

To improve practice, departments can develop a library of images that sonographers can access for group reviews and teaching purposes. All members of the team should be encouraged to participate with subsequent audits in order to improve familiarity and compliance with the audit tool and promote a sense of ownership and responsibility.

A database for identifying cases that have been reviewed, and for storing the audit data, will need to be established. This can be an electronic database, a system linked to hospital patient records or a paper filing system. Services need to be mindful of data protection and information governance guidance and legislation regarding the storing of patient data³².

7.4 Review process

7.4.1 Sets of images

The reviewer will access three randomly selected sets of reported growth scan measurements and audit the relevant images against the set criteria shown in Appendix 5. The measurements that should be included in the audit set are HC, AC, FL and DVP. The reported Doppler assessments, namely UtA, UA and MCA, undertaken during the three scans should also be included in the audit. As Doppler assessment(s) may not be performed at every growth scan, it is acknowledged that the successful audit cycle of these measurements may be longer than that required for the default growth scan measurements.

The relevant criteria are recorded as being met (✓ or yes) or not met (x or no). The growth scan audit data should form the basis of the feedback discussion with each practitioner.

Detailed feedback should include examples of both good practice and any common themes or common areas where improvement is needed. If necessary, references to the individual images should be given to provide context and visual feedback.

There are no recommendations for threshold values for acceptable practice, rather we recommend that the growth scan audit and its feedback are used as an improvement tool. If consistent poor practice is detected and continues after mentoring and support have been provided, the capability policy may need to be followed.

The Growth Scan Audit tool template is shown in Appendix 5a.

7.4.2 Single measurement

The reviewer will access 25 randomly selected reported measurements (e.g. 25 AC measurements per practitioner) and audit the relevant reported images against the set criteria for the specific measurement chosen from the Growth Scan Audit tool. An example using the AC is shown in Appendix 5b. The measurements that should be included in the single measurement audit are HC, AC, FL, DVP, UtA, UA and MCA on a rotational basis.

We recommend that the AC is the first measurement to undergo single measurement audit.

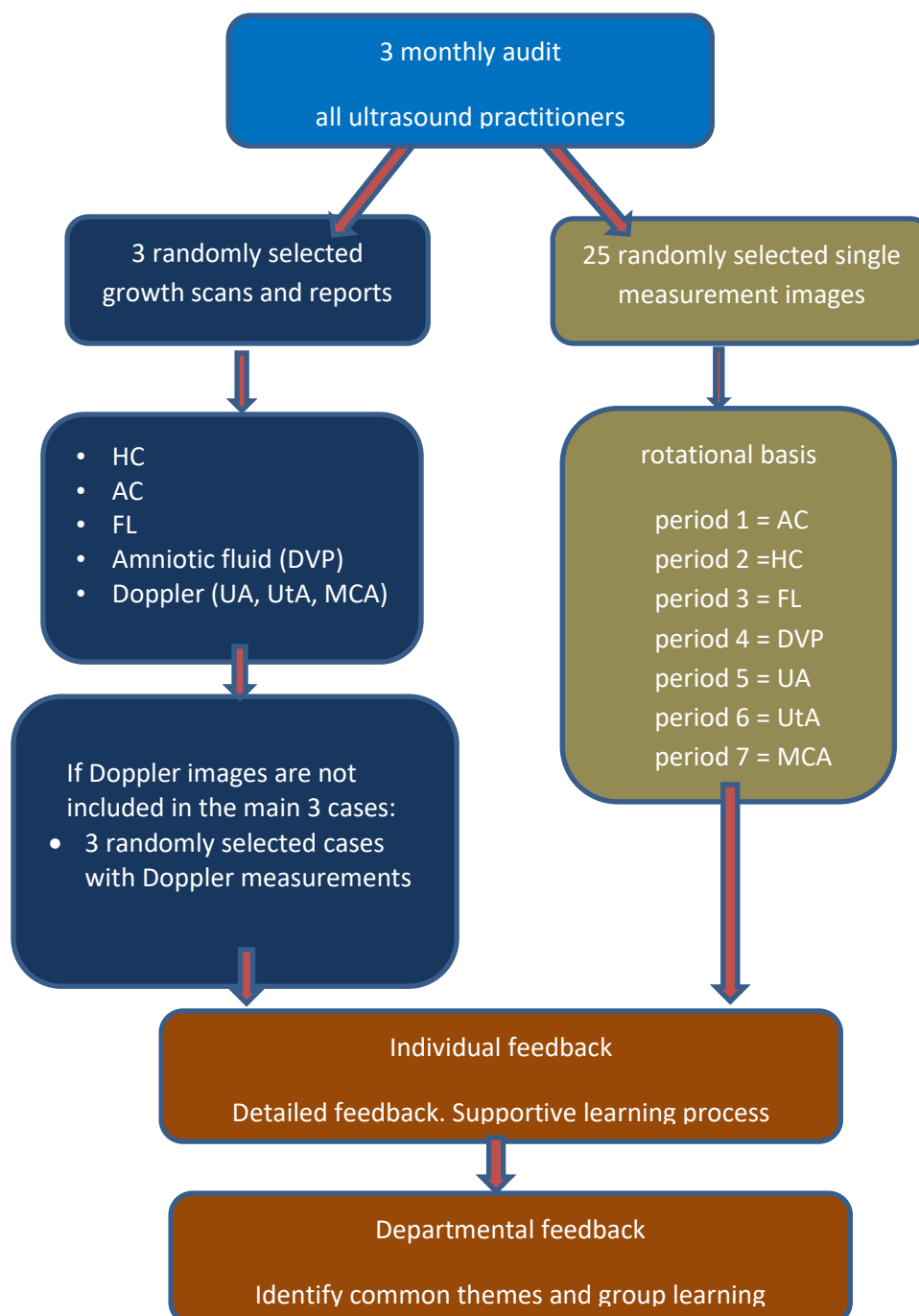
Relevant criteria are recorded as being met (✓ or yes) or not met (x or no). The single measurement growth scan audit data should form the basis of the feedback discussion with each practitioner.

Detailed feedback should include examples of both good practice and any common themes or common areas where improvement is needed. If necessary, references to the individual images should be given to provide context and visual feedback.

There are no recommendations for threshold values for acceptable practice, rather we recommend that the single image growth scan audit and its feedback are used as an improvement tool. If consistent poor practice is detected and continues after mentoring and support have been provided, the capability policy may need to be followed.

The Single Measurement Growth Scan Audit tool template for AC is shown in Appendix 5b.

The recommended audit programme for images and reports which should be audited for each ultrasound practitioner every 3 months is shown schematically below.



8 REFERENCES

1. Public Health England NHS Fetal Anomaly Screening Programme Handbook 2021.
<https://www.gov.uk/government/publications/fetal-anomaly-screening-programme-handbook>
2. Chudleigh T, Smith A & Cumming S. First steps in examining the second trimester of pregnancy in Obstetric and Gynecological Ultrasound How, Why and When (4th ed). Elsevier 2017 p 164-188
3. Salomon LJ, Alfirevic Z, Berghella V, Bilardo C, Hernandez-Andrade E, Johnsen SL, Kalache K, Leung KY, Malinger G, Munoz H, Prefumo F, Toi A, Lee W. ISUOG Practice guidelines for performance of the routine mid-trimester fetal ultrasound scan. *Ultrasound Obstet Gynecol* 2011; **37**: 116-126
4. Salomon LJ, Alfirevic Z, da Silva Vosta F, Deter RL, Figueras F, Ghi T, Glanc P, Khalil A, Lee W, Napolitano R, Papageorgiou AT, Sotiriadis A, Stirnemann J, Toi A & Yeo G. ISUOG Practice Guidelines: ultrasound assessment of fetal biometry and growth. *Ultrasound Obstet Gynecol* 2019; **53**:715-723
5. Bhide A, Acharya G, Baschat A, Bilardo CM, Brezinka C, Cafici D, Ebbing C, Hernandez-Andrade E, Kalache K, Kingdom J, Kiserud T, Kumar S, Lee W, Lees C, Leung KY, Malinger G, Mari G, Perfumo F, Sepulveda W & Trudinger B. ISUOG Practice Guidelines (updated): use of Doppler velocimetry in obstetrics. *Ultrasound Obstet Gynecol* 2021; **58**:331-339
6. Health Education England E-learning for healthcare.
<https://www.elfh.org.uk/programmes/clinical-imaging/>
7. Royal College of Obstetricians and Gynaecologists. The Investigation and Management of the Small-for-Gestational-Age Fetus. Green-top Guideline No 31. RCOG:2014
8. Saving Babies' Lives Version Two. A care bundle for reducing perinatal mortality. 2019.
<https://www.england.nhs.uk/wp-content/uploads/2019/07/saving-babies-lives-care-bundle-version-two-v5.pdf>
9. Chitty LS, Altman DG, Henderson A & Campbell S. Charts of fetal size:2. Head measurements. *Br J Obstet Gynaecol* 1994; **101**:35-43
10. Chitty LS, Altman DG, Henderson A & Campbell S. Charts of fetal size:3. Abdominal measurements. *Br J Obstet Gynaecol* 1994; **101**:125-131
11. Chitty LS, Altman DG, Henderson A & Campbell S. Charts of fetal size:4. Femur length. *Br J Obstet Gynaecol* 1994; **101**: 132-135
12. Campbell S & Thoms A. Ultrasound measurement of the fetal head to abdominal circumference ratio in the assessment of fetal growth retardation. *Br J Obstet Gynaecol* 1977; **84**: 165-174
13. Campbell S & Wilkin D. Ultrasonic measurement of fetal abdomen circumference in the estimation of fetal weight. *Br J Obstet Gynaecol* 1975; **82**: 689-697
14. Loughna P, Chitty L, Evans T & Chudleigh T. Fetal size and dating: charts recommended for clinical obstetric practice. *Ultrasound* 2009; **17(3)**:161-167

15. Hadlock FP, Harrist RB, Sharman RS, Deter RL & Park SK. Estimation of fetal weight with the use of head, body and femur measurements – A prospective study. *Am J Obstet Gynecol* 1985; **151**: 333-337
16. Dudley N & Varley H. Caveats in the monitoring of fetal growth using ultrasound estimated fetal weight, *Ultrasound* 2021; **29**(1):10-17
17. Gordijn SJ, Beune IM, Thilaganathan B, Papageorgiou A, Baschat AA, Baker, PN, Silver RM, Wynia K & Ganzevoort W. Consensus definition of fetal growth restriction: a Delphi procedure. *Ultrasound Obstet Gynecol* 2016; **48**: 333-339
18. New Zealand Maternal Fetal Medicine Network. Guideline for the Management of Suspected Small for Gestational Age Singleton Pregnancies and Infants after 34 Weeks' Gestation. NZMFM:2014
19. Hadlock FP, Harrist RB & Martinez-Poyer J. In utero analysis of fetal growth: a sonographic weight standard. *Radiology* 1991; **181**:129-133
20. Khalil A, Rodgers M, Baschat A, Bhide A, Gratacos E, Hecher K, Kilby MD, Lewi L, Nicolaidis KH, Oepkes D, Raine-Fenning N, Reed K, Salomon LJ, Sotiriadis A, Thilaganathan B & Ville Y. ISUOG Practice Guidelines: role of ultrasound in twin pregnancy. *Ultrasound Obstet Gynecol* 2016; **47**:247-263
21. Chauhan SP, Sanderson M, Hendrix NW, Magann EF & Devoe LD. Perinatal outcome and amniotic fluid index in the antepartum and intrapartum periods: A meta-analysis. *Am J Obstet Gynecol* 1999; **181**:1473-1478
22. Lim KJ, Butt K, Naud K & Smithies M. Amniotic fluid: technical update on physiology and measurement. *J Obstet Gynecol Can* 2017; **39**:52-58
23. Hughes DS, Whittington JR, Kim H, Gunderman B, Ounpraseuth S, Magann EF. Is there a difference in sonographic estimation of amniotic fluid volume when measuring with the probe perpendicular to the floor compared with perpendicular to the uterine contour? *J Obstet Gynaecol Can.* 2019;**41**(9):125-130
24. Magann E, Chauhan S, Whitworth N, Anfanger P, Rinehart B & Morrison J. Determination of amniotic fluid volume in twin pregnancies. *Am J Obstet Gynecol* 2000; **182**:6:1606-1609
25. Moore TR & Cayle JE. The amniotic fluid index in pregnancy. *Am J Obstet Gynecol* 1990; **162**:5: 1168-1173
26. Jauniaux ERM, Alfirevic Z, Bhide AG, Belfort MA, Burton GJ, Collins SL, Dornan S, Jurkovic D, Kayem G, Kingdom J, Silver R & Sentilhes L on behalf of the Royal College of Obstetricians and Gynaecologists. Placenta Praevia and Placenta Accreta: Diagnosis and Management. Green-top Guideline No. 27a. BJOG 2018
27. Jauniaux ERM, Alfirevic Z, Bhide AG, Burton GJ, Collins SL & Silver R on behalf of the Royal College of Obstetricians and Gynaecologists. Vasa praevia: diagnosis and management. Green-top Guideline No. 27b. BJOG 2018

28. Ter Haar G. 2012. Guidelines and recommendations for the safe use of diagnostic ultrasound: the user's responsibilities in The Safe Use of Ultrasound in Medical Diagnosis 3rd edition, ter Haar (editor). British Institute of Radiology, UK p 142-157
29. Kaminopetros P, Higuera MT & Nicolaides KH. Doppler study of uterine artery blood flow: comparison of findings in the first and second trimesters of pregnancy. *Fetal Diagn Ther* 1991; **6**:58–64.
30. Parra-Cordero M, Lees C, Missfelder-Lobos H, Seed P & Harris C. Fetal arterial and venous Doppler pulsatility index and time averaged velocity ranges. *Prenat Diagn* 2007;**27**: 1251-1257
31. Mari G. Middle cerebral artery peak systolic velocity for the diagnosis of fetal anemia: the untold story. *Ultrasound Obstet Gynecol* 2005; **25**:323-330
32. BMUS Recommended Audit Tool. <https://www.bmus.org/policies-statements-guidelines/professional-guidance/guidance-pages/bmus-recommended-audit-tool/>
33. Astraia software gmbh, Ismaning, Germany
34. Dudley N. Are ultrasound foetal circumference measurement methods interchangeable? *Ultrasound* 2019; **27**(3):176-182

APPENDIX 1 RECOMMENDED REFERENCE DATASETS

Measurement	Author	Reference
Biometry		
BPD (outer to outer)	Chitty et al ⁹	BJOG 1994; 101 : 35-43
OFD (outer to outer)	Chitty et al ⁹	BJOG 1994; 101 : 35-43
HC size (derived)	Chitty et al ⁹	BJOG 1994; 101 : 35-43
AC size (derived)	Chitty et al ¹⁰	BJOG 1994; 101 : 125-131
FL size	Chitty et al ¹¹	BJOG 1994; 101 : 132-135
Estimated fetal weight		
EFW (formulae)	Hadlock et al ¹⁵	Am J Obstet Gynecol 1985; 151 :333-337
EFW (chart)	Hadlock et al ¹⁷	Radiology 1991; 181 :129-133
Amniotic fluid assessment		
DVP	Magann et al ²⁴	Am J Obstet Gynecol 2000; 182 : 6: 1606-1609
AFI	Moore & Cayle ²⁵	Am J Obstet Gynecol 1990; 162 : 5: 1168-1173
Doppler assessment		
Uterine artery mean PI	Kaminopetros et al ²⁹	Fet Diagn Ther 1991; 6 : 58-64
Umbilical artery PI	Parra-Cordero et al ³⁰	Prenat Diag 2007; 27 : 1251-1257
MCA PI	Parra-Cordero et al ²³⁰	Prenat Diag 2007; 27 : 1251-1257
MCA Vmax (PSV)	Mari ²⁹	Ultrasound Obstet Gynecol 2005; 25 : 323-330

Abbreviations:

AC	abdominal circumference
AFI	amniotic fluid index
BPD	biparietal diameter
DVP	deepest vertical pool
EFW	estimated fetal weight
FL	femur length
HC	head circumference
MCA	middle cerebral artery
OFD	occipitofrontal diameter
PI	pulsatility index
PSV	peak systolic velocity
Vmax	maximum velocity

APPENDIX 2 EQUATIONS FOR RECOMMENDED REFERENCE DATASETS

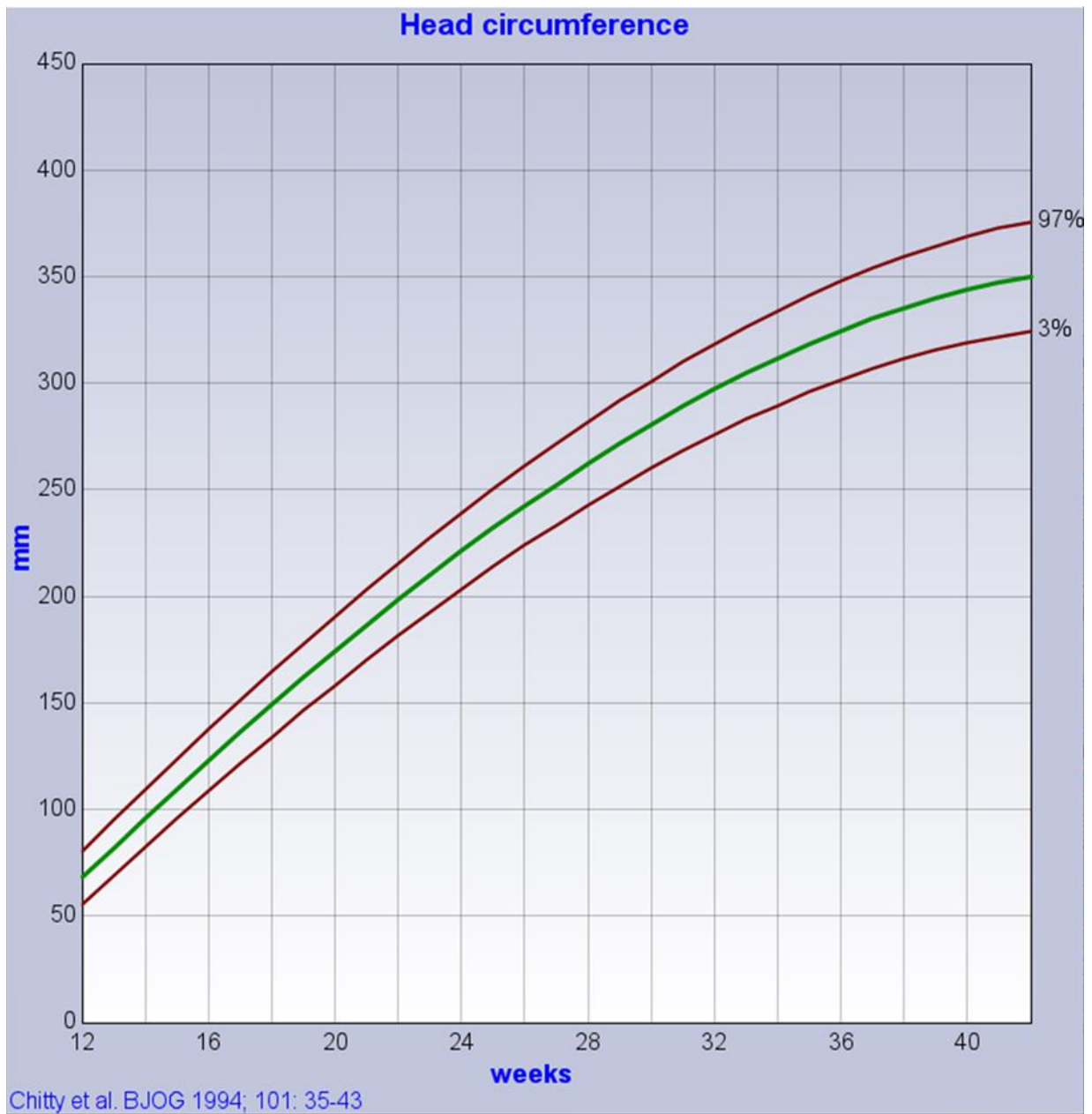
Measurement	Author	Equation
Biometry		
BPD (outer to inner)	Chitty 1994 ⁹	$BPD = - 28.36 + 3.967w - 0.0005543w^3$
BPD (outer to outer)	Chitty 1994 ⁹	$BPD = - 28.59 + 4.110w - 0.0005985w^3$
OFD (outer to outer)	Chitty 1994 ⁹	$OFD = - 41.58 + 5.550w - 0.0009141w^3$
HC size (derived)	Chitty 1994 ⁹	$HC = - 109.7 + 15.16w - 0.002388w^3$
AC size (derived)	Chitty 1994 ¹⁰	$AC = - 85.84 + 11.92w - 0.0007902w^3$
FL size	Chitty 1994 ¹¹	$FL = - 32.43 + 3.416w - 0.0004791w^3$
Estimated fetal weight (formulae require measurements in cm)		
HC, AC, FL (Hadlock 3)	Hadlock 1985 ¹⁵	$\log_{10} \text{ weight} = 1.326 - 0.00326 AC \times FL + 0.0107 HC + 0.0438 AC + 0.158 FL$
AC, FL (Hadlock 2)	Hadlock 1985 ¹⁵	$\log_{10} \text{ weight} = 1.304 + 0.05281 AC + 0.1938 FL - 0.004 AC \times FL$
BPD, HC, AC, FL (Hadlock 4)	Hadlock 1985 ¹⁵	$\log_{10} \text{ weight} = 1.3596 + 0.00386 AC \times FL + 0.0064HC + 0.00061 BPD \times AC + 0.0424 AC + 0.174 FL$
Doppler assessment		
Uterine artery, mean PI	Kaminopetros 1991 ²⁹	<i>Not provided</i>
Umbilical artery PI	Parra-Cordero 2007 ³⁰	$\log_{10} (UA PI) = 0.0134GA + 0.405$
MCA PI	Parra-Cordero 2007 ³⁰	$\log_{10} (MCA PI) = -0.00204GA^2 + 0.114GA - 1.24$
MCA Vmax (PSV)	Mari 2000 ³¹	$MCA PSV = e^{(2.31+0.046 GA)}$

Abbreviations:

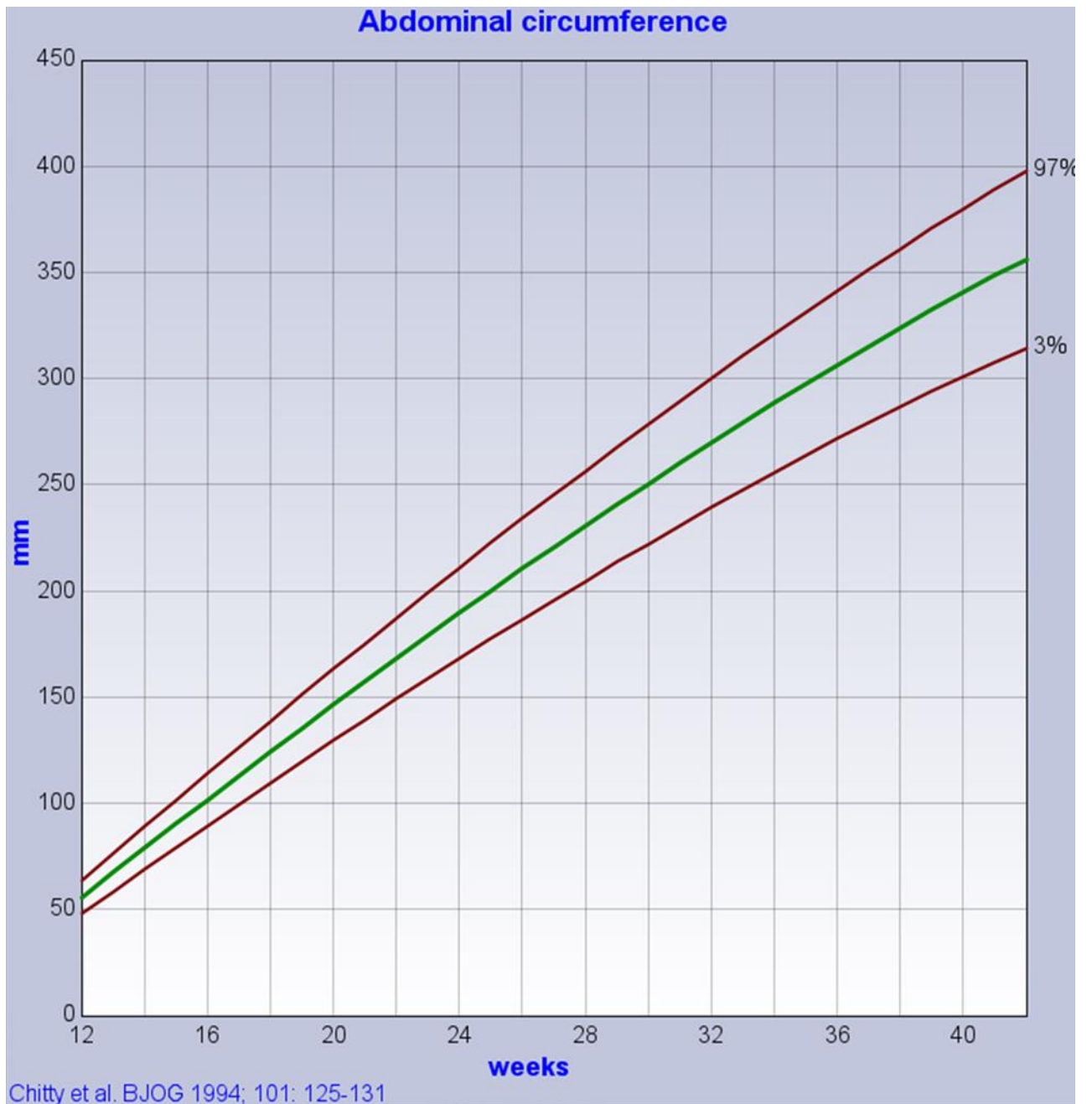
AC	abdominal circumference
BPD	biparietal diameter
EFW	estimated fetal weight
FL	femur length
GA	gestational age
HC	head circumference
MCA	middle cerebral artery
OFD	occipitofrontal diameter
PI	pulsatility index
PSV	peak systolic velocity
UA	umbilical artery
Vmax	maximum velocity
w	exact gestational age in weeks

APPENDIX 3 REFERENCE CHARTS³³

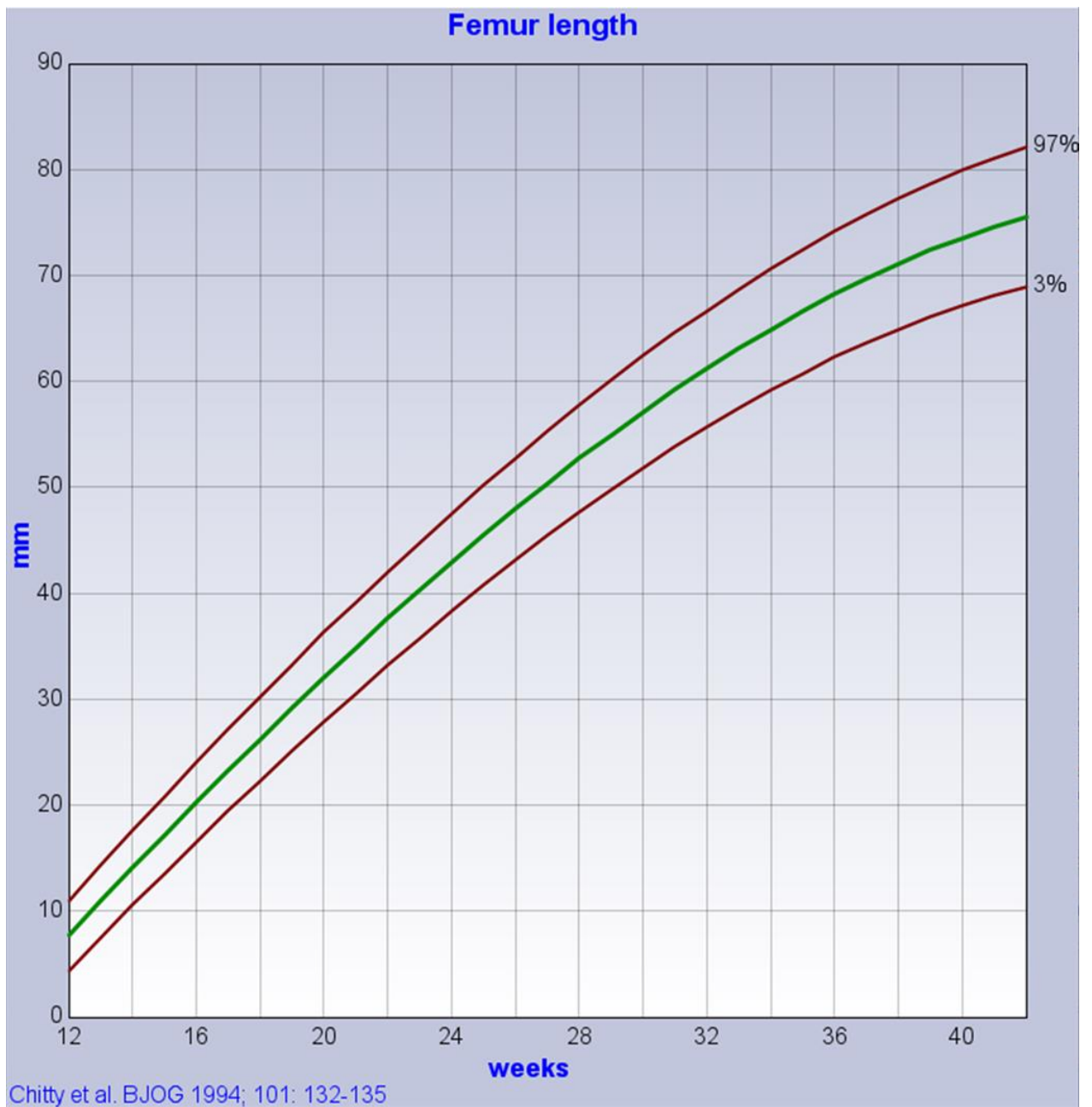
1. Head circumference (HC) size chart



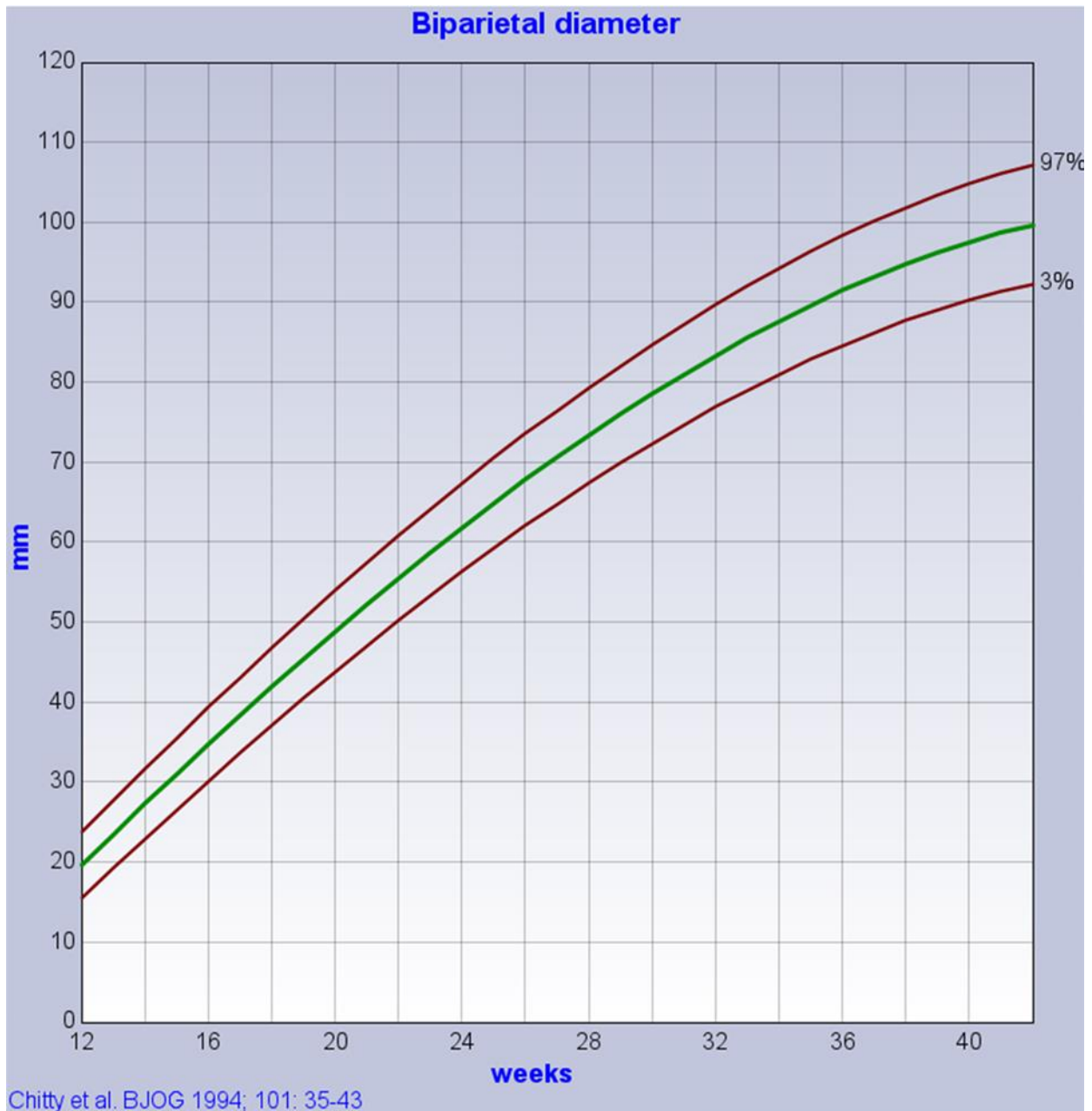
2. Abdominal circumference (AC) size chart



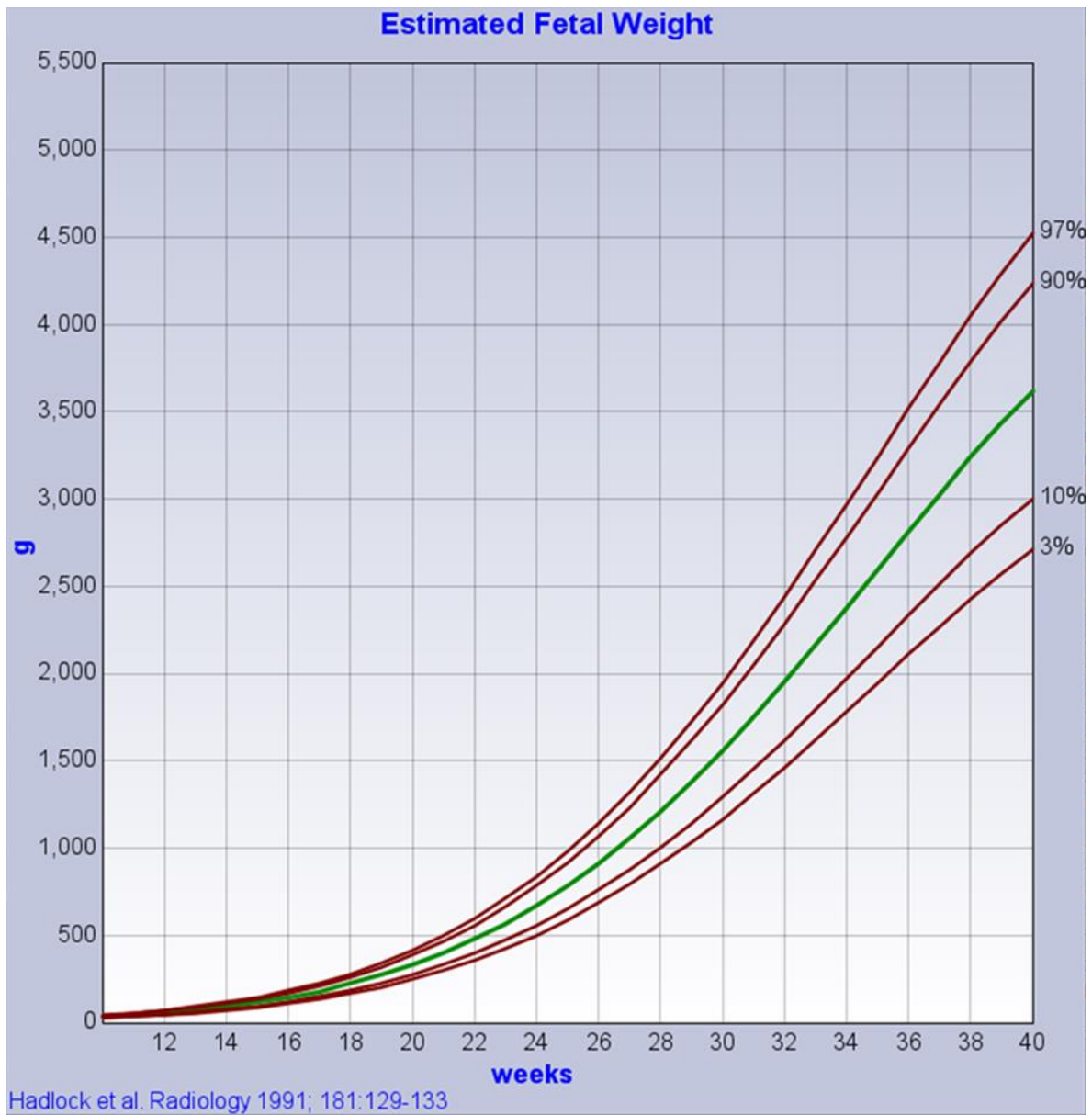
3. Femur length (FL) size chart



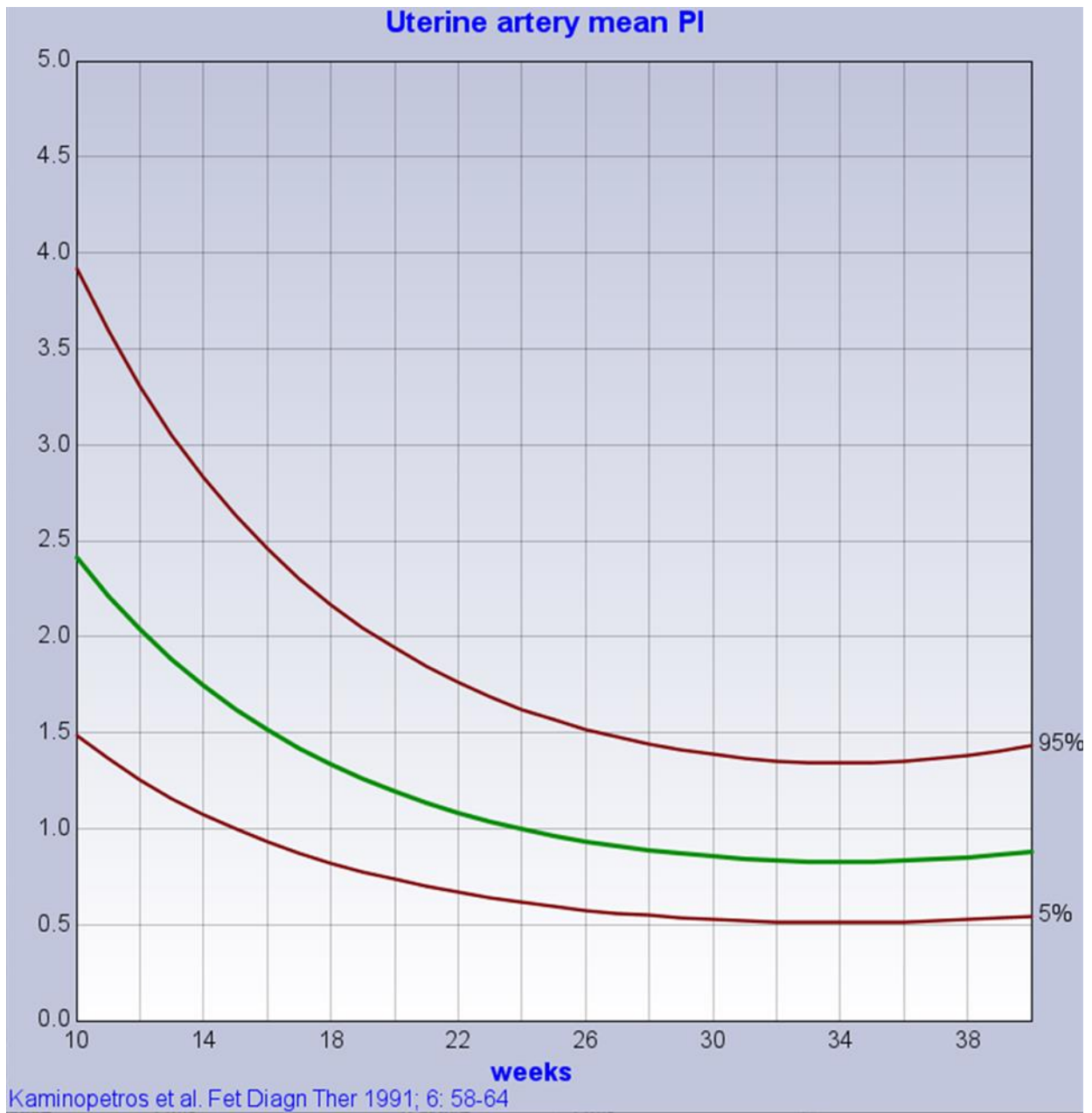
4. Biparietal Diameter (BPD) - outer to outer - size chart



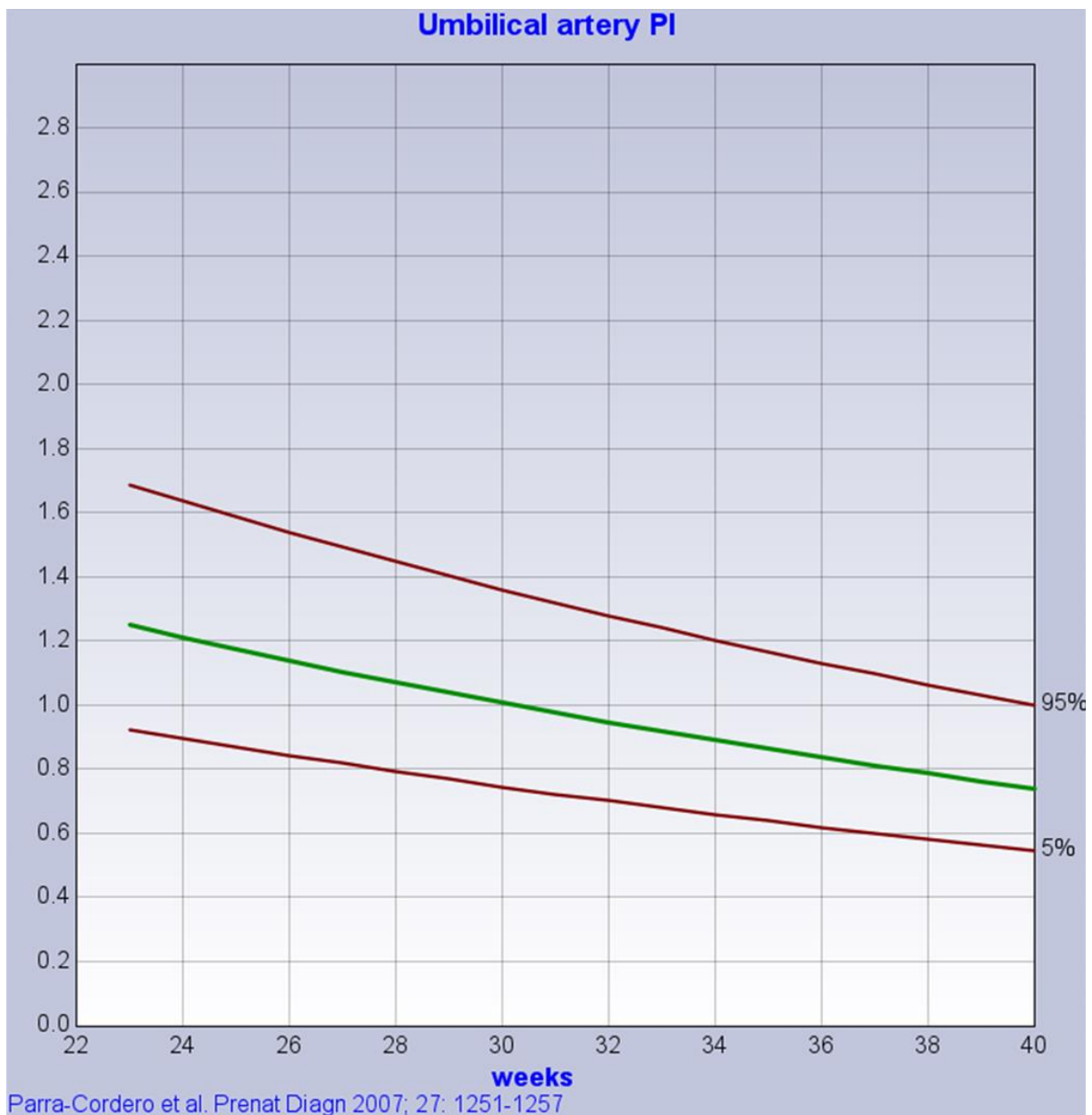
5. Estimated Fetal Weight (EFW)



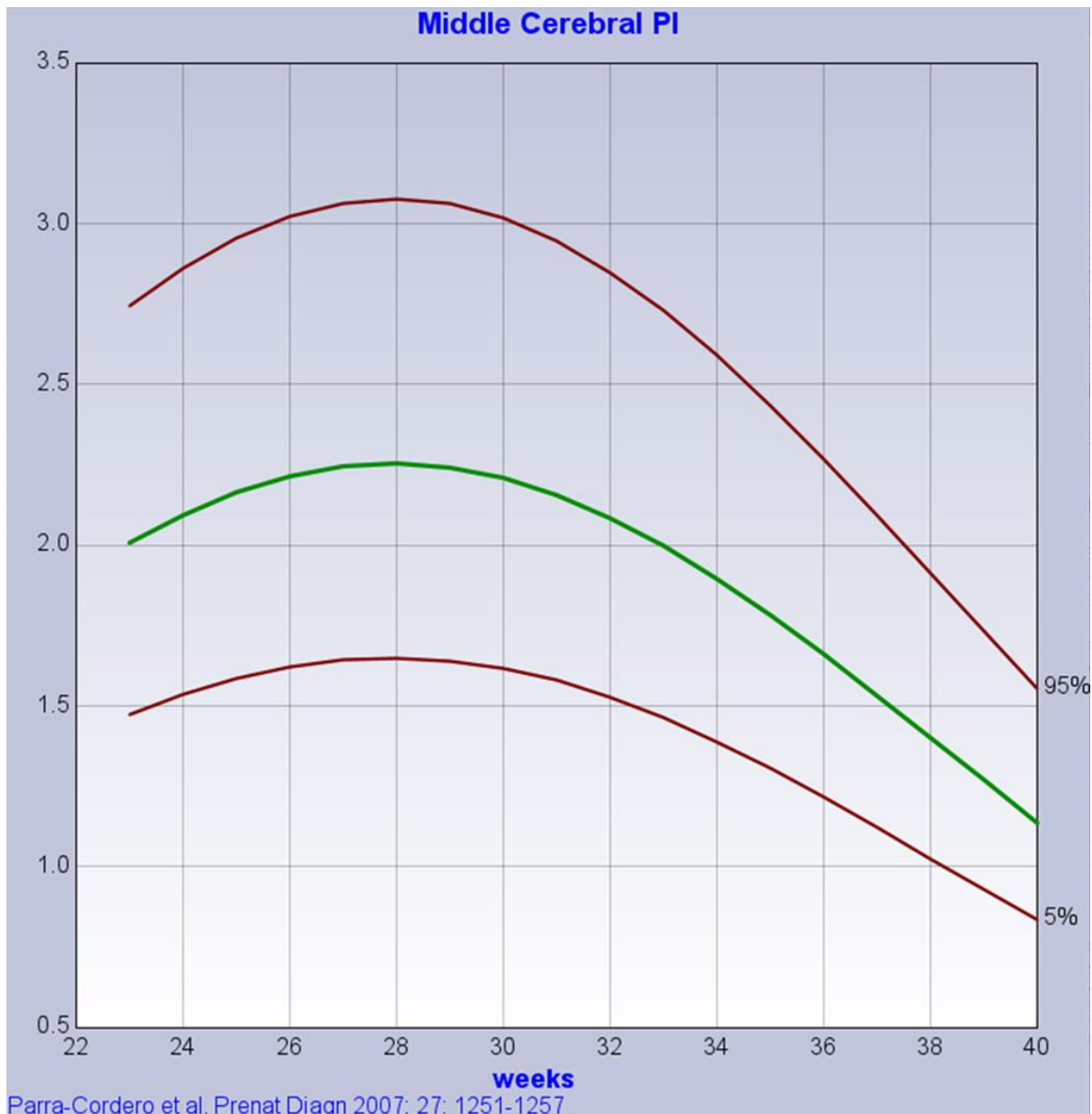6. Uterine artery (UtA) mean PI



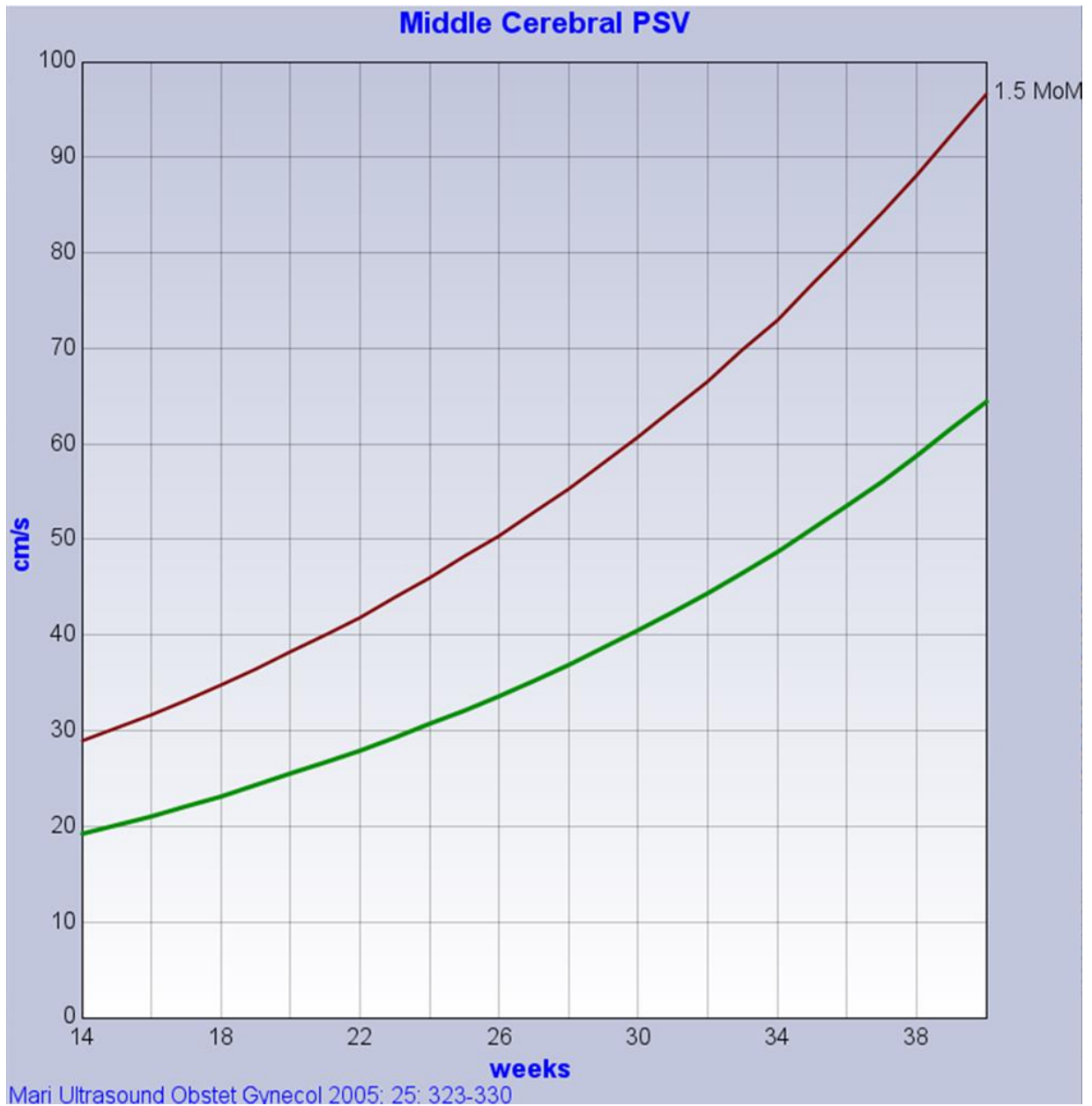7. Umbilical artery pulsatility index (UA PI)



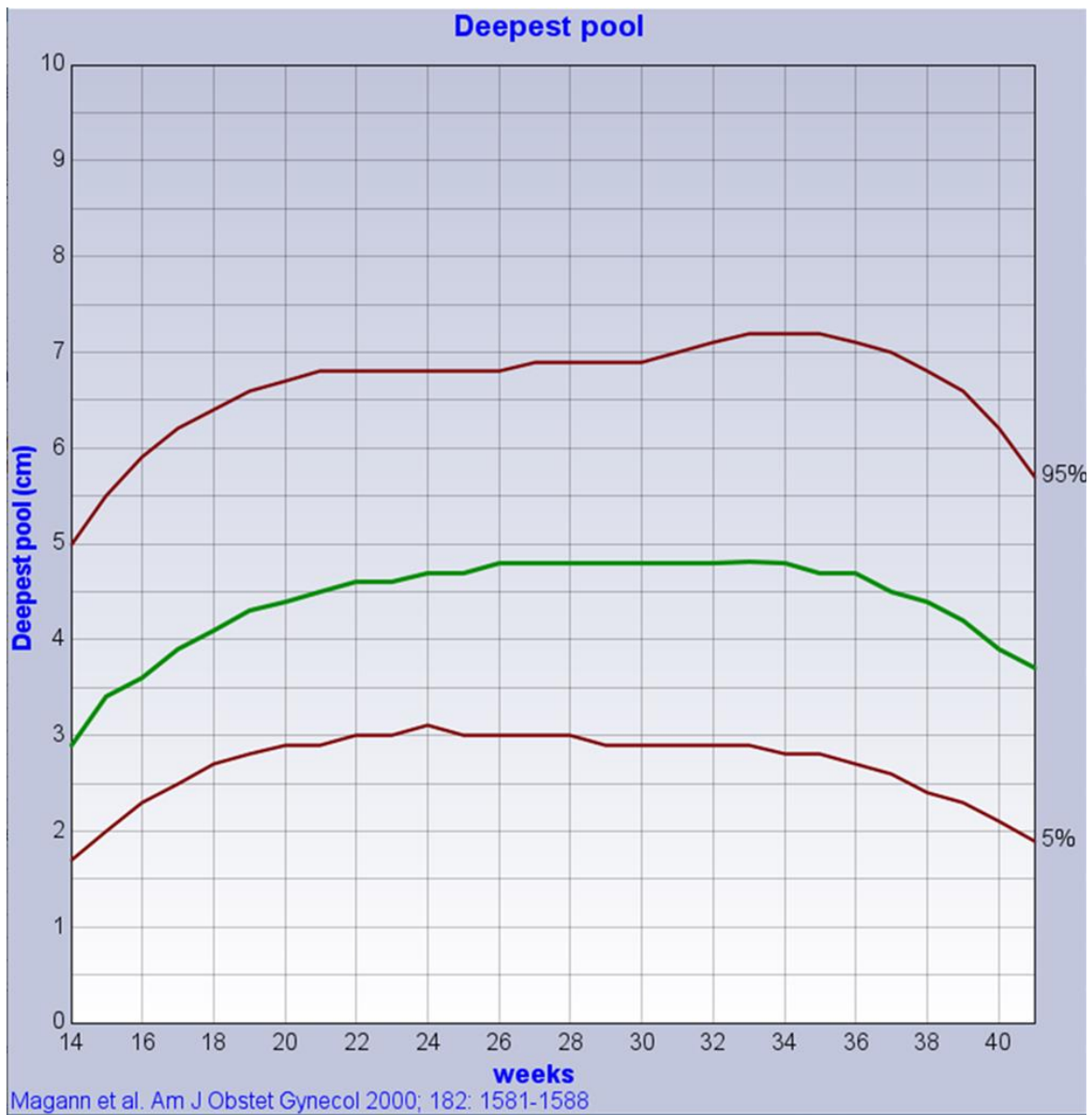
8. Middle cerebral artery pulsatility index (MCA PI)



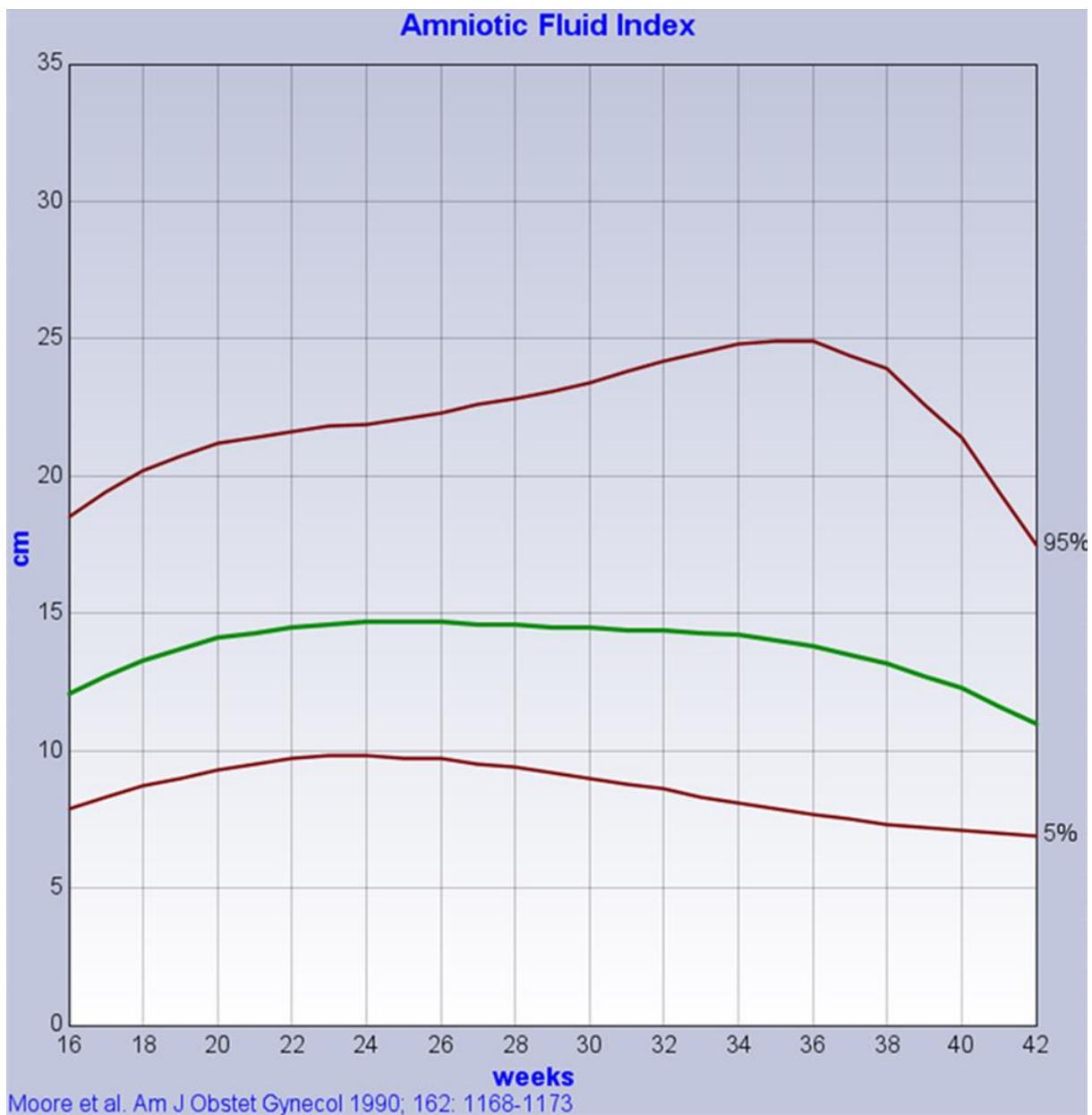
9. Middle cerebral artery peak systolic velocity (MCA PSV)



10. Deepest vertical pool (DVP)



11. Amniotic fluid index (AFI)



APPENDIX 4 RATIONALE FOR USING DIAMETERS IN THE CALCULATION OF HC and AC

Chitty et al published HC and AC size charts and their respective equations from circumference measurements obtained by two methods:

- i) 'plotted' - tracing freehand round the circumference and using the measurement given by the ultrasound machine's software. It will be noted that, with modern ultrasound machines, this method is no longer an option. However, it is similar to the newer 'plot' method although the latter is probably subject to smaller uncertainty
- ii) 'derived' - deriving the measurement from the two maximum diameters of the circumference at 90° (orthogonal) to each other and then applying a formula to calculate the measurement.

As the circumference measurements obtained by the two methods differ, it is important that the method used in current clinical practice mirrors the method described for the recommended Chitty size charts. This is because the plotted measurements are larger than the derived measurements by approximately 1% across all gestations for the HC and approximately 3.5% across all gestations for the AC^{9,10}.

Method of obtaining circumference measurements

Historically, circumference measurements were obtained by freehand tracing around the perimeter of the head or abdomen. Although modern machines offer a modified, 'plot' version of this method, fitting an ellipse or measuring two orthogonal maximum diameters are now the methods of choice.

We recommend the two diameters method for two reasons:

- i) The Chitty HC and AC size charts were constructed using the two-diameter method, rather than the fitted ellipse method. This is because the fitted ellipse method was not available on the equipment used at the time the data were collected.
- ii) The reproducibility of the two-diameter method is superior to that of the ellipse method. This is likely to relate to the placement of two linear calipers requiring less subjectivity than attempting to fit an electronically generated ellipse to a non-elliptical outline³⁴.

Formula for calculating circumference measurements

Having obtained the two diameters d1 and d2, the resulting circumference can be calculated from one of two formulae – the formula that approximates to a circle or the formula for an ellipse.

Fortuitously, current clinical practice does not require the operator to calculate a circumference measurement from d1 and d2 manually, rather, simply, to enter the two diameters into the relevant ultrasound machine or computer software. The circumference measurement is then calculated automatically by the software.

The circular approximation to calculate the circumference of an ellipse using two diameters (CD) is given below:

$$CD = \pi (d1+d2)/2$$

The exact formula used to calculate the circumference of an ellipse (CE) is given below:

$$CE = \pi(a+b)(1 + x^2/4 + x^4/64 + x^6/256 + 25x^8/16384)$$

where a = length of major axis, b = length of minor axis, $x = (a-b)^2/(a+b)^2$.

In practice the calculations based on the circumference of a circle and of an ellipse respectively give results to within 1% of each other, until the cephalic index (BPD/OFD) is less than approximately 0.7.

APPENDIX 5a SET OF IMAGES GROWTH SCAN AUDIT TOOL TEMPLATE

B mode Image: Criteria met (Yes or v), Criteria not met (No or X)				
Criteria	Scan 1	Scan 2	Scan 3	Comments/feedback
Head Circumference				
HC occupies 60% or more of ultrasound image				
Rugby ball shape				
Presence of cavum septum pellucidum				
Midline less than 20° to horizontal				
Midline centrally placed				
Medial walls of anterior & posterior horns of lateral ventricles centrally placed around midline				
Accurate caliper placing (BPD)				
Accurate caliper placing (OFD)				
Abdominal circumference				
AC occupies 60% or more of ultrasound image				
As close as possible to circular in shape				
Spine appears as three ossification centres				
Single rib, of equal length, on both sides				
Short length of UV, in the middle one third of the abdomen				
Stomach present				
Lung bases absent				
Kidney absent				
Accurate caliper placing (APAD)				
Accurate caliper placing (TAD)				
Femur length				
FL occupies 60% or more of ultrasound image				
Full length of diaphysis, excluding distal epiphysis if visible & end plate irregularity at either end				
Angle less than 15° to horizontal				
Accurate caliper placing				

AC, abdominal circumference; APAD, antero-posterior abdominal diameter; BPD, biparietal diameter; FL, femur length; HC, head circumference; OFD, occipito-frontal diameter; TAD, transverse abdominal diameter; UV, umbilical vein

B mode Image: Criteria met (Yes or v), Criteria not met (No or X)				
Criteria	Scan 1	Scan 2	Scan 3	Comments/feedback
Deepest pool or AFI				
Empty fluid pool (no cord or fetal parts seen)				
True maximum depth in section demonstrated				
Accurate caliper placing perpendicular to floor				
Accurate caliper placing taking into account any artefact present				
AFI (criteria as above) (score for each section)				
Q1	Q2	Q3	Q4	

AFI, amniotic fluid index; Q, quadrant

Doppler Image Review: Criteria met (Yes or v), Criteria not met (No or X)				
Vessel investigated	Scan 1	Scan 2	Scan 3	Comments/feedback
Colour Doppler				
TIB within safety guidelines				
Colour box includes only the area to be studied				
No aliasing/noise/artefacts				
Spectral Doppler				
TIB within safety guidelines				
Waveform fills at least 75% of the part of the screen displaying the spectral trace (PRF)				
Angle of insonation less than 30° from the vertical				
4-10 waveforms displayed				
Gate length 3.00mm or more				
The measured waveforms similar in appearance				
No aliasing/artefacts/movements				

TIB, thermal index for bone

**APPENDIX 5b SINGLE MEASUREMENT GROWTH SCAN AUDIT TOOL
TEMPLATE (AC)**

Criteria for Abdominal circumference	1	2	3	4	5	6	7	8	9	10	11	12	13	14	15
AC occupies 60% or more of ultrasound image															
As close as possible to circular in shape															
Spine appears as three ossification centres															
Single rib, of equal length, on both sides															
Short length of UV, in the middle one third of the abdomen															
Stomach present															
Lung bases absent															
Kidney absent															
Accurate caliper placing (APAD)															
Accurate caliper placing (TAD)															

Criteria for Abdominal circumference	16	17	18	19	20	21	22	23	24	25
AC occupies 60% or more of ultrasound image										
As close as possible to circular in shape										
Spine appears as three ossification centres										
Single rib, of equal length, on both sides										
Short length of UV, in the middle one third of the abdomen										
Stomach present										
Lung bases absent										
Kidney absent										
Accurate caliper placing (APAD)										
Accurate caliper placing (TAD)										

AC, abdominal circumference; APAD, antero-posterior abdominal diameter; TAD, transverse abdominal diameter; UV, umbilical vein

APPENDIX 6 GUIDANCE ON DOPPLER EXAMNATIONS

Doppler examinations assess impedance to flow downstream from the sampling point. This corresponds to the uteroplacental interface when sampling the uterine arteries (UtA), the placental bed when sampling the umbilical artery (UA) and the cortex of the fetal brain when sampling the middle cerebral artery (MCA).

1. SAFETY GUIDANCE

The thermal index for bone (TIB) and the mechanical index (MI) should be displayed on the ultrasound screen throughout any Doppler examination. The thermal index for soft tissue (TIS) should not be used after 8 weeks of gestation. The BMUS safety guidelines for the thermal index (TI), as summarised below, should be followed²⁸.

TI (TIS <8wks, TIB >8wks)	Maximum exposure (mins)
0.7*	60
1.0	30
1.5	15
2.0	4
2.5	1

*TI >0.7 – the overall exposure time (including pauses) of an embryo or fetus should be restricted

It is the responsibility of the operator to ensure that any examination, including spectral (pulsed or PW) Doppler examination, is performed within safety guidelines. Where it is not possible to reduce an unsafe TI value by manipulation of the ultrasound machine's controls, advice from the local medical physics department and/or the manufacturer should be sought.

2. RECOMMENDATIONS FOR ALL DOPPLER EXAMINATIONS

We make the following general recommendations that are applicable to the Doppler assessment of the UtA, UA and MCA:

1. Colour Doppler is helpful, although not essential, in identifying the correct vessel to assess.
2. Scanner presets should be configured with a gate length of at least 3.0 mm to reduce spectral broadening. The gate length may be reduced only to eliminate signals from adjacent vessels.

3. Where end diastolic flow is a diagnostic feature the wall filter should be at a low setting.
4. It is important to set gain to a level where the signal is not saturated or affected by noise.
5. The maximum Doppler shift, or the 'largest' waveform, is obtained when the vessel being interrogated is in complete alignment to the sound beam, that is lying in the vertical rather than the horizontal plane on the ultrasound screen, with the insonation angle therefore as close to 0° as possible. This angle should never be more than 30° from the vertical. Note that, in order to achieve this for the UA, it is important also to consider the alignment of the vessel in the slice direction.
6. Avoid pressure on the probe during recording of the Doppler signal. The increased pressure can influence the flow directly, or indirectly, by causing uterine contraction.
7. The flow velocity scale or pulse repetition frequency (PRF), and the position of the baseline, should be adjusted so that the waveform fills at least 75% of the part of the screen displaying the spectral trace.
8. Unless reverse flow is anticipated in the vessel being interrogated, there is no need to maintain the baseline centrally in the display. It can be moved towards the lower end of the display, thus allowing a larger waveform to be obtained.
9. The horizontal sweep speed of the Doppler trace should be set to display a minimum of 4 and a maximum of 10 waveforms.
10. The 4-10 waveforms displayed should be similar in appearance ('width' and 'height') with no aliasing or background artefacts. The assessment should be repeated if these criteria are not met.
11. The Doppler waveform should be recorded during periods of fetal quiescence, that is in the absence of general fetal movements and/or fetal breathing movements.
12. Pulsatility index (PI) measurements should be made using the automatically generated maximum velocity envelope (MVE). This should only include waveforms that are similar in appearance. It is important to check the fit of the MVE to ensure no artefacts are included before recording a result. Manual tracing should be avoided where possible.
13. It is particularly important to be able to reproduce a pathological finding in order to exclude a possible inaccurate interpretation of the waveform^{5,29}.

14. Conventionally blood flow towards the probe is displayed as red when colour Doppler is applied, and the waveforms of the Doppler display appearing above the baseline when spectral pulsed Doppler is applied. Activating the invert control in colour or spectral mode will result in the same flow being displayed as blue, and the waveforms of the Doppler display appearing below the baseline respectively.
15. The invert control is not required when assessing the UtA or MCA but is often useful when sampling the coiled UA, as it is easier to evaluate a waveform that is above the baseline than below.

3. UTERINE ARTERY ASSESSMENT

Doppler assessment of the uterine arteries (UtA) is carried out transabdominally, ideally at 22-23 weeks of gestation. At the present time, UtA Doppler assessment is only offered to women at increased risk of fetal growth restriction as determined by criteria set locally and/or nationally^{7,8}. There are currently no data to support the clinical benefit of UtA in the third trimester of pregnancy.

The abdominal probe is placed longitudinally in the lower lateral quadrant of the maternal abdomen over the iliac fossa and angled until the external iliac vessels are visualised. With the aid of colour Doppler, the main branch of the uterine artery is then identified crossing the iliac vessels. As flow in the uterine artery is towards the probe, flow in this vessel will appear red. The sample volume or gate should be obtained approximately 10mm downstream from this crossover point. Thus, the sample gate should be placed over the uterine artery, approximately 10mm above where it crosses the external iliac artery as seen on the ultrasound image. Occasionally, the uterine artery bifurcates before crossing the external iliac artery. In these cases, the sample volume should be placed on the artery just before the bifurcation⁵.

Blood flow in the UtA is forwards throughout the cardiac cycle. The baseline for the spectral trace can therefore be positioned towards the lower end of the display to allow a maximum spectral trace of the UtA to be displayed.

The abnormal finding of the UtA is:

- Mean UtA PI *above* the normal range (i.e. above the 95th percentile).

4. UMBILICAL ARTERY ASSESSMENT

Impedance to flow in the two umbilical arteries changes significantly along the length of the cord, being highest at the fetal end and lowest at the placental insertion end. A loop of cord freely floating within the amniotic fluid should be sought for assessment of the UA.

The coiling of the cord vessels results in flow within the UA being both towards (therefore appearing red on colour flow) and away from (therefore appearing blue on colour flow) the ultrasound probe. Where the flow in the UA site being sampled is away from the probe, it is acceptable to apply the invert/reverse control so that the spectral trace is displayed above rather than below the baseline. The maximum Doppler shift, and therefore the 'best' spectral trace, will be obtained from sampling a section of the umbilical artery lying in the vertical, as opposed to the horizontal, plane.

Blood flow in the normal UA is forwards throughout the cardiac cycle, with absent or reverse end diastolic flow being abnormal findings. The baseline for the spectral trace should be positioned centrally in the display initially. Providing there is no evidence of reverse flow, it can then be moved downwards to allow a larger spectral trace of the UA to be displayed.

The maximum Doppler shift is obtained when the section of UA being sampled lies in alignment to the ultrasound beam. This will result in a spectral trace displaying the UA only, and, providing flow is forward throughout the whole cardiac cycle, in the upper channel only. This is advantageous as reverse flow, if present, can be easily identified in the lower channel. Where this alignment is not obtained, the spectral trace will typically display the UA in the upper channel and flow from the umbilical vein (UV) in the lower channel. This is advantageous as fetal breathing movements can be readily observed, or excluded, from inspection of the UV trace in the lower channel. The disadvantages of this latter technique are that the UV trace has the potential to mask any reverse flow in the UA and also makes it difficult to distinguish between absent and reverse flow in the UA.

Where absent or reversed EDF is suspected, care should be taken to ensure that the finding is reproducible over a number of separate traces and is not caused by, for example, poor placement of the sample gate, fetal movement or incorrect setting (too high) of the wall motion filter.

In a two vessel cord the diameter of the single umbilical artery is larger than in a cord where two arteries are present. This results in a subsequent reduction of impedance and will typically result in a lower PI than in the UA from a three vessel cord. The fact that a two vessel cord is present, that the single artery has been sampled and the effect this may have on the PI obtained should be included in the report, with the recommendation that the PI is interpreted with caution.

Do not attempt to assess the UA when the fetus is actively moving or breathing as the resulting trace and its measurement will be inaccurate.

Abnormal findings of the UA are:

- PI *above* the normal range (i.e. above the 95th percentile)
- *absent or reversed EDF.*

5. MIDDLE CEREBRAL ARTERY DOPPLER

The proximal MCA, adjacent to the Circle of Willis, is best imaged from a transverse section of the fetal head at the level of the thalami, with the midline in the horizontal plane. The angle between the ultrasound beam and the direction of blood flow should be kept as close as possible to 0° . Where the midline does not lie in the horizontal plane moving the probe across the maternal abdomen, and thus imaging the fetal head from a different approach, will frequently result in the required reduction in insonation angle of the MCA. The distal vessel may be chosen if obtaining an insonation angle of 0° is easier for the distal MCA than for the proximal MCA.

As the systolic velocity in the MCA decreases with distance from its point of origin, the sample volume should be placed over the proximal third of the MCA, close to, that is just above, its origin in the internal carotid artery. Care should be taken to avoid undue pressure on the fetal head as can occur when, for example, the fetal head is very low in the maternal pelvis. This is because the pressure can result in a decrease in blood flow in the MCA and produce unreliable results. An empty maternal bladder may be advantageous in reducing pressure on the fetal head although this in turn may compromise subsequent image quality. In such situations, it is preferable not to attempt to measure the MCA rather than report an inaccurate value which may in turn contribute to inappropriate clinical decisions being made.

Blood flow in the proximal MCA will always be towards the probe and its spectral trace will therefore always appear above the base line. Reverse flow is not a feature of the MCA. There is therefore no need to maintain the baseline for the spectral trace centrally in the display. Moving it downwards will allow a larger spectral trace of the MCA to be displayed.

Two different measurements of the MCA can be taken, namely the PI and the peak systolic velocity (PSV) or maximum velocity (V_{max}).

5.1 MCA PI

The MCA PI is used to indicate redistribution within the fetal circulation in response to worsening hypoxia. Unlike the other Doppler parameters used in growth assessment, a PI value below the normal range is abnormal.

Do not attempt to assess the MCA PI when the fetus is actively moving or breathing as the resulting trace and its measurement will be inaccurate.

There is no requirement to apply angle correction when measuring the MCA PI.

Applying undue pressure on the probe may cause a decrease, or a disappearance, in end diastolic velocities in the MCA. This will result in a falsely increased PI measurement and therefore a false negative result.

The abnormal finding of the MCA PI is:

- MCA PI below the normal range (i.e. below the 5th percentile).

5.2 MCA PSV

We acknowledge that measurement of the MCA PSV is not currently part of routine growth assessment in either singleton or twin pregnancies. It is included here as department may wish to consider this if advanced imaging is undertaken.

The PSV is used in the evaluation of fetal anaemia in singleton or multiple pregnancies and in the evaluation of twin anaemia polycythaemia sequence (TAPS) in monochorionic diamniotic (MCDA) twin pregnancies^{20,31}

Do not attempt to assess the MCA PSV when the fetus is actively moving or breathing as the resulting trace and its measurement will be inaccurate.

Applying undue pressure on the probe may cause a decrease in end diastolic velocities but overall increased flow in the MCA. This may result in a falsely increased MCA PSV measurement and therefore a potentially false positive result in both the assessment of fetal anaemia and of TAPS.

In order to obtain the correct velocity in cm/s, all measurements of PSV require manual angle correction of the Doppler beam unless the angle between the ultrasound beam and the direction of blood flow in the MCA is 0°.

Angle correction can be applied to the MCA vessel in real time or to the frozen image of the MCA vessel after the correct trace has been obtained. It must be carried out **before** the PSV measurement is made. Failure to angle correct will result in an erroneously lower MCA PSV being obtained.

Assessment of PSV uses multiples of the median rather than percentiles. A 'normal' measurement is therefore one which is 1.0MoM for gestation. A PSV above 1.5 multiples of the median (MoM) is abnormal in the evaluation of fetal anaemia, while a combination of PSVs above 1.5 MoM and below 1.0MoM is abnormal in the evaluation of TAPS.

Abnormal findings of the MCA PSV are:

- MCA PSV greater than 1.5MoM, suggestive of *fetal anaemia*^{20,31}
- MCA PSV greater than 1.5MoM in one twin and less than 1.0MoM in the second twin, indicating *TAPS*.

6. CEREBROPLACENTAL & UMBILICOCEREBRAL RATIOS (CPR & UCR)

In addition to measuring the PI in the UA and the MCA, the ratio of the two values can be calculated. This potentially provides a more sensitive indicator of fetal hypoxia than the two values individually.

The cerebroplacental ratio (CPR) is calculated by dividing the MCA PI by the UA PI.

The umbilicocerebral ratio (UCR) is calculated by dividing the UA PI by the MCA PI.

Both ratios can be used in the management of pregnancies at increased risk of fetal growth restriction, with the CPR currently being more commonly used than the UCR.

A number of reference charts have been published for both ratios but at the current time there is a lack of consensus as to which of the reference charts for either ratio is recommended. There is similarly a lack of consensus as to which ratio is preferable in the management of pre-eclampsia and/or FGR or indeed whether both may be clinically useful, but in different scenarios.

We therefore do not recommend the use of either ratio in the assessment of growth at the current time but rather recommend that the PI of both vessels is reported separately.