

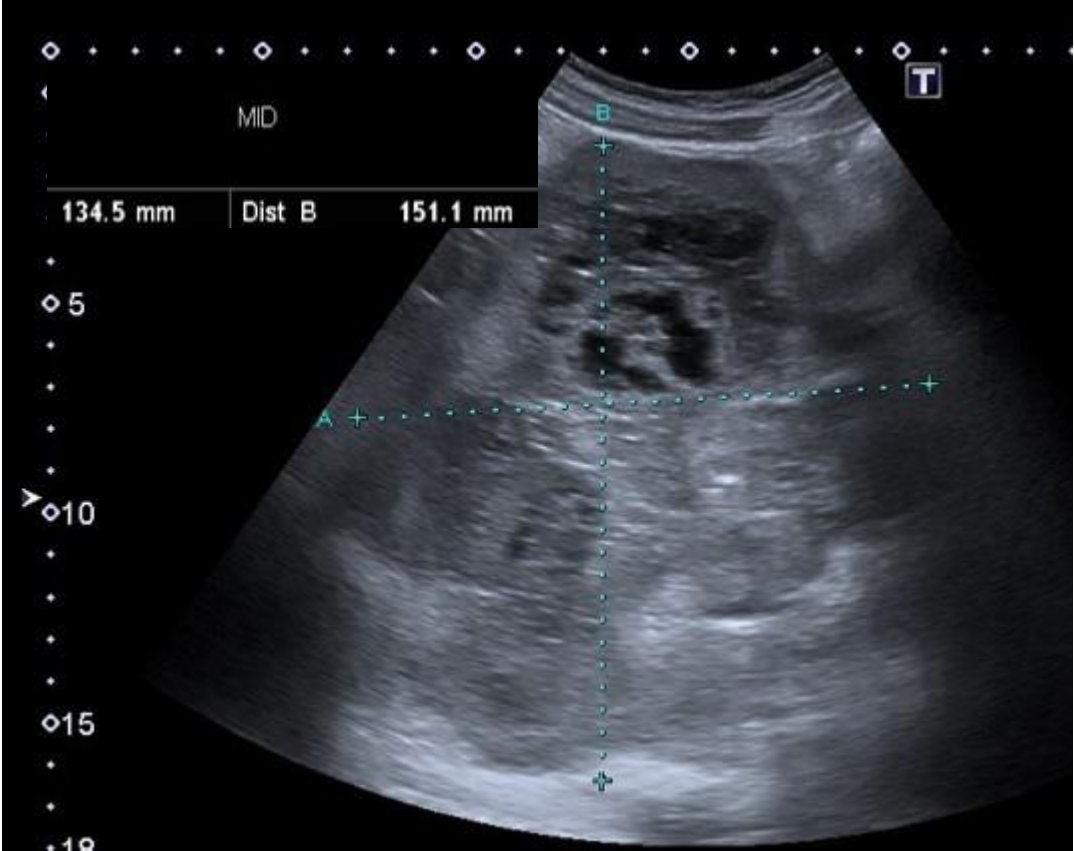
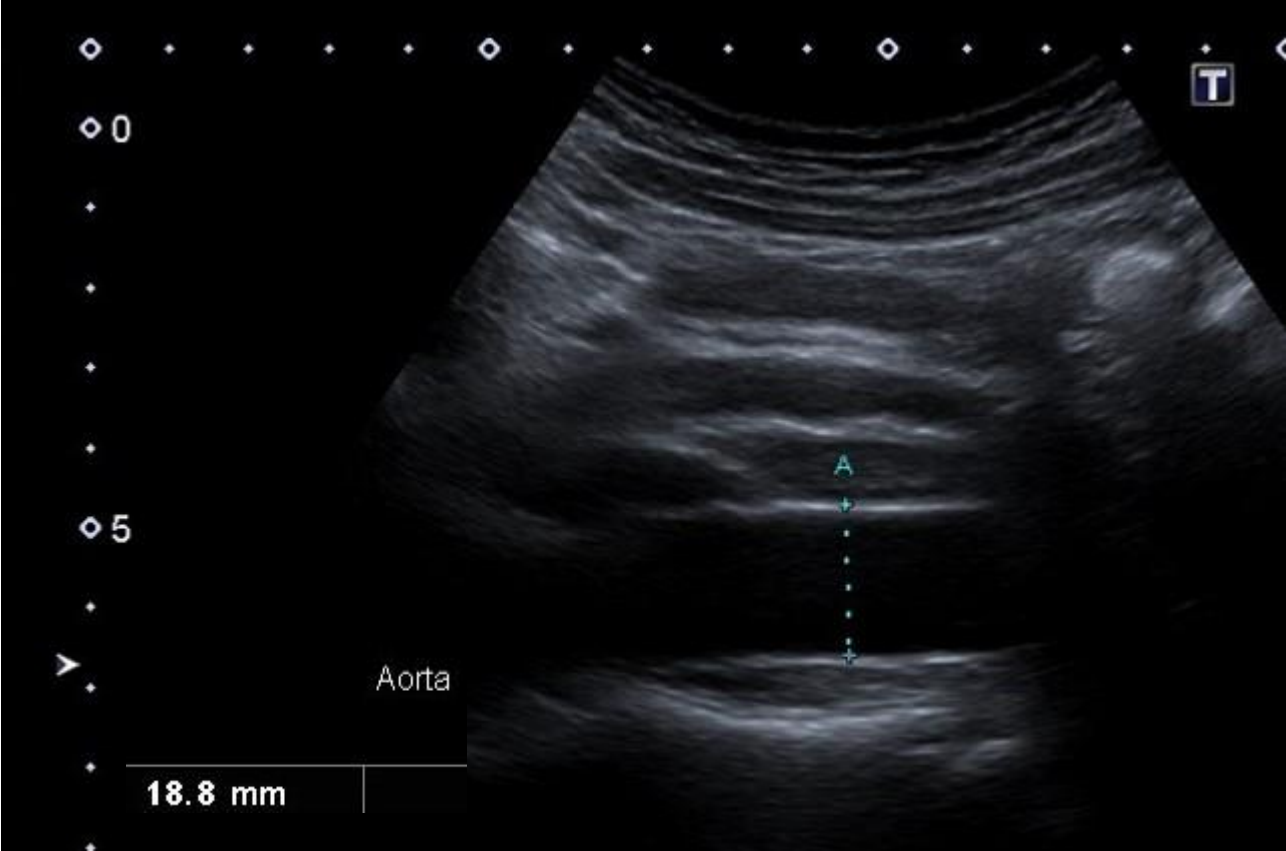
General Medical Case 1

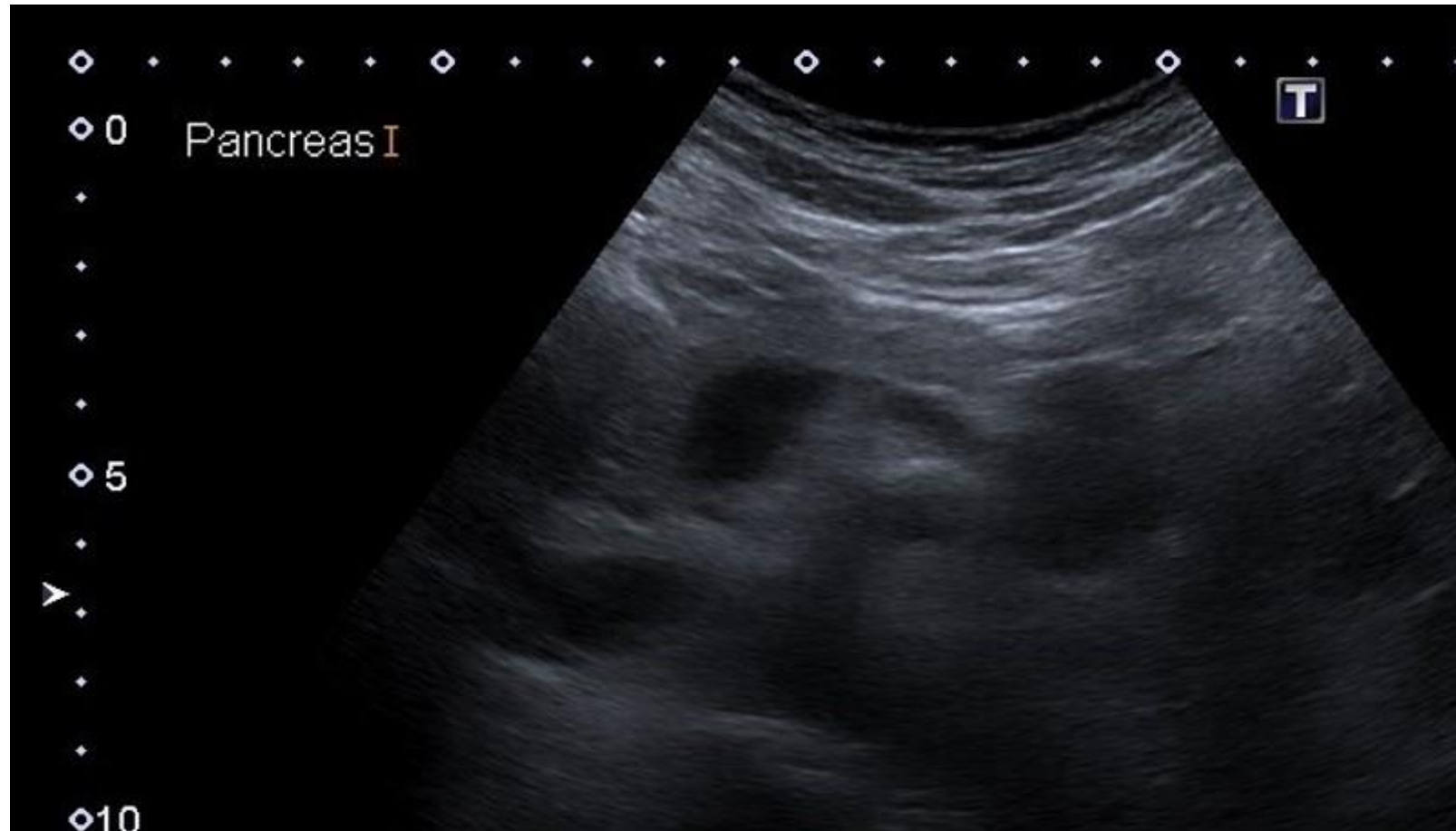
April 2021

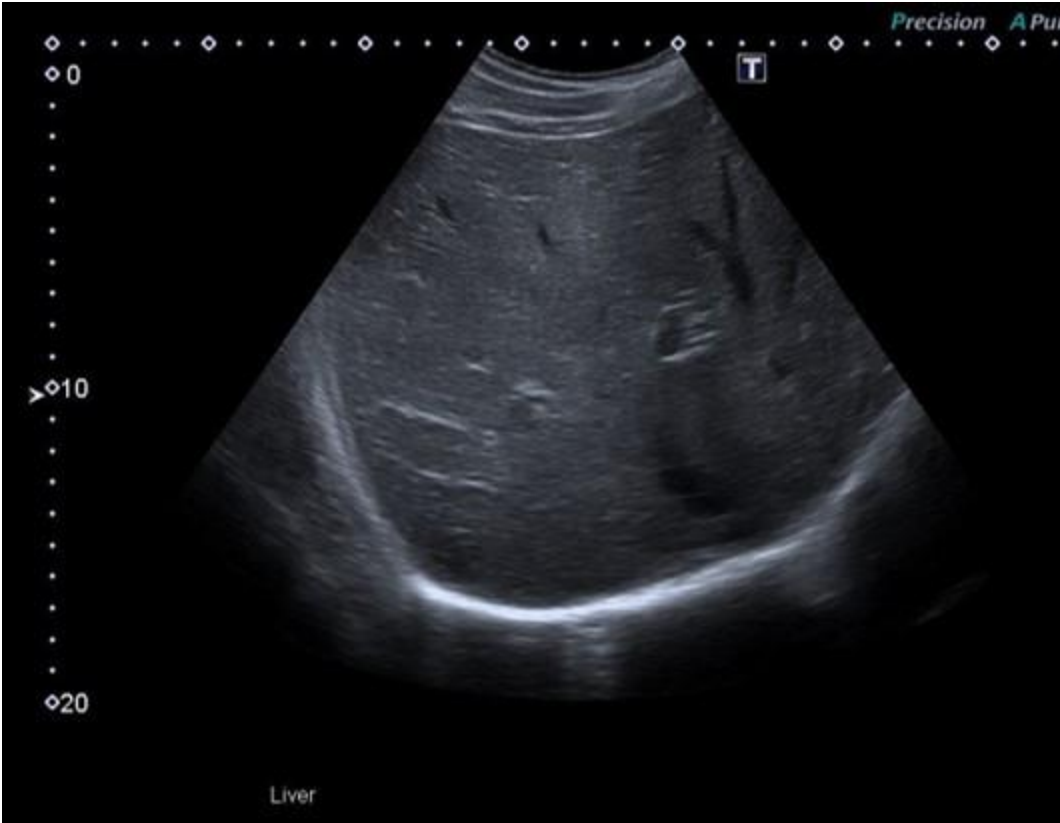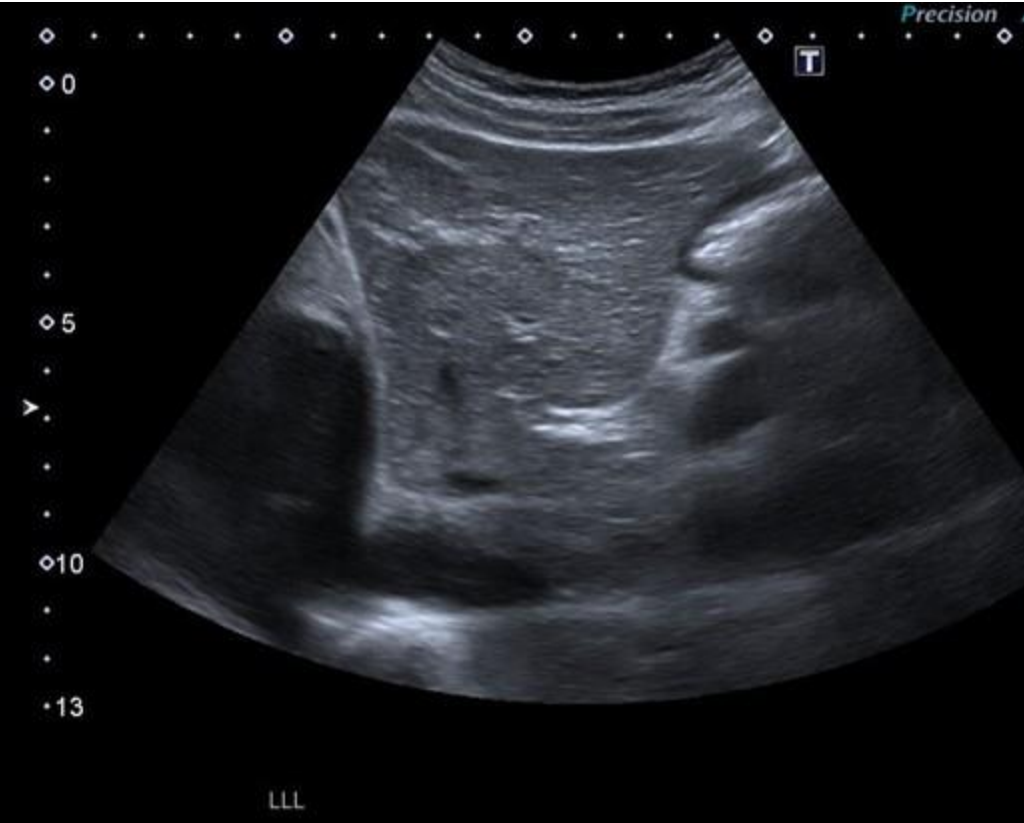Presentation: Middle aged man with new unexplained symptoms for a few weeks and anaemia.

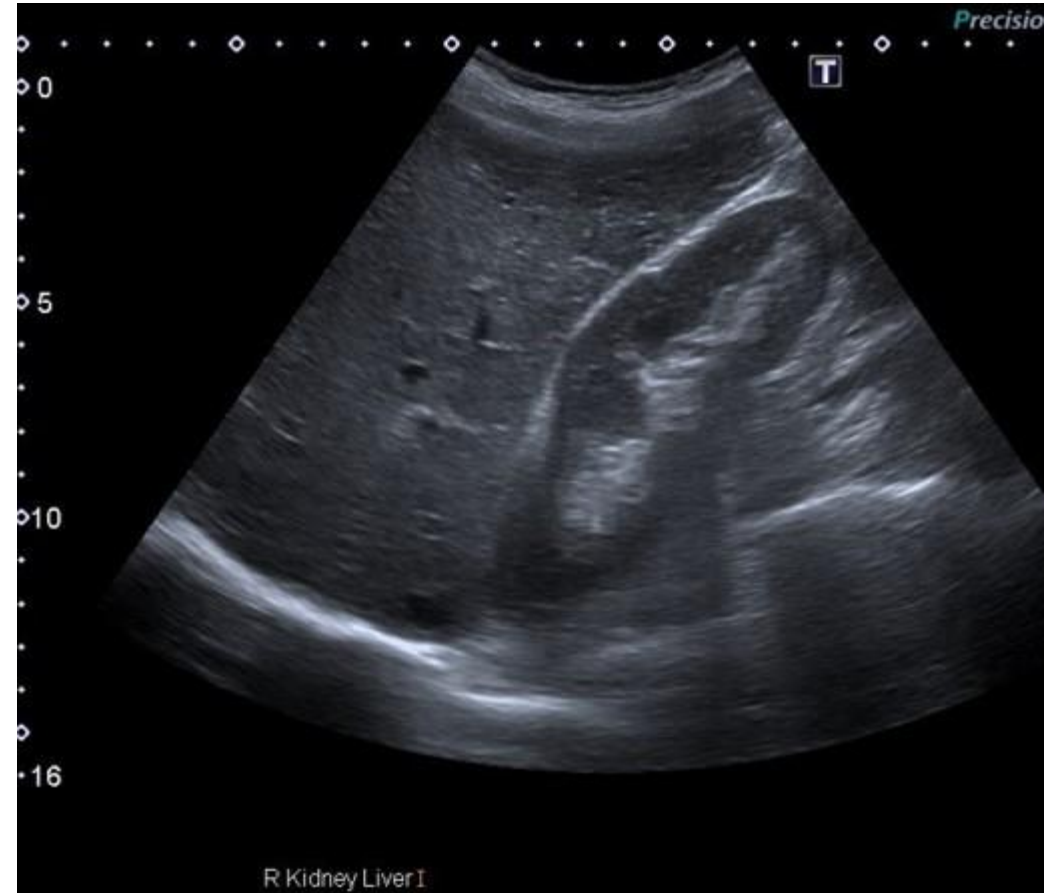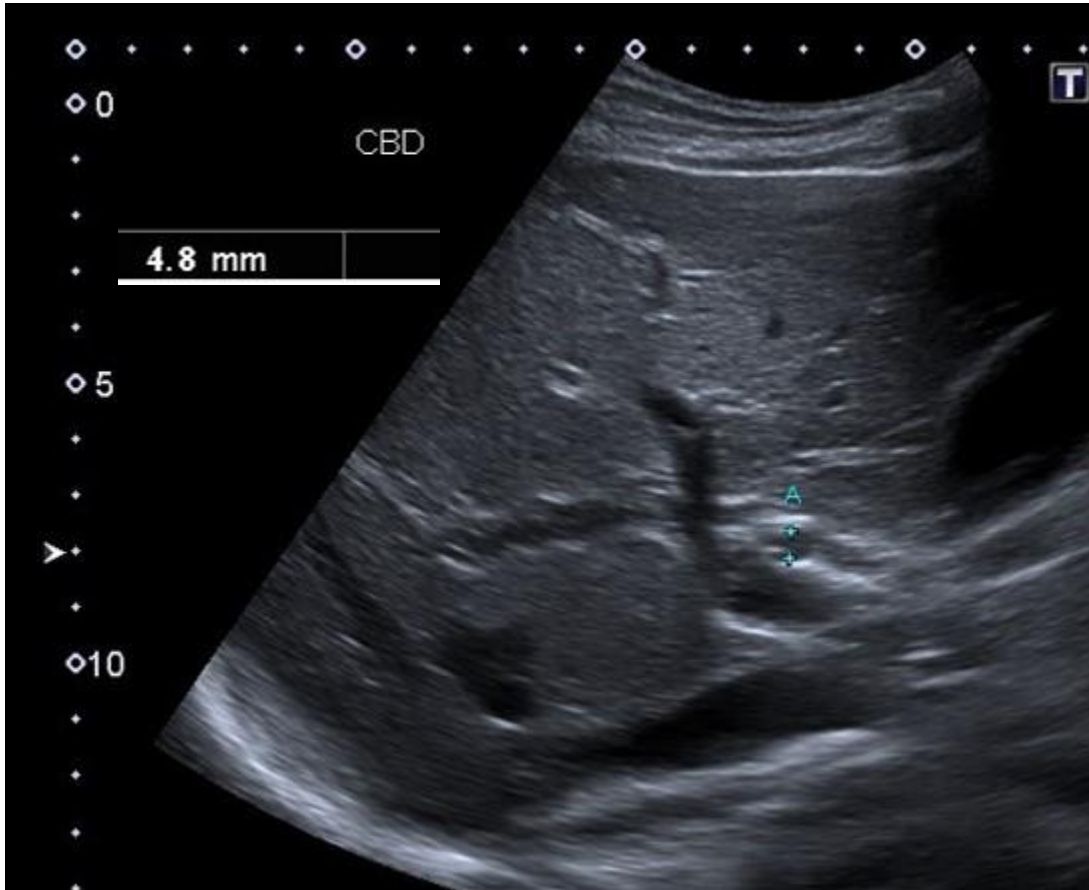
Additional info from patient

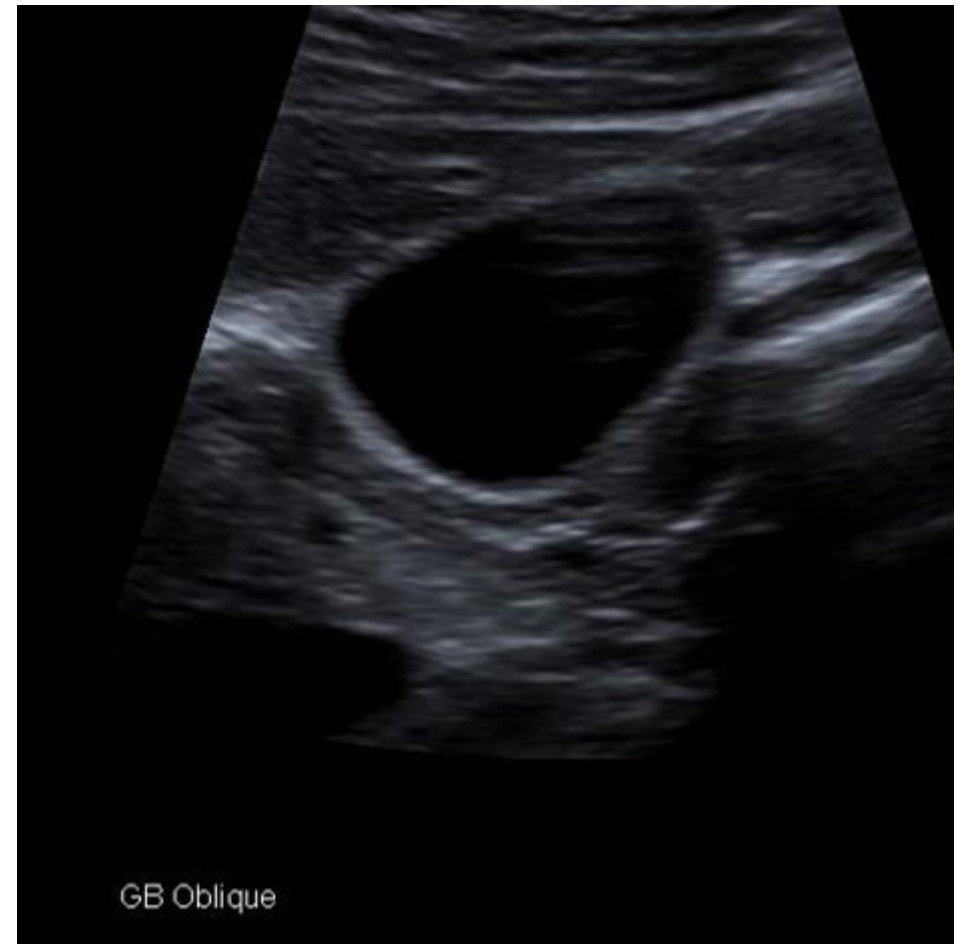
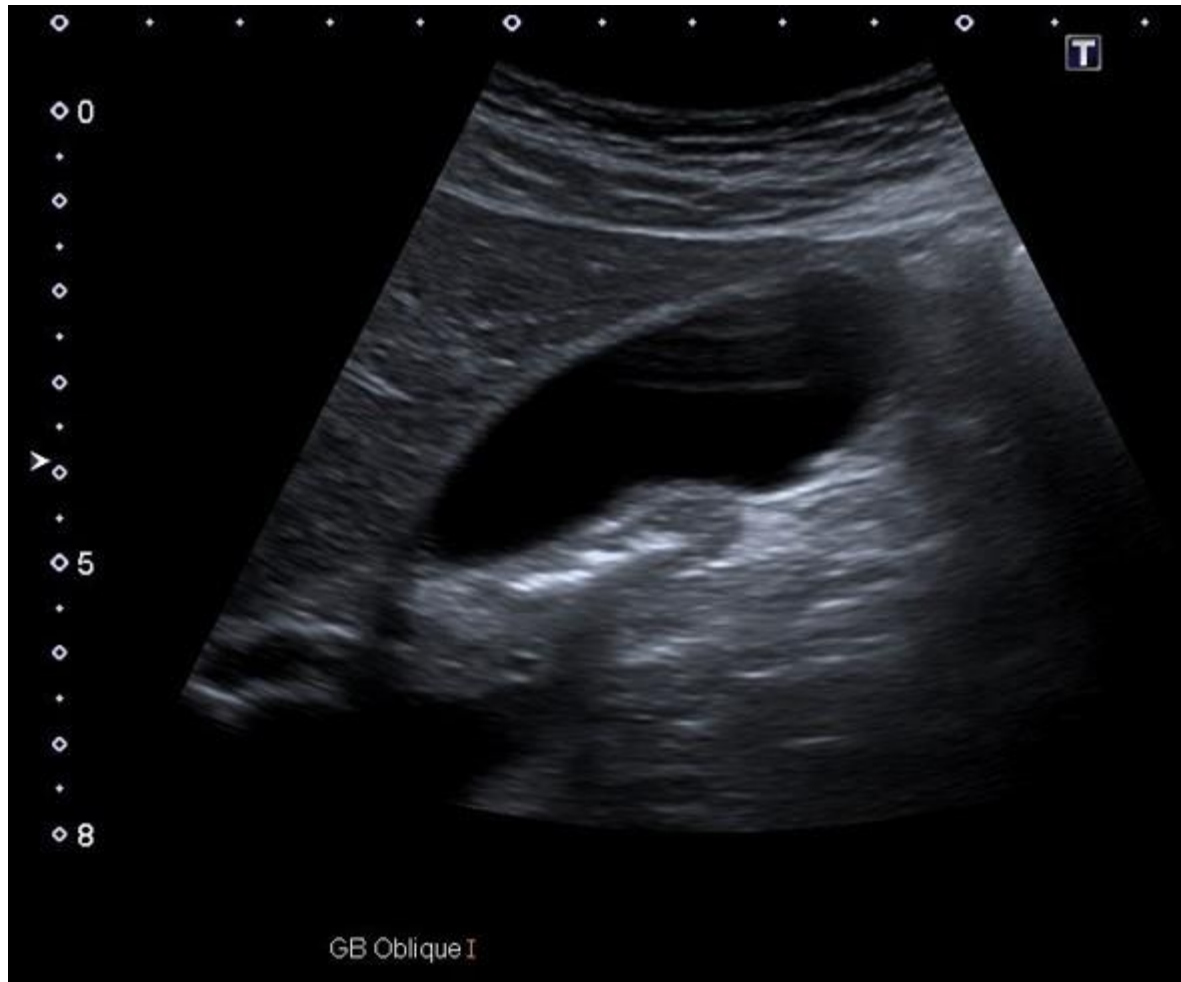- **Within the last SIX MONTHS have you had any of the following?**
- • **Weight loss** **No**
- • **Pain** **Recent aching along the left flank**
- • **Reflux** **Yes - hx of this, on Lansoprazole**
- • **Nausea** **No**
- • **Vomiting** **No**
- • **Diarrhoea** **No**
- • **Constipation** **No**
- • **New onset diabetes (within last three months)** **No**
- • **Night Sweats** **Yes - however long standing**
- • **Groin lumps** **No**

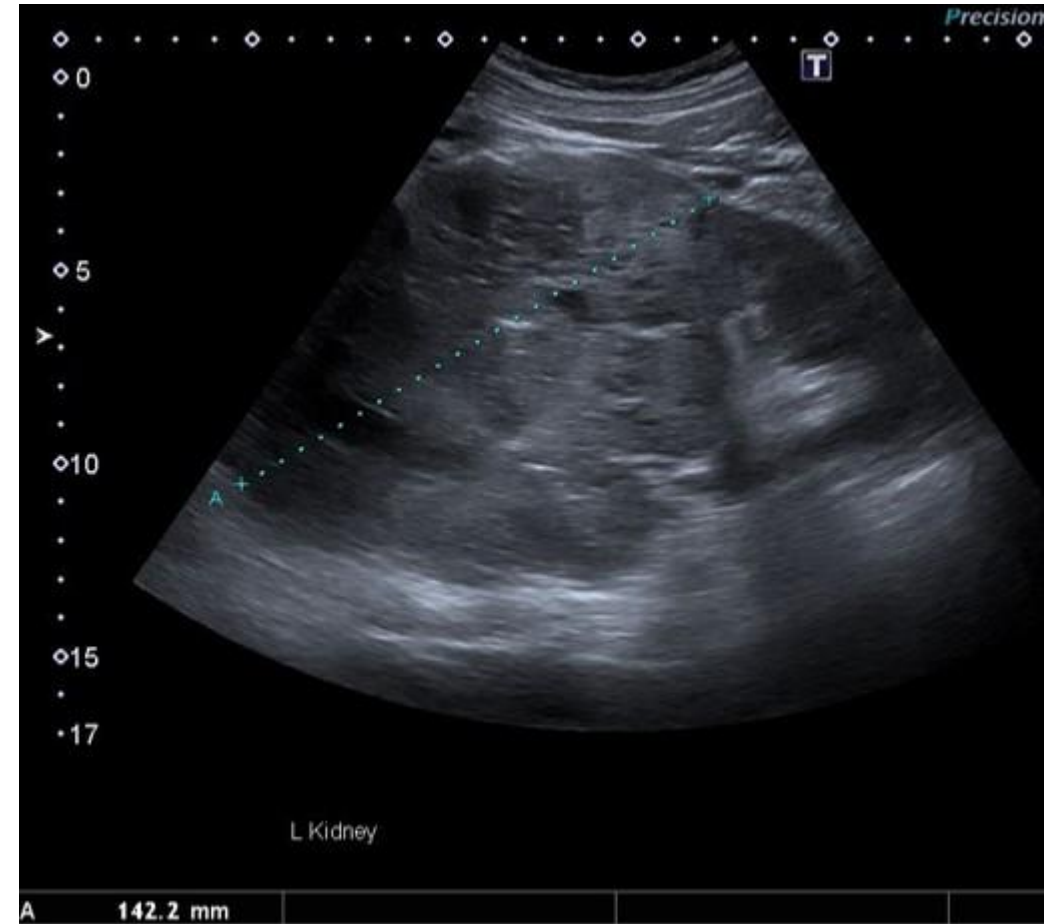
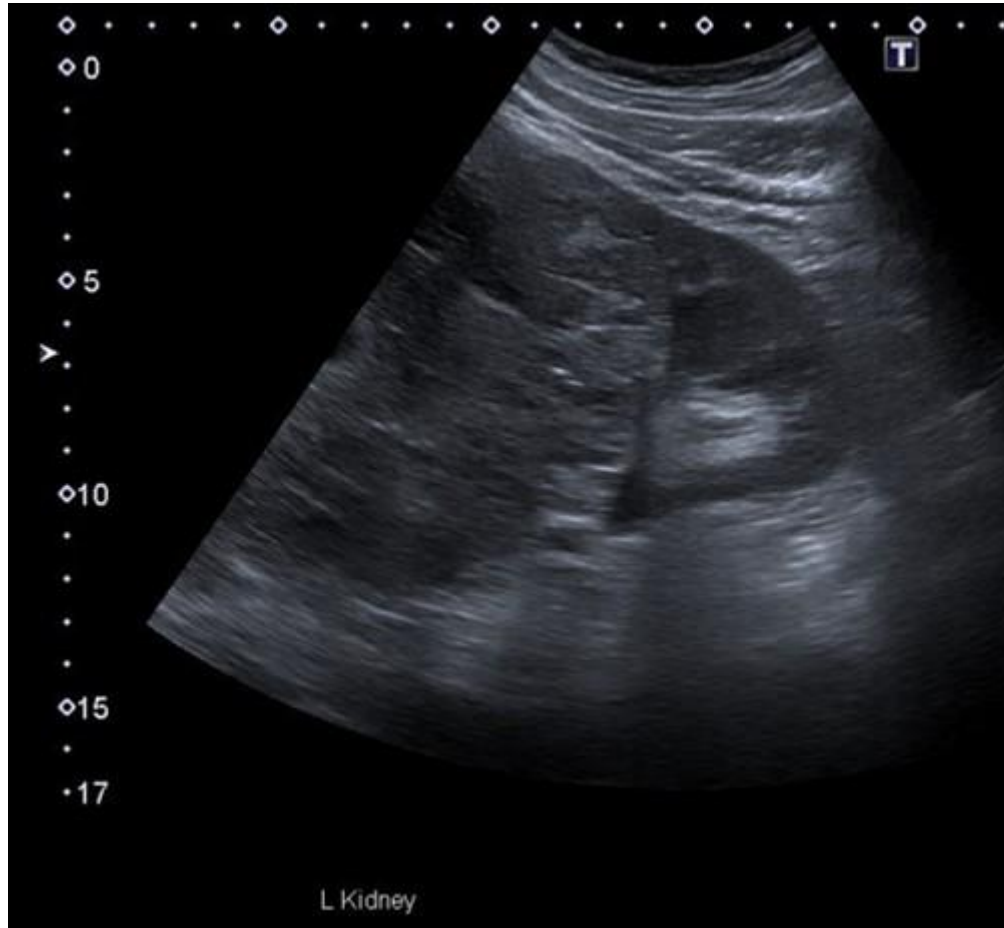


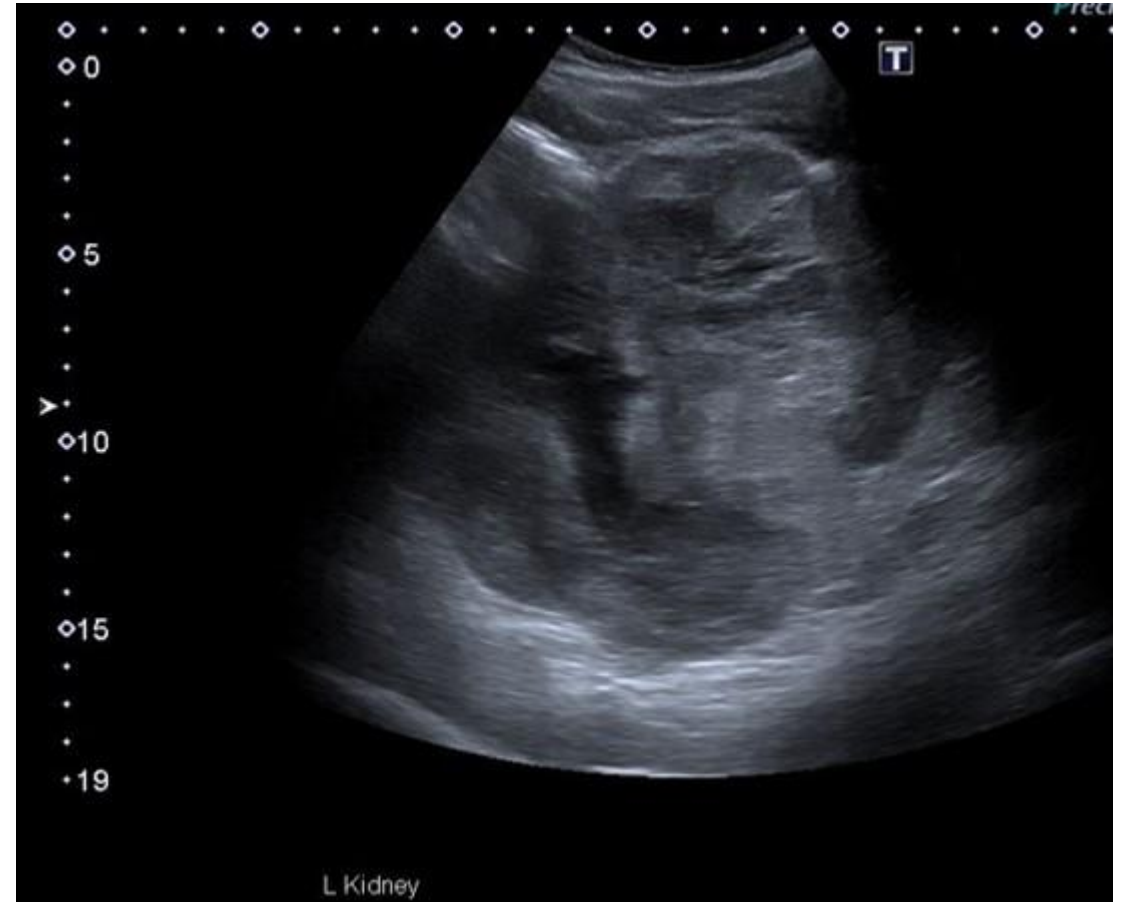
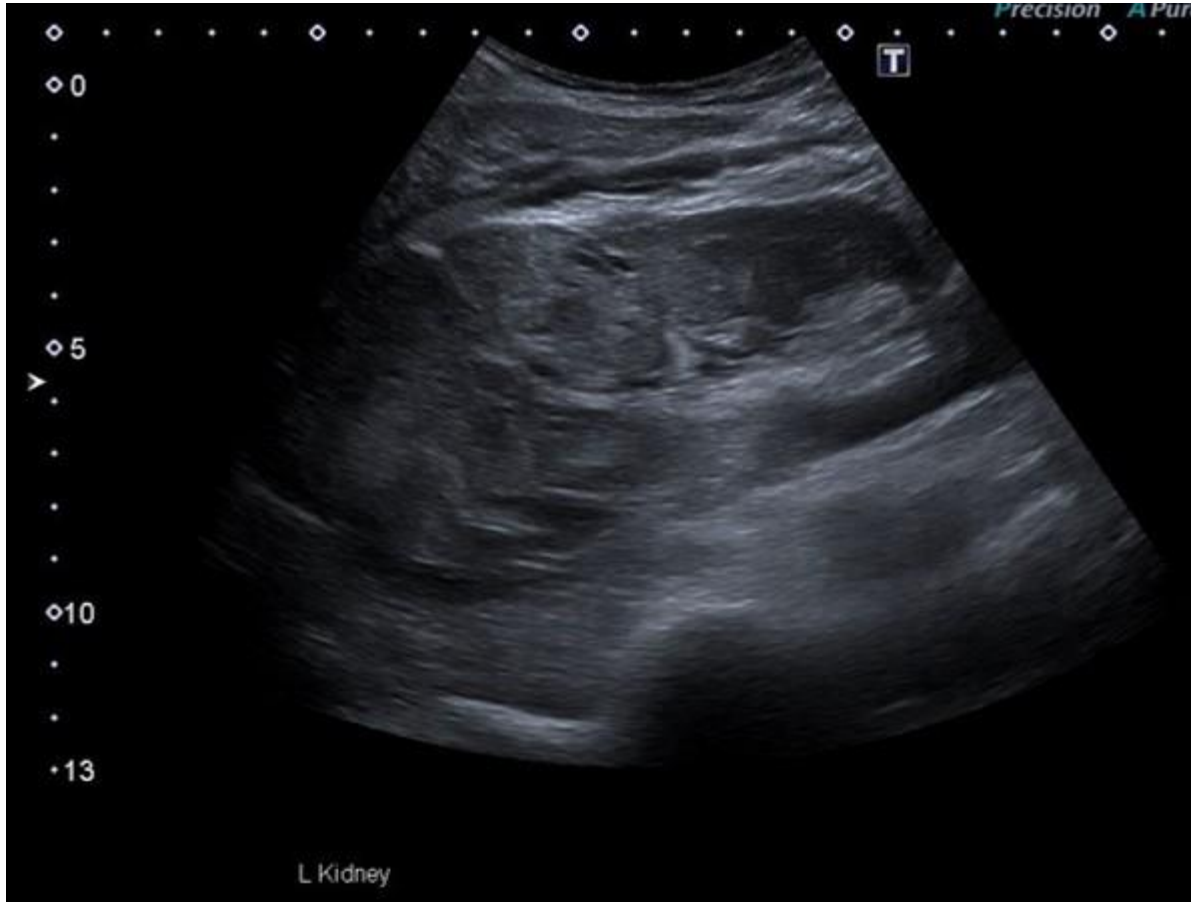




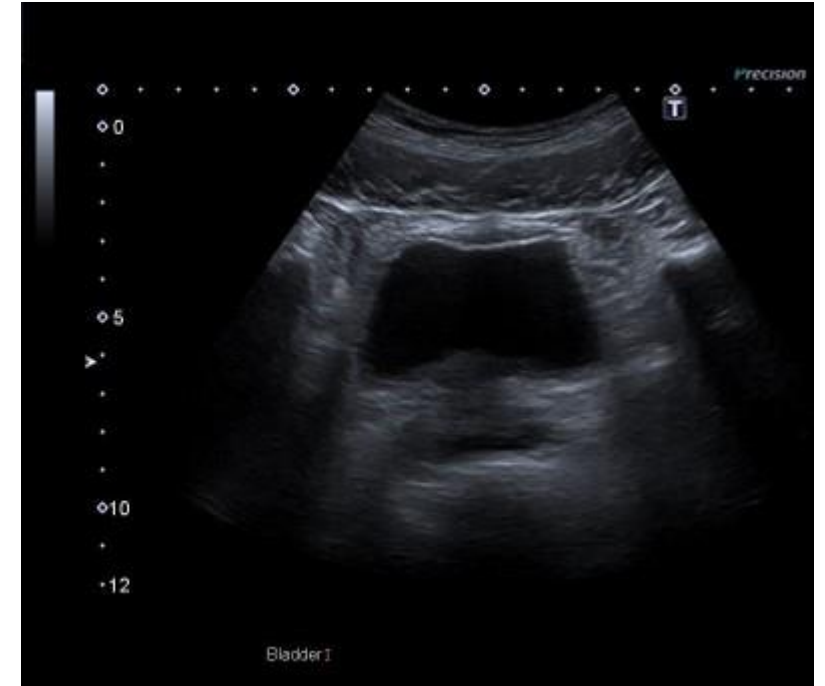
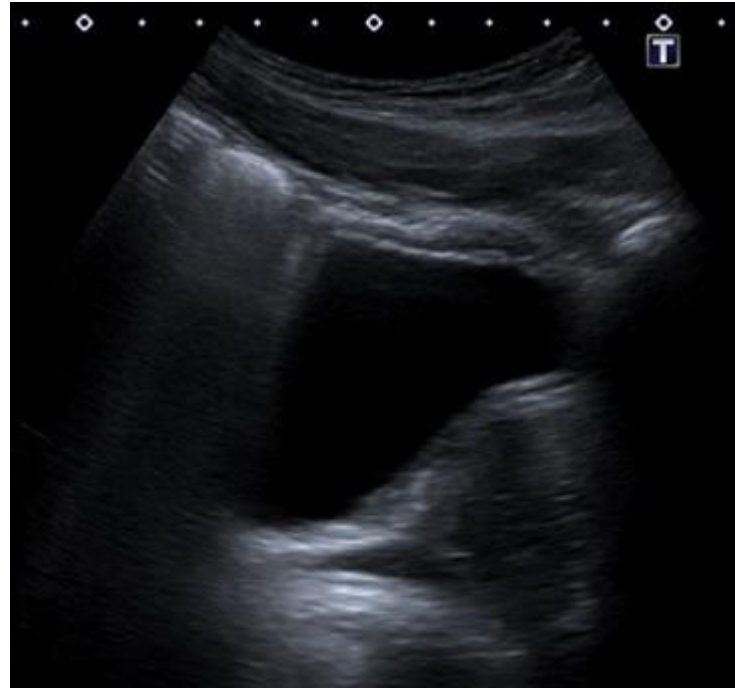
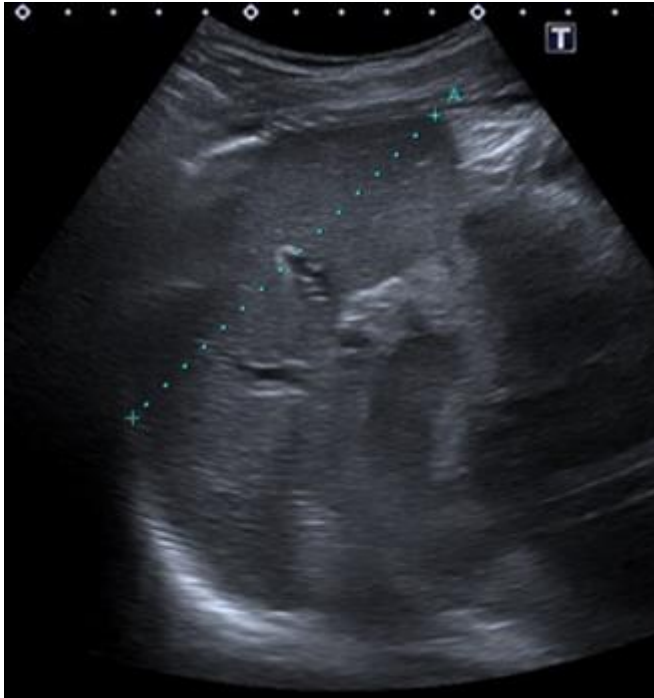



Spleen and bladder



Do not progress to next slide until you have attempted
to write your own report.

US Report

Ultrasound findings:

Arising from the upper pole of the left kidney there is a large heterogeneous, irregular mass. It extends to the midline. Unable to obtain accurate dimensions however it measures in excess of 15cm. It appears to have completely replaced the renal cortex of the upper and mid region of the left kidney. Appearances are consistent with a renal malignancy. I have informed patient that there is a lesion on the left kidney however he is currently unaware of the significance of this.

Other than a few simple cysts throughout the liver, the liver appears normal in size and echotexture. No sinister focal lesions or intrahepatic duct dilatation.

No significant pathology of the gallbladder, bile duct, aorta, spleen, IVC and right kidney.

The urinary bladder is underfilled however no gross pathology. Prostate does not appear enlarged.

Conclusion:

Large left sided renal malignancy. Urgent referral to urology is advised.

This report contains a serious, unexpected or urgent finding, requiring acknowledgement (CODE: YELLOW1)

CT report

Malignancy is confirmed. There are multiple lung metastases predominantly in the lower lobe. The upper abdomen has been scanned in the arterial phase. Left-sided renal cell carcinoma is confirmed. No evidence of hypervascular metastases. Normal appearance of the right kidney.

Left renal malignancy measures 17 x 12 cm. There is extensive venous collaterals and the renal vein is patent. Difficult to confidently identify the left adrenal gland due to the collaterals vessels extending into the splenic vein. The spleen and pancreas are not directly involved.

No significant retroperitoneal lymphadenopathy.

No other significant abnormality identified.

Large left-sided renal cell carcinoma with multiple venous collaterals but no evidence of T4 disease. Multiple lung metastases. Urgent referral to urology is advised.

This report contains a serious, unexpected or urgent finding, requiring acknowledgement (CODE: YELLOW1)

Epidemiology:

Usually between ages of 50 to 70 years

Risk factors:

Smoking, hypertension, obesity, pre-existing renal disease

Symptoms:

Commonly haematuria, flank pain, palpable mass

None – RCC is often an incidental finding